



HAL
open science

Understanding Thoracic Spine Morphology, Shape, and Proportionality

Renaud Lafage, Jeremy Steinberger, Sebastien Pesenti, Ayman Assi, Jonathan Elysee, Sravisht Iyer, Lawrence Lenke, Frank Schwab, Han Jo Kim, Virginie Lafage

► **To cite this version:**

Renaud Lafage, Jeremy Steinberger, Sebastien Pesenti, Ayman Assi, Jonathan Elysee, et al.. Understanding Thoracic Spine Morphology, Shape, and Proportionality. *Spine*, 2020, 45 (3), pp.149-157. 10.1097/BRS.0000000000003227 . hal-03183834

HAL Id: hal-03183834

<https://hal.science/hal-03183834>

Submitted on 30 Apr 2021

HAL is a multi-disciplinary open access archive for the deposit and dissemination of scientific research documents, whether they are published or not. The documents may come from teaching and research institutions in France or abroad, or from public or private research centers.

L'archive ouverte pluridisciplinaire **HAL**, est destinée au dépôt et à la diffusion de documents scientifiques de niveau recherche, publiés ou non, émanant des établissements d'enseignement et de recherche français ou étrangers, des laboratoires publics ou privés.

Understanding Thoracic Spine Morphology, Shape, and Proportionality

Renaud Lafage, MS¹ ; Jeremy Steinberger, MD¹ ; Sebastien Pesenti, MD² ; Ayman Assi, PhD³ ; Jonathan C Elysee, MS¹ ; Sravisht Iyer, MD¹ ; Lawrence G Lenke, MD⁴ ; Frank J Schwab, MD¹ ; Han Jo Kim, MD¹ ; Virginie Lafage, PhD¹

1. Spine research laboratory, Hospital for Special Surgery, New York, NY, USA
2. Aix Marseille Univ, CNRS, ISM, Inst Movement Sci, Marseille, France
3. Laboratory of Biomechanics and Medical Imaging, Faculty of Medicine, University of Saint-Joseph, Beirut, Lebanon
4. Columbia University Medical Center, The Spine Hospital, New York-Presbyterian Healthcare System, New York, NY, USA

Corresponding author:

Virginie Lafage, PhD

525 E 71st St., Belaire 4E

New York, NY 10021

Tel: (917) 260-4601

Fax: (212) 774-2642

Email: virginie.lafage@gmail.com

The manuscript submitted does not contain information about medical device(s)/drug(s).

No funds were received in support of this work.

Relevant financial activities outside the submitted work: board membership, consultancy, grants, royalties, stocks, expert testimony, travel/accommodations/meeting expenses.

Abstract:**Study Design:**

Retrospective review

Objective: The aim of this study was to describe TK in a normal asymptomatic population and to evaluate the association between TK magnitude and its shape.

Summary and Background Data: Understanding spinal anatomy requires a 3-dimensional appreciation of the spine's shape, morphology, and proportions. The customary definition of thoracic kyphosis (TK) is the angle between T4 and T12. However, little is known on the actual shape of TK in adults.

Methods: Asymptomatic volunteers were recruited; demographic data along with full body standing radiographs were recorded. Radiographic data such as T1-12 and T4-12 angles were collected. Maximum TK (MaxTK) and vertebral orientation/tilt were also collected, in addition to cumulative TK and Centered Kyphosis at T7. The cohort was stratified by T1-12 value (<40, 40-60° and >60) and comparisons and regressions were performed afterwards.

Results: 119 subjects were included (average age 50.8 years, 81 female). Mean T1-12 kyphosis was 49.5°, mean T4-12 kyphosis 41.5°, and mean MaxTK was 52.6°. T1 was the most anteriorly tilted vertebra, L1 the most posteriorly tilted; T7 was horizontal, independently of T1-12 value or age. Cumulative kyphosis analysis revealed that the apex of kyphosis was located at T6-T7. Regression analysis predicting the value and the percentage of T1-7 both yielded T1-12 as a predictor (Adj. $r^2=0.32$, Adj. $r^2=0.13$).

Conclusion: Changes in kyphosis distribution in an asymptomatic population suggest that TK is not a simple circle arc: with low TK, 2/3 of the kyphosis is located in the upper part and when TK increases, the distribution of kyphosis will be symmetric around T7. It is possible to predict the amount of kyphosis in the upper part using total kyphosis value. This could help estimate preoperative compensation and predict reciprocal change.

Keywords:

Thoracic Kyphosis, Thoracic Shape, Thoracic Morphology, Normative alignment

Level of Evidence: 3

Key Points

1. T1-12 was more representative of the maximum kyphosis and should be taken as a reference when evaluating TK.
2. Our results suggest that measuring T4-12 kyphosis tends to underestimate the maximum kyphosis in the whole spine and that T1-T12 is a more appropriate description of “thoracic kyphosis.”
3. Most of the curvature located proximal for low TK values, and even distribution for high TK values.
4. T1 was the most anteriorly tilted vertebrae, while L1 was the most posteriorly tilted vertebrae. T7 was the most horizontal vertebrae independent of TK or age.
5. An improved understanding TK is a critical first step to a better understanding what drives surgical failures in this area - adjacent segment disease, DJK, PJK, and PJF.

Introduction:

Understanding spinal anatomy requires a 3-dimensional appreciation of the spine's shape, morphology, and proportions. To comprehend pathophysiology and correction, one has to appreciate sagittal, coronal, and axial 3-dimensionality. Restoring a diseased spine to a globally balanced state in spinal deformity is instrumental to successful outcomes. In adult spinal deformity, studies have shown that postoperative sagittal malalignment results in lower Health-Related Quality of Life (HRQoL), higher revision rates, and residual pain¹.

The primary drivers of deformity are vastly different in adolescents versus adult patients. In Adolescent Idiopathic Scoliosis (AIS), the major concern is coronal deformity², whereas in adult spinal deformity, restoring sagittal alignment is paramount³. Because the loss of lumbar lordosis has been recognized as a significant driver of adult spinal deformity⁴, a large amount of research has focused on lumbar spine shape and morphology.

Areas of investigation in the lumbar spine have included: age related changes^{5,6} and the relationship between lordosis and pelvic morphology⁷. Recent studies have gone beyond "global alignment" and have begun to focus on the morphology of the lumbar spine; namely, the position of the apex of lumbar lordosis⁸, the distribution of normal lumbar lordosis and the segmental angles of the lumbar vertebrae⁹. These avenues of investigation have created a sophisticated understanding of lumbar lordosis that allows for patient-specific alignment parameters based on pelvic morphology and age¹⁰.

Despite our progress in understanding lumbar morphology, very little is known about thoracic alignment in adults. Understanding normal thoracic kyphosis (TK) is critical given the burden of proximal junctional kyphosis (PJK) in adult deformity surgery; there is already evidence, for instance, to suggest that a lack of proper restoration of TK is associated with PJK¹¹. This study aims to address the shortcomings in the existing literature. Using a cohort

of asymptomatic adults, we describe: “normal” TK in terms of regional and segmental angles, ideal parameters associated with TK, changes in TK with age, and the evolution of TK shape as it related to changing kyphosis.

Methods:

This was a retrospective review of a prospective single center database of asymptomatic adult volunteers. Exclusion criteria for the database included prior spinal surgery, previous hip or knee arthroplasty, lower limb realignment (due to trauma or osteotomy), disabling back pain or degenerative spine conditions requiring any intervention (physical therapy, corticosteroid injection, etc.), inability to walk, history of neuromuscular or inflammatory conditions, and pregnancy. Informed consent was obtained from each individual before study enrollment. A total of 119 asymptomatic volunteers were recruited at a single center (Washington University School of Medicine, St Louis, MO, USA). Institutional Review Board (IRB) approval was obtained before study initiation.

Data collection

Demographic information collected included age, gender, weight, Body Mass Index (BMI) and height. All patients underwent full-body biplanar stereoradiographic images (EOS imaging, Paris, France)¹², which acquires images of the entire skeleton using low radiation. For radiographic acquisition, subjects were asked to stand naturally placing their fists on their shoulders with with arms bent at 45 degrees. Two trained independent observers measured radiographic parameters using validated software (Spineview; ENSAM laboratory of Biomechanics, Paris, France)¹³. Radiographic parameters collected included pelvic incidence (PI), pelvic tilt (PT), lumbar lordosis (LL), pelvic incidence minus lumbar lordosis (PI-LL), T1 pelvic angle (TPA), and sagittal vertebral axis (SVA) (Figure 1). In addition, this study analyzed thoracic kyphosis by measuring T4-T12 kyphosis (the angle between the superior

endplate of T4 and the superior endplate of T12) and T1-T12 kyphosis (the angle between superior endplate of T1 and the superior endplate of T12) as well as T5-T12 kyphosis and T2-T5 kyphosis (Figure 1). Maximum thoracic kyphosis was measured as the angle between the two superior endplates of the two most tilted thoracic vertebrae in the sagittal plane. Segmental measurements included: the slope of every superior and inferior endplate of thoracic vertebrae, the segmental kyphosis at each level between T1 and T12 (the angle between the inferior endplate of one level with the superior endplate of one level above), the cumulative kyphosis (the angle between a given level and the T12 inferior endplate), and the centered kyphosis (the angle between a given level and T7 superior endplate) (Figure 2). By convention a lordotic curvature will be reported using a positive value while a kyphotic curvature will be reported using a negative value. Similarly, slope of every endplate were reported using signed values (positive=tilted forward; negative=tilted backward).

Statistical analysis

Mean values were collected for demographic data and radiographic parameters. Descriptive statistics were provided for TK values, both traditional kyphosis measurements (T4-T12 and T1-T12) and for maximum kyphosis. The average slope of each thoracic vertebra between superior and inferior plates was analyzed to define the sagittal orientation of the vertebra. The relationship between thoracic kyphosis and patient characteristics (demographic data and pelvic morphology) was analyzed using a Pearson correlation test. Finally, the cohort was stratified by maximum thoracic kyphosis value into 3 groups: small kyphosis (below 25th percentile); average kyphosis (between 25th and 75th percentile); large kyphosis (above 75th percentile). A comparison of the segmental orientation between the 3 groups of thoracic kyphosis was performed using an ANOVA.

Results

Cohort description

The study group consisted of 81 females and 38 males. The average age was 50.8 ± 17.0 years, ranging from 22 to 78 year old with approximately 20 patients per decade. Mean height $168\text{cm} \pm 9$, mean weight $80.1\text{kg} \pm 19$ and mean BMI was $28 \pm 6.0 \text{ kg/m}^2$. The mean PI was $52^\circ \pm 11.4$, PT $14^\circ \pm 7.7$, lumbar lordosis $58.1^\circ \pm 13$, PI-LL of $-6.1^\circ \pm 12.5$, TPA of $8.4^\circ \pm 8.5$, T1SPi of $-5.6^\circ \pm 3.6$, and SVA $-9\text{mm} \pm 45$.

Thoracic kyphosis description:

The mean and median values of the thoracic kyphosis are listed on table 1. The median value of T4-T12 was $-41.5^\circ \pm 12.7$; T1-T12 was $-49.5^\circ \pm 13.3$. For the maximum kyphosis the median was -51.9° ; the 25th percentile was -60.8° while the 75th percentile was -44° .

The comparison between traditional levels of measurement of TK and maximum kyphosis revealed significant differences between different levels and their measurements (Table 1). T5-T12 represented $67.5\% \pm 13.2\%$ of the maximum kyphosis, T4-T12 $78.2\% \pm 11.3\%$ of the maximum kyphosis, T2-T5 $32.7\% \pm 12\%$ of the maximum kyphosis, and T1-T12 made up $93.6\% \pm 7.2\%$ of the maximum kyphosis.

The analysis of the orientation of each vertebra revealed that L1 had a tilt of $-20^\circ \pm 8.2$, the most posteriorly tilted of the vertebrae. T7 represented the apex of kyphosis and was the most horizontal (least tilted) at $-0.1^\circ \pm 7.4$. T1, with an orientation of $26.5^\circ \pm 9.5$, had the most anterior tilt. T9 vertebra was the most stable with the lowest standard deviation ($-10.8^\circ \pm 6.9$). There was a symmetry observed in the number of tilted vertebrae moving away from T7; six inferior vertebrae were posteriorly tilted from L1 to T8 and six superior vertebrae were anteriorly tilted from T6 to T1 (Figure 3).

While the number of tilted vertebrae around T7 was consistent, the distribution of kyphosis around T7 was not. There was higher segmental kyphosis from T1 to T7 than from T7 to L1. The maximum segmental kyphosis was located between T6 and T7 with an increase of -6.9° (Figure 4).

Association with demographic parameters

When age was compared to TK, a negative correlation was found with thoracic kyphosis for traditional levels ($r=-0.244$ for T5-T12, $r=-0.240$ for T4-T12, $r=-0.253$ for T1-T12, all $p<0.05$) as well as maximum kyphosis ($r=-0.242$, $p=0.008$), except for the T2-T5 level ($p=0.794$). No significant correlation was found with other demographic features (height, weight, BMI). There was no significant correlation with pelvic morphology (PI and PT). Maximum kyphosis was significantly smaller for women than men (-56.7 vs -50.7 $p = 0.022$) but other TK measurements were not significantly different between sexes.

Stratification by TK values

30 patients were having a maximum TK below the 25th percentile, 55 between 25th and 75th percentile and 34 above the 75th percentile. Patients in the low TK group predictably had smaller values of segmental kyphosis and global kyphosis. For the low, medium, and high kyphosis, respectively, the T5-T12 group values were -23.1° , -35.2° , -49.1° , T4-T12 values were -28.3° , -40.3° , -55.1° , T2-T5 values were -13.7° , -16.5° , -20.4° , and T1-T12 values were -33.8° , -48.3° , -65.1° (all $p < 0.001$). The maximum kyphosis was -37.7 , -51.0 , and -69.0 in the low, medium, and high kyphosis groups, respectively.

As global kyphosis increased, increased segmental kyphosis and larger changes in vertebral orientation were observed. Except for T8 and T9 ($p=0.696$ and $p=0.071$ respectively), there were significant differences in vertebral orientation between the low, medium and high TK groups at all levels. The T7 vertebra, however, remained relatively horizontal in all three

groups (slope of -2.6° , -1.0° and 3.5° in low, medium and high TK groups, respectively) (Figure 5).

Similar to vertebral orientation, increases in segmental kyphosis were seen across the entire thoracic spine with higher TK with the exception of T12-L1 and T1-T2 levels ($p=0.161$ and $p=0.580$ respectively).

The centered kyphosis analysis revealed that as maximum TK increased, the thoracic spine became more symmetric around T7. For small TK, T7-L1 kyphosis was -10.8° compared to T1-T7 kyphosis which was -21.4° . For medium TK, T7-L1 kyphosis is -18.8° compared to T1-T7 kyphosis which is -26.1° . For larger TK, T7-L1 kyphosis is -29.9° , compared to T1-T7 kyphosis which is -32.3° . Proportion between L1-T7 and T1-T7 increase significantly between TK group (low TK: 57.5% vs medium TK: 77.5% vs high TK: 111% $p = 0.001$) (Figure 6).

Discussion:

Surgery for spinal deformity correction aims to restore balance and normal alignment. In order to accomplish this, understanding the thoracic spine as a 3-dimensional structure is critical. Despite cervicothoracic, thoracic, and thoracolumbar deformity representing a large proportion of the deformities treated today, relatively little is known about thoracic shape and the distribution of thoracic kyphosis. Our results address this deficiency in the literature by providing the first detailed description of normative thoracic alignment in a cohort of asymptomatic adults. Using a variety of kyphosis parameters in 119 asymptomatic volunteers with EOS imaging, we display a remarkable consistency of thoracic shape in healthy patients, T7 serving as a reliable apex regardless of age and proportionality above and below T7 staying consistent throughout.

Our results suggest that measuring T4-12 kyphosis tends to underestimate the maximum kyphosis in the whole spine by approximately 20%, as well as T5-T12 by approximately 30%, and that T1-T12 is a more appropriate description of “thoracic kyphosis” with more than 90% of the maximum thoracic. In addition, we show that the distribution of kyphosis is not symmetric throughout the thoracic spine. Similar to how the majority of lordosis is derived from L4-S1, we show that changes in TK cannot be modeled as a “circle.” Indeed, TK should be considered a more sinusoidal than the characteristic “S” shape. There is a smaller progression on the ends with maximum progression seen in the middle. With regard to orientation of vertebra, T1 was the most anteriorly tilted vertebrae, while L1 was the most posteriorly tilted vertebrae. T7 was the most horizontal vertebrae independent of TK or age.

In addition to providing a global understanding of shape in our analysis, contrary to the value of TK, the shape of the TK was not a constant. Patients who exhibit smaller TK levels have more kyphosis seen on the top of the thoracic spine, while patients with larger kyphosis have an equal percentage distributed throughout the upper and lower spine. This shows that kyphosis shape and proportion is more than a simple measurement of kyphotic magnitude. As seen in the centered shape model, there was a significant increase in T1-T7 angle within the TK groups and there was a significant correlation between TK and proportionality – as the TK increased, the proportion of the curve coming from above decreased and the thoracic kyphosis become more symmetric (Figure 7).

Although tremendous progress has been made in the conceptual understanding of the lumbar spine and its shape, thoracic morphology remains an abstruse entity. Relatively few investigations of normal TK have been performed. Perriman described TK as sagittal plane curvature from T1-T12¹⁴. Using a flexible electrogoniometer, they showed comparable measurements with the standard measurement with Cobb angle. Lorbergs describe TK as the angle from T4-T12¹⁵ and showed that thoracic kyphosis was not associated with physical

function in women or men who were high functioning. Other works have shown a “normal” kyphosis to range from 20-50 degrees¹⁶ between T4 and T12 and that excessive thoracic kyphosis can lead to decreased mobility and loss of physical independence¹⁷. For assessment of the thoracic kyphosis on AIS, the Lenke Classification reported a “normal” T5-T12 thoracic kyphosis angle between 10 and 40°¹⁸

The effect of age on TK is well documented. This study’s results are consistent with the literature showing that age correlates significantly with TK ($r=-0.253$): as age increases, the TK increases. Possible contributing factors include habitual posture, occupational tolls, and decreased muscle tone¹⁹. With the cumulative centered angle measurements, the effect of age did not change the symmetry of the shape. The symmetry of the spine was preserved even in older age.

Notably, T7 was consistently preserved as the apex of the kyphosis regardless of patient age and the level of overall kyphosis. The “conserved” orientation of T7 suggests that it may play an important role in spinal balance. While the current study was conducted in a cohort of asymptomatic patients, it would be interesting to observe how the thoracic apex changes with progression of sagittal imbalance and activation of thoracic compensation. Additionally, it would be interesting to observe if fusions extending into the thoracic spine (cervicothoracic or thoracolumbar) alter the thoracic apex and if these changes predispose to junctional complications. These are questions are of tremendous clinical relevance and represent an important area of future investigation.

Proximal Junctional Kyphosis (PJK) can develop in 23-41% of patients undergoing surgery for spinal deformity²⁰. Despite recent focus on its pathogenesis, risk factors, prevention, and treatment, PJK remains a formidable complication. Increased thoracic kyphosis was an important predictor of PJK²¹ but this may be an oversimplification of a

complex morphological issue. The decision of the upper instrumented vertebra (UIV) plays an important role of PJK. The UIV selected in the upper and lower thoracic spine has been shown to correlate with PJK²². Patients exhibiting preoperative thoracic compensation were more likely to develop proximal junctional kyphosis²³. The data from this study may help modify the risk of PJK; evaluating deviation from “ideal thoracic shape” in patients with deformity and PJK, perhaps the risk of PJK can be modified. In evaluating preoperative interventions, the superior portion of TK can be predicted using the total value of kyphosis. This can be used to estimate pre-operative compensation, predict reciprocal change, and potentially PJK as hypothesized by previous study²³.

There are several limitations to this study. The relatively small size of our cohort (119 patients) limits the generalizability of our findings. Second, we did not use three-dimensional or virtual models, which may have enhanced the ability to understand thoracic shape. Third, because we wished to define thoracic alignment, we did not correlate kyphosis with cervical and lumbar measurements in this study. Understanding how this shape changes with lumbar and cervical parameters is an important area of future investigation. Studies have shown, for example, that a change in kyphosis is an important compensatory method in patients with sagittal deformity²⁴. Finally, the limited sample size did not allow for a deeper analysis on the thoracic shape by demographic information. Further investigation with a larger cohort may elucidate potential differences in thoracic kyphosis shape by demographic groups.

Despite these limitations, the current work represents the most complete evaluation of “normal” thoracic shape in an asymptomatic patient population. An improved understanding TK is a critical first step to a better understanding what drives surgical failures in this area - adjacent segment disease, Distal Junctional Kyphosis or Proximal Junctional Kyphosis.

References

1. Glassman SD, Berven S, Bridwell K, Horton W, Dimar JR. Correlation of radiographic parameters and clinical symptoms in adult scoliosis. *Spine (Phila Pa 1976)*. 2005;30(6):682-688. doi:10.1097/01.brs.0000155425.04536.f7.
2. Souder C, Newton PO, Shah SA, Lonner BS, Bastrom TP, Yaszay B. Factors in Surgical Decision Making for Thoracolumbar / Lumbar AIS : It ' s About More Than Just the Curve Magnitude. 2017;37(8):530-535. doi:10.1097/BPO.0000000000000746.
3. Lafage V, Schwab FJ, Patel A, et al. Pelvic tilt and truncal inclination: two key radiographic parameters in the setting of adults with spinal deformity. *Spine (Phila Pa 1976)*. 2009;34(17):E599-606. doi:10.1097/BRS.0b013e3181aad219.
4. Lee C-H, Chung CK, Jang J-S, Kim S-M, Chin D-K, Lee J-K. "Lumbar Degenerative Kyphosis" Is Not Byword for Degenerative Sagittal Imbalance: Time to Replace a Misconception. *J Korean Neurosurg Soc*. 2017;60(2):125-129. doi:10.3340/jkns.2016.0607.001.
5. Iyer S, Lenke LG, Nemani VM, et al. Variations in Sagittal Alignment Parameters based on Age: A Prospective Study of Asymptomatic Volunteers using Full-Body Radiographs. *Spine (Phila Pa 1976)*. 2016;41(23):605-610. doi:10.1097/BRS.0000000000001642.
6. Vialle R, Levassor N, Rillardon L, Templier A, Skalli W, Guigui P. Radiographic analysis of the sagittal alignment and balance of the spine in asymptomatic subjects. *J Bone Joint Surg Am*. 2005;87(2):260-267. doi:10.2106/JBJS.D.02043.
7. Boulay C, Tardieu C, Hecquet J, et al. Sagittal alignment of spine and pelvis regulated

by pelvic incidence: standard values and prediction of lordosis. *Eur Spine J*. 2006;15(4):415-422. doi:10.1007/s00586-005-0984-5.

8. Roussouly P, Gollogly S, Berthonnaud E, Dimnet J. Classification of the normal variation in the sagittal alignment of the human lumbar spine and pelvis in the standing position. *Spine (Phila Pa 1976)*. 2005;30(3):346-353. doi:00007632-200502010-00016 [pii].
9. Pesenti S, Lafage R, Stein D, et al. The Amount of Proximal Lumbar Lordosis Is Related to Pelvic Incidence. *Clin Orthop Relat Res*. 2018;476(8):1603-1611. doi:10.1097/CORR.0000000000000380.
10. Lafage R, Schwab F, Challier V, et al. Defining Spino-Pelvic Alignment Thresholds: Should Operative Goals in Adult Spinal Deformity Surgery Account for Age? *Spine (Phila Pa 1976)*. 2016;41(1):62-68. doi:10.1097/BRS.0000000000001171.
11. Lafage R, Line BG, Gupta S, et al. Orientation of the Upper-most Instrumented Segment Influences Proximal Junctional Disease Following Adult Spinal Deformity Surgery. *Spine (Phila Pa 1976)*. 2017;42(20):1570-1577. doi:10.1097/BRS.00000000000002191.
12. Dubousset J, Charpak G, Dorion I, et al. [A new 2D and 3D imaging approach to musculoskeletal physiology and pathology with low-dose radiation and the standing position: the EOS system]. *Bull Acad Natl Med*. 2005;189(2):287-97; discussion 297-300.
13. Rillardon L, Levassor N, Guigui P, et al. [Validation of a tool to measure pelvic and spinal parameters of sagittal balance]. *Rev Chir Orthop Reparatrice Appar Mot*. 2003;89(3):218-227.

14. Perriman DM, Scarvell JM, Hughes AR, Ashman B, Lueck CJ, Smith PN. Validation of the flexible electrogoniometer for measuring thoracic kyphosis. *Spine (Phila Pa 1976)*. 2010;35(14):E633-40. doi:10.1097/BRS.0b013e3181d13039.
15. Lorbergs AL, Murabito JM, Jarraya M, et al. Thoracic Kyphosis and Physical Function: The Framingham Study. *J Am Geriatr Soc*. 2017;65(10):2257-2264. doi:10.1111/jgs.15038.
16. Willner S. Spinal pantograph - a non-invasive technique for describing kyphosis and lordosis in the thoraco-lumbar spine. *Acta Orthop Scand*. 1981;52(5):525-529. <http://www.ncbi.nlm.nih.gov/pubmed/7331788>.
17. Lydick E, Zimmerman SI, Yawn B, et al. Development and validation of a discriminative quality of life questionnaire for osteoporosis (the OPTQoL). *J Bone Miner Res*. 1997;12(3):456-463. doi:10.1359/jbmr.1997.12.3.456.
18. Lenke LG, Betz RR, Harms JJ, et al. Adolescent idiopathic scoliosis: a new classification to determine extent of spinal arthrodesis. *J Bone Joint Surg Am*. 2001;83-A(8):1169-1181. doi:10.1097/00007632-200101010-00009.
19. Milne JS, Lauder IJ. Age effects in kyphosis and lordosis in adults. *Ann Hum Biol*. 1974;1(3):327-337. <http://www.ncbi.nlm.nih.gov/pubmed/4419577>.
20. Liu F-Y, Wang T, Yang S-D, Wang H, Yang D-L, Ding W-Y. Incidence and risk factors for proximal junctional kyphosis: a meta-analysis. *Eur Spine J*. 2016;25(8):2376-2383. doi:10.1007/s00586-016-4534-0.
21. Mendoza-Lattes S, Ries Z, Gao Y, Weinstein SL. Proximal junctional kyphosis in adult reconstructive spine surgery results from incomplete restoration of the lumbar lordosis relative to the magnitude of the thoracic kyphosis. *Iowa Orthop J*.

2011;31:199-206. <http://www.ncbi.nlm.nih.gov/pubmed/22096442>. Accessed October 15, 2014.

22. Hyun S-J, Lee BH, Park J-H, Kim K-J, Jahng T-A, Kim H-J. Proximal Junctional Kyphosis and Proximal Junctional Failure Following Adult Spinal Deformity Surgery. *Korean J Spine*. 2017;14(4):126-132. doi:10.14245/kjs.2017.14.4.126.
23. Protopsaltis TS, Diebo BG, Lafage R, et al. Identifying Thoracic Compensation and Predicting Reciprocal Thoracic Kyphosis and PJK in Adult Spinal Deformity Surgery. *Spine (Phila Pa 1976)*. August 2018. doi:10.1097/BRS.0000000000002843.
24. Klineberg E, Schwab FJ, Ames CP, et al. Acute reciprocal changes distant from the site of spinal osteotomies affect global postoperative alignment. *Adv Orthop*. 2011;2011:415946. doi:10.4061/2011/415946.

ACCEPTED

Figure Legends:

Figure 1: Radiographic parameters included on the current analysis: Radiographic parameters collected included pelvic incidence (PI), pelvic tilt (PT), lumbar lordosis (LL), T1 pelvic angle (TPA), sagittal vertebral axis (SVA), Thoracic Kyphosis between T4 and T12 (T4-T12), between T1 and T12 (T1-T12), between T5 and T12 (T5-T12) and between T2 and T5 (T2-T5).

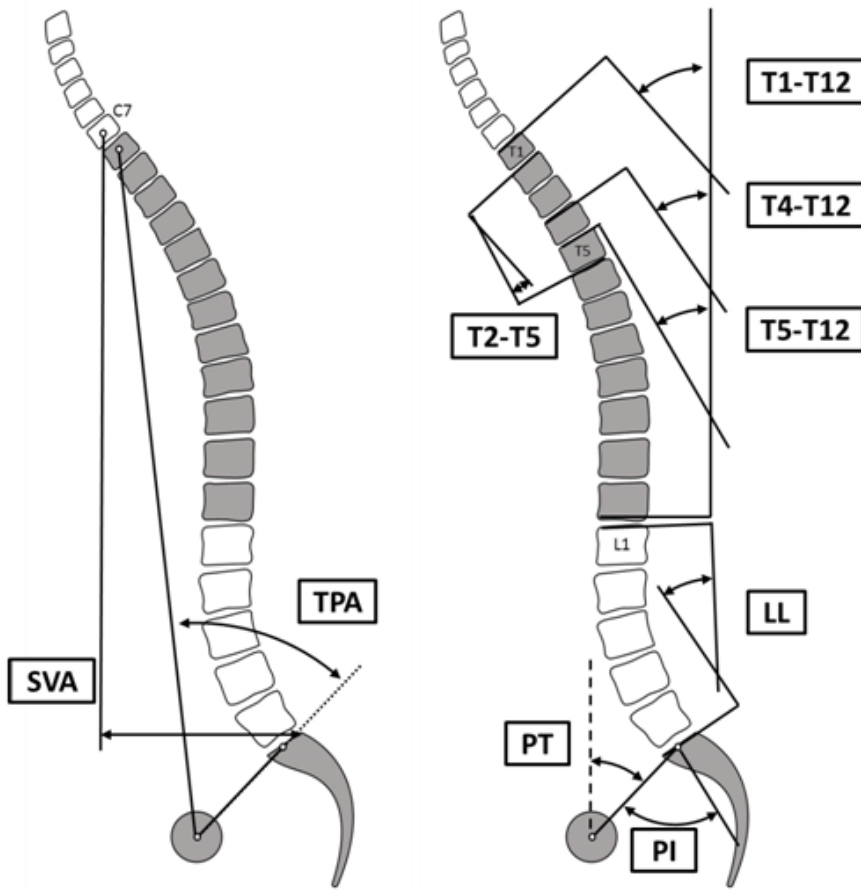


Figure 2: Radiographic parameters related to the thoracic spine: Segmental Kyphosis, Cumulative Kyphosis and Centered Kyphosis

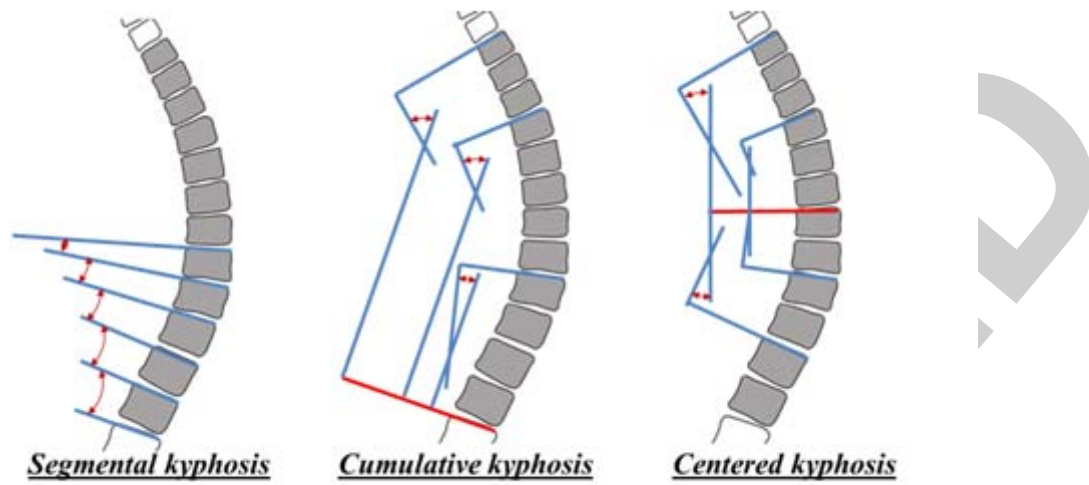
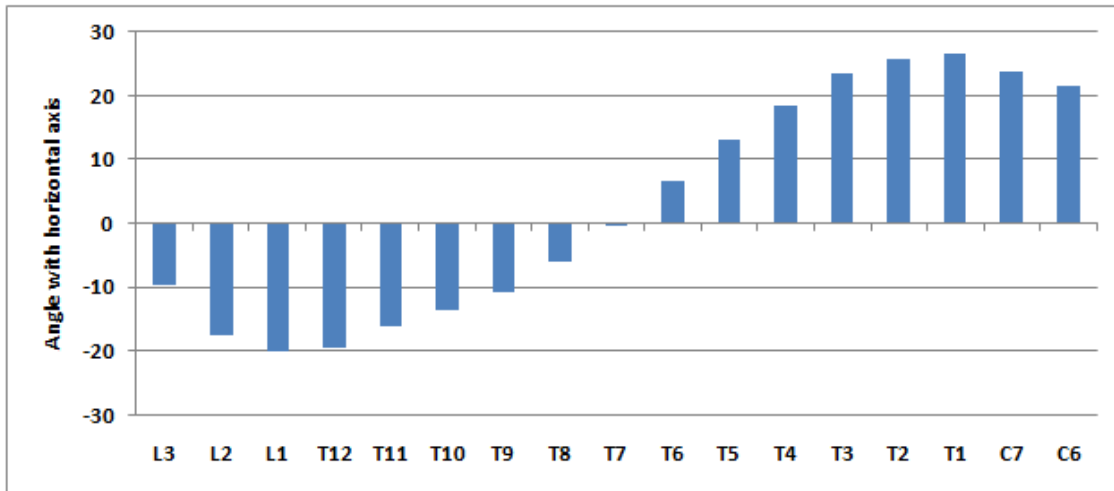


Figure 3: Mean Vertebra orientation versus horizontal axis in degree. A negative value denoted a posterior inclination while positive value denoted an anterior inclination.



ACCEPT

Figure 4: Mean values of Segmental Kyphosis (degree), Cumulative Kyphosis (degree) and Centered Kyphosis (degree) for the entire cohort

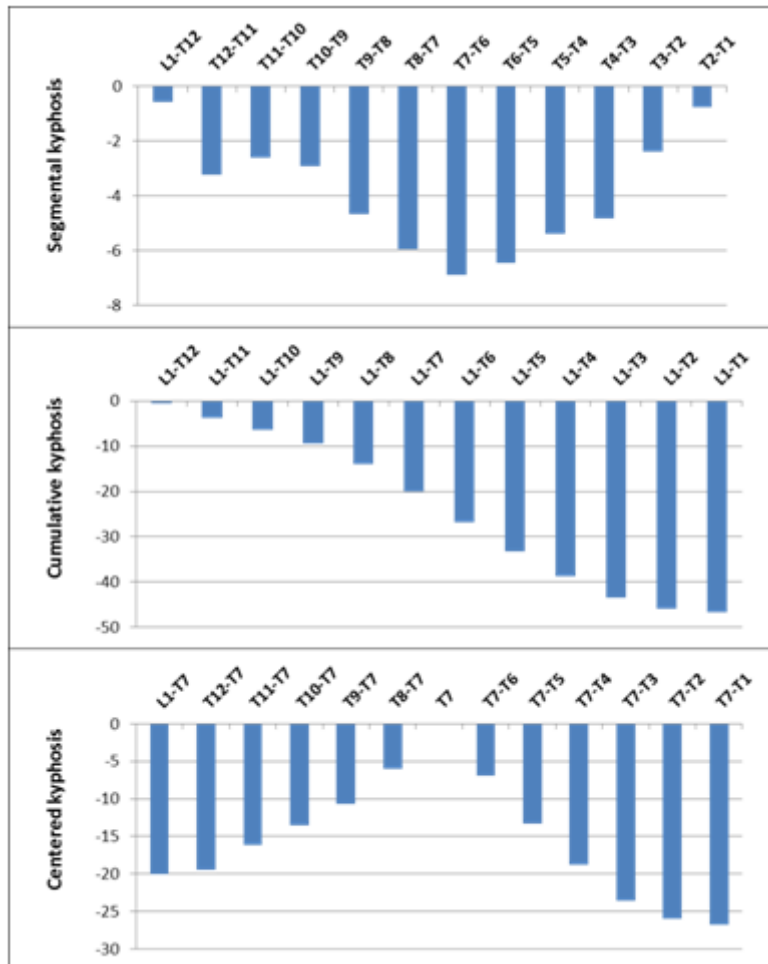
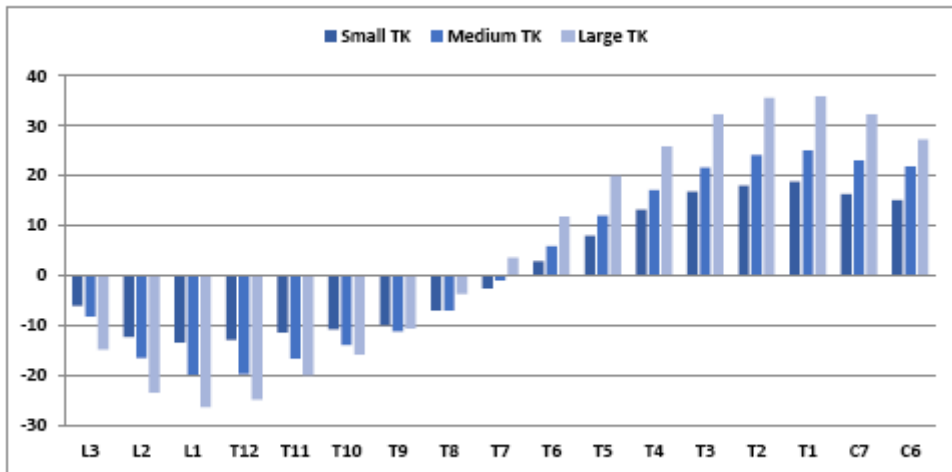


Figure 5: Mean Vertebra orientation versus horizontal axis in degree for the 3 groups of thoracic kyphosis. A negative value denoted a posterior inclination while positive value denoted an anterior inclination.



ACCEPT

Figure 6: Mean values of Segmental Kyphosis (degree), Cumulative Kyphosis (degree) and Centered Kyphosis (degree) by group of thoracic Kyphosis.

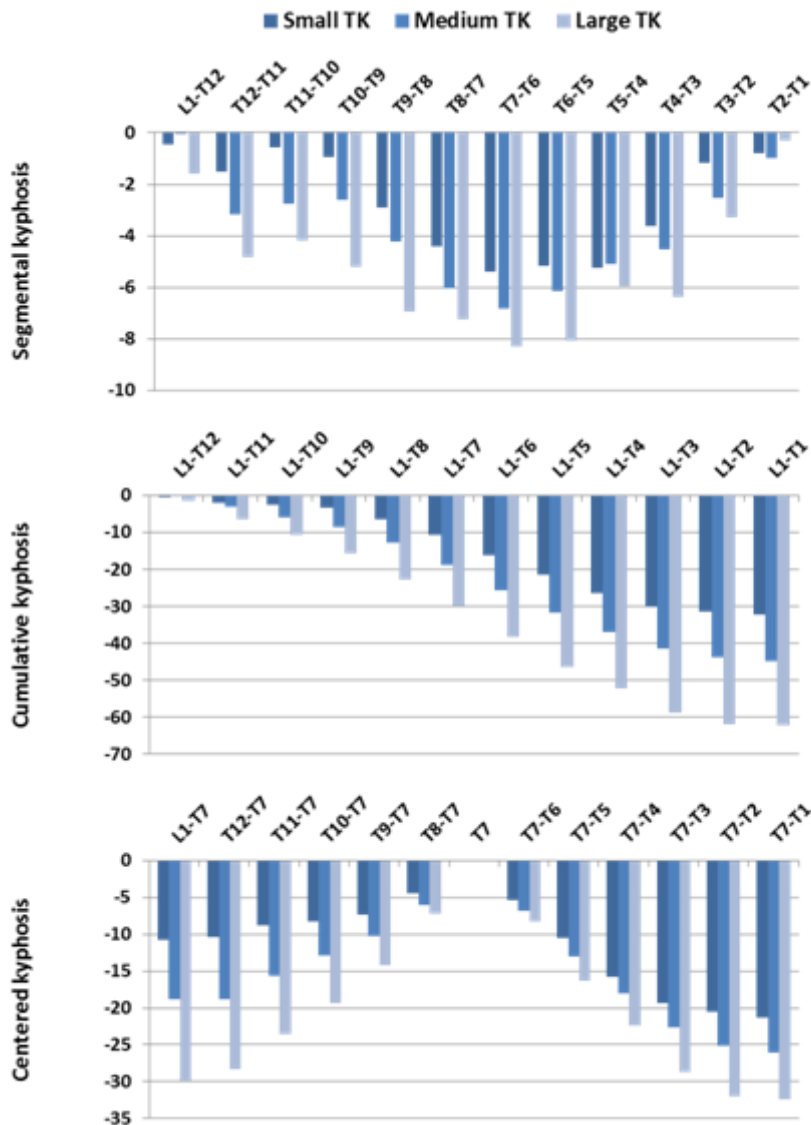


Figure 7: Example of Low, Medium and High Thoracic kyphosis illustrating the change in proximal / distal proportion

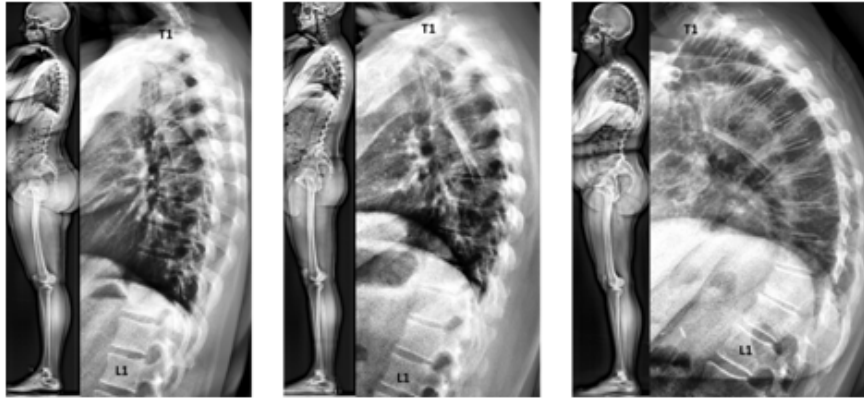


Table Legends:

Table 1: Description of the different Cobb angles associated with thoracic kyphosis

	Mean	StD	25th	Median	75th	Min	Max
T5-T12 (°)	-36.1	12.5	-44.1	-36.1	-29.1	-74.4	-4.9
T4-T12 (°)	-41.5	12.7	-50	-40.1	-34.8	-81.2	-7
T1-T12 (°)	-49.5	13.3	-57.7	-48.8	-41	-89.4	-13.1
T2-T5 (°)	-16.8	6.6	-20.6	-15.7	-12.3	-39.2	3.2
Max Kyphosis (°)	-52.6	13.3	-60.8	-51.9	-44	-92.2	-14.5

ACCEPTED