



HAL
open science

Patella Distal Pole Fracture Treated Using Ipsilateral Hamstring Autograft Augmentation and No Additional Hardware

Yassine Bulaïd, Sébastien Parratte, Jean-Noël Argenson, Matthieu Ollivier

► **To cite this version:**

Yassine Bulaïd, Sébastien Parratte, Jean-Noël Argenson, Matthieu Ollivier. Patella Distal Pole Fracture Treated Using Ipsilateral Hamstring Autograft Augmentation and No Additional Hardware. *Arthroscopy Techniques*, 2021, 10 (1), pp.e61-e65. <10.1016/j.eats.2020.09.013>. <hal-03176995>

HAL Id: hal-03176995

<https://hal.science/hal-03176995v1>

Submitted on 23 Mar 2021

HAL is a multi-disciplinary open access archive for the deposit and dissemination of scientific research documents, whether they are published or not. The documents may come from teaching and research institutions in France or abroad, or from public or private research centers.

L'archive ouverte pluridisciplinaire **HAL**, est destinée au dépôt et à la diffusion de documents scientifiques de niveau recherche, publiés ou non, émanant des établissements d'enseignement et de recherche français ou étrangers, des laboratoires publics ou privés.



Distributed under a Creative Commons CC BY-NC-ND 4.0 - Attribution - Non-commercial use - No Derivative Works - International License



Patella Distal Pole Fracture Treated Using Ipsilateral Hamstring Autograft Augmentation and No Additional Hardware

Yassine Bulaïd, M.D., Maxime Fabre, M.D., Sébastien Parratte, M.D., Ph.D.,
Jean-Noël Argenson, M.D., Ph.D., and Matthieu Ollivier, M.D., Ph.D.

Abstract: Patellar lower-pole fractures occur in relatively young patients after eccentric contraction of the quadriceps or direct trauma. Early diagnosis and adequate treatment lead to excellent outcomes and prevent tendon retraction and scarring. The aim of surgical treatment is to restore articular congruence and reestablish the extensor mechanism of the knee. All surgical treatments (sutures and tension band wiring, separate vertical wiring or augmented with Krackow sutures, wiring through screws, basket plate, hook plate) use additional hardware. We propose a hardware-free technique using ipsilateral hamstring augmentation.

Patellar lower-pole fractures occur in relatively young patients after eccentric contraction of the quadriceps or direct trauma.^{1,2} Early diagnosis and adequate treatment lead to excellent outcomes and prevent tendon retraction and scarring.²⁻⁴ The aim of surgical treatment is to restore articular congruence and reestablish the extensor mechanism of the knee. Almost all surgical treatments (sutures and tension band wiring, separate vertical wiring or augmented with Krackow sutures, wiring through screws, basket plate, hook plate) use additional hardware.^{5,6} Because

new techniques aim to reduce implant complications,⁷ we propose a hardware-free technique using ipsilateral hamstring augmentation ([Video](#)).

Procedure

Patient Positioning and Visualization

The patient is positioned supine on the operating table. The lower extremity is prepared and draped in the usual sterile fashion. We do not use tourniquet or elastic wrap, as we often performed the procedure without limb exsanguination. A 15- to 20-cm anterior incision is made in line with the medial third of the patella and tibial tubercle. Dissection is carried down through the skin and subcutaneous tissues to the level of the paratenon, which is carefully preserved for a layered closure. The patellar fracture is identified, and the hematoma is evacuated. After careful exposure of the patellar tendon ends, nonviable tissue is debrided, and the fracture is reduced using a reduction clamp.

Semitendinosus Graft Harvest and Preparation

The sartorial fascia is sharply incised longitudinally and reflected off the underlying gracilis and semitendinosus tendons ([Figure 1A](#)). A tendon hook is looped under the gracilis tendon, which is pulled into the wound. All fascial bands are identified and transected. Four-sided tendon mobility to the level of the musculotendinous junction is confirmed by palpation before proceeding to graft harvest. The semitendinosus tendon is harvested in a similar fashion using a closed tendon stripper (Depuy, Warsaw, IN). The 2 tendons are left

From the CapOrtho Centre de Chirurgie Orthopédique et Sportive, Béthune, France (Y.B.); Clinique Anne d'Artois, Béthune, France (Y.B.); l'Assistance Publique des Hôpitaux de Marseille, Institut du Mouvement et de L'appareil Locomoteur, Department of Orthopaedic Surgery, Sainte-Marguerite Hospital, Marseille, France (M.F., S.P., J-N.A., M.O.); and Aix-Marseille University, CNRS, ISM UMR 7287, Marseille, France (M.F., S.P., J-N.A., M.O.)

The authors report the following potential conflicts of interest or sources of funding: S.P. reports consultant, Zimmer, Graftys, Adler Ortho, Arthrex; royalties, Zimmer. J-N.A. reports board member, Journal of Bone and Joint Surgery, American Volume, The European Knee Associates, SOF-COT; consultant, Zimmer; royalties, Zimmer, Symbios. Full ICMJE author disclosure forms are available for this article online, as [supplementary material](#).

Received April 23, 2020; accepted September 11, 2020.

Address correspondence to Yassine Bulaïd, MD, Caportho, Centre de Chirurgie Orthopédique et Sportive, Clinique Anne d'Artois, 100 Rue Emile Basly, 62400 Béthune, France. E-mail: yassine.bulaid@gmail.com

© 2020 Published by Elsevier on behalf of the Arthroscopy Association of North America. This is an open access article under the CC BY-NC-ND license (<http://creativecommons.org/licenses/by-nc-nd/4.0/>).

2212-6287/20670

<https://doi.org/10.1016/j.eats.2020.09.013>

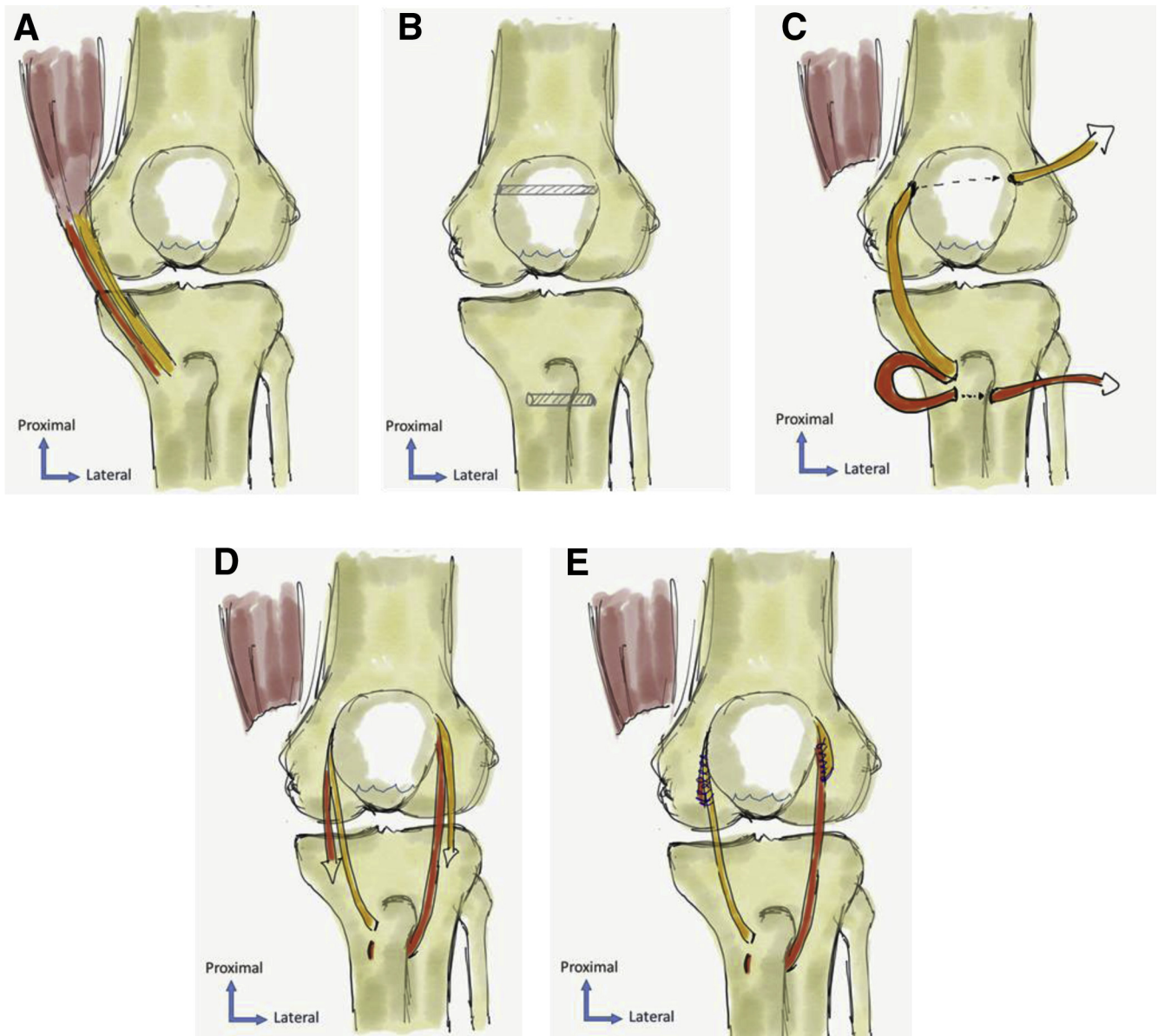


Fig 1. (A) The insertions of the gracilis and semitendinosus, which should be harvested carefully, are left attached to the proximal tibia. The muscle fibers are debrided from the tendon proximal part, and two no. 0 absorbable braided sutures (Vicryl®; Ethicon, Somerville, NJ) are whipstitched through the proximal ends of the tendons. The tendons are sized for later drilling of the patella and the tibia. (B) Preparation of the tibial and femoral tunnel. The diameter of the tibial tunnel must be the same as that of the longest tendon, usually the semitendinosus, and the femoral tunnel must be the size of both tendons. Both tunnels are centered to avoid fracture, especially on the patella. (C) The longest tendon should be passed through the tibial tunnel from medial to lateral; both tendons should be passed subcutaneously from distal to lateral and then through the patella tunnel; the lateral tendon should be passed from lateral to medial; and the medial tendon should be passed from medial to lateral. Make sure to clean both ends of the tunnels of soft tissues so that the tendons can be passed smoothly. In our experience, it is easier to pass each end of the sutures before passing the tendons through the tunnels. The traction should be done in the tunnel direction to avoid fractures. (D) Tension is applied simultaneously to both tendons' proximal ends, with the knee flexed at 30°. After satisfactory restoration of patellar height, the sutures are tied and temporarily locked on the proximal part of the other hamstring tendon using small clamps. (E) The 2 tendons are securely sutured using two no. 2 FiberForce® (Wright Medical, Memphis, TN) sutures, starting at each side of the patellar horizontal tunnel then continuing to the distal aspect of the patella, attaching the hamstring tendons to parapatellar soft tissue and paratenon. The arms of the 2 hamstring grafts are tensioned beneath the patellar tendon and sutured to the native patellar tendon, to the level of the distal tubercle insertion. Finally, no. 0 absorbable braided trans osseous sutures (Vicryl®; Ethicon) are placed to stabilize the 2 parts of the fracture after removal of the reduction clamp (Figure 1). The torn medial and lateral retinacula are closed with interrupted no. 0 absorbable braided suture (Vicryl®; Ethicon).

Table 1. Pearls and Pitfalls

Pearls	Pitfalls
Transect all fascia bands before stripping the tendons	Failure to identify and transect all fascia bands can divert the tendon stripper into the main tendon, leading to premature tendon amputation; in this case, one should check whether the other tendon is long enough to be passed through both tunnels and be sutured to the other tendon or consider another technique
Pass the longest tendon (usually the semitendinosus) through the tibial tunnel to have enough length	
The patellar tunnel should be centered to avoid fracture	A transosseous tunnel that breaches the anterior cortex is more likely to fracture ⁸
Pass both ends of the sutures in the patellar tunnel before passing each one of the tendons	

attached to the proximal tibia. The muscle fibers are debrided from the tendon proximal part, and two no. 0 absorbable braided sutures (Vicryl®; Ethicon, Somerville, NJ) are whipstitched through the proximal ends of the tendons. The tendons are sized for later drilling of the patella and tibia.

Tibia Preparation

A spade-tipped guide pin is inserted through the proximal tibia anterior and superior to the distal hamstring attachment, and a cannulated reamer of diameter equal to that of the semitendinosus tendon (3 to 5 mm) is used to create a tunnel across the tibia medially to laterally (Figure 1B).

Patella Preparation

A spade-tipped guide pin is inserted at the middle aspect of the patella medially to laterally, trying to divide in 2 the patellar bone by both length and thickness. A cannulated reamer of diameter equal to the summed diameter of the semitendinosus plus gracilis tendons (6 to 8 mm) is used to create a tunnel across the patella medially to laterally.

Bone Fixation and Augmentation Sequences

The patellar fracture is reduced using a reduction clamp all along the augmentation procedure. A shuttle-relay is used to pass the ends of the no. 0 absorbable braided locking whipstitch sutures. 1) The semitendinosus proximal end is passed through the tibia medially to laterally (Figure 1C); 2) the semitendinosus proximal end is passed through the patella laterally to medially; and 3) the gracilis proximal end is passed through the patella medially to laterally. We advise you to pass both ends of the sutures in the patellar tunnel before passing each tendon, as it may be more difficult to pass the ends of the sutures of one tendon while the other tendon is already in the tunnel.

Tension is applied simultaneously to both tendons' proximal ends, with the knee flexed at 30° (Figure 1D). After satisfactory restoration of patellar height, the sutures are tied and temporarily locked on the proximal part of the other hamstring tendon using small clamps. The 2

tendons are securely sutured using two no. 2 Fiber-Force® (Wright Medical, Memphis, TN) sutures, starting at each side of the patellar horizontal tunnel then continuing to the distal aspect of the patella, attaching hamstring tendons to parapatellar soft tissue and paratenon. The arms of the 2 hamstring grafts are tensioned beneath the patellar tendon and sutured to the native patellar tendon to the level of the distal tubercle insertion. Finally, no. 0 absorbable braided transosseous sutures (Vicryl; Ethicon, Somerville, NJ) are performed to stabilize the 2 parts of the fracture after removal of the reduction clamp (Figure 1E). The torn medial and lateral retinacula are closed with interrupted no. 0 absorbable braided suture (Vicryl®; Ethicon, Somerville, NJ). Passive knee flexion is performed while the tendon construct is visualized. Typically, knee flexion of 90° to 110° is observed without undue tension. The wound is thoroughly irrigated. The skin and subcutaneous tissues are closed with absorbable braided suture followed by staple skin closure. No knee immobilizer is applied, to allow day 0 rehabilitation. Pearls and pitfalls are described in Table 1.

Rehabilitation

At 0 to 3 weeks, the patient is restricted to crutch-assisted partial weightbearing without any knee brace. Active and passive range of motion are allowed immediately from 0° to 90°. At 3 to 6 weeks, the patient is sequentially increased to full weight bearing while weaning from using crutches. Range of motion of 0 to 120° in a hinged knee brace is allowed after 6 weeks. Active and passive knee range of motion is allowed as

Table 2. Advantages and Disadvantage

Advantages	Disadvantages
No hardware means less risk of infection, breakage, or painful hardware and no need for hardware removal	Need for good tendon quality
Cost saving (depending on the prices of the sutures)	Open surgery
Immediate weightbearing and early mobilization	

tolerated. After 12 weeks, resisted and strengthening exercises are allowed.

Discussion

The conventional surgical techniques do not allow sufficient stability for comminuted fracture of the lower pole of the patella.^{5,9-13} The described technique answers different challenges: 1) the possible loss of reduction, 2) the soft tissue irritation due to breakage of wire and migration, and 3) the need for additional surgery for the removal of implants. The advantages and disadvantages of the technique are described in Table 2. The hamstring harvest is associated with morbidity, yet Larson and Simonian did not find any functional loss in their patients.¹⁴ They reported a case series of 4 patients with acute rupture of the patellar tendon treated with primary surgical repair along with semitendinosus autograft augmentation. The assessment at 40 months of follow up included the evaluation of the strength of hamstrings and quadriceps, the Lysholm score, a 1-legged hop distance, the range of motion of the knee, and the length of the patellar tendon. In each case, the quadriceps and hamstring muscles strength were essentially the same in the 2 legs.¹⁵ A Lysholm score from 89 to 100 is considered good. All the patients had full extension, and flexion ranged from 128° to 145°.

Studies have shown that patients had fewer adverse events and less residual knee pain after patella fracture treated with percutaneous technique compared with open surgery with a tension band technique or with the use of cable and pins. However, these studies had a low quality of evidence.^{13,16,17} The technique described is an open surgery technique, yet no hardware is needed; only braided sutures are used. Hence, there is less risk of infection, breakage or painful hardware with the necessity of hardware removal. Luna-Pizarro et al.¹⁶ studied 53 patients with displaced patellar fractures in a randomized trial. The fractures were treated with either a minimally invasive technique or open surgery both with pins and cerclage. At 24 month of follow up, 17 patients in the minimally invasive group and 18 patients in the open surgery group had undergone hardware removal indicated by pain or irritation.^{13,16,18} This technique is cost saving, as no materials is necessary, yet specific sutures are most expensive than simple sutures. Moreover, the need for additional surgery for hardware removal is frequent in the literature.^{19,20} Jang et al. described a hook plating technique for lower pole fractures of the patella, with good outcomes.²¹ However, they had to remove the implants in 16 of the 30 patients included in their study.

Prolonged immobilization may lead to joint stiffness, poor cartilage nutrition, and muscle atrophy.²² Hence, the greatest advantage of the described technique is the possibility of immediate weightbearing and early mobilization. A parallel could be drawn with the biological augment for acute patellar tendon repair, in

which semitendinosus augmentation allows immediate postoperative mobilization with excellent functional results.¹⁴ This allows patients with early functional exercise and has a positive significance for the smooth recovery of the articular surface of the patella and recovery of knee extensor device function.

Conclusion

This article describes a surgical technique for fracture of the distal pole of the patella with ipsilateral hamstring autograft augmentation and no additional hardware. Although clinical evidence is needed, the potential benefits of the double frame augmentation around the patella include early mobilization and weightbearing avoiding hardware removal.

References

1. Siwek CW, Rao JP. Ruptures of the extensor mechanism of the knee joint. *J Bone Joint Surg Am* 1981;63:932-937.
2. Woodmass JM, Johnson JD, Wu IT, Krych AJ, Stuart MJ. Patellar tendon repair with ipsilateral semitendinosus autograft augmentation. *Arthrosc Tech* 2017;6:e2177-e2181.
3. West JL, Keene JS, Kaplan LD. Early motion after quadriceps and patellar tendon repairs: Outcomes with single-suture augmentation. *Am J Sports Med* 2008;36:316-323.
4. Roudet A, Boudissa M, Chaussard C, Rubens-Duval B, Saragaglia D. Acute traumatic patellar tendon rupture: Early and late results of surgical treatment of 38 cases. *Orthop Traumatol Surg Res* 2015;101:307-311.
5. Yang X, Wu Q, Lai C-H, Wang X. Management of displaced inferior patellar pole fractures with modified tension band technique combined with cable cerclage using Cable Grip System. *Injury* 2017;48:2348-2353.
6. Swensen S, Fisher N, Atanda A, Egol KA. Suture repair of a pole patella fracture. *J Orthop Trauma* 2017;31:S28.
7. Kakazu R, Archdeacon MT. Surgical management of patellar fractures. *Orthop Clin North Am* 2016;47:77-83.
8. Bonazza NA, Lewis GS, Lukosius EZ, Roush EP, Black KP, Dhawan A. Effect of transosseous tunnels on patella fracture risk after medial patellofemoral ligament reconstruction: A cadaveric study. *Arthroscopy* 2018;34:513-518.
9. Smith ST, Cramer KE, Karges DE, Watson JT, Moed BR. Early complications in the operative treatment of patella fractures. *J Orthop Trauma* 1997;11:183-187.
10. Hung LK, Chan KM, Chow YN, Leung PC. Fractured patella: Operative treatment using the tension band principle. *Injury* 1985;16:343-347.
11. Gosal HS, Singh P, Field RE. Clinical experience of patellar fracture fixation using metal wire or non-absorbable polyester—a study of 37 cases. *Injury* 2001;32:129-135.
12. Tian Q, Hai Y, Du X, et al. Comparison of tension-band wiring with the cable pin system in patella fractures: A randomized prospective study. *J Orthop Trauma* 2015;29:e459-e463.
13. Mao N, Liu D, Ni H, Tang H, Zhang Q. Comparison of the cable pin system with conventional open surgery for transverse patella fractures. *Clin Orthop* 2013;471:2361-2366.
14. Larson RV, Simonian PT. Semitendinosus augmentation of acute patellar tendon repair with immediate mobilization. *Am J Sports Med* 1995;23:82-86.

15. Lysholm J, Tegner Y. Knee injury rating scales. *Acta Orthop* 2007;78:445-453.
16. Luna-Pizarro D, Amato D, Arellano F, Hernández A, López-Rojas P. Comparison of a technique using a new percutaneous osteosynthesis device with conventional open surgery for displaced patella fractures in a randomized controlled trial. *J Orthop Trauma* 2006;20:529-535.
17. Sayum Filho J, Lenza M, Teixeira de Carvalho R, Pires OGN, Cohen M, Belloti JC. Interventions for treating fractures of the patella in adults. *Cochrane Database Syst Rev* 2015:CD009651.
18. Chen A, Hou C, Bao J, Guo S. Comparison of biodegradable and metallic tension-band fixation for patella fractures. 38 patients followed for 2 years. *Acta Orthop Scand* 1998;69:39-42.
19. Lazaro LE, Wellman DS, Sauro G, et al. Outcomes after operative fixation of complete articular patellar fractures: Assessment of functional impairment. *J Bone Joint Surg Am* 2013;95:e96.
20. LeBrun CT, Langford JR, Sagi HC. Functional outcomes after operatively treated patella fractures. *J Orthop Trauma* 2012;26:422-426.
21. Jang JH, Rhee SJ, Kim JW. Hook plating in patella fractures. *Injury* 2019;50:2084-2088.
22. Enneking WF, Horowitz M. The intra-articular effects of immobilization on the human knee. *J Bone Joint Surg Am* 1972;54:973-985.