



**HAL**  
open science

# Does labral repair have a clinical benefit during arthroscopic treatment of femoro-acetabular impingement? Prospective multicentre study with 2-year follow-up

Olivier May, Karim Ouattara, Xavier Flecher, Michael Wettstein

## ► To cite this version:

Olivier May, Karim Ouattara, Xavier Flecher, Michael Wettstein. Does labral repair have a clinical benefit during arthroscopic treatment of femoro-acetabular impingement? Prospective multicentre study with 2-year follow-up. *Orthopaedics & Traumatology: Surgery & Research*, 2020, 106 (8), pp.S237-S241. 10.1016/j.otsr.2020.09.002 . hal-03176980

**HAL Id: hal-03176980**

**<https://hal.science/hal-03176980>**

Submitted on 8 Apr 2021

**HAL** is a multi-disciplinary open access archive for the deposit and dissemination of scientific research documents, whether they are published or not. The documents may come from teaching and research institutions in France or abroad, or from public or private research centers.

L'archive ouverte pluridisciplinaire **HAL**, est destinée au dépôt et à la diffusion de documents scientifiques de niveau recherche, publiés ou non, émanant des établissements d'enseignement et de recherche français ou étrangers, des laboratoires publics ou privés.

# Does labral repair have a clinical benefit during arthroscopic treatment of femoro-acetabular impingement? Prospective multicentre study with 2-year follow-up

Olivier May<sup>a,\*</sup>, Karim Ouattara<sup>b</sup>, Xavier Flecher<sup>c</sup>, Michael Wettstein<sup>d,e</sup>,  
the Francophone Arthroscopy Society (SFA)<sup>f</sup>

<sup>a</sup> Centre de chirurgie de la hanche, Médipole Garonne, 45, rue de Gironis, 31036 Toulouse, France

<sup>b</sup> Institut universitaire locomoteur et sport, université Côte d'Azur, CHU Pasteur 2 de Nice, 30, voie Romaine, 06000 Nice, France

<sup>c</sup> Department of Orthopaedics and Traumatology, Aix-Marseille University, AP-HM, CNRS, ISM, Sainte-Marguerite Hospital, Institute for Locomotion, Marseille, France

<sup>d</sup> Institut de traumatologie et d'orthopédie du léman suisse, clinique Genolier, route du Muids 3, 1272 Genolier, Switzerland

<sup>e</sup> Service d'orthopédie-traumatologie, HRC centre hospitalier de Rennaz, route du Vieux-Séquoia 20, 1847 Rennaz, Switzerland

<sup>f</sup> 15, rue Ampère, 92500 Rueil-Malmaison, France

## ABSTRACT

**Introduction:** Hip arthroscopy has emerged as an effective tool for treating labral tears associated with femoro-acetabular impingement (FAI).

**Objective:** Compare the effectiveness of debridement versus labral repair on functional outcomes at 2 years after hip arthroscopy and evaluate the influence of the repair technique.

**Hypothesis:** There is no statistical difference in short-term functional outcomes between debridement and repair. The type of repair technique has no influence on functional outcomes.

**Methods:** From July 2017 to June 2018, a prospective study was done at 10 participating hospitals specialised in hip preservation surgery. Patients over 18 years of age, who underwent hip arthroscopy for a labral tear due to femoro-acetabular impingement, were enrolled. Patients underwent either labral repair or debridement. The labral repairs were performed with either the loop or mattress technique and functional outcomes were evaluated using the Non-Arthritic Hip Score (NAHS).

**Results:** One hundred and eighty-seven patients who underwent arthroscopic treatment for FAI were enrolled; 42 (22.5%) underwent labral debridement and 145 (77.5%) underwent labral repair. In the repair group, 66 (46%) were mattress sutures and 79 (54%) were loop sutures. Mean patient age was  $33.3 \pm 10.3$  (18–63) and 38% of patients were women ( $n = 71$ ). Mean follow-up was 16.2 months (10–26.4). The mean NAHS improved from 47.3 to 72.8 ( $p < 0.05$ ) at final follow-up. There was no significant difference between the repair and debridement groups ( $p > 0.05$ ). There was no significant difference between the mattress and loop repair subgroups ( $p > 0.05$ ).

**Conclusions:** There is no statistical difference in short-term functional outcomes between debridement and repair. The type of repair technique has no influence on functional outcomes.

**Level of evidence:** II, prospective cohort study.

**Keywords:**  
Arthroscopy  
Labrum  
Repair  
Debridement

## 1. Introduction

Femoro-acetabular impingement (FAI) was first described in 1936 by Marius Niegard Smith-Petersen [1]; subsequently, Reinhold Ganz and his team were the first to extensively analyse its

anatomy and pathophysiology [2]. Labral tears, caused by morphological changes in the acetabular bone or the femur, have been implicated in the development of osteoarthritis [3]. Preserving the labrum appears to protect the joint from secondary cartilage degeneration [4]. Arthroscopic techniques – which are less invasive and less damaging, especially to the greater trochanter – have been developed and widely accepted with functional outcomes equal to open surgical treatment [5–11]. For the labrum, several treatment options have been described: debridement, repair and

\* Corresponding author.

reconstruction. Currently, there is no definitive evidence that one treatment is better than the others at preserving the labrum and the results are sometimes contradictory [12]. The indications for each option and the surgical technique have been extensively described in the literature [13,14]. The debate over which type of repair technique (translabral versus perilabral or loop) is more recent [15,16]. While the number of studies is limited, some authors prefer using the translabral technique as it does not alter the shape or function of the labrum.

The aim of this study was to report the 2-year functional outcomes of arthroscopic treatment of labral tears associated with FAI. The primary hypothesis is that there is no statistical difference in short-term functional outcomes between labral debridement and repair. The secondary hypothesis is that the type of repair technique has no influence on functional outcomes.

## 2. Materials and methods

Between July 2017 and July 2018, 197 patients underwent hip arthroscopy in the 10 participating research sites. The procedure was done in patients over 18 years of age, who had a labral tear associated with FAI. The exclusion criteria were:

- advanced hip arthritis (defined as Tönnis grade  $\geq 2$ );
- femoral or acetabular cartilage lesions graded as Beck  $\geq 2$ ;
- hip dysplasia with lateral centre-edge angle  $< 18^\circ$ ;
- previous surgery on the involved hip [17,18].

The diagnosis of FAI was made based on clinical and radiological findings. Standard radiographs for all patients included a standing anteroposterior (AP) view of the pelvis, Dunn lateral view, and Lequesne's false-profile view. The hallmarks of FAI were documented (alpha angle, loss of femoral head sphericity, coxa profunda, acetabular protrusion, acetabular version) [19,20]. The labrum was evaluated with CT arthrography or MR arthrography and the tears classified per Czerny et al. [21].

### 2.1. Surgical technique

The surgical procedure consisted first in correcting bone abnormalities due to impingement, both at the acetabular and femoral levels. Dynamic tests, generally done at the end of the procedure, were used to check that no residual impingement was present after the femoroplasty and/or acetabuloplasty. The cartilage condition was classified as described by Beck et al. [17]. Depending on the condition of the labrum, either debridement or repair was done. Labrum debridement consisted of resecting the detached or degenerated segment using cautery, basket forceps or shaver. The resection was limited to the pathological segment with the aim of preserving as much healthy labral tissue as possible. Labral repair is the gold standard treatment for detachments occurring in a healthy appearing labrum, where vascularisation contributes to healing. This repair must always be done after treating the root cause (femoroplasty, acetabuloplasty), otherwise there is a risk of recurrence. The technique may require the labrum to be detached at the tear, although we try to limit this procedure to not disrupt the labrum–cartilage junction. Next, the acetabulum margin is decorticated to remove excess bone; and lastly, the labrum is reattached using one or more suture anchors, ensuring these anchors do not protrude in the joint.

### 2.2. Debridement or repair

The condition of the labrum at the time of arthroscopic intervention was assessed and a decision was made as to whether repair or

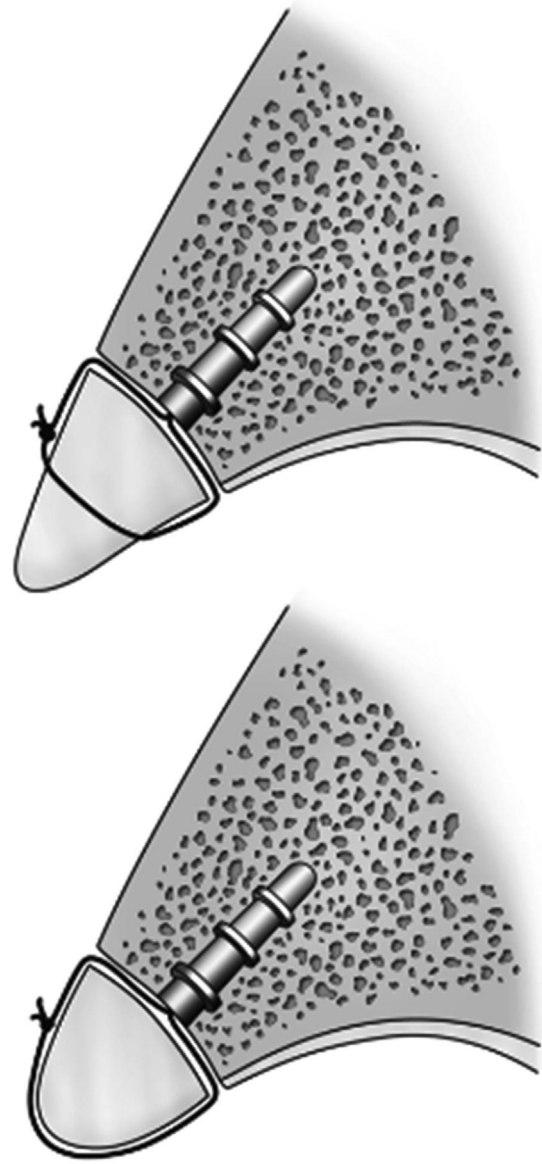
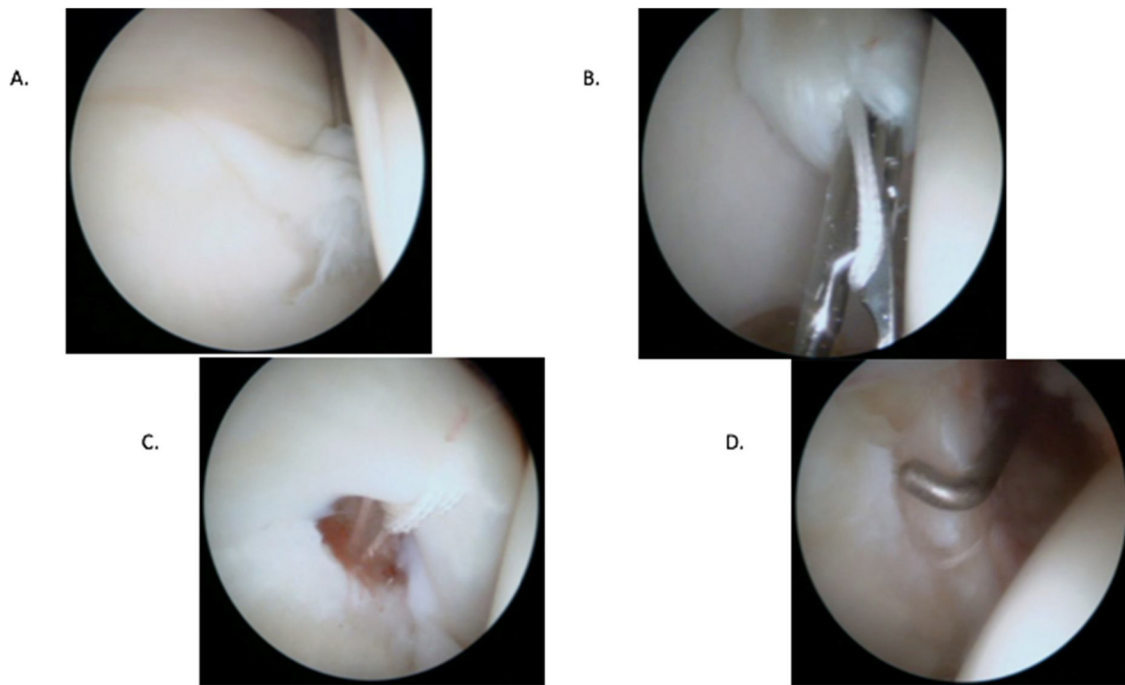


Fig. 1. Mattress (top) and loop (bottom) repair techniques.

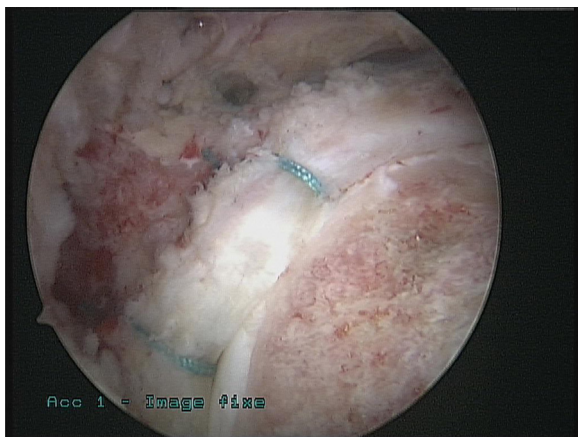
resection would be performed. It was felt that a hypoplastic labrum, or one that was highly degenerative in appearance, would not benefit from repair, as this would not succeed at restoring its physiologic function. Otherwise, the labrum was anatomically repaired with suture anchors in order to preserve its function [22,23]. Intra-labral ossifications cannot be repaired.

### 2.3. Postoperative rehabilitation

Whether in the debridement or repair group, the postoperative instructions were identical and allowed for immediate weight bearing using two crutches depending on pain levels. Rehabilitation was started early on, combining gentle mobilisation, progressive muscle strengthening, while limiting flexion to  $90^\circ$  and complex movements during the first 6 weeks.



**Fig. 2.** Intraoperative view of mattress repair. A. Labral tear. B. Translabral passage. C. Setting the suture tension. D. Appearance of completed mattress repair.  
Copyright Dr. O. May.



**Fig. 3.** Intraoperative view of loop (perilabral) repair with femoroplasty and resection of the anterior inferior iliac spine.  
Copyright Dr. M. Wettstein.

#### 2.4. Repair techniques

Labrum repair was performed with two types of suture configuration:

- perilabral loop;
- mattress suture (Fig. 1).

In cases where the labral tissue was deemed to be more degenerative, a perilabral loop configuration was utilised. A mattress suture configuration was used in the setting of more robust labral tissue. The chondrolabral junction was maintained when performing a labrum repair to restore the hip joint's negative suction seal (Figs. 2 and 3).

When the labrum is hypertrophic, perilabral (loop) repair is more likely to deform it with retraction at the suture. Conversely, a hypotrophic labrum can be cut in two by translabral suture and

result in a tear. Thus, the type of repair technique was chosen based on the local observations of labrum's viability and the surgeon's preferences (Figs. 1–3).

#### 2.5. Functional outcomes

Functional outcomes were evaluated pre- and postoperatively with the four domains of the NAHS (pain, mechanical symptoms, difficulty with function, activity).

#### 2.6. Statistical analysis

A descriptive analysis (mean, median, minimum, maximum, standard deviation for continuous variables and counts with proportions for categorical variables) was done to summarise the study parameters.

Student's *t*-test (parametric) or the Wilcoxon rank sum (non-parametric), and the Chi<sup>2</sup> test (parametric) or Fisher's exact test were done to test the differences between repair versus debridement groups, and to compare mattress versus loop repair for the qualitative and quantitative variables. A *p* value of 0.05 or less was considered as statistically significant. The statistical tests were carried out using the EasyMedStat© software and the R software (version 3.3.2, R Core Team 2013. R: A language and environment for statistical computing. R Foundation for Statistical Computing, Vienna, Austria).

### 3. Results

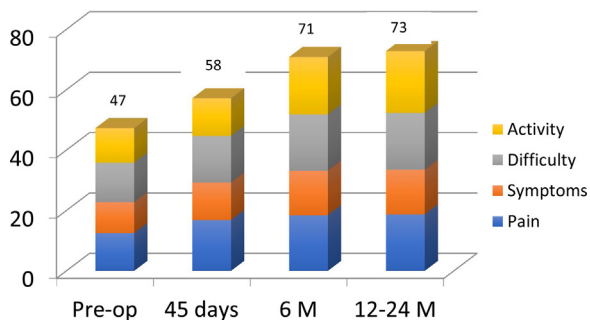
Of the 197 patients who underwent arthroscopy, 187 met the inclusion criteria. The mean age of the cohort was 33.3 years (18–63) and there were 71 women (38%). The mean follow-up was 16.2 months (12–26.4). There were 30 cam type impingements, 14 pincer types and 143 mixed types.

The labral tears were treated by debridement in 42 cases (22.5%) and by repair in 145 cases (77.5%). The Nötzli  $\alpha$  angle was significantly higher in the debridement group preoperatively (*p* = 0.001).

**Table 1**  
Characteristics of the patients who underwent debridement versus labral repair.

	Debridement (n = 42)	Repair (n = 145)	p value
Mean age	35.40	32.79	0.144
% Women	33	40	0.434
BMI	24.4	21.8	0.012
Mean follow-up	14.57	15.86	0.0156
Alpha angle (Nötzli)	72.1	65.1	0.001
Crossover sign (%) <sup>a</sup>	55	66	0.18
Coxa profunda (%)	17	9.5	0.34
Czerny < 2a (%)	29	49	0.021
Czerny ≥ 2b (%)	71	51	
Tönnis (%)	80	71	0.48
0	20	29	
1			
Preop NAHS	10.6	10.0	0.27
Symptoms	14.0	12.0	0.008
Pain	12.6	11.0	0.07
Activity	13.5	12.9	0.42
Difficulty			
NAHS at 2 years	15.1	14.6	0.19
Symptoms	18.9	18.6	0.61
Pain	20.2	20.6	0.59
Activity	18.8	18.8	0.97
Difficulty			

<sup>a</sup> Anterior wall of the acetabulum crosses over the posterior wall to the lateral side.



**Fig. 4.** Change in the NAHS from preoperative to postoperative follow-up (M: months).

There were significantly more Czerny ≥ 2b tears, which are degenerative, in the debridement group (69%, 29/42) than in the repair group (51%, 74/145) ( $p = 0.021$ ) (Table 1).

In the entire cohort, the mean NAHS improved from 47 preoperatively to 73 at the final assessment ( $p < 0.05$ ) (Fig. 4).

The patients who underwent suture repair were in significantly more pain preoperatively than the patients in the debridement group (12 versus 14 on NAHS pain domain) ( $p = 0.008$ ). There were no significant differences between groups in the other parameters. At the final assessment, there was no significant difference between groups in the four domains of the NAHS ( $p > 0.05$ ).

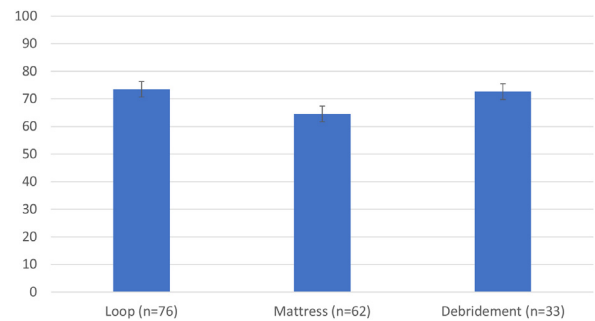
In the patients who underwent labral repair, 54% (79/145) were loop repairs and 46% (66/145) were mattress repairs. There were significantly more degenerative lesions (Czerny ≥ 2b) in the loop repair subgroup (62%, 49/79) than in the mattress repair subgroup (38%, 25/66) ( $p = 0.01$ ). Clinically, the patients who underwent mattress suture labrum repair had significantly more pain, more discomfort and more difficulty in day-to-day activities preoperatively ( $p = 0.000$ ). There were significantly more instances of coxa profunda in the loop repair subgroup ( $p = 0.012$ ). At the final assessment, there was no significant difference in the overall NAHS between the two repair subgroups (Table 2, Fig. 5).

In the NAHS domains, the subgroup that underwent mattress repair had more difficulty during day-to-day activities ( $p = 0.033$ ).

**Table 2**  
Characteristics of the patients who underwent loop (perilabral) versus mattress (translabral) repair.

	Loop repair (n = 79)	Mattress repair (n = 66)	p value
Czerny < 2a (%)	37	62	0.01
Czerny ≥ 2b (%)	63	38	
Alpha angle (Nötzli)	66.1	63.9	0.285
Crossover sign <sup>a</sup> (%)	72	57	0.07
Coxa profunda (%)	25	8	0.012
Preop NAHS	10.30	9.6	0.22
Symptoms	14.0	9.3	0.000
Pain	13.0	8.3	0.000
Activity	14.3	11.0	0.000
Difficulty			
NAHS at 2 years	14.7	17.7	0.034
Symptoms	18.7	13.9	0.65
Pain	20.9	18.9	0.075
Activity	19.1	18.1	0.033
Difficulty			

<sup>a</sup> Anterior wall of the acetabulum crosses over the posterior wall to the lateral side.



**Fig. 5.** NAHS at final assessment for different types of labral tear treatments.

Conversely, the patients in the loop repair subgroup had significantly more mechanical symptoms ( $p = 0.034$ ).

#### 4. Discussion

In this study of young adults undergoing arthroscopic treatment for FAI, we found no differences in functional outcomes in the short term between labral repair and labral debridement. High-grade labral tears are the main indication for debridement. When the tears were repaired, the type of suture technique had no impact on the overall functional outcomes in the short term.

The main goal of treating labral tears is to restore the hip's negative suction seal [22–24]. Debridement is considered when repair is not anatomically feasible because the lesion is highly deteriorated, or when the labrum is hypoplastic, making it impossible to suture after the tear is debrided. The clinical benefit of resection is that it reduces pain because innervated labral tissue is removed. Chen et al. showed that debridement, when done in the appropriate conditions, leads to excellent clinical outcomes [10]. Abrams et al. [25] described growth of a neolabrum after debridement and bone decortication. However, this finding is controversial, according to animal and MRI studies, since it was the result of a single study group, although it is not completely ruled out [26]. The regenerated tissue is hypoplastic relative to normal labral tissue, even if it resembles the structure. The short-term and long-term functional outcomes of the two treatments have been compared and neither was found to be superior [6,7,9]. In return, Wang et al. [27] showed that poor labrum fixation increases the risk of osteoarthritis and subchondral fracture. The final decision on treatment is based on the observations during arthroscopy: a healthy, non-degenerated

labrum more than 4 mm thick in a young, non-smoker adult is the typical indication for labral repair [11].

Two repair techniques – mattress and loop sutures – have been described. Mattress suture repairs are more often done in patients who have more pain and more difficulty in their day-to-day lives, which corresponds to more advanced lesions. Perilabral (loop) repairs are more often done in patients with pincer type impingement, since the labrum is often hypotrophic. The non-anatomical nature of perilabral repair and the risk of tearing during translabral suture are some of the drawbacks of these two techniques. When the labrum is hypertrophic, there is a greater risk of deforming it with perilabral repair, which would make it difficult to achieve a negative suction seal. Conversely, a hypotrophic labrum can be torn by translabral sutures and require resection. Jackson et al. [12] found no significant difference in the functional outcomes for these two methods. According to Sawyer et al. [15], there was no difference in the functional outcomes, failure risk, or revision risk between these two methods. It has been shown that the tension applied has a bigger impact on the treatment's success than the type of repair technique used [16]. Thus, the type of repair technique was chosen based on the local observations of labrum's viability and/or the surgeon's preferences.

Our prospective interventional study has several limitations: its multicentre and multi-surgeon nature creates technical and evaluation biases. The unequal group size increases the evaluation bias. There is also a selection bias since not all research sites recruited the same number of patients. The strengths of our study are that the cohort was followed prospectively, the surgical protocol was uniform and none of the patients were lost to follow-up.

## 5. Conclusions

During arthroscopic treatment of FAI, there are no functional differences in the short term in our study cohort between labrum debridement and labrum repair. Moreover, there is no difference in the functional outcomes between mattress and loop repair techniques.

## Disclosure of interest

Oliver May is consultant for Smith & Nephew and Adler; Xavier Flecher is consultant for Stryker and Zimmer Biomet Institute. Karim Ouattara declares that he has no competing interest.

## Sources of funding

No financing was received for this study.

## Author contribution

All authors have contributed to the study.

## References

- [1] Smith-Petersen MN. The classic: treatment of malum coxae senilis, old slipped upper femoral epiphysis, intrapelvic protrusion of the acetabulum, and coxa plana by means of acetabuloplasty. *Clin Orthop Relat Res* 2009;467:608–15.
- [2] Ganz R, Parvizi J, Beck M, Leunig M, Nötzli H, Siebenrock K. Femoroacetabular impingement: a cause for osteoarthritis of the hip. *Clin Orthop Relat Res* 2003;417:112–20.
- [3] Ganz R, Leunig M, Leunig-Ganz K, Harris WH. The etiology of osteoarthritis of the hip: an integrated mechanical concept. *Clin Orthop Relat Res* 2008;466:264–72.
- [4] Kim Y, Giori NJ, Lee D, Ahn K-S, Kang CH, Shin CS, et al. Role of the acetabular labrum on articular cartilage consolidation patterns. *Biomech Model Mechanobiol* 2019;18:479–89.
- [5] Cetinkaya S, Tokar B, Ozden VE, Dikmen G, Taser O. Arthroscopic labral repair versus labral debridement in patients with femoro-acetabular impingement: a minimum 2.5 year follow-up study. *HIP Int* 2016;26:20–4.
- [6] Haddad B, Konan S, Haddad FS. Debridement versus re-attachment of acetabular labral tears: a review of the literature and quantitative analysis. *Bone Joint J* 2014;96-B:24–30.
- [7] Larson CM, Giveans MR, Stone RM. Arthroscopic debridement versus refixation of the acetabular labrum associated with femoroacetabular impingement: mean 3.5-year follow-up. *Am J Sports Med* 2012;40:1015–21.
- [8] Krych AJ, Thompson M, Knutson Z, Scoon J, Coleman SH. Arthroscopic labral repair versus selective labral debridement in female patients with femoroacetabular impingement: a prospective randomised study. *Arthroscopy* 2013;29:46–53.
- [9] Menge TJ, Briggs KK, Dornan GJ, McNamara SC, Philippon MJ. Survivorship and outcomes 10 years following hip arthroscopy for femoro-acetabular impingement: labral debridement compared with labral repair. *J Bone Joint Surg* 2017;99:997–1004.
- [10] Chen AW, Yuen LC, Ortiz-Declet V, Litrenta J, Maldonado DR, Domb BG. Selective debridement with labral preservation using narrow indications in the hip: minimum 5-year outcomes with a matched-pair labral repair control group. *Am J Sports Med* 2018;46:297–304.
- [11] Domb BG, Hartigan DE, Perets I. Decision making for labral treatment in the hip: repair versus debridement versus reconstruction. *J Am Acad Orthop Surg* 2012;28:1170–9.
- [12] Jackson TJ, Hammarstedt JE, Vemula SP, Domb BG. Acetabular labral base repair versus circumferential suture repair: a matched-paired comparison of clinical outcomes. *Arthroscopy* 2015;31:1716–21.
- [13] Ayeni OR, Wong I, Chien T, Musahl V, Kelly BT, Bhandari M. Surgical indications for arthroscopic management of femoro-acetabular impingement. *Arthroscopy* 2012;28:1170–9.
- [14] de SAD, Lian J, Sheehan AJ, Inman K, Drain N, Ayeni O, et al. A systematic summary of systematic reviews on the topic of hip arthroscopic surgery. *Orthop J Sports Med* 2018;6 [232596711879622].
- [15] Sawyer GA, Briggs KK, Dornan GJ, Ommen ND, Philippon MJ. Clinical outcomes after arthroscopic hip labral repair using looped versus pierced suture techniques. *Am J Sports Med* 2015;43:1683–8.
- [16] Kollmorgen R, Mather R. Current concepts in labral repair and refixation: anatomical approach to labral management. *Am J Orthop (Belle Mead NJ)* 2017;46:42–8.
- [17] Nepple JJ, Larson CM, Smith MV, Kim Y-J, Zaltz I, Sierra RJ, et al. The reliability of arthroscopic classification of acetabular rim labrochondral disease. *Am J Sports Med* 2012;40:2224–9.
- [18] Kovalenko B, Bremjitt P, Fernando N. Classifications in brief: Tönnis classification of hip osteoarthritis. *Clin Orthop Relat Res* 2018;476:1680–4.
- [19] Smith KM, Gerrie BJ, McCulloch PC, Lintner DM, Harris JD. Comparison of MRI, CT, Dunn 45° and Dunn 90° alpha angle measurements in femoro-acetabular impingement. *HIP Int* 2018;28:450–5.
- [20] Zhou J, Melugin HP, Hale RF, Leland DP, Bernard CD, Levy BA, et al. The prevalence of radiographic findings of structural hip deformities for femoro-acetabular impingement in patients with hip pain. *Am J Sports Med* 2020;48:647–53.
- [21] Czerny C, Hofmann S, Urban M, Tschauner C, Neuhold A, Pretterklieber M, et al. MR arthrography of the adult acetabular capsular-labral complex: correlation with surgery and anatomy. *Am J Roentgenol* 1999;173:345–9.
- [22] Philippon MJ, Nepple JJ, Campbell KJ, Dornan GJ, Jansson KS, LaPrade RF, et al. The hip fluid seal – Part I: the effect of an acetabular labral tear, repair, resection, and reconstruction on hip fluid pressurisation. *Knee Surg Sports Traumatol Arthrosc* 2014;22:722–9.
- [23] Nepple JJ, Philippon MJ, Campbell KJ, Dornan GJ, Jansson KS, LaPrade RF, et al. The hip fluid seal – Part II: the effect of an acetabular labral tear, repair, resection, and reconstruction on hip stability to distraction. *Knee Surg Sports Traumatol Arthrosc* 2014;22:730–6.
- [24] Cadet ER, Chan AK, Vorys GC, Gardner T, Yin B. Investigation of the preservation of the fluid seal effect in the repaired, partially resected, and reconstructed acetabular labrum in a cadaveric hip model. *Am J Sports Med* 2012;40:2218–23.
- [25] Abrams GD, Safran MR, Sadri H. Spontaneous hip labrum regrowth after initial surgical debridement. *Clin Orthop Relat Res* 2013;471:2504–8.
- [26] Miozzari HH, Clark JM, Jacob HAC, von Rechenberg B, Nötzli HP. Effects of removal of the acetabular labrum in a sheep hip model. *Osteoarthritis Cartilage* 2004;12:419–30.
- [27] Wang X, Fukui K, Kaneuji A, Hirosaki K, Miyakawa H, Kawahara N. Inversion of the acetabular labrum causes increased localised contact pressure on the femoral head: a biomechanical study. *Int Orthop (SICOT)* 2019;43:1329–36.