



**HAL**  
open science

## Can dual mobility cups prevent dislocation without increasing revision rates in primary total hip arthroplasty? A systematic review

Ragna C Jonker, Loes W.A.H. van Beers, Bart C.H. van Der Wal, H. Charles Vogely, Sebastien Parratte, René M Castelein, Rudolf W Poolman

### ► To cite this version:

Ragna C Jonker, Loes W.A.H. van Beers, Bart C.H. van Der Wal, H. Charles Vogely, Sebastien Parratte, et al. Can dual mobility cups prevent dislocation without increasing revision rates in primary total hip arthroplasty? A systematic review. *Orthopaedics & Traumatology: Surgery & Research*, 2020, 106 (3), pp.509-517. 10.1016/j.otsr.2019.12.019 . hal-03176977

**HAL Id: hal-03176977**

**<https://hal.science/hal-03176977v1>**

Submitted on 15 Apr 2021

**HAL** is a multi-disciplinary open access archive for the deposit and dissemination of scientific research documents, whether they are published or not. The documents may come from teaching and research institutions in France or abroad, or from public or private research centers.

L'archive ouverte pluridisciplinaire **HAL**, est destinée au dépôt et à la diffusion de documents scientifiques de niveau recherche, publiés ou non, émanant des établissements d'enseignement et de recherche français ou étrangers, des laboratoires publics ou privés.

# Can dual mobility cups prevent dislocation without increasing revision rates in primary total hip arthroplasty? A systematic review<sup>☆</sup>

Ragna C. Jonker<sup>a,\*</sup>, Loes W.A.H. van Beers<sup>b</sup>, Bart C.H. van der Wal<sup>a</sup>, H. Charles Vogely<sup>a</sup>, Sebastien Parratte<sup>c</sup>, René M. Castelein<sup>a</sup>, Rudolf W. Poolman<sup>b,d</sup>

<sup>a</sup> Department of Orthopaedic Surgery, University Medical Center Utrecht, PO Box 85500, 3508 GA Utrecht, The Netherlands

<sup>b</sup> Department of Orthopaedic Surgery, OLVG, PO Box 95500, 1090 HM Amsterdam, The Netherlands

<sup>c</sup> Department of Orthopedic Surgery and Traumatology, St. Marguerite Hospital Marseille, 270 Boulevard de Sainte-Marguerite, 13009 Marseille, France

<sup>d</sup> Department of Orthopaedic Surgery, Leiden University Medical Center, PO Box 9600, 2300 RC Leiden, The Netherlands

## A B S T R A C T

**Keywords:**  
Dual mobility  
Unipolar  
Total hip arthroplasty  
Dislocation  
Revision

**Background:** Dislocation is one of the leading causes for early revision surgery after total hip arthroplasty (THA). To address this problem, the dual mobility (DM) cup was developed in the 1970s by the French. Despite the increased and, in some countries, broad use of DM cups, high quality evidence of their effectiveness compared to traditional unipolar (UP) cups is lacking. There are a few well-conducted literature reviews, but the level of evidence of the included studies was moderate to low and the rates of revision were not specifically investigated. Therefore, we did a systematic review to investigate whether there is a difference in the rate of dislocations and revisions after primary THA with a DM cup or a UP cup.

**Methods:** We conducted a systematic literature search in PubMed, Embase and Cochrane databases in July 2019. The articles were selected based upon their quality, relevance and measurement of the predictive factor. We used the MINORS criteria to determine the methodological quality of all studies.

**Results:** The initial search resulted in 702 citations. After application of the inclusion and exclusion criteria, eight articles met our eligibility criteria and were graded. Included studies were of medium to low methodological quality with a mean score of 14/24 (11–16) points following the MINORS criteria. In the case-control studies, a total of 549 DM cups and 649 UP cups were included. In the registry studies, a total of 5,935 DM cups and 217,362 UP cups were included. In the case-control studies, one (0.2%) dislocation was reported for the DM cups and 46 (7.1%) for the UP cup ( $p=0.009$ , IQR = 0.00–7.00). Nine (1.6%) revisions, of which zero due to dislocation, were reported for the DM cup and 39 (6.0%), of which 30 due to dislocation, for the UP cup ( $p=0.046$ , CI = –16.93–5.73). In the registry studies 161 (2.7%) revisions were reported for the DM cup, of which 14 (8.7%) due to dislocation. For the UP cup, 3,332 (1.5%) revisions were reported ( $p=0.275$ , IQR = 41.00–866.25), of which 1,093 (32.8%) due to dislocation ( $p=0.050$ , IQR = 3.50–293.25).

**Conclusion:** This review suggests lower rates of dislocation and lower rates of revision for dislocation in favor of the DM cups. Concluding, DM cups might be an effective solution to reduce dislocation in primary THA. To evaluate the efficacy of DM cups compared to UP cups, an economic evaluation alongside a randomized controlled trial is needed focusing on patient important endpoints.

**Level of evidence:** III, systematic review of level III studies.

## 1. Introduction

Total hip arthroplasty (THA) for end-stage osteoarthritis of the hip is one of the most successful orthopedic surgical procedures. It treats pain, improves function and thereby increases quality-of-life [1]. However, dislocation is the leading cause for early revision surgery after THA [2]. Most dislocations occur during the first year after surgery, of which approximately half within the first three months after surgery [3–5]. Hip dislocation is a major problem that

results in reduced functioning and a deterioration in quality-of-life [6]. After a first dislocation, there is an increased chance that the THA will re-dislocate again, with rates reported up to 60% [7–9]. In addition to the negative consequences for a patient, dislocations also increase healthcare costs. For an uncomplicated single dislocation, these costs were estimated at 19% of total hospital costs, when revision surgery was required these costs increased up to 148% [10,11].

To address the problem of dislocation, Gilles Bousquet developed the dual mobility (DM) cup in France in the 1970s [12]. This design is a combination of the low friction arthroplasty by Sir John Charnley [13] and a large diameter head by Mac Kee [14]. The DM cup consists of two articulations between three different components; a metallic acetabular shell, a mobile polyethylene liner and a femoral head. The mobile liner articulates both with the acetabular shell and the femoral head. This should provide more stability and biomechanically reduce the risk of dislocation [15–17]. Dislocation rates reported for the DM cup range from 0 to 3.6% [16–21], which seems slightly lower than the 0.5 to 6% reported for the standard, unipolar (UP) cups [22–26]. Also, the use of DM cups for revision surgery in patients with recurrent dislocation has shown promising results [3,27,28]. Internationally, DM cups are used widely for revision surgery [29–31] and as primary THA in patients at high risk for dislocation [32,33]. In France, DM cups are used in an estimated 30% of all primary THAs [34]. In the Netherlands, DM cups are mostly used in case of specific patient characteristics, such as cognitive impairment, neuromuscular diseases or as a standard procedure for revision surgeries due to recurrent dislocations [35]. These characteristics might negatively affect the risk for dislocation and revision surgery compared to the general THA population. Potential disadvantages of DM cups are known to include; increased liner wear [36], loosening [37,38] and intra prosthetic dislocation (IPD) [37,39]. These disadvantages may result in revision surgery at longer follow-up. However, when used for revision surgery, there seems to be a significantly lower re-revision rate for the DM cup at 5 years of follow-up [40]. Higher implant costs in several countries compared with many conventional UP cup implants [41] are of topic, but a systematic review of Rudy et al. [42] states that DM cups are cost-effective.

Despite the increased and, in some countries, extensively use of DM cups, high quality evidence of their effectiveness is lacking [19]. There are a few well-conducted literature reviews, but the level of evidence of the included studies is moderate to low and the rates of revision were not specifically investigated. These studies did not make a distinction between case-control and registry studies, which is important because dislocations resolved by closed reduction will be missed in registry studies with revision as endpoint. Some of these reviews report on outcomes of the DM cup in revision surgery [43,44], or included patients with femoral neck fractures [45]. There are also reviews that did not make a direct comparison between the DM cup and UP cup [12,19,43–49], particularly regarding the rate of revision. Therefore, the aim of this study was to perform a systematic review of the literature to investigate whether there is a difference in the rate of dislocations and revisions after primary THA for degenerative diagnoses, between a DM cup or a UP cup.

## 2. Methods

### 2.1. Search strategy and selection criteria

We performed a systematic review of literature in order to identify articles reporting on dislocation rates in both DM cups and UP cups for patients undergoing primary THA. We conducted a literature search of the PubMed, Embase and Cochrane databases

in July 2019. To improve the search quality, a medical librarian assisted in the literature search. The search terms in PubMed for [Title/Abstract] were (((dual OR double) AND mobility) OR mobile bearing OR tripolar) AND hip. In Embase the search included: 1. dual mobility OR double mobility OR tripolar OR mobile bearing / 2. dislocat\* / 3. hip / 4: 1+2+3. In Cochrane we searched for: (((dual OR double) AND mobility) OR tripolar OR mobile bearing) AND dislocat\* AND hip (in title, abstract & keywords).

Inclusion criteria for our review were:

- Patients receiving a primary THA, due to a degenerative diagnosis (e.g. osteoarthritis, necrosis of the femoral head, rheumatoid arthritis, dysplasia)
- DM cup used as an intervention
- UP cup used as a control
- Dislocation and/or revision described as outcome

There was no selection in time period. Studies published in English or French were eligible for inclusion in this review. To gain reliable results on dislocation rates, we set a minimum follow-up period of 6 months. Exclusion criteria included the use of the DM cup in revision or trauma surgery primarily and reports of the same patient cohorts in different journals.

Two authors (RJ and LvB) performed all data screening and data extraction, using the mentioned selection criteria. Both reviewers screened the full-text articles of the papers found eligible in the first round. In case of different opinions, consensus was reached by discussion between both reviewers. Included articles were divided into two groups; case-control studies and registry studies.

### 2.2. Methodological quality assessment

We used Methodological Index for Non-randomized Studies (MINORS) to assess methodological quality [50]. This validation index was developed to determine the quality of observational and non-randomized studies. Two investigators (RJ and LvB) independently assessed the quality of each study, scoring the 12-item scale. In case of discussion, a third investigator (NW) was consulted. An item was scored as '0' when not reported, '1' when it was inadequately reported, and '2' when it was adequately reported, with a maximum and ideal score of 24 for comparative studies. This systematic review conforms with the PRISMA guidelines [51] and was registered at Prospero (registry number CRD42018091921).

### 2.3. Statistics

For descriptive statistics, we used totals, means and medians. Statistical analyses were performed using SPSS version 21. A test for normality was performed. With normally distributed data, an independent *t*-test was performed and the 95% confidence interval (CI) was given. In case of no normality, a Mann-Whitney-U test was used and the interquartile range (IQR) was given. A *p* value < 0.05 was considered significant.

## 3. Results

### 3.1. Study selection

The initial search identified 702 articles, of which, after screening for title, abstract and full-text, a total of eight articles met our inclusion criteria and were eligible for inclusion in this systematic review [15,18,35,52–56] (Fig. 1).

**Table 1**  
Study characteristics of included studies.

Author	Year	Country	Type of study	Surgery period	Pre-operative diagnoses	Approach	Implant head size
Bouchet et al. [15]	2011	France	Retrospective case-control, single center, One surgeon	DM: 2005–2007 UP: 2003–2005	DM: osteoarthritis ( <i>n</i> = 95), trauma ( <i>n</i> = 4), osteonecrosis ( <i>n</i> = 3), other ( <i>n</i> = 3) UP: osteoarthritis ( <i>n</i> = 100), osteonecrosis ( <i>n</i> = 8)	Posterolateral	DM: not specified UP: 28 mm
Caton et al. [18]	2014	France	Retrospective case-control, one surgeon	04/2000–09/2002	DM: osteoarthritis ( <i>n</i> = 95), osteonecrosis ( <i>n</i> = 6), fracture ( <i>n</i> = 4) UP: osteoarthritis ( <i>n</i> = 209), osteonecrosis ( <i>n</i> = 2), rheumatoid arthritis ( <i>n</i> = 4)	Posterolateral	DM: 22.2 mm UP: 22.2 mm
Epinette et al. [52]	2015	France	Prospective comparative cohort study. One surgeon	02/2007–12/2011	DM: osteoarthritis ( <i>n</i> = 134), osteonecrosis ( <i>n</i> = 7), other ( <i>n</i> = 2) UP: osteoarthritis ( <i>n</i> = 111), osteonecrosis ( <i>n</i> = 12), other ( <i>n</i> = 7)	Posterolateral	DM: 28 mm UP: 28 mm
Homma et al. [53]	2016	Japan	Retrospect case-control, single centre. Age matched control group	DM: ?/2013–01/2015 UP: 10/2011–?/2013	DM: osteoarthritis ( <i>n</i> = 41), osteonecrosis ( <i>n</i> = 3), fracture ( <i>n</i> = 14), other ( <i>n</i> = 2) UP: osteoarthritis ( <i>n</i> = 55), osteonecrosis ( <i>n</i> = 2), fracture ( <i>n</i> = 3)	Direct anterior	DM: not specified UP: 32 mm ( <i>n</i> = 46) and 36 mm ( <i>n</i> = 14)
Rowan et al. [54]	2017	United States of America	Retrospective matched case-control, single center	DM: 12/2011–12/2013 UP: 02/2007–06/2014	DM: osteoarthritis ( <i>n</i> = 106), dysplasia ( <i>n</i> = 11), osteonecrosis ( <i>n</i> = 10), inflammatory arthritis ( <i>n</i> = 3), trauma ( <i>n</i> = 3), other ( <i>n</i> = 3) UP: osteoarthritis ( <i>n</i> = 111), dysplasia ( <i>n</i> = 11), osteonecrosis ( <i>n</i> = 9), inflammatory arthritis ( <i>n</i> = 4), trauma ( <i>n</i> = 1)	Posterolateral	DM: 22.2 mm ( <i>n</i> = 9) and 28 mm ( <i>n</i> = 127) UP: 28 mm ( <i>n</i> = 13), 32 mm ( <i>n</i> = 90) and 36 mm ( <i>n</i> = 33)
Tarasevicius et al. [55]	2017	Lithuania	Retrospective registry study of the Lithuanian Arthroplasty Register (LAR). DM systems compared to the Exeter cemented system	01/2011–12/2014	DM: osteoarthritis ( <i>n</i> = 371), fracture ( <i>n</i> = 138), rheumatoid arthritis ( <i>n</i> = 4), hip dysplasia ( <i>n</i> = 16), post-traumatic osteoarthritis ( <i>n</i> = 22), osteonecrosis ( <i>n</i> = 40), other ( <i>n</i> = 29) UP: osteoarthritis ( <i>n</i> = 1.614), fracture ( <i>n</i> = 365), rheumatoid arthritis ( <i>n</i> = 6), hip dysplasia ( <i>n</i> = 38), post-traumatic osteoarthritis ( <i>n</i> = 50), osteonecrosis ( <i>n</i> = 88), other ( <i>n</i> = 9)	DM: posterolateral ( <i>n</i> = 573) and anterolateral ( <i>n</i> = 47) UP: posterolateral ( <i>n</i> = 2.074) and anterolateral ( <i>n</i> = 96)	DM: not specified UP: 28 mm
Kreipke et al. [56]	2019	Denmark	Retrospective registry study of the Nordic Arthroplasty Register Association (NARA). Matched cohort	1995–2013	DM: all osteoarthritis UP: all osteoarthritis	DM: posterolateral ( <i>n</i> = 2.162) and anterolateral or other ( <i>n</i> = 115) UP: posterolateral ( <i>n</i> = 1.905) and anterolateral or other ( <i>n</i> = 372)	DM: not specified UP: 28 mm, 32 mm or 36 mm (not specified)
Bloemheuvel et al. [35]	2019	Netherlands	Retrospective registry study of the Dutch Arthroplasty Register (LROI)	2007–2016	DM: osteoarthritis ( <i>n</i> = 1.688), fracture ( <i>n</i> = 424), late posttraumatic ( <i>n</i> = 406), other ( <i>n</i> = 476) UP: osteoarthritis ( <i>n</i> = 185.062), fracture ( <i>n</i> = 7.065), late posttraumatic ( <i>n</i> = 4.415), Other ( <i>n</i> = 14.163)	DM: posterolateral ( <i>n</i> = 2.607), anterior ( <i>n</i> = 96), anterolateral ( <i>n</i> = 41), direct lateral ( <i>n</i> = 254), other ( <i>n</i> = 9) UP: posterolateral ( <i>n</i> = 128.275), anterior ( <i>n</i> = 21.102), anterolateral ( <i>n</i> = 15.801), direct lateral ( <i>n</i> = 44.249), other ( <i>n</i> = 706)	DM: 22–28 mm (not specified) ( <i>n</i> = 2.784) UP: 22–28 mm ( <i>n</i> = 66.703), 32 mm ( <i>n</i> = 93.619), 36 mm ( <i>n</i> = 4.002), ≥ 38 mm ( <i>n</i> = 1.452)

DM = dual mobility, UP = unipolar.

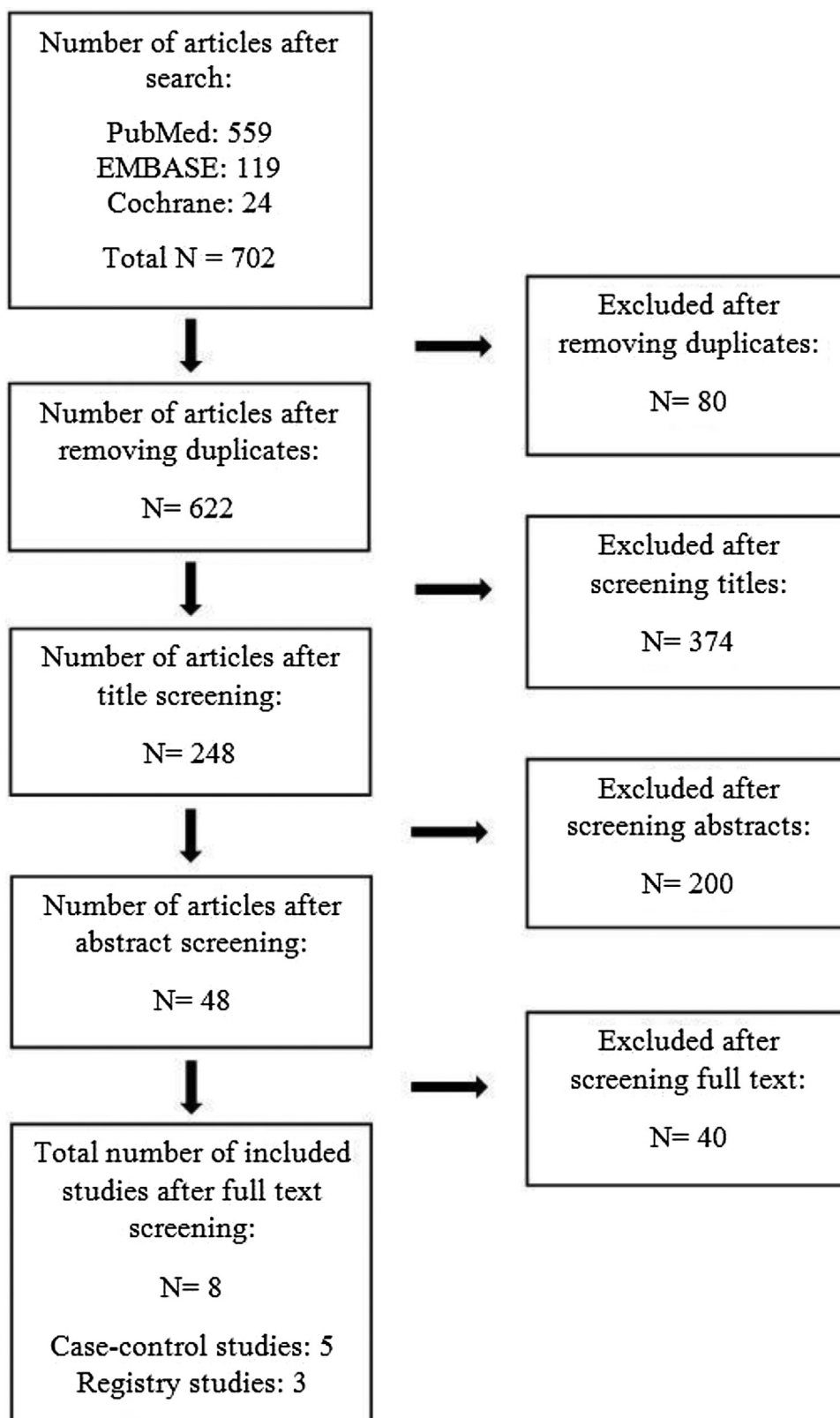


Fig. 1. Flowchart of study selection procedure.

### 3.2. Study characteristics and methodological quality assessment

The eight articles we included were published between 2011 and 2019, with a reported surgery period from 1995 to 2016. Five of the included articles were case-control studies of which

three were single surgeon reports published by French authors [15,18,52]. The two other case-control studies were single center studies from Japan [53] and the United States of America [54]. We included three registry studies reporting on dislocation of the DM cup [35,55,56]. Head size differed from 22.2 mm to  $\geq 38$  mm

**Table 2**  
Quality assessment of non-randomised studies, using MINORS [50] criteria.

Quality evaluation criteria*	Bouchet 2011	Caton 2014	EpINETTE 2015	Homma 2016	Rowan 2017	Tarasevicius 2017	Kreipke 2019	Bloemheugel 2019
Clearly stated aim	2	2	1	2	2	2	2	2
Inclusion of consecutive patients	2	2	0	1	1	2	2	2
Prospective collection of data	0	0	1	0	0	1	0	0
Endpoints appropriate to the study aim	2	2	1	2	2	2	2	2
Unbiased assessment of the study endpoint	0	0	0	0	0	0	0	0
Appropriate follow-up period	2	2	2	1	2	1	2	2
Loss to follow-up less than 5%	0	1	2	0	0	0	0	0
Prospective calculation of the study size	0	0	0	0	0	0	0	0
Adequate control group	2	2	2	2	2	2	2	2
Contemporary groups	1	2	2	1	1	2	2	2
Baseline equivalence	1	1	1	1	1	1	1	1
Adequate statistical analysis	2	2	1	1	2	2	2	2
<b>Total</b>	<b>14</b>	<b>16</b>	<b>13</b>	<b>11</b>	<b>13</b>	<b>15</b>	<b>15</b>	<b>15</b>

The items are scored 0 (not reported), 1 (reported but inadequate) or 2 (reported and adequate). The global ideal score being 16 for non-comparative studies and 24 for comparative studies.

for the UP cup and was 22.2 mm, 28 mm or not specified for the DM cup (Table 1). Implants used for the DM cup were; Novea by Serf, Quattro by Lepine, Avantage by Biomet, ADM and MDM by Stryker, Stafit by Zimmer, Saturne by Amplitude, Polarcup by Smith & Nephew, Selexys DS by Mathys and Gyros-cup by Depuy. The mean MINORS score for the assessment of methodological quality was 14 points (58% of ideal score), ranging from 11 to 16 (Table 2). No meta-analysis was performed, because there was too much dissimilarity in the methodology of the studies, resulting in clinical and methodological heterogeneity.

### 3.3. Case-control studies: dislocation and revision rates

A total of 1.198 hips were included, of which 549 were DM cups and 649 were UP cups (Table 3). Mean age at surgery was 68.2 years for the DM cups and 65.9 years for the UP cups. Follow-up differed from a minimum of 6 months up to 10 years. Only one dislocation was reported for the DM cup group (0.2%), in contrast to 46 reported dislocations for the UP cup group (7.1%) ( $p=0.009$ ,  $IQR=0.00-7.00$ ). The overall revision rate was nine (1.6%) in the DM group and 39 (6.0%) in the UP group ( $p=0.046$ ,  $CI=-16.93-5.73$ ). All cause revisions reported in the DM group were for aseptic loosening (cup;  $n=1$ , stem;  $n=3$ , total;  $n=4$ ), periprosthetic fracture ( $n=4$ ) and groin pain ( $n=1$ ). All cause revisions for the UP group were for instability ( $n=30$ ), aseptic loosening (cup;  $n=2$ , stem;  $n=3$ , both;  $n=1$ , total;  $n=6$ ), infection ( $n=2$ ) and periprosthetic fracture ( $n=1$ ). Overall cup revision rate (aseptic cup loosening, dislocation and groin pain) for the DM cup was two (0.4%) and 33 (5.1%) for the UP cup ( $p=0.081$ ,  $IQR=0.00-3.25$ ).

### 3.4. Registry studies: revision for dislocation and overall revision rates

A total of 223.297 hips were included, of which 5.935 were DM cups and 217.362 were UP cups (Table 4). Mean age at surgery was 71.4 years for the DM cups and 69.1 years for the UP cups. The median follow-up time differed from 2.5 to 3.2 years. The overall revision rate was 161 (2.7%) in the DM group and 3.332 (1.5%) in the UP group ( $p=0.275$ ,  $IQR=41.00-866.25$ ). There were 14 revisions for dislocation reported in the DM cup group (8.7%) and 1.093 reported in the UP cup group (32.8%) ( $p=0.050$ ,  $IQR=3.50-293.25$ ).

## 4. Discussion

Dislocation remains one of the most common complications of THA. Risk factors for dislocation can be patient-related, procedure-related or implant-related. Because patient related factors cannot be changed, investigation on procedure-related or implant-related factors have been a topic of research. This systematic review presents an overview of literature comparing the results of dislocation and revision rates between two principally different types of acetabular components for primary THA; the DM cup and the UP cup. Key findings of this systematic review are a lower rate of dislocation and lower rate of revision surgery for dislocation in DM cups, when used in primary THA, based on level 3 quality of evidence.

The case-control studies of this systematic review, reported only one [18] dislocation (0.2%) for the DM cup and 46 dislocations (7.1%) for the UP cup. Although research has shown that the use of a larger femoral heads may provide more stability and thereby reduce the risk of dislocation [14,57-59], three out of five case-control studies used heads of 28 mm or smaller for the UP cup [15,18,52]. Caton et al. [18] in particular reported a high rate of dislocation (12.1%) with the use of small size 22.2 mm heads in this group, operated with a posterolateral approach. In contrast, Homma et al. [53], reported only on one dislocation in their UP group, using 32 mm ( $n=46$ ) and 36 mm ( $n=14$ ) heads and a direct anterior approach. Despite their great benefits on stability and range-of-motion, a potential disadvantage of a large femoral head in combination with a thin polyethylene liner may be the increased risk of liner fracture [60] and wear [61]. However, specifically in newer, highly cross-linked polyethylene DM liners, no implications of high failure rates due to wear have been reported [62-64]. Another factor that could have contributed to the low rate of dislocation reported by Homma et al. [53], may be the direct anterior approach. Although, various studies have shown benefits of the direct anterior approach on dislocation rate [65,66], a systematic review of Higgins et al. [67] did not confirm any clear superiority on dislocation compared to the well known posterior approach.

Rates of revision surgery in the case-control studies also seem to be considerably lower in the DM cup group; 1.6% versus 6.0%. In the UP cup group, 30 out of 39 (76.9%) revisions were performed for recurrent instability. Despite the fact that this large share may probably be due to a selection bias for articles reporting on dislocation rates, other studies confirm that instability in UP cups is one of the most common reasons for revision surgery [2,3].

In contrast to the case-control studies, the registry studies showed higher rates of revision surgery for the DM cup. Whereas

**Table 3**

Results of included case-control studies.

Author	Total operated hips (n)	DM cup (n)	UP cup (n)	Mean age DM cup (years)	Mean age UP cup (years)	Gender DM cup (M/F)	Gender UP cup (M/F)	Follow-up DM cup	Follow-up UP cup	Dislocations DM cup (n)	Dislocations UP cup (n)	Total revisions DM cup (n)	Total revisions UP cup (n)	Cup revisions DM cup (n)	Cup revisions UP cup (n)
Bouchet et al. [15]	213	105	108	76.6	74.2	45/60	52/56	Mean 28 months	Mean 52 months	0	5	0	1	0	1
Caton et al. [18]	320	105	215	78	70.8	42/63	91/124	Minimum 10 years	Minimum 10 years	1	26	2	26	1	23
Epinette et al. [52]	273	143	130	70.6	65.5	49/87	53/72	Maximum 4.45 years	Maximum 6.71 years	0	7	4	9	1	7
Homma et al. [53]	120	60	60	75.6	74	12/46	7/50	Minimum 6 months	Minimum 6 months	0	1	0	1	0	0
Rowan et al. [54]	272	136	136	48.5	48.4	43/74	48/79	Median 3.2 years	Median 3.4 years	0	7	3 <sup>a</sup>	2	0	2

DM = dual mobility, UP = unipolar, M = male, F = female.

<sup>a</sup> 24 recalled modular femoral stems were excluded because of a specific stem-type complication.**Table 4**

Results of included registry studies.

Author	Total operated hips (n)	DM cup (n)	UP cup (n)	Mean age DM cup (years)	Mean age UP cup (years)	Gender DM cup (M/F)	Gender UP cup (M/F)	Follow-up DM cup	Follow-up UP cup	Revisions for dislocation DM cup (n)	Revisions for dislocation UP cup (n)	Total revisions DM cup (n)	Total revisions UP cup (n)
Tarasevicius et al. [55]	2.790	620	2.170	63.2	68	237/383	787/1.383	Median 2.5 years	Median 2.5 years	4	52	14	86
Kreipke et al. [56]	4.554	2.277	2.277	75.5	75.5	896/1.381	914/1.363	Median 2.99 years	Median 3.2 years	2	24	97	72
Bloemheuvel et al. [35]	215.953	3.038	212.915	70	69	1.104/1.934	70.144/14.771	Median 3 years	Median 3 years	8	1.017	50	3.174

DM = dual mobility, UP = unipolar, M = male, F = female.

dislocation (32.8%) is the leading reason for revision of UP cups, infection (29.8%) seems to be a common reason for revision of DM cups. Literature on the relation between DM cups and revision for infection is not consistent and based on observational data [68,69]. Because DM cups are regularly used in frail patients at risk for dislocation, this risk of infection and overall increased rate of revision surgery in DM cups is probably due to confounding for patient characteristics and co-morbidities. Patient characteristics reported by Bloemheugel et al. [35] confirm this suspicion, with an ASA-score of three and four in 31% in the DM cup group, compared to only 13% in the UP cup group.

The DM cup is becoming increasingly utilized worldwide. It is regularly selected in revision surgery to treat instability [29–31] and at present often used as primary THA in patients at high risk for dislocation [32,33,70]. Since the DM cup was already developed in the 1970s, many long-term results of case series with DM cups in primary THA have been published [16,17,20,21,38,71]. To our knowledge, there are only a few other systematic reviews reporting on the DM cup [12,19,42–49]. A network meta-analysis of four different bearings was performed by Pituckanotai et al. [46] in which all preoperative diagnoses were included for both primary THA and revision surgery. Batailler et al. [12], Martino et al. [48], Darrith et al. [19] Rudy et al. [42] Reina et al. [47] and Levin et al. [43] reported on outcomes of the DM cup in primary THA and revision surgery. However, no direct comparison between the primary THA with both DM cup and UP cup was made. Faldini et al. [44] only reported on revisions. Romagnoli et al. [45] included patients with femoral neck fractures and revision surgery. De Martino et al. [48] excluded French language articles. De Martino et al. [49] only reported on patients with early IPD.

There are some limitations applying to this study. Only eight articles met our inclusion criteria for comparing results of the DM cup to the UP cup. Although, the DM cup was already developed in France in the 1970s, we did not find any French comparative studies before 2011. Looking at the results of the MINORS-criteria, ranging from 11 to 16 points, the methodological quality of the included articles may be rated as medium to low depending on the cut-off points [72,73]. Furthermore, we need to make two substantive remarks on the included studies. First, we must note that 24 stem revisions in the study of Rowan et al. [54] were excluded (Table 3), because of a specific stem-type complication. This specific stem was only used in the DM group and because of the potential risk of fretting and corrosion at the modular neck junction, voluntarily recalled by its own manufacturer [74,75]. Secondary, we must note that there may be a selection bias by differences in population selection of the registry studies. Bloemheugel et al. [35] reported on their entire study population, whereas Tarasevicius et al. [55] chose an implant selected control group and Kreipke et al. [56] a sex, age, component fixation and year of surgery matched control group. Results of this systematic review suggests lower rates of dislocation and lower rates of revision for dislocation in favor of the DM cups. However, because included studies were of medium to low methodological quality, no clear conclusion on the use of DM cups for primary THA can be drawn. Therefore, level 1 studies (randomized controlled trials) should be conducted to confirm the results of the current literature.

## 5. Conclusion

This systematic review assessed dislocation and revision rates of DM cups compared to UP cups in primary THA for degenerative diagnosis in five case-control studies and three registry studies. The case-control studies reported overall lower rates of dislocation and revision for DM cups. However, this finding is not confirmed in the registry studies, which may be due to biased, patient specific

indication, for using DM cups. Though rates of revision for dislocation in DM cups seem considerably lower in the registry studies. Further research is necessary to evaluate the possible advantages using a DM cup in patients with hip osteoarthritis.

## Disclosure of interest

The authors declare that they have no competing interest. The research department of the OLVG received grant from Link and Lima, unrelated to this work.

## Funding

Authors Ragna C. Jonker, Bart C.H. van der Wal, H. Charles Vogely, Sebastien Parratte, René M. Castelein and Rudolf W. Poolman did not receive any financing for this study. This systematic review was part of a grant application for a project towards dislocation in total hip arthroplasty. Part of this grant application was to perform a systematic review on this topic. This grant has been approved by the Van Rens Foundation and provides in salary costs for author Loes W.A.H. van Beers. No further funding was received for conducting this systematic review.

## Author's contribution

Ragna C. Jonker; conceptualization and design of the study, methodology, data screening, data extraction, analysis descriptive data, writing and editing original draft.

Loes W.A.H. van Beers; conceptualization and design of the study, methodology, data screening, check extracted data, statistical tests, reviewing and editing manuscript.

Ragna C. Jonker and Loes W.A.H. van Beers contributed equally to this manuscript and join a first authorship.

Bart C.H. van der Wal and Rudolf W. Poolman; conceptualization and design of the study, supervision, validation and reviewing the manuscript.

H. Charles Vogely, Sebastien Parratte and René M. Castelein; supervision and validation of the manuscript.

## Acknowledgement

We would like to thank the medical librarian that helped with the literature search: B. Berenschot (OLVG, Amsterdam). We also would like to thank Dr. N. Willigenburg (OLVG, Amsterdam) for helping with the assessment of the methodological quality.

## References

- [1] March LM, Cross MJ, Lapsely H, Brnabic AJ, Tribe KL, Bachmeier CJ, et al. Outcomes after hip or knee replacement surgery for osteoarthritis. A prospective cohort study comparing patients' quality of life before and after surgery with age-related population norms. *Med J Aust* 1999;171:235–8.
- [2] Bozic KJ, Kurtz SM, Lau E, Ong K, Vail TP, Berry DJ. The epidemiology of revision total hip arthroplasty in the United States. *J Bone Joint Surg Am* 2009;91:128–33.
- [3] Hailer NP, Weiss RJ, Stark A, Kärrholm J. The risk of revision due to dislocation after total hip arthroplasty depends on surgical approach, femoral head size, sex, and primary diagnosis. *Acta Orthop* 2012;83:442–8.
- [4] Meek RMD, Allan DB, McPhillips G, Kerr L, Howie CR. Epidemiology of dislocation after total hip arthroplasty. *Clin Orthop Relat Res* 2006;447:9–18.
- [5] Phillips CB, Barrett JA, Losina E, Mahomed NN, Lingard EA, Guadagnoli E, et al. Incidence rates of dislocation, pulmonary embolism, and deep infection during the first six months after elective total hip replacement. *J Bone Joint Surg Am* 2003;85:20–6.
- [6] Enocson A, Pettersson H, Ponzer S, Törnkvist H, Dalén N, Tidemark J. Quality of life after dislocation of hip arthroplasty: a prospective cohort study on 319 patients with femoral neck fractures with a one-year follow-up. *Qual Life Res* 2009;18:1177–84.
- [7] Martinot P, Blairon A, Putman S, Pasquier G, Girard J, Migaud H. Course of dislocated posterior hip arthroplasty: a continuous 232-patient series at a



- mean 10 years' follow up (range, 1-22 years). *Orthop Traumatol Surg Res* 2018;104:325-31.
- [8] Kotwal RS, Ganapathi M, John A, Maheson M, Jones SA. Outcome of treatment for dislocation after primary total hip replacement. *J Bone Joint Surg Br* 2009;91:321-6.
  - [9] Yuan L, Shih C. Dislocation after total hip arthroplasty. *Arch Orthop Trauma Surg* 1999;119:263-6.
  - [10] Abdel MP, Cross MB, Yassen AT, Haddad FS. The functional and financial impact of isolated and recurrent dislocation after total hip arthroplasty. *Bone Joint J* 2015;97-B:1046-9.
  - [11] Sanchez-Sotelo J, Haidukewych GJ, Boberg CJ. Hospital cost of dislocation after primary total hip arthroplasty. *J Bone Joint Surg Am* 2006;88:290-4.
  - [12] Batailler C, Fary C, Verdier R, Aslanian T, Caton J, Lustig S. The evolution of outcomes and indications for the dual-mobility cup: a systematic review. *Int Orthop* 2017;41:645-59.
  - [13] Charnley J. The long-term results of low-friction arthroplasty of the hip performed as a primary intervention. *J Bone Joint Surg Br* 1972;54-B:61-76.
  - [14] Burroughs BR, Hallstrom B, Golladay CJ, Hoeffel D, Harris WH. Range of motion and stability in total hip arthroplasty with 28-, 32-, 38-, and 44-mm femoral head sizes: an in vitro study. *J Arthroplasty* 2005;20:11-9.
  - [15] Bouchet R, Mercier N, Saragaglia D. Posterior approach and dislocation rate: a 213 total hip replacements case-control study comparing the dual mobility cup with a conventional 28-mm metal head/polyethylene prosthesis. *Orthop Traumatol Surg Res* 2011;97:2-7.
  - [16] Boyer B, Philippot R, Geringer J, Farizon F. Primary total hip arthroplasty with dual mobility socket to prevent dislocation: a 22-year follow-up of 240 hips. *Int Orthop* 2012;36:511-8.
  - [17] Philippot R, Camilleri JP, Boyer B, Adam P, Farizon F. The use of a dual-articulation acetabular cup system to prevent dislocation after primary total hip arthroplasty: analysis of 384 cases at a mean follow-up of 15 years. *Int Orthop* 2009;33:927-32.
  - [18] Caton JH, Prudhon JL, Ferreira A, Aslanian T, Verdier R. A comparative and retrospective study of three hundred and twenty primary Charnley type hip replacements with a minimum follow up of ten years to assess whether a dual mobility cup has a decreased dislocation risk. *Int Orthop* 2014;38:1125-9.
  - [19] Darrith B, Courtney PM, Della Valle CJ. Outcomes of dual mobility components in total hip arthroplasty: a systematic review of the literature. *Bone Joint J* 2018;100-B:11-9.
  - [20] Fresard PL, Alverne C, Cartier JL, Cuinet P, Lantuejoul JP. Seven-year results of a press-fit, hydroxyapatite-coated double mobility acetabular component in patients aged 65 years or older. *Eur J Orthop Surg Traumatol* 2013;23:425-9.
  - [21] Prudhon JL, Ferreira A, Verdier R. Dual mobility cup: dislocation rate and survivorship at ten years of follow-up. *Int Orthop* 2013;37:2345-50.
  - [22] Bourne RB, Mehin R. The dislocating hip: what to do, what to do. *J Arthroplasty* 2004;19:111-4.
  - [23] Dargel J, Oppermann J, Bruggemann GP, Eysel P. Dislocation following total hip replacement. *Dtsch Arztebl Int* 2014;111:884-90.
  - [24] Jolles BM, Bogoch ER. Posterior versus lateral surgical approach for total hip arthroplasty in adults with osteoarthritis. *Cochrane Database Syst Rev* 2006;19:CD003828.
  - [25] Lachiewicz PF, Soileau ES. Low early and late dislocation rates with 36- and 40-mm heads in patients at high risk for dislocation hip. *Clin Orthop Relat Res* 2013;471:439-43.
  - [26] Malkani AL, Ong KL, Lau E, Kurtz SM, Justice BJ, Manley MT. Early- and late-term dislocation risk after primary hip arthroplasty in the medicare population. *J Arthroplasty* 2010;25:21-5.
  - [27] Langlais FL, Ropars M, Gaucher F, Musset T, Chaix O. Dual mobility cemented cups have low dislocation rates in THA revisions. *Clin Orthop Relat Res* 2008;466:389-95.
  - [28] Philippot R, Adam P, Reckhaus M, Delangle F, Verdout F, Curvale G, et al. Prevention of dislocation in total hip revision surgery using a dual mobility design. *Orthop Traumatol Surg Res* 2009;95:407-13.
  - [29] Guyon O, Pibarot V, Vaz G, Chevillotte C, Bèjui-Hugues J. Use of a dual mobility socket to manage total hip arthroplasty instability. *Clin Orthop Relat Res* 2009;467:465-72.
  - [30] Simian E, Chatellard R, Druon J, Berhouet J, Rosset P. Dual mobility cup in revision total hip arthroplasty: dislocation rate and survival after 5 years. *Orthop Traumatol Surg Res* 2015;101:577-81.
  - [31] Vasukutty NL, Middleton RG, Matthews EC, Young PS, Uzoigwe CE, Minhas THA. The double-mobility acetabular component in revision total hip replacement: the United Kingdom experience. *J Bone Joint Surg Br* 2012;94:603-8.
  - [32] Vasukutty NL, Middleton RG, Young P, Uzoigwe C, Barkham B, Yusoff S, et al. A double mobility acetabular implant for primary hip arthroplasty in patients at high risk of dislocation. *Ann R Coll Surg Engl* 2014;96:597-601.
  - [33] Hernigou P, Trousselier M, Roubineau F, Bouthors C, Flouzat Lachaniette CH. Dual-mobility or constrained liners are more effective than preoperative bariatric surgery in prevention of THA dislocation. *Clin Orthop Relat Res* 2016;474:2202-10.
  - [34] Epinette JA, Lafuma A, Robert J, Doz M. Cost-effectiveness model comparing dual-mobility to fixed-bearing designs for total hip replacement in France. *Orthop Traumatol Surg Res* 2016;102:143-8.
  - [35] Bloemheuvel EM, Steenbergen LN, Van, Swierstra BA. Dual mobility cups in primary total hip arthroplasties: trend over time in use, patient characteristics, and mid-term revision in 3,038 cases in the Dutch Arthroplasty Register (2007-2016). *Acta Orthop* 2019;90:11-4.
  - [36] Gaudin G, Ferreira A, Gaillard R, Prudhon JL, Caton JH, Lustig S. Equivalent wear performance of dual mobility bearing compared with standard bearing in total hip arthroplasty: in vitro study. *Int Orthop* 2017;41:521-7.
  - [37] Philippot R, Boyer B, Farizon F. Intra-prosthetic dislocation: a specific complication of the dual-mobility system hip. *Clin Orthop Relat Res* 2013;471:965-70.
  - [38] Farizon F, De Lavison R, Azouli JJ, Bousquet G. Results with a cementless alumina-coated cup with dual mobility. A twelve-year follow-up study. *Int Orthop* 1998;22:219-24.
  - [39] Fabry C, Langlois J, Hamadouche M, Bader R. Intra-prosthetic dislocation of dual-mobility cups after total hip arthroplasty: potential causes from a clinical and biomechanical perspective. *Int Orthop* 2016;40:901-6.
  - [40] Bloemheuvel E, Steenbergen L, Van, Swierstra B. Lower 5-year cup re-revision rate for dual mobility cups compared with unipolar cups: report of 15,922 cup revision cases in the Dutch Arthroplasty Register (2007-2016). *Acta Orthop* 2019;90:338-41.
  - [41] Mendenhall S. Orthopedic Network News Editorial - 2015 Hip and Knee Implant Review, 26; 2015.
  - [42] Rudy HL, Padilla JA, Gabor JA, Iorio R. Cost-effectiveness of dual mobility and a value-based algorithm of utilization. *Orthop Clin North Am* 2019;50:151-8.
  - [43] Levin JM, Sultan AA, O'Donnell JA, Sodhi N, Khlopas A, Piuze NS, et al. Modern dual-mobility cups in revision total hip arthroplasty: a systematic review and meta-analysis. *J Arthroplasty* 2018;33:3793-800.
  - [44] Faldini C, Stefanini N, Fenga D, Neonakis EM, Perna F, Mazzotti A, et al. How to prevent dislocation after revision total hip arthroplasty: a systematic review of the risk factors and a focus on treatment options. *J Orthop Traumatol* 2018;19:1-8.
  - [45] Romagnoli M, Grassi A, Costa GG, Lazaro LE, Lo Presti M, Zaffagnini S. The efficacy of dual-mobility cup in preventing dislocation after total hip arthroplasty: a systematic review and meta-analysis of comparative studies. *Int Orthop* 2019;43:1071-82.
  - [46] Pituckanotai K, Arirachakaran A, Tuchinda H. Risk of revision and dislocation in single, dual mobility and large femoral head total hip arthroplasty: systematic review and network meta-analysis. *Eur J Orthop Surg Traumatol* 2018;28:445-55.
  - [47] Reina N, Pareek A, Krych AJ, Pagnano MW, Berry DJAM. Dual-mobility constructs in primary and revision total hip arthroplasty: a systematic review of comparative studies. *J Arthroplasty* 2019;34:594-603.
  - [48] De Martino I, D'Apolito R, Soranoglou VG, Poultsides LA, Sculco PK, Sculco TP. Dislocation following total hip arthroplasty using dual mobility acetabular components a systematic review. *Bone Joint J* 2017;99B:18-24.
  - [49] De Martino I, D'Apolito R, Waddell BS, McLawhorn AS, Sculco PK, Sculco TP. Early intra-prosthetic dislocation in dual-mobility implants: a systematic review. *Arthroplast Today* 2017;3:197-202.
  - [50] Slim K, Nini E, Damien F, Kwiatkowski F, Panis Y, Chipponi J. Methodological Index for non-randomized studies (MINORS): development and validation of a new instrument. *ANZ J Surg* 2003;73:712-6.
  - [51] Moher D, Shamseer L, Clarke M, Ghersi D, Liberati A, Petticrew M, et al. Preferred reporting items for systematic review and meta-analysis protocols (PRISMA-P) 2015 statement. *Syst Rev* 2015;4:1-9.
  - [52] Epinette JA. Clinical outcomes, survivorship and adverse events with mobile-bearings versus fixed-bearings in hip arthroplasty-A prospective comparative cohort study of 143 ADM versus 130 Trident cups at 2 to 6-year follow-up. *J Arthroplasty* 2015;30:241-8.
  - [53] Homma Y, Baba T, Kobayashi H, Desroches A, Ochi H, Ozaki Y, et al. Benefit and risk in short term after total hip arthroplasty by direct anterior approach combined with dual mobility cup. *Eur J Orthop Surg Traumatol* 2016;26:619-24.
  - [54] Rowan FE, Salvatore AJ, Lange JK, Westrich GH. Dual-mobility vs fixed-bearing total hip arthroplasty in patients under 55 years of age: a single-institution, matched-cohort analysis. *J Arthroplasty* 2017;32:3076-81.
  - [55] Tarasevicius S, Smailys A, Grigaitis K, Robertsson O, Stucinskas J. Short-term outcome after total hip arthroplasty using dual-mobility cup: report from Lithuanian Arthroplasty Register. *Int Orthop* 2017;41:595-8.
  - [56] Kreipke R, Rogmark C, Pedersen AB, Hallan G, Havelin LI. Dual mobility cups: effect on risk of revision of primary total hip arthroplasty due to osteoarthritis. *J Bone Joint Surg Am* 2019;101:169-76.
  - [57] Sikes C, Van, Lai LP, Schreiber M, Mont MA, Jinnah RH, et al. Instability after total hip arthroplasty. Treatment with large femoral heads vs constrained liners. *J Arthroplasty* 2008;23:59-63.
  - [58] Howie D, Holubowycz O, Middleton R. Large femoral heads decrease the incidence of dislocation after total hip arthroplasty: a randomized controlled trial. *J Bone Joint Surg Am* 2012;94:1095-102.
  - [59] Berry DJ, von Knoch M, Schleck CD, Harmsen WS. Effect of femoral head diameter and operative approach on risk of dislocation after primary total hip arthroplasty. *J Bone Joint Surg Am* 2005;87:2456-63.
  - [60] Moore BKD, Beck PR, Petersen DW, Cuckler JM, Lemons JE, Eberhardt AW. Early failure of a cross-linked polyethylene acetabular liner. A case report. *J Bone Joint Surg Am* 2008;9:2499-504.
  - [61] Johnson AJ, Loving L, Herrera L, Delanois RE, Wang A, Mont MA. Short-term wear evaluation of thin acetabular liners on 36-mm femoral heads. *Clin Orthop Relat Res* 2014;472:624-9.
  - [62] Adam P, Farizon F, Fessy M. Dual articulation retentive acetabular liners and wear: surface analysis of 40 retrieved polyethylene implants. *Rev Chir Orthop* 2005;91:627-36.
  - [63] Loving L, Lee RK, Herrera L, Essner AP, Nevelos JE. Wear performance evaluation of a contemporary dual mobility hip bearing using multiple hip simulator testing conditions. *J Arthroplasty* 2013;28:1041-6.

- [64] Netter J, Hermida J, Chen P, Nevelos J, D'Lima D. Effect of microseparation and third-body particles on dual-mobility crosslinked hip liner wear. *J Arthroplast* 2014;29:1849–53.
- [65] Sheth D, Cafri G, Inacio MCS, Paxton EW, Namba RS. Anterior and anterolateral approaches for THA are associated with lower dislocation risk without higher revision risk. *Clin Orthop Relat Res* 2015;473:3401–8.
- [66] Tsukada S, Wakui M. Lower dislocation rate following total hip arthroplasty via direct anterior approach than via posterior approach: five-year-average follow-up results. *Open Orthop J* 2015;9:157–62.
- [67] Higgins BT, Barlow DR, Heagerty NE, Lin TJ. Anterior vs. posterior approach for total hip arthroplasty, a systematic review and meta-analysis. *J Arthroplasty* 2015;30:419–34.
- [68] Reina N, Delaunay C, Chiron P, Ramdane N, Hamadouche M. Infection as a cause of primary total hip arthroplasty revision and its predictive factors. *Orthop Traumatol Surg Res* 2013;99:555–61.
- [69] Prudhon JL, Desmarchelier R, Hamadouche M, Delaunay C, Verdier R. Is dual mobility associated with an increased risk of revision for infection? Matched cohort of 231 cases of dual-mobility cups and 231 fixed cups. *Hip Int* 2018;28:200–4.
- [70] Fessy MH, Putman S, Viste A, Isida R, Ramdane N, et al. What are the risk factors for dislocation in primary total hip arthroplasty? A multicenter case-control study of 128 unstable and 438 stable hips. *Orthop Traumatol Surg Res* 2017;103:663–8.
- [71] Philippot R, Farizon F, Camilleri J, Boyer B, Derhi G, Bonnan J, et al. Survival of cementless dual mobility socket with a mean 17 years follow-up. *Rev Chir Orthop* 2008;94:23–7.
- [72] Grisar K, Chaabouni D, Romero LPG, Vandendriessche T, Politis C, Jacobs R. Auto-genous transalveolar transplantation of maxillary canines: a systematic review and meta-analysis. *Eur J Orthod* 2018;40:608–16.
- [73] de Boer A, Taskila T, Ojajarvi A, van Dijk F, Verbeek J. Cancer survivors and unemployment: a meta-analysis and meta-regression. *JAMA* 2009;301:753–62.
- [74] Meftah M, Haleem AM, Burn MB, Smith KM, Incavo SJ. Early corrosion-related failure of the Rejuvenate modular total hip replacement. *J Bone Joint Surg Am* 2014;96:481–7.
- [75] Nawabi DH, Do HT, Ruel A, Lurie B, Elpers ME, Wright T, et al. Comprehensive analysis of a recalled modular total hip system and recommendations for management. *J Bone Joint Surg Am* 2016;98:40–7.