



HAL
open science

Long-term results of custom-made femoral stems

Christophe Jacquet, Xavier Flecher, Charles Pioger, Maxime Fabre-Aubrespy,
Matthieu Ollivier, Jean-Noël Argenson

► **To cite this version:**

Christophe Jacquet, Xavier Flecher, Charles Pioger, Maxime Fabre-Aubrespy, Matthieu Ollivier, et al.. Long-term results of custom-made femoral stems. *Orthopäde*, 2020, 49 (5), pp.408-416. <10.1007/s00132-020-03901-z>. <hal-03175931>

HAL Id: hal-03175931

<https://hal.science/hal-03175931v1>

Submitted on 8 Apr 2021

HAL is a multi-disciplinary open access archive for the deposit and dissemination of scientific research documents, whether they are published or not. The documents may come from teaching and research institutions in France or abroad, or from public or private research centers.

L'archive ouverte pluridisciplinaire **HAL**, est destinée au dépôt et à la diffusion de documents scientifiques de niveau recherche, publiés ou non, émanant des établissements d'enseignement et de recherche français ou étrangers, des laboratoires publics ou privés.



HAL Authorization

Long-term results of custom-made femoral stems

Introduction

The combined progress of 3D imaging and manufacturing of implants has made it possible to implement the custom-made implant concept in total hip arthroplasty (THA), now integrated in a whole concept of computer-assisted surgery. This article focuses on custom-made hip prostheses, describing the elements which lead to the design and the clinical use of custom-made stems. It presents a specific philosophy, describing the planning, design and long-term clinical results of custom-made hip prostheses.

Why custom-made implant?

Osteoarthritis in young and active patients

The success of THA in older patients has inevitably led to its increased use in young and active patients. In this population THA will have higher rates of femoral loosening and osteolysis compared with the general population [7, 24].

On the femoral side, the durability of cementless components may be at least as good as for cemented implants, particularly in young patients [14] but depend on the design, the material and the type of coating used [6, 7]. Some prerequisites are essential when using cementless stems: initial implant stability, durable long-term bone implant fixation, strain transmission to the proximal femur and

restoration of hip mechanics. Primary stability of the stem is a fundamental element for secondary bone ingrowth and proper long-term fixation. Initial stability depends either on filling the proximal femur with intimate contact between the stem and the anatomic shape of the proximal femur (an anatomic fit) or filling the femoral diaphysis [39]. In previous anatomic studies, important anatomic variations in the upper femur intramedullary shape and the femoral neck (FA, FO and neck-shaft angle) were described for primary hip OA [2, 34]. This variability may prevent ensuring a primary stability and accurately restoring the hip biomechanical parameters with clinical consequences such as limping [3], instability, edge loading [32] and dislocation. For instance, a decrease of 15% in FO generates consequences on the gait quality [33], suggesting that the accuracy of FO restoration should be higher in patients with high expectations such as young and active patients; however, when proximal fixation on cancellous bone is favored, with an anatomic stem, optimal fit-and-fill of the metaphysis can be difficult to achieve with commercially available prostheses, even with various anatomic designs and sizes [25].

In order to address this highly variable proximal femur anatomy, most manufacturers propose several designs including at least two neck-diaphysis angle stems and one high femoral offset stem; however, such cementless stems do not allow a fine tuning of the femoral anteversion. Modular neck stems have also been proposed to increase the possibilities for restoration of FO, leg length and

FA. The risk of neck fracture or pseudotumors [22] related to modular taper corrosion has limited the use of these type of stems. Considering intramedullary and extramedullary expected anatomic variations, it is presumed that custom-made cementless femoral stems might restore and maintain hip function and result in less osteolysis and a high survival rate in patients younger than 50 years.

Secondary osteoarthritis due to developmental dysplasia of the hip (DDH) Crowe grades III and IV [9]

The use of THA for neglected DDH is a technically demanding and difficult procedure for arthroplasty surgeons [17]. The placement of the acetabular component in the true acetabulum is now considered to be the ideal choice for biomechanical and biological reasons [38]. It can, thus, be challenging

Abbreviations

<i>AP</i>	Anteroposterior
<i>AVN</i>	Avascular necrosis
<i>BMI</i>	Body mass index
<i>CT</i>	Computed tomography
<i>DDH</i>	Developmental dysplasia of the hip
<i>FA</i>	Femoral anteversion
<i>FO</i>	Femoral offset
<i>GTO</i>	Greater trochanteric osteotomy
<i>HHS</i>	Harris hip score
<i>OA</i>	Osteoarthritis
<i>THA</i>	Total hip arthroplasty

Table 1 Demographic data of the 212 young patients (233 hips)

Parameter	Results (range)
Age (years)	39.6 ± 7 (20–50)
BMI (kg/m ²)	25 ± 5 (16–48)
Male (n;%)	106 (50%)
Primary osteoarthritis (n;%)	41 (17.6%)
Secondary osteoarthritis (n;%)	115 (49.4%)
DDH (n;%)	88
Posttraumatic (n;%)	27
AVN (n;%)	77 (33%)
Preoperative Harris hip score	54.2 (26–87)
Preoperative Merle d'Aubigne-Postel score	7.6 (0–13)
Mean follow-up (years)	20 (14–27)

BMI body mass index, DDH developmental dysplasia of the hip, AVN avascular necrosis

to reduce the hip joint and achieve leg length restoration while avoiding neurologic traction injury [8, 9]. Therefore, to reduce the hip without stretching the sciatic nerve, femoral shortening was introduced by Paavilainen et al. [31] and Eskelinen et al. [15] as an adjunct to THA. Several authors have reported long-term results of THA for high DDH performed using shortening osteotomy [21, 30, 37]. To avoid the complications related to osteotomy, recent studies described a two-stage progressive femoral lowering followed by a cementless THA [5, 38]; however, only few papers have documented the long-term results of isolated cementless THA with such an etiology (Crowe III and IV) [23] and none using isolated custom-made stems without the use of a combined osteotomy. In the review by Tsiampas et al. [36] the long-term series mentioned in the article with custommade femoral implants was not only focused on high DDH but also combined femoral shortening osteotomy.

This study focused on the clinical and radiographic results after a minimum of 10 years follow-up of THA for Crowe III and IV DDH using a customized stem without shortening osteotomy, combined with sequential tenotomies and/or GTO when necessary.

Table 2 Demographic data of the 21 DDH Crowe III and IV patients (26 hips)

Parameter	Results (range)
Age (years)	45 ± 12.3 (17–73)
BMI (kg/m ²)	27.3 ± 6.1(16–52)
Male (n;%)	13 (61.9%)
DDH Crowe III	12 (46.1%)
DDH Crowe IV	14 (53.9%)
Preoperative Harris hip score	41.5 (21–70)
Mean follow-up (years)	16 (10–22)

BMI body mass index, DDH developmental dysplasia of the hip

Methods

A consecutive series of 232 primary custom-made cementless stem THAs was retrospectively evaluated in 212 patients less than 50 years old at the time of the surgery and surgically treated between January 1990 and September 2002. Primary hip osteoarthritis, AVN, DDH classified as grade I or II of the classification of Crowe and an age between 17 and 50 years at the time of the index procedure were the inclusion criteria. Patient characteristics are summarized in **Table 1**.

A second consecutive series of one-stage custom-made cementless stem for 26 THAs for late DDH (21 patients) including only Crowe grade III (75–100% subluxation) and grade IV (100% subluxation), surgically treated between 1990 to 2013 were also retrospectively evaluated. Patient characteristics are summarized in **Table 2**.

How to design a custom-made implant?

Preoperative planning

The custom femoral stem design was based on preoperative radiographs and CT scan analysis and individually customized for each patient. The radiographs include AP and lateral views of the hip, an AP view of the pelvis, and full length views of the two lower limbs (with the patient in the supine position), which enable estimation of lengthening and offset correction necessary during the definitive surgery. A CT scan

was performed to simulate the three-dimensional design of the stem for its intramedullary fit, promoting cancellous bone contact without cortical bone contact. This is enabled by the use of a single smooth custom stainless steel rasp of the same shape as the final implant to compress the cancellous bone. The CT scan also enabled evaluation of the correction needed for the appropriate offset and anteversion of the neck of the prosthesis in order to restore the hip center (**Fig. 1**). The surgeon provided the technician with the correction to be made laterally for each patient based on the contralateral side when normal or on the lever-arm ratio described by Amstutz and Sakai [1] and the abductor angle [16] when abnormal or in the case of bilateral disease. Regarding the additional information provided by the CT scan (femoral neck anteversion) and the lengthening to be realized (based on the full-leg view of the limbs), the three-dimensional neck of the prosthesis could then be planned.

For the young patient group, a hemispherical uncemented titanium alloy hydroxyapatite (HA)-coated cup (Hilock, Symbios, Yverdon, Switzerland) was used. For the DDH group, a hemispherical press-fit uncemented titanium alloy, HA-coated acetabular component (Hilock Rev, Symbios) was implanted in the true acetabulum with a hook placed in the obturator foramen and two screws in the acetabular roof. Autogenous femoral head grafts were used to provide additional superolateral acetabular coverage in 7 hips (27%), 3 in Crowe III (3 of 12, 25%), and 4 in Crowe IV (4 of 14, 29%). In all cases, a polyethylene insert was used in association with a 28 mm diameter ceramic head. The same custom-made cementless femoral stem Ti-alloy (Symbios) was used for both groups (**Fig. 2**).

Surgical techniques

All the procedures were performed with the patient under general anesthesia by a senior surgeon using the anterolateral approach in the supine position without a traction table. A single smooth custom stainless steel rasp was used in all procedures to prepare the femur.

Long-term results of custom-made femoral stems

Abstract

Background. The progress of 3D imaging and manufacturing of implants has made it possible to achieve a custom-made concept in THA. The custom-made cementless femoral stem provides optimal implant stability combined with restoration of the native hip mechanics.

Objective. The purpose of this study was to evaluate the long-term survivorship of custom-made hip femoral stems in two populations of patients undergoing THA: patients under 50 years old (young patients group) and patients with high-grade developmental dysplasia of the hip (DDH group).

Methods. A series of 232 primary custom-made cementless THA stems were retrospectively evaluated in patients less than 50

years old at the time of surgery and at follow-up after an average of 20 years. A second series of 26 custom-made cementless stem THAs for late DDH (21 patients) including only Crowe grade III and grade IV were also retrospectively evaluated with an average follow-up of 16 years. The clinical and radiological evaluations were performed preoperatively and at yearly intervals.

Results. For the young patient group, the follow-up ranged from 14 to 27 years. The HHS and the Merle D'Aubigne-Postel score significantly improved from preoperatively to a mean of 94.1 (range 48–100) and 15.9 (range 9–18), respectively. Taking stem revision for aseptic loosening as an endpoint, survivorship was 96.8% at 20 years (95% confidence interval, CI 95.1–98.5). For the DDH group,

the follow-up ranged from 10 to 22 years. The mean HHS increased significantly from preoperative 49 ± 22 points to the most recent follow-up examination with 86 ± 13 points and survivorship was 96.1% (95% CI, 92.7–99.9).

Conclusion. Custom-made femoral stems provide good functional outcome and long-term survivorship in two specific populations of patients undergoing THAs: patients under 50 years old with high expectations and patients with high-grade DDH.

Keywords

Custom implant · Total hip arthroplasty · Young patients · Developmental dysplasia of the hip · Cementless stem

Langzeitergebnisse zu maßgefertigten Femurschäften

Zusammenfassung

Hintergrund. Der Fortschritt der 3-D-Bildgebung und der Herstellung von Implantaten hat es ermöglicht, ein maßgeschneidertes Konzept in der THA zu erreichen. Der maßgefertigte zementfreie Femurschaft bietet optimale Implantatstabilität bei gleichzeitiger Wiederherstellung der nativen Hüftmechanik.

Ziel. Das Ziel dieser Studie war es, die Langzeitüberlebensfähigkeit maßgefertigter Femurschäfte der Hüfte bei zwei Patientenpopulationen zu untersuchen, die sich einer Hüfttotalendoprothese (TEP) unterziehen: Patienten unter 50 Jahren (Gruppe junger Patienten) und Patienten mit hochgradiger Entwicklungsdysplasie der Hüfte (DDH-Gruppe).

Methoden. Eine Serie von 232 primären zementfreien maßgefertigten TEP-Schäften wurde bei Patienten unter 50 Jahren retrospektiv zum Zeitpunkt der Operation und

nach durchschnittlich 20 Jahren Follow-up ausgewertet. Eine zweite Serie von 26 maßgefertigten zementfreien THA-Schäften für späte DDH (21 Patienten), darunter nur Crowe-Grad III und IV, wurde ebenfalls retrospektiv mit einem durchschnittlichen Follow-up von 16 Jahren ausgewertet. Die klinischen und radiologischen Auswertungen wurden präoperativ und in jährlichen Abständen durchgeführt.

Ergebnisse. Bei der jungen Patientengruppe reichte die Nachbeobachtung von 14 bis 27 Jahren. Der HHS- und der Merle-D'Aubigne-Postel-Score verbesserten sich signifikant von präoperativ auf einen Mittelwert von 94,1 (Range: 48–100) bzw. 15,9 (Range: 9–18). Nimmt man die Schaftrevision aufgrund aseptischer Lockerung als Endpunkt, so betrug die Überlebensrate nach 20 Jahren 96,8% (95% Konfidenzintervall, [KI] 95,1–98,5). Bei der

DDH-Gruppe reichte die Nachbeobachtung von 10 bis 22 Jahren. Der mittlere HHS stieg signifikant von präoperativ 49 ± 22 Punkten bis zur letzten Nachuntersuchung mit 86 ± 13 Punkten, und die Überlebensrate betrug 96,1% (95% KI 92,7–99,9).

Schlussfolgerung. Maßgefertigte Femurschäfte bieten gute funktionelle Ergebnisse und langfristige Überlebenschancen bei zwei spezifischen Patientenpopulationen, die sich einer TEP unterziehen: bei Patienten unter 50 Jahren mit hohen Erwartungen und bei Patienten mit hochgradiger DDH.

Schlüsselwörter

Maßgefertigtes Implantat · Hüfttotalendoprothese · Junge Patienten · Entwicklungsdysplasie der Hüfte · Zementfreier Schaft

In cases of DDH III and IV, GTO was performed in 6 hips (23%) for lateral repositioning when excessive femoral anteversion was present to relocate the abductor muscles action line and avoid a posterior position. Sequential tenotomies were performed if needed for lowering of the femur including adductor or iliopsoas tenotomy (22/26 hips, 85%). The femoral head-neck resection

was performed at the level of the lesser trochanter to ensure a complete capsular detachment. No abductor or fascia lata muscles release, intertrochanteric shortening or rotational femoral osteotomy was performed, and no external fixator was used. No sciatic nerve tension assessment or release was performed and GTO, when performed, was stabilized

with three cerclages with the lower limb in abduction (■ Fig. 3).

Postoperative management

Postoperative rehabilitation protocols included immediate weightbearing protected by crutches during the first 2–3 weeks depending on patient tolerance, and exercises focused on passive and then active recuperation of range

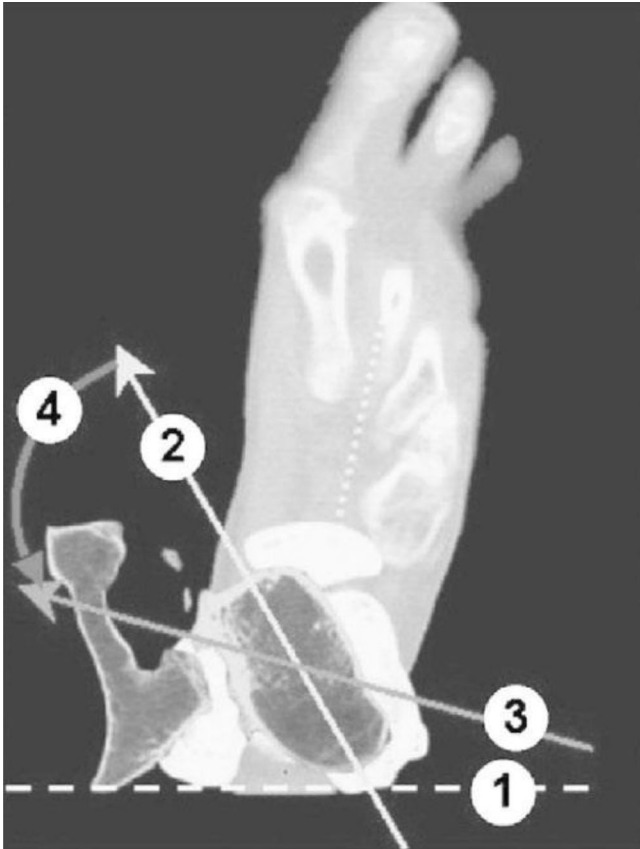


Fig. 1 ◀ The measurements performed with the CT scan analysis: the bicondylar plan (1), the femoral neck anteversion (2), the desired final prosthetic anteversion (3) and the alpha angle (4) are shown. Cross-sectional horizontal view of the lower limb using CT-scan

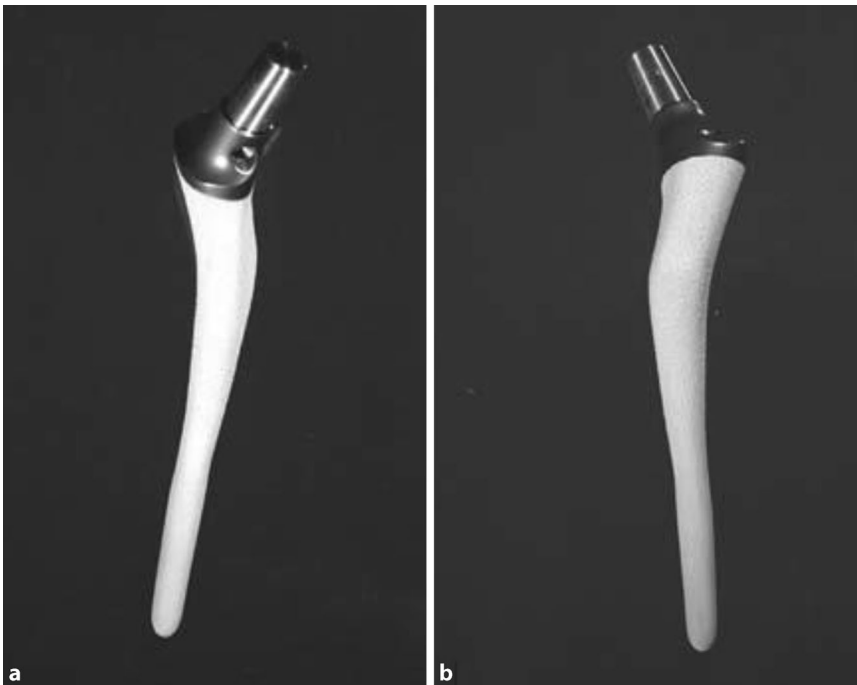

Fig. 2 ▲ a Medial and b lateral views of the custom-made titanium alloy hydroxyapatite-coated prosthesis

of motion. In the case of grades III and IV DDH, the 2 crutches were used for 6 weeks in cases of GTO, without active abduction work-out and for 3 weeks when no GTO was performed, and a single crutch on the opposite side was required for an 3 additional weeks. No brace was used. All patients received thromboprophylaxis with low molecular weight heparin preoperatively and postoperatively for 21 days.

Clinical and radiographic evaluation

The clinical evaluations were performed by the surgeon preoperatively, at 3 months postoperatively, then at yearly intervals until the last follow-up, during which a radiographical and clinical evaluation was carried out by one surgeon not involved in the treatment. The presence of intraoperative or postoperative complications including infection, nerve palsy, dislocations and loosening was recorded. The Merle D'Aubigne-Postel score [10] (only for the young patients group) and Harris hip score (HHS) [20] were used to evaluate the patient's preoperative and postoperative functional level. The University of California at Los Angeles (UCLA) score [4] was also used to evaluate the patient's level of activity only for the young patient group. To evaluate the postoperative radiographical results AP views of the pelvis, hips and true lateral views of the hip were performed. A comparison with the first postoperative radiograph was then used to search for any radiolucency, osteolysis or subsidence. To study postoperative leg lengths, a measure of the distance from the lesser trochanter to the acetabular teardrop was realized. The 7 zones described by Gruen et al. [19] were used to analyze the femur and the progressive appearance of radiolucency. The criteria of Engh and Bobyn [13] were used to evaluate femoral component stability. Polyethylene wear was not measured but revisions for wear were recorded.

Statistical analysis

Data are presented as mean values with ranges. The Student's t test was used for comparisons of continuous variables. *P* value < 0.05 was significant. Kaplan-

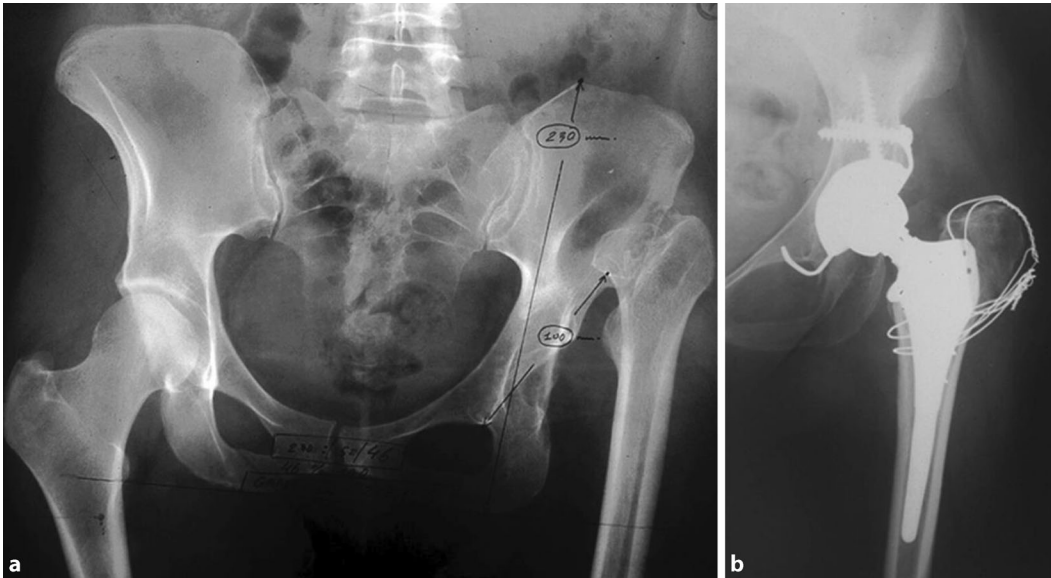


Fig. 3 ◀ Crowe IV DDH with greater trochanter osteotomy. Frontal X-ray image of the pelvis and the hip showing Crowe IV DDH case of the left hip (a) and the post-operative view (b) with the custom stem combined to greater trochanter osteotomy

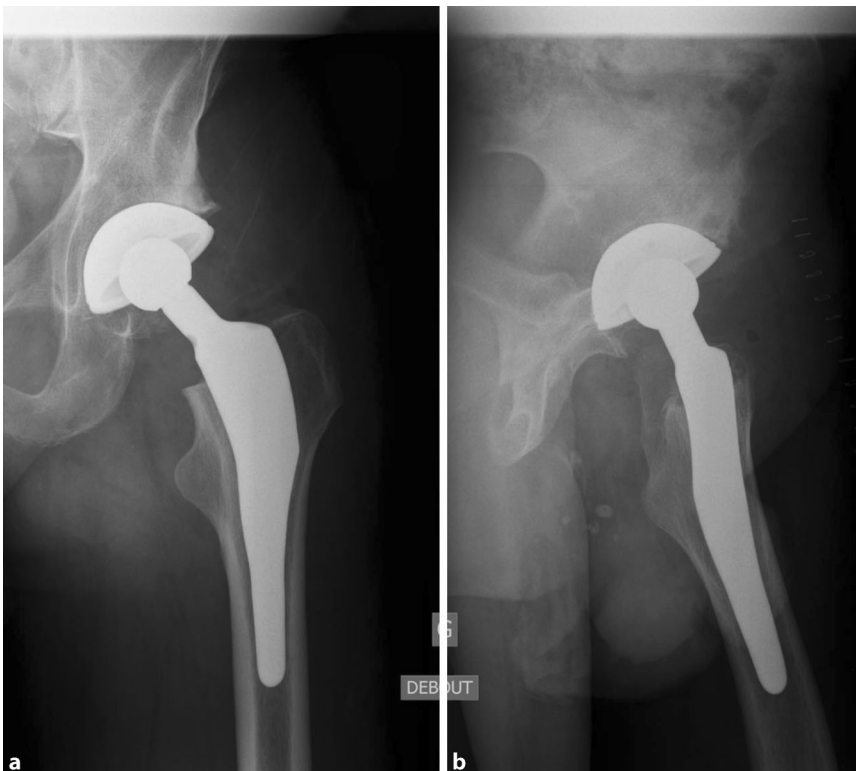


Fig. 4 ▲ Postoperative X-rays of a 44-year-old patient with custom-made cementless femoral stem. Postoperative X-ray images in frontal (a) and dorsal (b) views of a 44-year-old patient with a custom-made cementless femoral stem

Meier survivorship analysis was performed with 2 end points: (1) revision for any reason and (2) revision for aseptic loosening, mechanical failure, or wear. Statistical analysis was performed using SPSS software (IBM, Armonk, NY, USA).

Results

Group 1: young patients

At the latest follow-up 148 patients were still working, 12 patients died including 2 who underwent a femoral revision at 14.7 and 21.1 years of age, respectively.

Clinical evaluations were completed for all living patients with a surviving custom-made femoral stem. An example is shown in **Fig. 4**. Radiographs were taken at an average of 20 years postoperatively (range 15–27 years) and were available for 112 patients (125 hips, 53.6%). At the time of follow-up, the HHS and the Merle D' Aubigne-Postel scores were significantly improved from preoperatively to a mean of 94.1 (range 48–100) ($p < 0.001$) and 15.9 (9–18) ($p < 0.001$), respectively. At the most recent follow-up, the mean UCLA score improved from 5.2 (range 2–8) points to 7.0 (range 4–10) points ($p = 0.007$) and 161 patients had a score > 6 , indicating regular involvement in moderate physical activities. The mean postoperative leg length discrepancy was 2.3 mm (0–13) and was less than 5 mm for 94% of patients. For the 125 hip radiographs available at a mean follow-up of 20 years, no patient had subsidence of the femoral stem. Furthermore, femoral abnormalities were recorded in 18 patients (8.5%): 6 cases of cortical hypertrophy (3 in Gruen zone 4, 2 in Gruen zone 2, 1 in Gruen zone 3), 7 osteolysis (4 in Gruen zone 1, 3 in Gruen zone 1 and 8), 4 stem-cortical contacts (1 in Gruen zone 12 and 3 in Gruen zone 6) without thigh pain, and 1 patient with cortical endomedullary densification with pain. Radiographic abnormalities were observed in the acetabulum for 10 patients

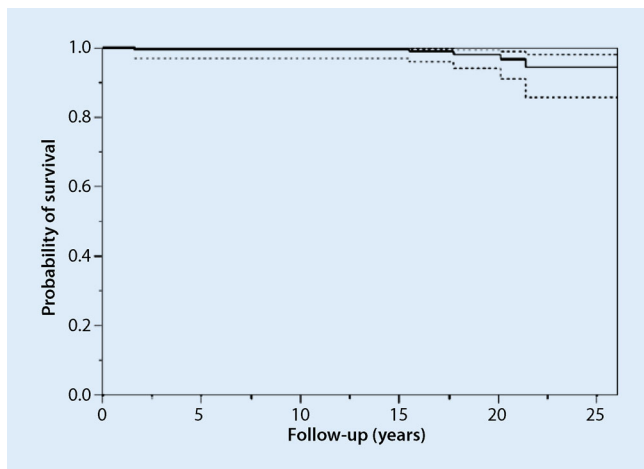


Fig. 5 ▲ Kaplan-Meier survivorship analysis with revision of the femoral stem for any reason as an endpoint. The 20-year survival rate of the femoral stem was 96.8%

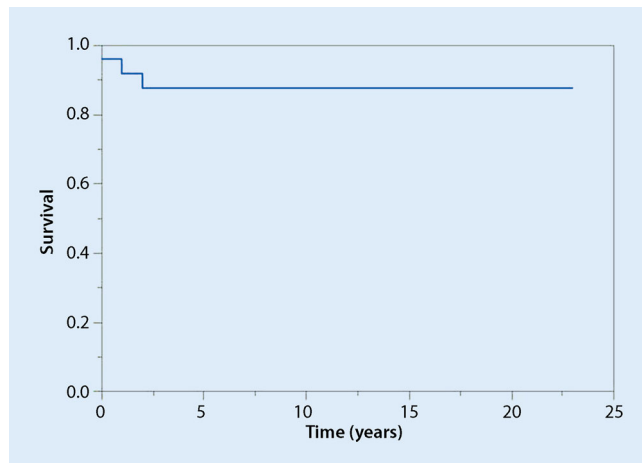


Fig. 6 ▲ Kaplan-Meier survivorship analysis with revision of the femoral stem for any reason as an endpoint. The 15-year survival rate of the femoral stem was 87.5%

(4.7%): 3 with migration and 7 with complete radiolucent lines. Reoperations without revision of at least 1 of the implants occurred for 12 hips (5.1%): 4 infections required surgical washout, 3 symptomatic heterotopic ossifications needed to be removed, 1 postoperative diaphyseal femoral fracture had to be fixed with a plate, 1 polyethylene liner-cup dislocation needed the liner to be replaced in the retained cup, 1 painful trochanteric wire had to be removed, 1 greater trochanteric fracture nonunion was r-fixed after a fracture and fixation with cerclage wires during the index surgery and 1 dislocation needed to be surgically reduced. A total of 8 dislocations occurred (3.4% patients) and were treated by closed reduction.

Since the beginning of the study 23 hips (9.9%) underwent revision of the implants, 13 were isolated cup revisions, including 7 for loosening and 6 for isolated polyethylene wear, 3 more hips had revision of both components for aseptic loosening at 21.4, 15.5 and 20.1 years, respectively. The 7 remaining hips were revised for deep infections with a 2-stage procedure for 6 hips and for chronic instability for 1 hip. Taking revision for any reason as an endpoint, survivorship was 77.7% at 20 years follow-up (95% confidence interval, CI 72.4–83; patients at risk 76). Taking stem revision for aseptic loosening as an endpoint, survivorship was 96.8% at 20 years (95%

CI, 95.1–98.5; patients at risk 76) and 94.5% at 25 years (91.7–97.3, patients at risk 12) (■ Fig. 5).

Group 2: DDH grades III and IV

The mean HHS of the 23 patients (26 hips) increased significantly from preoperative to the most recent follow-up examination to a mean of 82 (48–96) ($p < 0.0001$). The mean LLD was 7 mm (0–17 mm). There were 2 cases of (7.7%) transient nerve palsy (1 sciatic and 1 femoral) which resolved completely at 18 and 11 months, respectively. Of the patients two (8.7%) had recurrent hip dislocations treated by cup revision, one hip (3.8%) had a symptomatic greater trochanter nonunion, which required an open reduction and internal fixation. All the acetabular components were located in the true acetabulum without detectable migration.

The radiographic analysis at the last follow-up showed a nonprogressive radiolucent line around the acetabular component in 1 hip (3.8%). An asymptomatic femoral osteolysis was present in two hips (7.7%) in zone I according to Gruen. Heterotopic ossifications were observed in one hip (3.8%). No pronounced resorption was noted around the femoral components according to Engh and Bobyn [13]. A revision was needed in 6 hips (23.1%): in addition to the 2 early cup revisions for instability mentioned pre-

viously and 1 cup was revised for aseptic loosening at 95 months. In 3 hips (11.5%) the stem was revised: 1 for a Vancouver B2 fracture (acute trauma) and 2 (7.7%) for aseptic loosening at 111 and 161 months, respectively. In 1 hip (3.8%) the liner was changed due to symptomatic wear at 132 months.

Kaplan-Meier survivorship analysis at 15 years of the femoral component considering revision for aseptic loosening as the end point was 87.5% (95% CI 76.5–99.1) (■ Fig. 6). For the acetabular implant considering aseptic loosening as the end point, survivorship was 96.1% (95% CI 92.7–99.9). Survivorship analysis at 15 years for both implants was 72.6% (95% CI 45.3–99.9) regarding any reason as the end point. The number of hips at risk for revision was 10 at 15 years.

Discussion

The 20-year survival rate of custom-made cementless femoral stems in a specific population of young active patients reported in the present study is encouraging, as well as the good functional outcome. This population has an increased life expectancy and an increased functional demand requiring after THA, full range of motion, quick and complete return to physical activity, long-term bone implant fixation and limited polyethylene wear and osteolysis.

A few studies have reported long-term survivorship of cementless stems in patients younger than 50 years, as confirmed by De Kam et al. [11] in their descriptive literature review. Muirhead-Allwood et al. [28] described the results after 10–17 years of a series of 112 computer-assisted designed cementless components with a 97.3% (95% CI 95–99%) survivorship and no revision for failure of the femoral component. In 2015, Swarup et al. [35] reported a 10-year survival rate of 85% for standards implants in THA performed in young patients with juvenile idiopathic arthritis and there was no significant difference between cemented and uncemented implants or between standard and custom stems.

Del Piccolo et al. [12] also reported that both short cementless stems and conventional cementless stems were able to provide stable fixation and good results in patients under 50 years at less than 6 years of follow-up. In an *in vitro* study Götze et al. [18] showed that an individualized custom stem fit into the endosteal cortical bone decreased micromotion. Avoiding the use of distal canal filing stems in any type of femoral anatomy frequently related to osteoarthritis affecting young patients, while preserving the cancellous bone during intramedullary preparation may represent an important advantage in cases of revision 20 years later for a population still very active, as demonstrated in the present study.

Extramedullary anatomy can be also corrected regarding 3D FO, which includes anteversion and leg length discrepancies. This facilitates surgery avoiding an additional femoral osteotomy or the use of metaphyseal modularity, reducing the potential for metallic wear debris. The restoration of optimal 3D offset has been shown to play a significant role in peri-articular muscle function and range of motion, 2 factors of great importance for an active population [26]. In this study, clinical and functional scores remained excellent at nearly 20 years of follow-up which compares favorably with studies looking at clinical outcomes after THA in young patients.

The second analysis describing a method using a 1-stage surgical technique without subtrochanteric shortening or

rotational osteotomy (STO) in grade III and IV DDH, has shown that all the acetabular components were located in the true acetabulum without detectable migration and a 96.1% cup survival at 15 years of follow-up. The custom stem used in this series of THA for high hip dislocation provides anatomical fit and 3D neck correction for anticipating surgical difficulties found in this etiology related to proximal femoral anatomy with limited neurological complications.

Anatomic socket placement can make hip reduction difficult and reduction may require considerable limb lengthening associated with increased risk of neurological injury. Therefore, femoral shortening has been proposed to facilitate reduction and protect the sciatic and femoral nerves. It is a one-stage technique, using the femoral component for intramedullary stabilization that also allows correction of a severe anteversion of the femoral neck; however, the procedure remains challenging as incongruences may appear between the proximal and distal canal diameters after shortening osteotomy leading to difficulties for achieving a secure fixation; these difficulties might increase the risk of delayed union or nonunion of the osteotomy. Mutlu et al. [29] reported in Crowe III and IV patients either 18.6% nonunion or 20.9% delayed union depending on the type of cementless stem used. Using cementless stems, weight bearing is usually carefully increased depending on the consolidation of the osteotomy site starting at 6 weeks and fully completed at 12 weeks according to several authors [15, 40]. In the present series without femoral osteotomy, patients were allowed to walk with partial weight bearing at day 3 with the help of 2 crutches and full weight bearing was normally applied after 3 weeks if a GTO was performed. Additional complications related to the procedure have been described as nerve palsy, intraoperative femoral fracture and dislocation. Mu et al. [27] using cementless Zweymüller THA with STO in 71 Crowe IV patients mentioned 1 case of complete and 7 cases of transient nerve palsy, 1 cup loosening, 4 polyethylene wear and 1 cup breakage, 1 dislocation, and 20 intraoperative

fractures. In the present series using custom stems, no intraoperative fractures were found, probably in relation with the adaptation between the stem and the proximal modified anatomy often found in such an etiology; however, the major concern described with the shortening osteotomy technique remains the residual postoperative LLD especially if the DDH is unilateral. The average 7mm (0–17mm) postoperative mean LLD reported in the present series using a custom femoral stem is close to the 6 mm (0–20 mm) reported by Ollivier et al. [30] but compares favorably with the other series associating a shortening osteotomy and reporting average LLD from 12 to 14 mm with maximum values ranging from 0 to 60 mm.

Long-term results of THA for high DDH with shortening osteotomy showed heterogeneous results. Eskelinen et al. [15] followed up 64 hips and reported a 10-year survival rate of 98.4% for the stem and 94.9% for the porous-coated cup, but 8 of the 9 threaded cups were revised. Ollivier et al. [30] reviewed 28 hips (24 cementless, 4 cementless modular stem and cementless cup) with a mean follow-up of 10 years and reported a 10-year survivorship of the components free of revision of 82%. These results were finally similar to those observed in this study.

This study has some limitations. First, it is a retrospective monocentric study without a control group, but custom THA was a relatively uncommon procedure in the early 1990s. Second, the X-ray analysis is limited to 125 hips out of 232 for the young patient group, mainly because some patients were lost to follow-up. For these patients only the functional patterns and the survival rate of the femoral components could be studied. Nevertheless, the radiographical study of this series remains relevant since the initial cohort was important. Third, a small number of patients were included in the DDH III and IV group, but this an uncommon pathology and this size is similar to the other series of literature. Finally, the extra cost of the custom THA is approximately 30% more than a THA using a conventional cementless stem; however, there are some cost savings because there is

a reduced need for keeping stockroom shelves of various sized prostheses, their associated hire/purchase costs, and specific equipment for implantation of each stem.

Conclusion

Custom-made femoral cementless stem implants offer good functional outcome and long-term survival in two specific populations of patients undergoing THA: patients under 50 years old with a high life expectation and patients with high grade of DDH.

Corresponding address



Jean-Noel Argenson, MD, PhD
Institute for Locomotion,
Department of Orthopedics and
Traumatology,
St. Marguerite Hospital
270 Boulevard Sainte
Marguerite, BP 29
13274 Marseille, France
jean-noel.argenson@ap-hm.fr

Compliance with ethical guidelines

Conflict of interest. J.-N. Argenson is a consultant for Zimmer and Symbios. M. Ollivier is a consultant for Stryker and New-Clip Technics. X. Flecher is a consultant for Zimmer and Symbios. C. Jacquet, C. Pioger and M. Fabre-Aubrespy declare that they have no competing interests.

Ethical standards. All studies performed were in accordance with the ethical standards indicated in each case. The local ethics committee approved the study protocol prior to the investigation.

References

- Amstutz HC, Sakai DN (1975) Total joint replacement for ankylosed hips. Indications, technique, and preliminary results. *J Bone Joint Surg Am* 57:619–625
- Argenson J-N, Ryembault E, Flecher X et al (2005) Three-dimensional anatomy of the hip in osteoarthritis after developmental dysplasia. *J Bone Joint Surg Br* 87:1192–1196. <https://doi.org/10.1302/0301-620X.87B9.15928>
- Asayama I, Chamnongkitch S, Simpson KJ et al (2005) Reconstructed hip joint position and abductor muscle strength after total hip arthroplasty. *J Arthroplasty* 20:414–420. <https://doi.org/10.1016/j.arth.2004.01.016>
- Beaulé PE, Dorey FJ, Hoke R et al (2006) The value of patient activity level in the outcome of total hip arthroplasty. *J Arthroplasty* 21:547–552. <https://doi.org/10.1016/j.arth.2005.09.004>
- Binazzi R (2015) Two-stage progressive femoral lowering followed by cementless total hip arthroplasty for treating Crowe IV-Hartofilakidis type 3 developmental dysplasia of the hip. *J Arthroplasty* 30:790–796. <https://doi.org/10.1016/j.arth.2014.12.019>
- Bugbee WD, Culpepper WJ, Engh CA, Engh CA (1997) Long-term clinical consequences of stress-shielding after total hip arthroplasty without cement. *J Bone Joint Surg Am* 79:1007–1012. <https://doi.org/10.2106/00004623-199707000-00006>
- Capello WN, D'Antonio JA, Feinberg JR, Manley MT (2003) Ten-year results with hydroxyapatite-coated total hip femoral components in patients less than fifty years old. A concise follow-up of a previous report. *J Bone Joint Surg Am* 85:885–889. <https://doi.org/10.2106/00004623-200305000-00017>
- Charnley J, Feagin JA (1973) Low-friction arthroplasty in congenital subluxation of the hip. *Clin Orthop.* <https://doi.org/10.1097/00003086-197303000-00015>
- Crowe JF, Mani VJ, Ranawat CS (1979) Total hip replacement in congenital dislocation and dysplasia of the hip. *J Bone Joint Surg Am* 61:15–23
- D'aubigne RM, Postel M (1954) Functional results of hip arthroplasty with acrylic prosthesis. *J Bone Joint Surg Am* 36-A:451–475
- De Kam DCJ, Busch VJF, Veth RPH, Schreurs BW (2011) Total hip arthroplasties in young patients under 50 years: limited evidence for current trends. A descriptive literature review. *Hip Int* 21:518–525. <https://doi.org/10.5301/HIP.2011.8641>
- Del Piccolo N, Carubbi C, Mazzotta A et al (2016) Return to sports activity with short stems or standard stems in total hip arthroplasty in patients less than 50 years old. *Hip Int* 26(Suppl 1):48–51. <https://doi.org/10.5301/hipint.5000404>
- Engh CA, Bobyn JD (1988) The influence of stem size and extent of porous coating on femoral bone resorption after primary cementless hip arthroplasty. *Clin Orthop* 231:7–28
- Eskelinen A, Remes V, Helenius I et al (2005) Total hip arthroplasty for primary osteoarthritis in younger patients in the Finnish arthroplasty register. 4,661 primary replacements followed for 0–22 years. *Acta Orthop* 76:28–41. <https://doi.org/10.1080/00016470510030292>
- Eskelinen A, Remes V, Ylinen P et al (2009) Cementless total hip arthroplasty in patients with severely dysplastic hips and a previous Schanz osteotomy of the femur: techniques, pitfalls, and long-term outcome. *Acta Orthop* 80:263–269. <https://doi.org/10.3109/17453670902967273>
- Flecher X, Argenson JN, Parratte S et al (2006) Custom cementless stem for osteoarthritis following developmental hip dysplasia. *Rev Chir Orthop Reparatrice Appar Mot* 92:332–342. [https://doi.org/10.1016/s0035-1040\(06\)75763-4](https://doi.org/10.1016/s0035-1040(06)75763-4)
- Flecher X, Parratte S, Aubaniac J-M, Argenson J-N (2007) Three-dimensional custom-designed cementless femoral stem for osteoarthritis secondary to congenital dislocation of the hip. *J Bone Joint Surg Br* 89:1586–1591. <https://doi.org/10.1302/0301-620X.89B12.19252>
- Götze C, Steens W, Vieth V et al (2002) Primary stability in cementless femoral stems: custom-made versus conventional femoral prosthesis. *Clin Biomech* 17:267–273. [https://doi.org/10.1016/s0268-0033\(02\)00012-8](https://doi.org/10.1016/s0268-0033(02)00012-8)
- Gruen TA, McNeice GM, Amstutz HC (1979) „Modes of failure“ of cemented stem-type femoral components: a radiographic analysis of loosening. *Clin Orthop* 141:17–27
- Harris WH (1969) Traumatic arthritis of the hip after dislocation and acetabular fractures: treatment by mold arthroplasty. An end-result study using a new method of result evaluation. *J Bone Joint Surg Am* 51:737–755
- Hartofilakidis G, Karachalios T, Georgiades G, Kourlaba G (2011) Total hip arthroplasty in patients with high dislocation: a concise follow-up, at a minimum of fifteen years, of previous reports. *J Bone Joint Surg Am* 93:1614–1618. <https://doi.org/10.2106/JBJS.J.00875>
- Kwon Y-M, Khormae S, Liow MHL et al (2016) Asymptomatic pseudotumors in patients with taper corrosion of a dual-taper modular femoral stem: MARS-MRI and metal ion study. *J Bone Joint Surg Am* 98:1735–1740. <https://doi.org/10.2106/JBJS.15.01325>
- Lee SJ, Yoo JJ, Kim HJ (2017) Cementless total hip arthroplasty involving trochanteric osteotomy without subtrocchanteric shortening for high hip dislocation. *Clin Orthop Surg* 9:19–28. <https://doi.org/10.4055/cios.2017.9.1.19>
- Maar DC, Mont MA, Krackow KA, Hungerford DS (1992) Long-term (twelve to eighteen-year) follow-up of cemented total hip replacements in patients who were less than fifty years old. A follow-up note. *J Bone Joint Surg Am* 74:307–308
- Massin P, Geais L, Astoin E et al (2000) The anatomic basis for the concept of lateralized femoral stems: a frontal plane radiographic study of the proximal femur. *J Arthroplasty* 15:93–101
- McGrory BJ, Morrey BF, Cahalan TD et al (1995) Effect of femoral offset on range of motion and abductor muscle strength after total hip arthroplasty. *J Bone Joint Surg Br* 77:865–869
- Mu W, Yang D, Xu B et al (2016) Midterm outcome of cementless total hip arthroplasty in Crowe IV-Hartofilakidis type III developmental dysplasia of the hip. *J Arthroplasty* 31:668–675. <https://doi.org/10.1016/j.arth.2015.10.011>
- Muirhead-Allwood SK, Sandiford N, Skinner JA et al (2010) Uncemented custom computer-assisted design and manufacture of hydroxyapatite-coated femoral components: survival at 10 to 17 years. *J Bone Joint Surg Br* 92:1079–1084. <https://doi.org/10.1302/0301-620X.92B8.23123>
- Mutlu T, Çiçek H, Yalçın N et al (2016) How do different designs of femoral stem affect total hip arthroplasty applied to Crowe type III and type IV dysplastic hips. *Hip Int* 26:374–379. <https://doi.org/10.5301/hipint.5000360>
- Ollivier M, Abdel MP, Krych AJ et al (2016) Long-term results of total hip arthroplasty with shortening subtrocchanteric osteotomy in Crowe IV developmental dysplasia. *J Arthroplasty* 31:1756–1760. <https://doi.org/10.1016/j.arth.2016.01.049>
- Paavilainen T, Hoikka V, Paavolainen P (1993) Cementless total hip arthroplasty for congenitally dislocated or dysplastic hips. Technique for replacement with a straight femoral component. *Clin Orthop* 297:71–81
- Sariali E, Klouche S, Mamoudy P (2014) Ceramic-on-ceramic total hip arthroplasty: is squeaking related to an inaccurate three-dimensional hip anatomy reconstruction? *Orthop Traumatol Surg Res* 100:437–440. <https://doi.org/10.1016/j.otsr.2014.01.009>
- Sariali E, Klouche S, Mouttet A, Pascal-Mous-sellard H (2014) The effect of femoral offset

-
- modification on gait after total hip arthroplasty. *Acta Orthop* 85:123–127. <https://doi.org/10.3109/17453674.2014.889980>
34. Sariali E, Mouttet A, Pasquier G, Durante E (2009) Three-dimensional hip anatomy in osteoarthritis. Analysis of the femoral offset. *J Arthroplasty* 24:990–997. <https://doi.org/10.1016/j.arth.2008.04.031>
 35. Swarup I, Lee Y, Christoph El et al (2015) Implant survival and patient-reported outcomes after total hip arthroplasty in young patients with juvenile idiopathic arthritis. *J Arthroplasty* 30:398–402. <https://doi.org/10.1016/j.arth.2014.09.018>
 36. Tsiampas DT, Pakos EE, Georgiadis GC, Xenakis TA (2016) Custom-made femoral implants in total hip arthroplasty due to congenital disease of the hip: a review. *Hip Int* 26:209–214. <https://doi.org/10.5301/hipint.5000355>
 37. Wang D, Li L-L, Wang H-Y et al (2017) Long-term results of cementless total hip arthroplasty with subtrochanteric shortening osteotomy in Crowe type IV developmental dysplasia. *J Arthroplasty* 32:1211–1219. <https://doi.org/10.1016/j.arth.2016.11.005>
 38. Yoon PW, Kim JI, Kim DO et al (2013) Cementless total hip arthroplasty for patients with Crowe type III or IV developmental dysplasia of the hip: two-stage total hip arthroplasty following skeletal traction after soft tissue release for irreducible hips. *Clin Orthop Surg* 5:167–173. <https://doi.org/10.4055/cios.2013.5.3.167>
 39. Zenz P, Pospisil C, Fertschak W, Schwägerl W (1995) 10 years of cementless implantation of total hip endoprosthesis using Zweymüller's stem. *Z Orthop Ihre Grenzgeb* 133:558–561. <https://doi.org/10.1055/s-2008-1039939>
 40. Zhu J, Shen C, Chen X et al (2015) Total hip arthroplasty with a non-modular conical stem and transverse subtrochanteric osteotomy in treatment of high dislocated hips. *J Arthroplasty* 30:611–614. <https://doi.org/10.1016/j.arth.2014.11.002>