



**HAL**  
open science

## Gynecologic cancers in pregnancy: guidelines based on a third international consensus meeting

F. Amant, P. Berveiller, I.A. Boere, E. Cardonick, R. Fruscio, M. Fumagalli, M.J. Halaska, A. Hasenburg, A.L.V. Johansson, M. Lambertini, et al.

► **To cite this version:**

F. Amant, P. Berveiller, I.A. Boere, E. Cardonick, R. Fruscio, et al.. Gynecologic cancers in pregnancy: guidelines based on a third international consensus meeting. *Annals of Oncology*, 2019, 30 (10), pp.1601-1612. 10.1093/annonc/mdz228 . hal-03170891

**HAL Id: hal-03170891**

**<https://hal.science/hal-03170891v1>**

Submitted on 7 Jun 2023

**HAL** is a multi-disciplinary open access archive for the deposit and dissemination of scientific research documents, whether they are published or not. The documents may come from teaching and research institutions in France or abroad, or from public or private research centers.

L'archive ouverte pluridisciplinaire **HAL**, est destinée au dépôt et à la diffusion de documents scientifiques de niveau recherche, publiés ou non, émanant des établissements d'enseignement et de recherche français ou étrangers, des laboratoires publics ou privés.



Distributed under a Creative Commons Attribution - NonCommercial - NoDerivatives 4.0 International License

## REVIEW

# Gynecologic cancers in pregnancy: guidelines based on a third international consensus meeting

F. Amant<sup>1,2\*</sup>, P. Berveiller<sup>3</sup>, I. A. Boere<sup>4</sup>, E. Cardonick<sup>5</sup>, R. Fruscio<sup>6</sup>, M. Fumagalli<sup>7,8</sup>, M. J. Halaska<sup>9</sup>, A. Hasenburger<sup>10</sup>, A. L. V. Johansson<sup>11</sup>, M. Lambertini<sup>12,13</sup>, C. A. R. Lok<sup>1</sup>, C. Maggen<sup>2</sup>, P. Morice<sup>14</sup>, F. Peccatori<sup>15</sup>, P. Poortmans<sup>16</sup>, K. Van Calsteren<sup>17</sup>, T. Vandenbroucke<sup>2</sup>, M. van Gerwen<sup>1,18</sup>, M. van den Heuvel-Eibrink<sup>18</sup>, F. Zagouri<sup>19</sup> & I. Zapardiel<sup>20</sup>

<sup>1</sup>Center for Gynecologic Oncology Amsterdam, Netherlands Cancer Institute/Antoni van Leeuwenhoek and Amsterdam University Medical Centers, the Netherlands; <sup>2</sup>Department of Oncology, KU Leuven, Leuven, Belgium; <sup>3</sup>Department of Obstetrics and Gynecology, Centre Hospitalier de Poissy-Saint-Germain-en-Laye, Poissy, France; <sup>4</sup>Department of Medical Oncology, Erasmus MC Cancer Institute, Erasmus University Medical Center, Rotterdam, the Netherlands; <sup>5</sup>Department of Obstetrics and Gynecology, Cooper University Health Care, Camden, USA; <sup>6</sup>Clinic of Obstetrics and Gynecology, University of Milan Bicocca, San Gerardo Hospital, Monza; <sup>7</sup>Foundation IRCCS Ca' Granda Ospedale Maggiore Policlinico, Neonatal Intensive Care Unit, Milan; <sup>8</sup>Department of Clinical Sciences and Community Health, University of Milan, Milan, Italy; <sup>9</sup>Department of Obstetrics and Gynaecology, 3rd Medical Faculty, Charles University and Faculty Hospital Kralovske Vinohrady, Prague, Czech Republic; <sup>10</sup>Department of Obstetrics and Gynecology, Mainz University Medical Center, Mainz, Germany; <sup>11</sup>Department of Medical Epidemiology and Biostatistics, Karolinska Institutet, Stockholm, Sweden; <sup>12</sup>Department of Medical Oncology, IRCCS Policlinico San Martino Hospital, Genova; <sup>13</sup>Department of Internal Medicine and Medical Specialties (DiMI), School of Medicine, University of Genova, Genova, Italy; <sup>14</sup>Department of Gynecologic Surgery, Institute de Cancérologie Gustave Roussy, Villejuif, France; <sup>15</sup>Department of Gynecologic Oncology, European Institute of Oncology IRCCS, Milan, Italy; <sup>16</sup>Department of Radiation Oncology, Institut Curie and Paris Sciences & Lettres - PSL University, Paris, France; <sup>17</sup>Department of Development and Regeneration, University Hospitals Leuven, Leuven, Belgium; <sup>18</sup>Princess Máxima Center for Pediatric Oncology, Utrecht, the Netherlands; <sup>19</sup>Department of Clinical Therapeutics, Alexandra Hospital, Medical School, University of Athens, Athens, Greece; <sup>20</sup>Department of Gynecologic Oncology, La Paz University Hospital, Madrid, Spain

\*Correspondence to: Prof. Frédéric Amant, Department of Oncology, KU Leuven - University of Leuven, Herestraat 49, Leuven 3000, Belgium. Tel: +32-16344273; E-mail: Frederic.amant@uzleuven.be

We aimed to provide comprehensive protocols and promote effective management of pregnant women with gynecological cancers. New insights and more experience have been gained since the previous guidelines were published in 2014. Members of the International Network on Cancer, Infertility and Pregnancy (INCIPI), in collaboration with other international experts, reviewed existing literature on their respective areas of expertise. Summaries were subsequently merged into a manuscript that served as a basis for discussion during the consensus meeting. Treatment of gynecological cancers during pregnancy is attainable if management is achieved by collaboration of a multidisciplinary team of health care providers. This allows further optimization of maternal treatment, while considering fetal development and providing psychological support and long-term follow-up of the infants. Nonionizing imaging procedures are preferred diagnostic procedures, but limited ionizing imaging methods can be allowed if indispensable for treatment plans. In contrast to other cancers, standard surgery for gynecological cancers often needs to be adapted according to cancer type and gestational age. Most standard regimens of chemotherapy can be administered after 14 weeks gestational age but are not recommended beyond 35 weeks. C-section is recommended for most cervical and vulvar cancers, whereas vaginal delivery is allowed in most ovarian cancers. Breast-feeding should be avoided with ongoing chemotherapeutic, endocrine or targeted treatment. More studies that focus on the long-term toxic effects of gynecologic cancer treatments are needed to provide a full understanding of their fetal impact. In particular, data on targeted therapies that are becoming standard of care in certain gynecological malignancies is still limited. Furthermore, more studies aimed at the definition of the exact prognosis of patients after antenatal cancer treatment are warranted. Participation in existing registries ([www.cancerinpregnancy.org](http://www.cancerinpregnancy.org)) and the creation of national tumor boards with multidisciplinary teams of care providers (supplementary Box S1, available at *Annals of Oncology* online) is encouraged.

**Key words:** cancer, pregnancy, gynecologic, chemotherapy, offspring, cognitive

## Introduction

The lack of knowledge and the rarity of cancer in pregnancy spearheaded the creation of the International Network on Cancer, Infertility and Pregnancy (INCIP) that aims to contribute to the advancement of cancer management for pregnant women and facilitate large-scale studies. INCIP has grown remarkably in the past years and now consists of 62 medical centers in 25 countries, which have registered over 2000 patients with a cancer diagnosis during pregnancy. Since inception of the registration in 2005, our knowledge on how to manage gynecological cancers has increased tremendously. During this time, two international consensus meetings [1, 2] with leading experts in the field were set up to create comprehensive protocols and to provide timely and effective guidance for pregnant cancer patients and healthcare providers. Despite all these efforts, however, many important questions are still not answered by evidence-based information. Therefore, the dissemination of experts' knowledge remains of utmost importance. The aim of this third consensus meeting was to disclose new evidence-based information and expert knowledge, to revise and strengthen the recommendations of the previous guidelines published in 2009 [1] and 2014 [2], to recommend appropriate techniques and to promote effective management of pregnant women with gynecological cancers and their offspring. Details of the consensus meeting are depicted in [supplementary Appendix S1](#), available at *Annals of Oncology* online.

## Epidemiology

The rare combination of cancer and pregnancy is expected to rise, as already demonstrated by population-based studies [3–5]. This will be most significant in countries where women tend to delay childbearing and where noninvasive prenatal testing (NIPT), that may reveal asymptomatic malignancies [6], is easily available or reimbursed by insurance.

Estimation of incidence of all antenatal cancers, including gynecological cancers is, however, a challenging task. This is mostly attributable to the fact that in most countries, obstetrical and oncological registries are not linked. Nationwide studies that combine obstetrical and oncological registries, to estimate the incidence of cancer during pregnancy, often lack information on miscarriage or termination of pregnancy, which can possibly result in an underestimation of the incidence. Furthermore, differences in the denominator used (pregnancies or live births) may lead to variation in reported incidence rates among studies. We present in Table 1 (and in [supplementary Tables S1 and S2](#), available at *Annals of Oncology* online) the incidences of cervical and ovarian cancer based on recent data [3–5, 7–12]. The relative risk of these malignancies is lower during pregnancy compared with nonpregnant women, indicating either delay in diagnosis/detection, a true lower risk or a healthy mother effect. Solid data on how pregnancy affects the outcome of gynecological cancers is missing, although a few reports have shown that both cervical and ovarian cancer during pregnancy might not be associated with a poorer prognosis [13, 14]. The gestational incidence of other malignancies of the female genital organs is low (Table 1) [4, 8, 15–23].

## Imaging and nuclear medicine during pregnancy

Imaging procedures in cancer diverge between pregnant and nonpregnant women, mainly due to the risk of teratogenicity and fetal death. The threshold for a significant risk for fetal damage is set at 100 mGy [24]. X-rays with proper abdominal shielding are allowed as they carry a negligible fetal radiation exposure of <0.1 mGy.

### Ionizing imaging procedures

Ionizing imaging procedures should be avoided, if possible, as radiation could affect the viability and development of the fetus [25]. Although computerized tomography (CT) scan is not recommended, it could be carried out only when strictly necessary, with intravenous iodinated contrast, as there is no trustworthy literature about its safety. In these cases, fetal exposure will depend on proper use of abdominal shielding, tumor location and quality and settings of the CT instrumentation. CT can also be considered as second choice to magnetic resonance imaging (MRI).

Concerning nuclear medicine procedures, adverse effects on the fetus differ by the type of radiotracer, the administered dose and the weight of the fetus [26]. During fluorine-18-fluorodeoxyglucose positron emission tomography/CT (<sup>18</sup>FDG-PET/CT) scan proper hydration and a bladder catheter should be used to reduce fetal radiation exposure. Although sentinel node mapping using radioactive materials is contraindicated for cervical, it is not for vulvar cancer (see below). The use of sentinel mapping using indocyanine green is still experimental, and published case reports are insufficient to make any recommendation [27]. Thus, in summary, ionizing radiation techniques may be carried out only after extensive discussion about indication and clinical relevance, in individual cases, and under strict and specific precautions.

### Nonionizing imaging procedures

Nonionizing imaging procedures, such as ultrasonography and MRI are preferred and can be used to determine tumor size, extent of invasion and lymph node involvement in any trimester of pregnancy. A recent study found that although gadolinium-enhanced MRI at any gestational age was not associated with a greater risk of congenital anomalies, it was associated with increased risk of a broad set of rheumatologic, inflammatory or infiltrative skin conditions in the offspring and risk of stillbirth or neonatal death [26]. Thus, the use of gadolinium for imaging in MRI is not recommended during pregnancy. A recent study has shown that whole-body diffusion-weighted MRI (WB-DWI/MRI) could replace <sup>18</sup>F-FDG-PET/CT as it presents equal efficacy in the detection of nodal and distant metastasis, including bone metastasis, both in solid tumors and lymphomas [28]. It also showed no adverse effects to the fetus. Therefore, WB-DWI/MRI could be used for staging and for tumor response evaluation in pregnant women with cancer [29]. One has to bear in mind that newer MRI scanners use significantly stronger magnets, leading to fetal exposure to increasing amount of tesla and research is mostly based on older MRI data. So, more studies on the consequences on pregnancy of new developments in imaging

**Table 1. Incidences gynecological cancers during pregnancy**

Malignancy	Incidence (cases/pregnancies)	Comments	References
Cervical cancer	1.4–4.6 per 100 000	The variation in incidence during pregnancy is likely to reflect differences in underlying cervical incidence rates across population and screening programs.	[3–5, 7–12]
Ovarian cancer	0.2–3.8 per 100 000		[11, 12]
Ovarian masses with low malignant potential	1.1–2.4 per 100 000		[11, 12]
Vulvar cancer	0.1 per 0.5 in 100 000	Rare, only 38 case reports in literature.	[4, 8, 15–20]
Vaginal cancer	0.1 per 0.5 in 100 000	Rare, only 12 case reports in literature.	[4, 8, 15–20]

Numbers are based on recent data. Vulvar cancer during pregnancy is rare, reflecting the general low incidence of the disease before the age of 40–45 years. Also, endometrial cancer is very rare among premenopausal women and to our knowledge only 39 cases in association with pregnancy have been published, usually diagnosed after curettage for miscarriage. As endometrial cancer is mostly diagnosed after delivery or miscarriage, standard treatment can then be applied. Adapted procedures for the other gynecological cancers are described in the text.

techniques are needed. Pineapple juice is used as a negative contrast for MRI (WB-DWI/MRI), allowing investigation of adhesions, peritoneal/intra-abdominal lesions; it is most frequently used in ovarian cancer. Pineapple juice is a very fitting contrast agent for cancer in pregnancy, since it helps patient comfort without compromising fetal health [30].

## Surgery

Surgery is the cornerstone in the treatment of most gynecologic cancers and can be carried out safely during pregnancy. Postponing a procedure until after delivery can be considered in selected cases.

### Surgery protocol

Physiological changes in pregnancy have consequences for preoperative, perioperative and postoperative care. Local or regional anesthesia are preferred. Although surgery is possible in all trimesters [31], it is preferably carried out in the (early) second trimester when the risk of miscarriage is decreased and the size of the uterus still allows a certain degree of access. Although a 'left lateral tilt' for elective cesarean delivery under spinal anesthesia appeared to have no effect on neonatal acid-base status, more vaso-active medication are needed to maintain hemodynamic stability when patients were not in left lateral tilt position for this short procedure [32]. Therefore, for oncologic procedures, the left lateral tilt position is still advised because of operating time and the use of general anesthesia. Right lateral tilt can be used if this leads to improved exposure.

Laparoscopy in pregnancy is feasible, but depends on the gestational age, surgeon's experience, type of procedure and the organs of interest. A recent study, comparing pregnant women undergoing laparotomy versus laparoscopy, found that in pregnancy laparoscopy was associated with less fetal adverse effects, shorter operative times and shorter hospital stays [33]. In addition, patients undergoing laparotomy for an adnexal mass in pregnancy experienced significantly more preterm contractions than women undergoing laparoscopy [34]. However, it is important

to note that laparoscopic surgery can cause hypercapnia, perforation of the uterus, and reduced blood flow due to increased abdominal pressure and use of carbon dioxide. Thus, the recommendations for surgery during pregnancy are a laparoscopic procedure (if possible), of no longer than 90–120 min, with low intra-abdominal pressure of 10–13 mmHg, open introduction and an experienced surgeon [35–37].

During surgery, careful preparation and adequate monitoring of the maternal condition is mandatory for maternal and fetal well-being. Risks of surgery in a pregnant patient include preterm delivery, miscarriage and fetal distress. Physiologic hemodynamic changes in pregnancy have consequences for perioperative monitoring [38]. The same precautions of anesthesia as in nonpregnant women should be taken. Pregnancy-associated gastroesophageal reflux increases the risk of aspiration. Maternal hypotension causes a reduced blood flow to the placenta and fetal hypoxia will become apparent shortly after hemorrhage and hypovolemia. Fetal distress can occur before maternal deterioration [38]. Precautions are especially important since cardiocotography monitoring during pelvic surgery is impossible.

Perioperative medication may result in a significant transplacental transfer depending on lipophilicity, degree of ionization, molecular weight and protein-binding (supplementary Table S3, available at *Annals of Oncology* online).

### Ovarian cancer

Diagnostic procedures in pregnant patients with ovarian cancer are explained in supplementary Box S2, available at *Annals of Oncology* online. Patients with apparent early stage malignant disease should be surgically treated and staged based on the histopathology report (low malignant potential, invasive or germ cell), of either definitive histology or by frozen section.

Staging procedures during pregnancy may include infracolic omentectomy, appendectomy, pelvic-peritoneal biopsies and lymph nodes dissection. A general recommendation is that, if the pelvic peritoneum and the pouch of Douglas cannot be reliably examined during surgery because of the enlarged dimension of the uterus and the limited possibility to manipulate it, restaging

surgery should be planned postpartum. The expert panel believes a threshold to perform an adequate gynecological surgical assessment could be proposed at around 22 weeks of gestation. Based on a low risk of progression to invasive cancer, surgery might be postponed until postpartum if a tumor of low malignant potential is diagnosed during the second or the third trimester.

In cases with advanced stage epithelial ovarian cancer, termination of pregnancy should be considered when the diagnosis is made in the first half of the pregnancy. In patients who are motivated for pregnancy preservation, a biopsy or an adnexectomy should be performed, followed by platinum-based chemotherapy. In these cases, cytoreductive surgery should be planned after delivery, as surgery to define residual disease cannot be carried out during pregnancy (Figures 1 and 2).

## Cervical cancer

### Surgery

Diagnostic procedures in pregnant patients with cervical cancer are explained in supplementary Box S2, available at *Annals of Oncology* online. Lymphadenectomy can be performed by laparotomy or laparoscopy (supplementary Table S4, available at *Annals of Oncology* online). Due to increased feasibility and safety, laparotomy should be reserved for cases beyond the 14–16th weeks of gestation, whereas laparoscopy can often be performed before the 14–16th weeks of gestation. Nodal resection is not recommended after the 22nd week of gestation, since insufficient number of nodes can be retrieved after this gestational age [39].

Several surgical procedures have been described in early stage cervical carcinomas (IA1-IB2, according to the most recent FIGO classification [39]) during pregnancy, such as large conization, simple trachelectomy and radical vaginal/abdominal/laparoscopic trachelectomy. As increasing number of studies in nonpregnant cervical cancer patients demonstrate, that with negative pelvic lymph nodes the risk of parametrial involvement is negligible, there is a growing support for large conization or simple trachelectomy only [40, 41]. Supplementary Table S5, available at *Annals of Oncology* online presents the cases of simple trachelectomy in pregnancy and shows the low number of major complications. Supplementary Table S6, available at *Annals of Oncology* online summarizes radical trachelectomy cases, showing that this procedure results in a high rate of obstetrical and surgical complications and should not be recommended during pregnancy.

### Management

Analysis of prognosis of cervical cancer during pregnancy shows no negative impact of pregnancy on the outcome of patients; therefore, pregnancy-preserving management should be considered initially. Figure 3 summarizes the different treatment options based on stage and gestational age at diagnosis.

**Pregnancy-preserving management.** A cone biopsy may be used to treat stage IA1 tumors without lymphovascular space invasion. For stage IA1 with lymphovascular space invasion, IA2 and IB1, staging lymphadenectomy should be performed as a first step. This can be safely done up to the 22nd week of gestation. After

the 22nd week of gestation, delayed treatment after delivery with regular follow-up could be initiated. Alternatively, neoadjuvant chemotherapy (NACT) could be used to control the disease.

In stage IB2 less than the 22nd week of gestation, two options are available: (i) pelvic lymphadenectomy as a first step followed by either chemotherapy or follow-up, and (ii) NACT and subsequent surgical staging of the disease after downstaging the tumor. In the case of positive nodes (including micro metastases), we recommend termination of pregnancy. However, the panel believes that for those patients who refuse this option, chemotherapy could be considered. In these instances, patients should be informed of the possible negative impact on the prognosis and the lack of available data. Follow-up of IB1, IB2 and IB3 tumors after staging lymphadenectomy has been described in a systematic review of Morice et al. [42], who collected 76 patients with a median follow-up of 37.5 months (mean 16 weeks of delay) and showed excellent oncological outcome. After the 22nd week of gestation, only NACT is an option.

In stage IB3 (according to the new FIGO 2018 classification [39]), the only pregnancy-preserving option is the application of NACT, although its efficiency has only been investigated in a small number of trials, and further research is warranted [43]. The role of staging lymphadenectomy is controversial [44]. Follow-up without therapy in such cases is likely to compromise the prognosis and is thus not recommended.

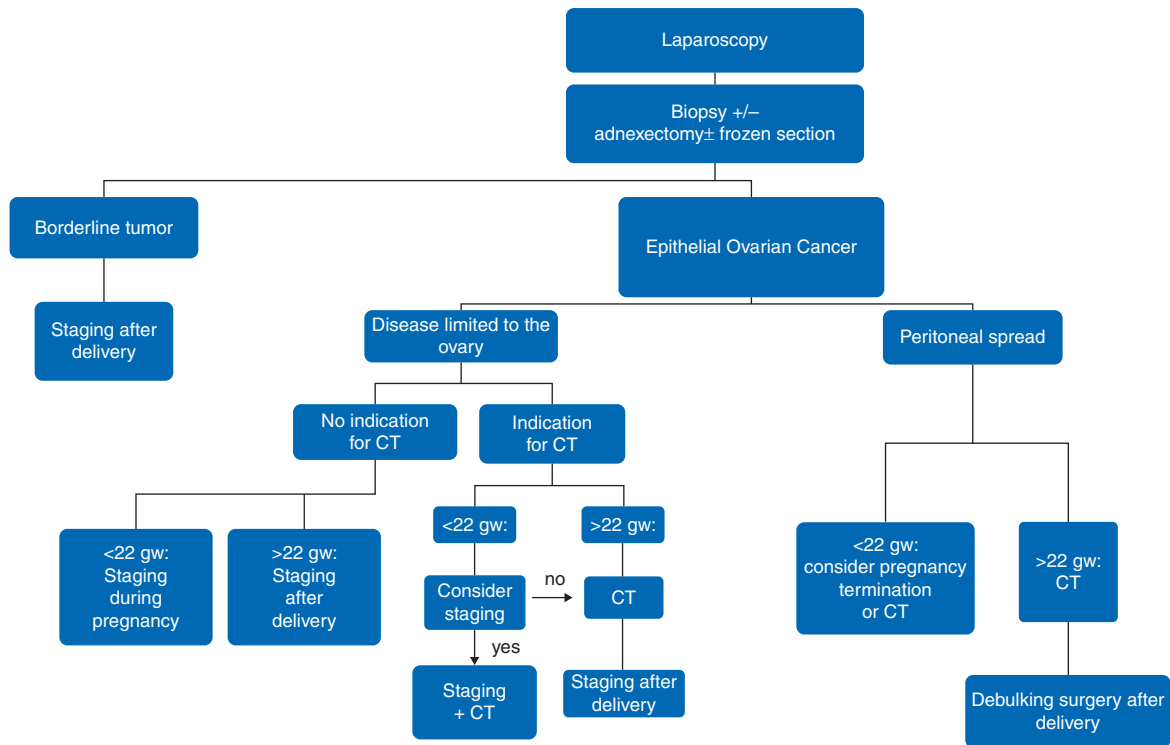
With increasing gestational age, a delay of definitive treatment is more commonly used, though NACT (until the 34–35th week of gestation) will prolong the duration of pregnancy until term delivery.

**Pregnancy nonpreserving management.** Pregnancy nonpreserving management is chosen in advanced disease (stage IIB or higher or lymph node metastases) or in cases when the patient chooses not to preserve her pregnancy (based on local legislation and usually until the 24th week of gestation). Treatment is thus planned without intention to preserve the fetus. In case of an operable disease (IA2-IB2), a radical hysterectomy with fetus in utero (during the first- or early-second trimester) or after hysterectomy (during the late second trimester) can be performed.

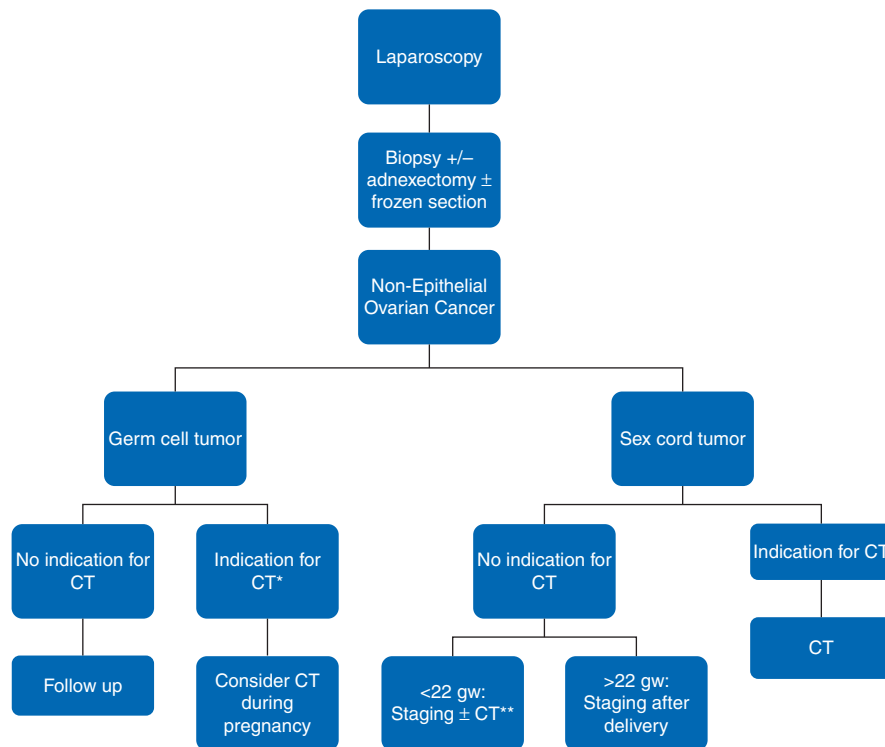
In IB3 and higher stages, during first trimester chemoradiation can be applied with the fetus in utero (the death of the fetus occurs within few days), while during second trimester a hysterectomy as a first step is advised. This reduces the risk of obstetrical complications (bleeding, rupture of the cervix, diffuse intravascular coagulation) and psychological impact on the patient. Alternatively, before chemoradiotherapy is initiated, feticide can be considered for ethical and psychological reasons [45].

### Vulvar cancer

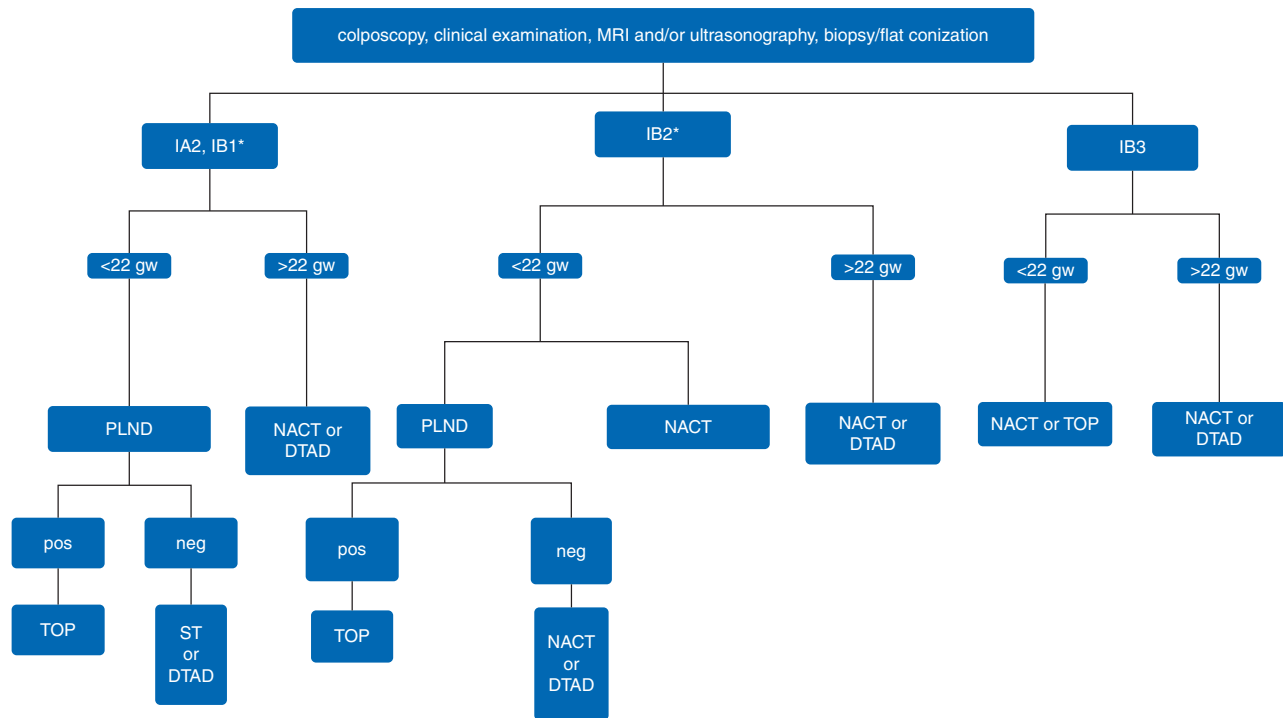
Standard surgical treatment of this very rare condition in pregnancy is radical local excision with unilateral or bilateral lymph node dissection or sentinel node procedure. Fetal exposure to locally injected technetium is small and can be further reduced by using a short treatment protocol, the lowest possible dose and performing the procedure 2 h after injection.  $T_{1/2}$  of technetium is 6 h, so the sooner the procedure is carried out, the less delay has occurred and the smaller the dose that can be used. Because the technetium is captured in the node, there is little systemic



**Figure 1.** Flowchart for management of epithelial OC tumors. Staging refers to surgical staging. CT, chemotherapy; gw, gestational weeks.



**Figure 2.** Flowchart for management of nonepithelial OC tumors. Staging refers to surgical staging. CT, chemotherapy; gw, gestational weeks. \*According to ESMO guidelines and \*\*CT administered according to restaging surgery findings.



**Figure 3.** Flowchart for cervical cancer management during pregnancy. PLND, pelvic lymph node dissection; NACT, neoadjuvant chemotherapy; AC, adjuvant chemotherapy; TOP, termination of pregnancy; ST, simple trachelectomy; DTAD, delayed treatment after delivery. \*FIGO 2018 for cervical cancer is used [39].

exposure. Also, nodal removal reduces exposure. The SPECT CT-scan that is often made in nonpregnant women should be omitted. Also, blue dye should be omitted because of the chance of anaphylaxis. Treatment of patients diagnosed in the late third trimester might be delayed until the postpartum period. Surgical radicality should be aimed for, as vulvar radiotherapy is contraindicated during pregnancy. Increased gestational vulvar blood flow can lead to more perioperative blood loss, which can be reduced by meticulous electrocautery.

Patients with sentinel node metastases require additional inguinal treatment. In the case of nodal involvement after inguino-femoral lymphadenectomy, depending on gestational age, pregnancy is advised to be terminated or delivery to be planned, and postpartum irradiation is subsequently advised. Delay of radiotherapy by 6–8 weeks is within safety limits, based on data from other epithelial cancers [46]. When preoperative examinations suggest inguinal lymph node involvement, the prognosis is less favorable and inguinal radiotherapy to prevent local groin recurrence becomes vital. Immediate treatment is then mandatory, and termination of the pregnancy in the first and second trimester is indicated.

Regarding mode of delivery, in the third trimester a cesarean delivery is performed to prevent vulvar wound dehiscence. In case of smaller wounds that have already healed well, vaginal delivery is an option. NACT to reduce tumor size for locally advanced disease remains experimental.

### Vaginal cancer

Since vaginal cancer occurs primarily in postmenopausal women, only 12 cases of antenatal vaginal cancer have been reported in

literature so far [21]. Depending on the location and tumor size, surgical resection can be done. When surgery is not an option, delay of radio(chemo)therapy or termination of pregnancy can be considered as shown in case reports.

### Systemic treatment

Pregnancy results in physiological changes that may influence the exposure and efficacy of systemic treatments, by influencing their pharmacokinetics with respect to distribution, metabolism and excretion of drugs. Current recommendations suggest dosing chemotherapeutic drugs during pregnancy based on actual pregnancy weight but not on ideal or prepregnancy body weight. These and other recommendations regarding systemic treatment are noted in Table 2.

### Chemotherapy

Chemotherapy is contra-indicated in the first trimester of gestation to avoid interference with organogenesis, as early exposure has been associated with a 10%–20% risk of major malformations [47]. Fetal benefit of treatment delay until the second trimester should be balanced against maternal risk. After 14 weeks of gestation, administration of a number of chemotherapy drugs is feasible, including taxanes, platinum agents, anthracyclines, etoposide and bleomycin. In several studies, the rate of fetal malformations was comparable to the general population, demonstrating the relative safety of chemotherapy beyond the first trimester [48–54]. Table 3 represents the chemotherapy regimens

**Table 2. Recommendations for systemic treatment and supportive medication**

- Dosing of chemotherapeutic drugs during pregnancy should be based on actual weight.
- The same dose/m<sup>2</sup> or dose/kg<sup>2</sup> should be used as in nonpregnant patients.
- Chemotherapy is contra-indicated in the first trimester of gestation to avoid interference with organogenesis; fetal benefit of treatment delay until the second trimester should be balanced against maternal risk.
- After 14 weeks of gestation, administration of a number of anticancer drugs is feasible including taxanes, platinum agents, anthracyclines, etoposide and bleomycin.
- Chemotherapy is not recommended beyond 35 weeks: it is important to give a 3-week window between the last cycle of chemotherapy and delivery to allow both maternal and fetal bone marrow to recover.
- Anti VEGF and other antiangiogenic drugs are contraindicated during pregnancy.
- Until safety data are available, targeted therapies should be avoided during pregnancy.
- Metoclopramide, 5HT<sub>3</sub> antagonists, ranitidine, proton pump inhibitors, methylprednisolone, prednisolone or hydrocortisone can be used if necessary.

**Table 3. Chemotherapy regimens used for cancer during pregnancy**

Tumor type	Preferred regimen
Cervical cancer	Paclitaxel/carboplatin weekly or 3-weekly
Epithelial ovarian cancer	Paclitaxel/carboplatin 3 weekly
Nonepithelial ovarian cancer	(Bleomycine/) etoposide/cisplatin (BEP or EP)

BEP, bleomycin, etoposide and platinum; EP, etoposide and cisplatin.

most commonly prescribed for gynecological cancers during pregnancy [55].

Chemotherapy is not recommended beyond a gestational age of 35 weeks since a 3-week window between the last cycle of chemotherapy and delivery is important to allow both maternal and fetal bone marrow recovery. This window is particularly important in preterm infants who lack the enzymes to metabolize chemotherapy adequately [56]. However, when weekly regimens are used, the panel recommends that administration should not go beyond 37-week gestational age.

Due to their relatively small molecular weight, most chemotherapeutic drugs can cross the placenta. For a detailed summary of the studies of placental transfer of chemotherapies used in gynecological cancers during pregnancy please refer to [supplementary Table S7](#), available at *Annals of Oncology* online.

### Specific agents

A favorable fetal toxicity profile of weekly paclitaxel, 3-weekly paclitaxel and docetaxel during the second and third trimesters of pregnancy is supported by pharmacological evidence [53]. Although substantial placental transfer has been ascribed to platinum-based compounds, administration of carboplatin during pregnancy seems safe. Cisplatin carries the risk of dose-dependent ototoxicity in children that were exposed during pregnancy [57–59]. Carboplatin is therefore preferred for gynecological malignancies except for germ cell cancers, in which a cisplatin-based schedule is standard of care. Etoposide remains relatively myelotoxic, but its use during pregnancy in combination with cisplatin with or without bleomycin has been

described and appears to be safe, although the numbers of cases are limited [60–62].

The use of targeted therapies or supportive medication during pregnancy is explained in supplementary Box S3, available at *Annals of Oncology* online.

### Radiation therapy

The influence of radiation on pregnancy in general may include fetal death, malformations and growth disturbances and may lead to carcinogenic effects, depending on gestational stage and radiation dose/dose rate (scheduling). We discriminate deterministic effects, occurring above a threshold dose with a severity related to the dose (e.g. teratogenesis), from stochastic effects, without a threshold, dose-related frequency and dose-independent severity (e.g. carcinogenesis) [24, 63]. Overall, there is no role for radiation therapy (RT) during pregnancy for pelvic cancers, unless embryo-fetal death is considered unavoidable. Nevertheless, all reported cases of nonpelvic RT during pregnancy describe healthy babies without RT-related side effects [64, 65]. Possible treatment options need to be discussed in a shared decision-making process with patient and partner. General recommendations can be seen in Table 4.

### Obstetrical care

All patients deserve referral to a high-risk, dedicated, well-equipped obstetric center for prenatal care.

After cancer diagnosis early in pregnancy or an inadvertent pregnancy during cancer treatment, it is important to obtain an accurate estimation of gestational age and assessment of the structural development of the fetus and placenta to exclude pre-existing anomalies. In fact, during the first trimester the embryo is most vulnerable to teratogenic exposure. Standard screening and diagnostics for chromosomal and structural anomalies should be offered, and gestational complications should be assessed. In addition, folic acid supplementation and nutritional counseling is important to optimize the materno-fetal status.

If an agreement on intervention has been reached, fetal monitoring should be performed before and after surgery to detect fetal distress. In case of uterine manipulations during surgery, prophylactic use of tocolytics can be considered. After cervical



**Table 4. Recommendations for radiation oncology teams treating pregnant gynecological cancer patients**

- Any radiation treatment to the pelvic region will deliver a significant dose to the fetus and should therefore be avoided if pregnancy is to be continued.
- Doses in the therapeutic range, starting from the first fraction, will lead to fetal death.
- The probability for a new pregnancy after successful cancer treatment decreases with the delivered radiation dose to the uterine structures.
- If radiation therapy is indicated after termination of pregnancy, it is advised that the ovaries are marked with radiological visible clips to guide ovary-sparing radiation therapy to decrease the risk of premature menopause.

conization, serial cervical length measurements are advised to assess cervical incompetence [66]. Vaginal progesterone administration is advised when the residual cervical length is <25 mm [67]. If there is no residual disease and limited residual cervical length, the panel believes a cerclage should be considered.

Abdominal and cervical surgeries are not associated with an increased likelihood of admission to neonatal intensive care units (NICUs) in comparison to pregnant cancer patients with or without other treatments [25]. In contrast, pregnant patients receiving chemotherapy seem to be at increased risk for having a fetus with intrauterine growth restriction, preterm premature rupture of membranes and preterm contractions [25]. In particular, platinum-based chemotherapy is associated with small-for-gestational age neonates, whereas taxanes are associated with NICU admission [25]. Thus, pregnant patients receiving antenatal chemotherapy should be monitored on a regular basis (2–4 weekly) with serial ultrasounds assessing interval growth, amniotic fluid and cervical length [25]. Further, the morphological development should be evaluated by ultrasonography. Fetal Doppler exams should be added in case of growth restriction or to evaluate fetal anemia via measurements of the peak systolic velocity (PSV) [68]; this might be particular evident after platinum derivatives are used.

If possible, delivery should not be induced before 37 weeks to avoid acute neonatal morbidities and long-term prematurity-related sequelae. When a preterm delivery is inevitable, steroids for fetal lung maturation should be considered (supplementary Table S3, available at *Annals of Oncology* online). Although the overall impact of mode of delivery on the oncological outcome of cervical cancer is controversial, vaginal delivery may result in tumor laceration, excessive bleeding and fatal implantation of malignant cells at the site of episiotomy [69–71]. In addition, cervical cancer can obstruct the birth canal. Thus, C-section is indicated for cervical and also for most vulvar cancers. As metastases can be found in the abdominal wound scar after surgery and C-section [72], a corporeal uterine incision is carried out to avoid surgical trauma of the lower uterine part harboring the cancer [27, 72, 73].

C-section could be combined with simple or radical hysterectomy. Usually, the C-section is carried out under locoregional anesthesia, with conversion to general anesthesia for the hysterectomy. Lymph node dissection, with or without sentinel node biopsy, can be carried out after delivery when nodal status was not assessed previously during pregnancy [27]. Meticulous surgery by an experienced gynecological oncologist is mandatory to minimize blood loss [73]. Patients with cervical cancer that was already completely excised during pregnancy and ovarian cancer have no oncologic indications for C-section [2].

Both the pregnancy/postpartum period and malignancy are risk factors for venous thromboembolism. Therefore, thromboprophylaxis with low-molecular-weight heparin should be considered [74], especially in postoperative setting or in the case of immobilization. Oncological treatment can be continued immediately after vaginal delivery, and 1 week after uncomplicated C-section. It is also important to discuss postpartum contraception if fertility is maintained [75].

Breastfeeding is allowed if there is no ongoing chemotherapy or targeted therapy, if the time since last administration is at least 3 weeks [76].

The placenta should be examined for metastatic disease [77–81]. In the rare case that the placenta shows metastases, three monthly clinical follow-up of the child is recommended by a specialized cancer expert in a pediatric oncology center. Metastasis to the fetus in gynecological cancers is exceptional [82].

### Neonatal and pediatric care

The neonate needs to be examined thoroughly by a neonatologist or pediatrician. After exposure to chemotherapy, hematological parameters, liver and renal function should be checked. Preterm and small-for-gestational age (SGA) infants require specific neonatal follow-up care. In the case of cardiotoxic treatment (e.g. anthracyclines) administered during pregnancy, an echocardiogram in the first weeks is advisable. After platinum exposure, special attention for hearing function is needed throughout infancy [58]. It is anticipated, based on animal models as well as childhood cancer studies, that combining platinum exposure with aminoglycosides or furosemide adds to the risk [83, 84].

Long-term toxicity data after chemotherapy exposure in young children with childhood cancer has shown cardiotoxicity, hearing loss, neurocognitive problems, endocrine impairment, secondary malignancy and general increased morbidities [85–88]. In particular, anthracyclines are notorious for long-term cardiotoxicity in cancer survivors, and cisplatin for irreversible hearing loss [87, 88]. Based on these findings, surveillance guidelines have been developed for life-long follow-up of young cancer survivors [89].

Although it is still unclear whether the effects of *in utero* chemotherapeutic exposure are similar to the effects of exposure in young children with cancer, it is important to address the same short- and long-term toxic effects. Several important large-scale studies have addressed the outcome of children born to mothers diagnosed with cancer, but none have specifically investigated outcome in gynecological cancers. These studies have shown that middle- and long-term cognitive and physical outcomes of children prenatally exposed to chemotherapy appear reassuring until now [25, 57, 90–94], although neurocognitive problems and

**Table 5. Follow-up of children born, after gynecological cancer in pregnancy**

Cancer in pregnancy	Screening of children with intrauterine chemotherapy/radiotherapy during pregnancy because of maternal gynecological cancer (including cervix carcinoma, ovarian cancer and breast cancer)													
	At birth	1–6	8	9	10	12	15	18	3	6	9	12	15	17
<b>Birth</b>														
Examination of placenta	X													
Examination of neonate	X													
Registration of family (mother and child) (signed informed consent)	X													
Follow-up/check-up (care)		X/X <sup>a</sup>							X	X	X	X	X	X
Blood count (morphology, differentiation) <sup>b</sup>	X													
Evaluation of auditory function <sup>c</sup>		X									X			
EKG and echocardiogram <sup>d</sup>		X			X				X	X	X		X	X
Neurocognitive development (psychologist)		X							X	X	X	X	X	X
Neuromotor development (qualified physiotherapist/ neurologist or pediatrician)		X							X	X	X	X	X	X
Genetic consultation offered		X												
<b>Time</b>														
<b>Months</b>														
<b>Years</b>														

The expert panel recommends the following roles for the multidisciplinary team involved in the follow-up: *Gynecologist*: Sends placenta for extensive pathological/histological examination (explicitly asks to examine for metastasis of maternal malignancy). Asks consultation of neonatologist. Consultation form: malignancy mother, moment of diagnosis, stage of the disease, metastasis, type, TCD and time of treatment. *Neonatologist*: Physical examination of the neonate, explanation of risk of metastasis and necessity to examine the placenta, reasons for follow-up. Monitor outcome of placental examination, contact parents with result, and perform additional diagnostic tests if indicated. Contact pediatrician experienced in chemo related toxicity, connected to INCIP. *Pediatrician* experienced in chemo related toxicity, connected to INCIP: Further follow-up child. Perform surveillance including additional diagnostic.

<sup>a</sup>Intensive follow-up when indicated: placenta positive for micrometastasis or when neonatal abnormalities suspicious for metastasis are identified at birth.

<sup>b</sup>Diagnostic tests: (i) *laboratory tests* will include complete blood count when chemotherapy was administered <4 weeks before the birth (risk of bone marrow depression) or complete blood count plus analyses of transaminases and lactic acid dehydrogenase (when the placenta contains metastasis or when neonatal abnormalities suspicious for metastasis are found); (ii) *abdominal ultrasound* when the placenta contains metastasis (in the first week of life), or when neonatal abnormalities suspicious for metastasis are identified (urgently in the first days postpartum).

<sup>c</sup>After intrauterine exposure to platin-based treatment: evaluation of auditory function by ALGO/OAE: until 6 years. Beyond the age of 6 years a tone audiogram is advised.

<sup>d</sup>Echocardiogram and electrocardiogram: after intrauterine anthracycline exposure.

OAE, oto-acoustic emissions; ALGO, automatic BERA; BERA, brainstem evoked response audiometry; TCD, total cumulative dose.

**Table 6. Recommendations for psychosocial caregivers treating pregnant cancer patients and their families**

- Psychologists should be included in the interdisciplinary team of caregivers for pregnant cancer patients.
- Counseling should be offered to both the affected woman and her partner.
- An extensive education about necessary medical steps and their implication on the outcome of the pregnancy and long-term effects on the physical and cognitive health of the offspring should be provided.
- Contact with other families who have experienced cancer during pregnancy should be encouraged as it might help to cope more easily with own emotions, thoughts, and concerns.
- In gynecological cancers hysterectomy and bilateral oophorectomy can be performed. Thus, the interdisciplinary team should be aware of the possible psychological effects of this surgery, including depression, loss of sexual pleasure and future childbearing.

cardiotoxicity may become more apparent later in life. In addition, in prenatally platinum-exposed children, irreversible hearing loss has been described [11, 58, 95]. Thus, we recommend a long-term follow-up of children exposed antenatally to chemotherapy every three years, in case of cisplatin or anthracycline *in*

*utero* exposure. Additionally, we recommend an auditory evaluation and echocardiographic follow-up, respectively (Table 5).

Furthermore, a consultation is recommended shortly after birth as a standard of care, to (ideally) confirm that the newborn is healthy, to inform the families regarding follow-up, and to

support them by giving information and access to specialized medical surveillance and psychosocial family care. This is further underscored by the fact that, in the following years, a probability exists that the child will lose the mother at an early age; hence, the team can anticipate that psychosocial support may be offered, when desired.

### Psychologic effects

A cancer diagnosis during pregnancy is a challenging life event. This can cause prenatal maternal stress and disruptions in mother–child interactions. In healthy women, stress and anxiety during pregnancy have been associated with adverse birth outcomes, developmental and cognitive impairments and psychopathology in the offspring. There is an increased risk of spontaneous abortion, preterm labor, malformations, growth restriction and low birth weight [96, 97]. Further, women confronted with this situation often do not feel completely understood by others. Treatment of gynecological cancers (e.g. hysterectomy, radiotherapy of the pelvis, bilateral oophorectomy) may also induce other psychological effects, including depression, but may also result in sexual dysfunctions such as dyspareunia or loss of sexual desire and arousal [98]. The psychological impact of such a devastating and threatening life event on the partner is often ignored, which can also compromise the partnership and the father–child relationship [99].

A recent study has shown that an extensive education about necessary medical steps and their implication on the outcome of the pregnancy and long-term effects on the physical and cognitive health of the offspring might alleviate the fear of harming the child, thus reducing guilt and anxiety [99]. Thus, pregnant cancer patients deserve a careful continuous assessment and support of their psychological wellbeing on a routine basis with follow-up in the postpartum period [25]. General recommendations are provided in Table 6.

### Acknowledgements

The authors would like to thank Roxana Schwab, Martine van Grotel and Hanne Stensheim, for critically reviewing the manuscript, and Dr Madeleine van de Perk and Dr Emma Verwaaijen for their contribution to the design of pediatric surveillance schedule. We would also like to acknowledge Marie-Astrid Van Hoorick and Katrien Van Tornout for the administrative support. Finally, we would like to thank Silvia Calpe for manuscript editing.

### Funding

This consensus meeting was sponsored by European Society of Gynaecological Oncology (ESGO) [no grant number applies].

### Disclosure

The authors have declared no conflicts of interest.

### References

- Amant F, Van Calsteren K, Halaska MJ et al. Gynecologic cancers in pregnancy. *Int J Gynecol Cancer* 2009; 19(Suppl 1): S1–12.
- Amant F, Halaska MJ, Fumagalli M et al. Gynecologic cancers in pregnancy: guidelines of a second international consensus meeting. *Int J Gynecol Cancer* 2014; 24(3): 394–403.
- Eibye S, Kjær SK, Møller L. Incidence of pregnancy-associated cancer in Denmark, 1977–2006. *Obstet Gynecol* 2013; 122(3): 608–617.
- Lee YY, Roberts CL, Dobbins T et al. Incidence and outcomes of pregnancy-associated cancer in Australia, 1994–2008: a population-based linkage study. *BJOG* 2012; 119(13): 1572–1582.
- Smith LH, Danielsen B, Allen ME, Cress R. Cancer associated with obstetric delivery: results of linkage with the California cancer registry. *Am J Obstet Gynecol* 2003; 189(4): 1128–1135.
- Amant F, Verheecke M, Wlodarska I et al. Presymptomatic identification of cancers in pregnant women during noninvasive prenatal testing. *JAMA Oncol* 2015; 1(6): 814–819.
- Cottreau CM, Dashevsky I, Andrade SE et al. Pregnancy-associated cancer: a U.S. population-based study. *J Womens Health (Larchmt)* 2019; 28(2): 250–257.
- Parazzini F, Franchi M, Tavani A et al. Frequency of pregnancy related cancer: a population based linkage study in Lombardy, Italy. *Int J Gynecol Cancer* 2017; 27(3): 613–619.
- Andersson T-L, Johansson AV, Fredriksson I, Lambe M. Cancer during pregnancy and the postpartum period: a population-based study. *Cancer* 2015; 121(12): 2072–2077.
- Dalrymple JL, Gilbert WM, Leiserowitz GS et al. Pregnancy-associated cervical cancer: obstetric outcomes. *J Matern Fetal Neonatal Med* 2005; 17(4): 269–276.
- Nazer A, Czuzoj-Shulman N, Oddy L, Abenheim HA. Incidence of maternal and neonatal outcomes in pregnancies complicated by ovarian masses. *Arch Gynecol Obstet* 2015; 292(5): 1069–1074.
- Leiserowitz GS, Xing G, Cress R et al. Adnexal masses in pregnancy: how often are they malignant? *Gynecol Oncol* 2006; 101(2): 315–321.
- Stensheim H, Møller B, van Dijk T, Fosså SD. Cause-specific survival for women diagnosed with cancer during pregnancy or lactation: a registry-based cohort study. *J Clin Oncol* 2009; 27(1): 45–51.
- Halaska MJ, Uzan C, Han SN et al. Characteristics of patients with cervical cancer during pregnancy: a multicenter matched cohort study. An initiative from the International Network on Cancer, Infertility and Pregnancy. *Int J Gynecol Cancer* 2019; 29(4): 676.
- Yael HK, Lorenza P, Evelina S et al. Incidental endometrial adenocarcinoma in early pregnancy. *Int J Gynecol Cancer* 2009; 19(9): 1580–1584.
- Haas JF. Pregnancy in association with a newly diagnosed cancer: a population-based epidemiologic assessment. *Int J Cancer* 1984; 34(2): 229–235.
- Matsuo K, Whitman SA, Blake EA et al. Feto-maternal outcome of pregnancy complicated by vulvar cancer: a systematic review of literature. *Eur J Obstet Gynecol Reprod Biol* 2014; 179: 216–223.
- Soo-Hoo S, Luesley D. Vulval and vaginal cancer in pregnancy. *Best Pract Res Clin Obstet Gynaecol* 2016; 33: 73–78.
- Hasanzadeh M, Zamiri-Akhlagh A, Hassanpoor-Moghaddam M, Shahidsales S. Vulvar carcinoma in pregnant women aged less than 40 years: case report. *Iran J Cancer Prev* 2014; 7: 175–178.
- Lecointre L, Gaudineau A, Hild C et al. Carcinome épidermoïde de la vulve et grossesse: des choix difficiles. *Gynécologie Obs Fertil* 2015; 43(9): 625–627.
- Fujita K, Aoki Y, Tanaka K. Stage I squamous cell carcinoma of vagina complicating pregnancy: successful conservative treatment. *Gynecol Oncol* 2005; 98(3): 513–515.
- Akil A, Kaya B, Karabay A, Kibar Y. Concurrent endometrial adenocarcinoma and an early pregnancy loss. *Arch Gynecol Obstet* 2012; 286(4): 1089–1090.
- Zhou F, Qian Z, Li Y et al. Endometrial adenocarcinoma in spontaneous abortion: two cases and review of the literature. *Int J Clin Exp Med* 2015; 8: 8230–8233.

24. Valentin J. Biological effects after prenatal irradiation (embryo and fetus). *Ann ICRP* 2003; 33: 1–206.
25. de Haan J, Verheeeck M, Van Calsteren K et al. Oncological management and obstetric and neonatal outcomes for women diagnosed with cancer during pregnancy: a 20-year international cohort study of 1170 patients. *Lancet Oncol* 2018; 19(3): 337–346.
26. Ray JG, Vermeulen MJ, Bharatha A et al. Association between MRI exposure during pregnancy and fetal and childhood outcomes. *JAMA* 2016; 316(9): 952.
27. Papadia A, Mohr S, Imboden S et al. Laparoscopic indocyanine green sentinel lymph node mapping in pregnant cervical cancer patients. *J Minim Invasive Gynecol* 2016; 23(2): 270–273.
28. Han SN, Amant F, Michielsen K et al. Feasibility of whole-body diffusion-weighted MRI for detection of primary tumour, nodal and distant metastases in women with cancer during pregnancy: a pilot study. *Eur Radiol* 2018; 28(5): 1862–1874.
29. Peccatori FA, Codacci-Pisanelli G, Del Grande M et al. Whole body MRI for systemic staging of breast cancer in pregnant women. *Breast* 2017; 35: 177–181.
30. Frisch A, Walter TC, Hamm B, Denecke T. Efficacy of oral contrast agents for upper gastrointestinal signal suppression in MRCP: a systematic review of the literature. *Acta Radiol Open* 2017; 6(9): 2058460117727315.
31. Mazze RI, Källén B. Reproductive outcome after anesthesia and operation during pregnancy: a registry study of 5405 cases. *Am J Obstet Gynecol* 1989; 161(5): 1178–1185.
32. Lee AJ, Landau R, Mattingly JL et al. Left lateral table tilt for elective cesarean delivery under spinal anesthesia has no effect on neonatal acid–base status. *Anesthesiology* 2017; 127(2): 241–249.
33. Shigemi D, Aso S, Matsui H et al. Safety of laparoscopic surgery for benign diseases during pregnancy: a nationwide retrospective cohort study. *J Minim Invasive Gynecol* 2019; 26(3): 501–506.
34. Webb K, Sakhel K, Chauhan S, Abuhamad A. Adnexal mass during pregnancy: a review. *Am J Perinatol* 2015; 32(11): 1010–1016.
35. Estadella J, Español P, Grandal B et al. Laparoscopy during pregnancy: case report and key points to improve laparoscopic management. *Eur J Obstet Gynecol Reprod Biol* 2017; 217: 83–88.
36. Jackson H, Granger S, Price R et al. Diagnosis and laparoscopic treatment of surgical diseases during pregnancy: an evidence-based review. *Surg Endosc* 2008; 22(9): 1917–1927.
37. Ye P, Zhao N, Shu J et al. Laparoscopy versus open surgery for adnexal masses in pregnancy: a meta-analytic review. *Arch Gynecol Obstet* 2019; 299(3): 625–634.
38. Evans SRT, Sarani B, Bhanot P, Feldman E. Surgery in pregnancy. *Curr Probl Surg* 2012; 49(6): 333–388.
39. Bhatla N, Aoki D, Sharma DN, Sankaranarayanan R. Cancer of the cervix uteri. *Int J Gynaecol Obstet* 2018; 143(Suppl 2): 22–36.
40. Covens A, Rosen B, Murphy J et al. How important is removal of the parametrium at surgery for carcinoma of the cervix? *Gynecol Oncol* 2002; 84(1): 145–149.
41. Strnad P, Robova H, Skapa P et al. A prospective study of sentinel lymph node status and parametrial involvement in patients with small tumour volume cervical cancer. *Gynecol Oncol* 2008; 109(2): 280–284.
42. Morice P, Uzan C, Gouy S et al. Gynaecological cancers in pregnancy. *Lancet* 2012; 379(9815): 558–569.
43. Rydzewska L, Tierney J, Vale CL, Symonds PR. Neoadjuvant chemotherapy plus surgery versus surgery for cervical cancer. *Cochrane Database Syst Rev* 2012; 12: CD007406.
44. Cibula D, Pötter R, Planchamp F et al. The European Society of Gynaecological Oncology/European Society for Radiotherapy and Oncology/European Society of Pathology guidelines for the management of patients with cervical cancer. *Int J Gynecol Cancer* 2018; 28(4): 641–655.
45. Sood AK, Sorosky JI, Mayr N et al. Radiotherapeutic management of cervical carcinoma that complicates pregnancy. *Cancer* 1997; 80(6): 1073–1078.
46. van Maaren MC, Bretveld RW, Jobsen JJ et al. The influence of timing of radiation therapy following breast-conserving surgery on 10-year disease-free survival. *Br J Cancer* 2017; 117(2): 179–188.
47. Weisz B, Meirou D, Schiff E, Lishner M. Impact and treatment of cancer during pregnancy. *Expert Rev Anticancer Ther* 2004; 4(5): 889–902.
48. Sood AK, Shahin MS, Sorosky JI. Paclitaxel and platinum chemotherapy for ovarian carcinoma during pregnancy. *Gynecol Oncol* 2001; 83(3): 599–600.
49. Ngu S-F, Ngan H. Chemotherapy in pregnancy. *Best Pract Res Clin Obstet Gynaecol* 2016; 33: 86–101.
50. Cardonick E, Iacobucci A. Use of chemotherapy during human pregnancy. *Lancet Oncol* 2004; 5(5): 283–291.
51. Shachar SS, Gallagher K, McGuire K et al. Multidisciplinary management of breast cancer during pregnancy. *Oncologist* 2017; 22(3): 324–334.
52. Ricci C, Scambia G, De Vincenzo R. Locally advanced cervical cancer in pregnancy. *Int J Gynecol Cancer* 2016; 26(8): 1490–1496.
53. Mir O, Berveiller P, Goffinet F et al. Taxanes for breast cancer during pregnancy: a systematic review. *Ann Oncol* 2010; 21(2): 425–426.
54. Zheng X, Zhu Y, Zhao Y et al. Taxanes in combination with platinum derivatives for the treatment of ovarian cancer during pregnancy: a literature review. *Int J Clin Pharmacol Ther* 2017; 55: 753–760.
55. Robova H, Halaska MJ, Pluta M et al. Oncological and pregnancy outcomes after high-dose density neoadjuvant chemotherapy and fertility-sparing surgery in cervical cancer. *Gynecol Oncol* 2014; 135(2): 213–216.
56. Sadler NC, Nandhikonda P, Webb-Robertson B-J et al. Hepatic cytochrome P450 activity, abundance, and expression throughout human development. *Drug Metab Dispos* 2016; 44(7): 984–991.
57. Amant F, Vandenbroucke T, Verheeeck M et al. Pediatric outcome after maternal cancer diagnosed during pregnancy. *N Engl J Med* 2015; 373(19): 1824–1834.
58. Geijteman ECT, Wensveen CWM, Duvekot JJ, van Zuylen L. A child with severe hearing loss associated with maternal cisplatin treatment during pregnancy. *Obstet Gynecol* 2014; 124: 454–456.
59. Raffles A, Williams J, Costeloe K, Clark P. Transplacental effects of maternal cancer chemotherapy. Case report. *Br J Obstet Gynaecol* 1989; 96(9): 1099–1100.
60. Han J-Y, Nava-Ocampo AA, Kim T-J et al. Pregnancy outcome after prenatal exposure to bleomycin, etoposide and cisplatin for malignant ovarian germ cell tumors: report of 2 cases. *Reprod Toxicol* 2005; 19(4): 557–561.
61. Cardonick E, Usmani A, Ghaffar S. Perinatal outcomes of a pregnancy complicated by cancer, including neonatal follow-up after in utero exposure to chemotherapy. *Am J Clin Oncol* 2009; 33: 1.
62. Ghaemmaghami F, Abbasi F, Abadi A. A favorable maternal and neonatal outcome following chemotherapy with etoposide, bleomycin, and cisplatin for management of grade 3 immature teratoma of the ovary. *J Gynecol Oncol* 2009; 20(4): 257–259.
63. ICRP. Pregnancy and medical radiation. *Ann ICRP* 2000; 84: 1–43.
64. Kal HB, Struikmans H. Radiotherapy during pregnancy: fact and fiction. *Lancet Oncol* 2005; 6(5): 328–333.
65. Vandenbroucke T, Verheeeck M, Fumagalli M et al. Effects of cancer treatment during pregnancy on fetal and child development. *Lancet Child Adolesc Heal* 2017; 1(4): 302–310.
66. Kyrgiou M, Athanasiou A, Paraskevaïdi M et al. Adverse obstetric outcomes after local treatment for cervical preinvasive and early invasive disease according to cone depth: systematic review and meta-analysis. *BMJ* 2016; 354: i3633.
67. Choi S-J. Use of progesterone supplement therapy for prevention of preterm birth: review of literatures. *Obstet Gynecol Sci* 2017; 60(5): 405–420.
68. Halaska MJ, Komar M, Vlk R et al. A pilot study on peak systolic velocity monitoring of fetal anemia after administration of chemotherapy during pregnancy. *Eur J Obstet Gynecol Reprod Biol* 2014; 174: 76–79.
69. Manuel-Limson GA, Ladines-Llave CA, Sotto LS, Manalo AM. Cancer of the cervix in pregnancy: a 31-year experience at the Philippine General Hospital. *J Obstet Gynaecol Res* 1997; 23(6): 503–509.

70. Nisker JA, Shubat M. Stage IB cervical carcinoma and pregnancy: report of 49 cases. *Am J Obstet Gynecol* 1983; 145(2): 203–206.
71. Vandervange N, Weverling G, Ketting B et al. The prognosis of cervical cancer associated with pregnancy: a matched cohort study. *Obstet Gynecol* 1995; 85(6): 1022.
72. Tewari K, Cappuccini F, Gambino A et al. Neoadjuvant chemotherapy in the treatment of locally advanced cervical carcinoma in pregnancy: a report of two cases and review of issues specific to the management of cervical carcinoma in pregnancy including planned delay of therapy. *Cancer* 1998; 82(8): 1529–1534.
73. Bigelow CA, Horowitz NS, Goodman A et al. Management and outcome of cervical cancer diagnosed in pregnancy. *Am J Obstet Gynecol* 2017; 216(3): 276.e1–276.e6.
74. Hase E, Barros V, Igai A et al. Risk assessment of venous thromboembolism and thromboprophylaxis in pregnant women hospitalized with cancer: preliminary results from a risk score. *Clinics* 2018; 73: e368.
75. Han SN, Van Peer S, Peccatori F et al. Contraception is as important as fertility preservation in young women with cancer. *Lancet* 2015; 385(9967): 508.
76. Stopenski S, Aslam A, Zhang X, Cardonick E. After chemotherapy treatment for maternal cancer during pregnancy, is breastfeeding possible? *Breastfeed Med* 2017; 12(2): 91–97.
77. Can NTT, Robertson P, Zaloudek CJ, Gill RM. Cervical squamous cell carcinoma metastatic to placenta. *Int J Gynecol Pathol* 2013; 32(5): 516–519.
78. Cailliez D, Moïrot MH, Fessard C et al. Placental localisation of cancer of the cervix (author's transl). *J Gynecol Obstet Biol Reprod (Paris)* 1980; 9: 461–463.
79. Frick R, Rummel H, Heberling D, Schmidt WO. Placental metastases from a maternal angiofibrosarcoma of the vagina (author's transl). *Geburtshilfe Frauenheilkd* 1977; 37: 216–220.
80. Alexander A, Samlowski WE, Grossman D et al. Metastatic melanoma in pregnancy: risk of transplacental metastases in the infant. *J Clin Oncol* 2003; 21(11): 2179–2186.
81. Orr JW, Grizzle WE, Huddleston JF. Squamous cell carcinoma metastatic to placenta and ovary. *Obstet Gynecol* 1982; 59(Suppl 6): 81S–83S.
82. Greaves M, Hughes W. Cancer cell transmission via the placenta. *Evol Med Public Health* 2018; 2018(1): 106–115.
83. Clemens E, de Vries AC, Pluijm SF et al. Determinants of ototoxicity in 451 platinum-treated Dutch survivors of childhood cancer: a DCOG late-effects study. *Eur J Cancer* 2016; 69: 77–85.
84. Clemens E, de Vries AC, am Zehnhoff-Dinnesen A et al. Hearing loss after platinum treatment is irreversible in noncranial irradiated childhood cancer survivors. *Pediatr Hematol Oncol* 2017; 34(2): 120–129.
85. Mennes M, Stiers P, Vandenbussche E et al. Attention and information processing in survivors of childhood acute lymphoblastic leukemia treated with chemotherapy only. *Pediatr Blood Cancer* 2005; 44: 478–486.
86. Van Der Plas E, Erdman L, Nieman BJ et al. Characterizing neurocognitive late effects in childhood leukemia survivors using a combination of neuropsychological and cognitive neuroscience measures. *Child Neuropsychol* 2018; 24(8): 999–1014.
87. Travis LB, Fossa SD, Sessa HD et al. Chemotherapy-induced peripheral neurotoxicity and ototoxicity: new paradigms for translational genomics. *JNCI J Natl Cancer Inst* 2014; 106(5): dju044.
88. Peleva E, Emami N, Alzahrani M et al. Incidence of platinum-induced ototoxicity in pediatric patients in Quebec. *Pediatr Blood Cancer* 2014; 61(11): 2012–2017.
89. Kremer LCM, Mulder RL, Oeffinger KC et al. A worldwide collaboration to harmonize guidelines for the long-term follow-up of childhood and young adult cancer survivors: a report from the International Late Effects of Childhood Cancer Guideline Harmonization Group. *Pediatr Blood Cancer* 2013; 60(4): 543–549.
90. Amant F, Van Calsteren K, Halaska MJ et al. Long-term cognitive and cardiac outcomes after prenatal exposure to chemotherapy in children aged 18 months or older: an observational study. *Lancet Oncol* 2012; 13(3): 256–264.
91. Cardonick EH, Gringlas MB, Hunter K, Greenspan J. Development of children born to mothers with cancer during pregnancy: comparing in utero chemotherapy-exposed children with nonexposed controls. *Am J Obstet Gynecol* 2015; 212(5): 658.e1–658.e8.
92. Avilés A, Neri N. Hematological malignancies and pregnancy: a final report of 84 children who received chemotherapy in utero. *Clin Lymphoma* 2001; 2(3): 173–177.
93. Avilés A, Neri N, Nambo M-J. Hematological malignancies and pregnancy: treat or no treat during first trimester. *Int J Cancer* 2012; 131(11): 2678–2683.
94. Avilés A, Neri N, Nambo MJ. Long-term evaluation of cardiac function in children who received anthracyclines during pregnancy. *Ann Oncol* 2006; 17(2): 286–288.
95. Yancey A, Harris MS, Egbelakin A et al. Risk factors for cisplatin-associated ototoxicity in pediatric oncology patients. *Pediatr Blood Cancer* 2012; 59(1): 144–148.
96. Mulder EJM, Robles de Medina PG, Huizink AC et al. Prenatal maternal stress: effects on pregnancy and the (unborn) child. *Early Hum Dev* 2002; 70(1–2): 3–14.
97. Loomans EM, van Dijk AE, Vrijkotte TGM et al. Psychosocial stress during pregnancy is related to adverse birth outcomes: results from a large multi-ethnic community-based birth cohort. *Eur J Public Health* 2013; 23(3): 485–491.
98. Vomvolaki E, Kalmantis K, Kioses E, Antsaklis A. The effect of hysterectomy on sexuality and psychological changes. *Eur J Contracept Reprod Health Care* 2006; 11(1): 23–27.
99. Vandenbroucke T, Han SN, Van Calsteren K et al. Psychological distress and cognitive coping in pregnant women diagnosed with cancer and their partners. *Psychooncology* 2017; 26(8): 1215–1221.