



HAL
open science

The super thin external pudendal artery (STEPA) free flap for oropharyngeal reconstruction – A case report

Agnès Dupret Bories, Mathieu Roumiguie, Guillaume de Bonnecaze, Jérôme Sarini, Benjamin Vairel, Sébastien Vergez, Bastien Benbassat

► To cite this version:

Agnès Dupret Bories, Mathieu Roumiguie, Guillaume de Bonnecaze, Jérôme Sarini, Benjamin Vairel, et al.. The super thin external pudendal artery (STEPA) free flap for oropharyngeal reconstruction – A case report. *Microsurgery*, 2019, 39 (8), pp.758-762. 10.1002/micr.30512 . hal-03169849

HAL Id: hal-03169849

<https://hal.science/hal-03169849>

Submitted on 15 Mar 2021

HAL is a multi-disciplinary open access archive for the deposit and dissemination of scientific research documents, whether they are published or not. The documents may come from teaching and research institutions in France or abroad, or from public or private research centers.

L'archive ouverte pluridisciplinaire **HAL**, est destinée au dépôt et à la diffusion de documents scientifiques de niveau recherche, publiés ou non, émanant des établissements d'enseignement et de recherche français ou étrangers, des laboratoires publics ou privés.




Open Archive Toulouse Archive Ouverte (OATAO)

OATAO is an open access repository that collects the work of Toulouse researchers and makes it freely available over the web where possible

This is an author's version published in: <http://oatao.univ-toulouse.fr/27630>


Official URL: <https://doi.org/10.1002/micr.30512>

To cite this version:

Dupret Bories, Agnès  and Roumiguie, Mathieu and De Bonnacaze, Guillaume and Sarini, Jérôme and Vairel, Benjamin and Vergez, Sébastien and Benbassat, Bastien *The super thin external pudendal artery (STEPA) free flap for oropharyngeal reconstruction – A case report.* (2019) *Microsurgery*, 39 (8). 758-762. ISSN 0738-1085

Any correspondence concerning this service should be sent to the repository administrator: tech-oatao@listes-diff.inp-toulouse.fr

The super thin external pudendal artery (STEPA) free flap for oropharyngeal reconstruction – A case report

Agnès Dupret-Bories MD, PhD¹  Mathieu Roumiguie MD, PhD²
Guillaume De Bonnecaze MD, PhD³ Jérôme Sarini MD¹ Benjamin Vairel MD³
Sébastien Vergez MD, PhD³ Bastien Benbassat Jr.³

¹Chirurgie ORL et cervico faciale, IUCT
Toulouse Oncopole, Institut Claudius Regaud,
Toulouse, France

²Chirurgie Urologique, Centre Hospitalier
Universitaire, Hôpital Rangueil, Toulouse,
France

³Chirurgie ORL et cervico faciale, Centre
Hospitalier Universitaire, Hôpital Larrey,
Toulouse, France

Correspondence

Agnès Dupret Bories, MD, PhD, Department
of Otorhinolaryngology, Institut Universitaire
du Cancer, 31009, Toulouse, France.
Email: dupret.bories.agnes@iuct oncopole.fr

Abstract

The radial forearm flap is one of the most used micro-anastomotic flaps in cervicofacial reconstruction in a carcinological context. This flap is an ideal in terms of reliability and fineness; it has, however, some disadvantages in terms of the functional and aesthetic complications of its donor site. In alternative to a radial forearm free flap, we report the use of the free super thin external pudendal artery flap (STEPA flap) for an oropharyngeal reconstruction. The aim was to decrease the donor site morbidity. A 71-years-old man with a T2N0M0 oropharyngeal squamous cell carcinoma has undergone surgical treatment. A left STEPA free flap was performed to reconstruct a defect about $8 \times 6 \text{ cm}^2$. This flap was designed as a half-scrotal free flap sized $9 \times 7 \text{ cm}^2$ and was inset after tunneling of the pedicle at the floor of the mouth. A surgical revision was needed on the 15th day postoperative for disunion. There was no skin flap failure. After 12 month of follow-up, no complication was observed at the donor site and no erectile dysfunction was recorded. Its characteristics in terms of fineness, flexibility, ease of conformation, and pedicle length are similar to those of the radial forearm flap with less aesthetic and functional sequelae of the donor site. The STEPA flap may be a promising free flap in oropharyngeal or oral cavity reconstruction.

1 | INTRODUCTION

Oropharyngeal reconstruction requires the use of a reliable free flap with tissue-like qualities to be reconstructed: fineness and flexibility for an ease of structure at the receiving site and a compact spatial design.

Since its description in 1981 by Yang et al. (Loeffelbein et al., 2012), the free radial forearm flap or Chinese flap (Benateau, Laraba, Alix, & Compere, 2002; Loeffelbein et al., 2012) is the most used in cervicofacial reconstruction in a carcinological context due to its fineness and plasticity. The primary criticisms are the sacrifice of one of the two major vascular axes of the hand and the functional and aesthetic morbidity caused at the donor site (Orlik et al., 2014). With equivalent features in terms of fineness and flexibility for minimal

scarring, the scrotal free flap named super thin external pudendal artery (STEPA) flap was recently described and used for the reconstruction of critical areas such as limbs or joint areas at the shoulder or knee (Phoon, Shah, Cormack, & Saint-Cyr, 2014). The STEPA flap was used for the first time in free form for the reconstruction of a foot defect in 2017 (Kiranantawat et al., 2018). In this article, we report the use of the STEPA flap for an oropharyngeal reconstruction.

2 | CASE REPORT

A 71-year-old man had an active continuation of a T2N0M0 left oropharyngeal squamous cell carcinoma at 6 months of treatment by external radiotherapy. The patient received a left posterior uninterrupted pelvi-mandibulectomy associated with a left oropharyngectomy with left

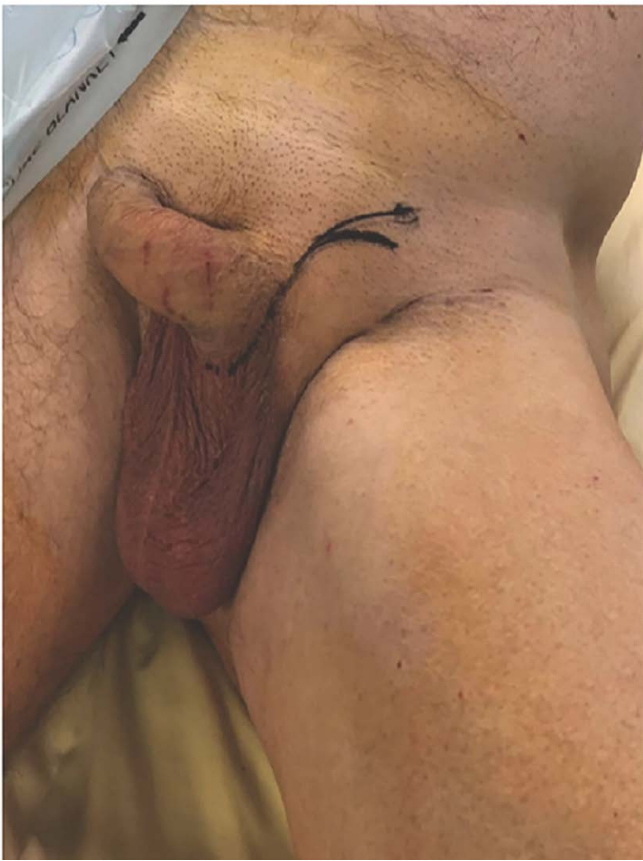

FIGURE 1 Initial skin markings. Arciform incision made on the inguinal ligament continuing on the lateral base of penis

cervical lymph node dissection and reconstruction with a left STEPA flap to reconstruct a defect about $8 \times 6 \text{ cm}^2$. The preoperative international index of erectile function (IIEF-5) survey recorded a mild erectile dysfunction (score 19 of 25).

The installation was standard for the resection of an oropharyngeal tumor in cervicofacial surgery, with the left lower limb entirely in the operative field so as to be able to position it in slight abduction and release the scrotum to perform the removal of the flap. An arciform incision was performed on the inguinal ligament then the dissection began in the subfascial layer (Figure 1). The first stage consisted of locating the suprapubic artery at its cross-over with the spermatic cord (Figure 2). Its prudent retrograde dissection was performed up to the base of its pedicle on the artery and the external pudendal vein, in the subcremasteric area. The artery and external pudendal vein were dissected, respectively, up to their base, femoral artery and large saphenous vein (Figure 2). The caliber of the artery and vein were, respectively, 2 and 2.2 mm and the length of the pedicle was 7.2 cm. The second step consisted of incising the scrotum at the median raphe following the preestablished limits of the cutaneous palette necessary for reconstruction with a dimension of 9 cm by 7 cm in our case. The incision began on the lateral portion of the base of the penis and continued along the median raphe. The testis and the testicular cord were separated from the scrotal sac by blunt dissection and carefully removed. The incision was continued inferiorly then parallel to the groin to join the initial exploratory incision. After ligation of the pedicle, the flap was placed on hold at the oropharyngeal receiving site after tunneling of the pedicle at the floor of the mouth

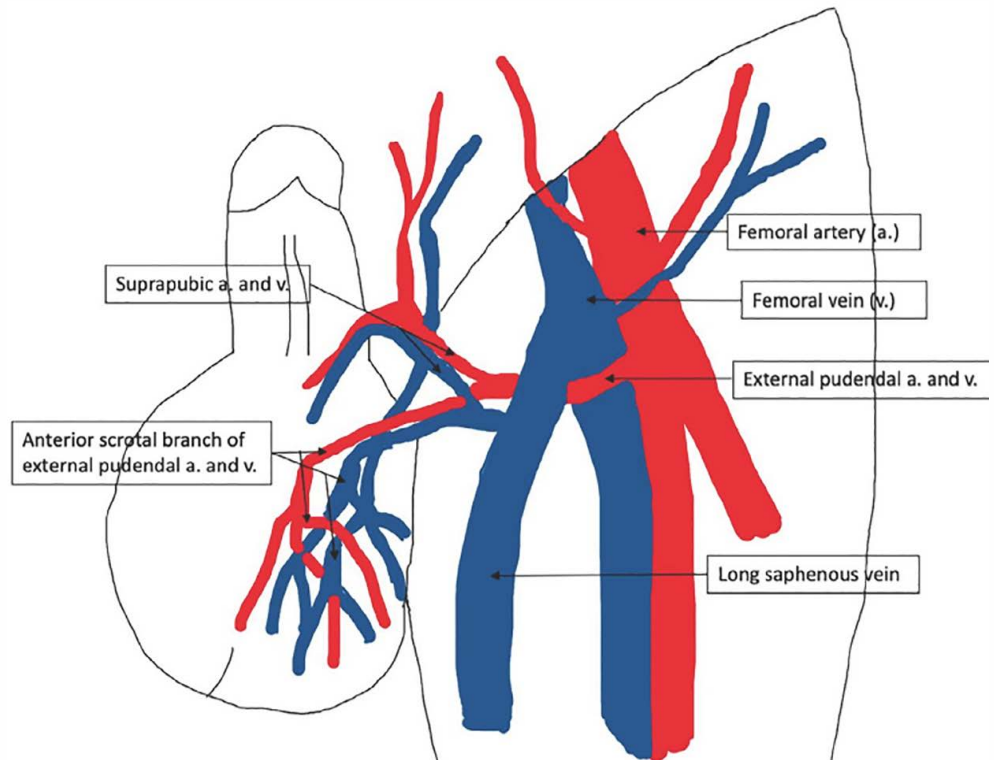


FIGURE 2 Super thin external pudendal artery flap (STEPA) flap's vascular anatomy

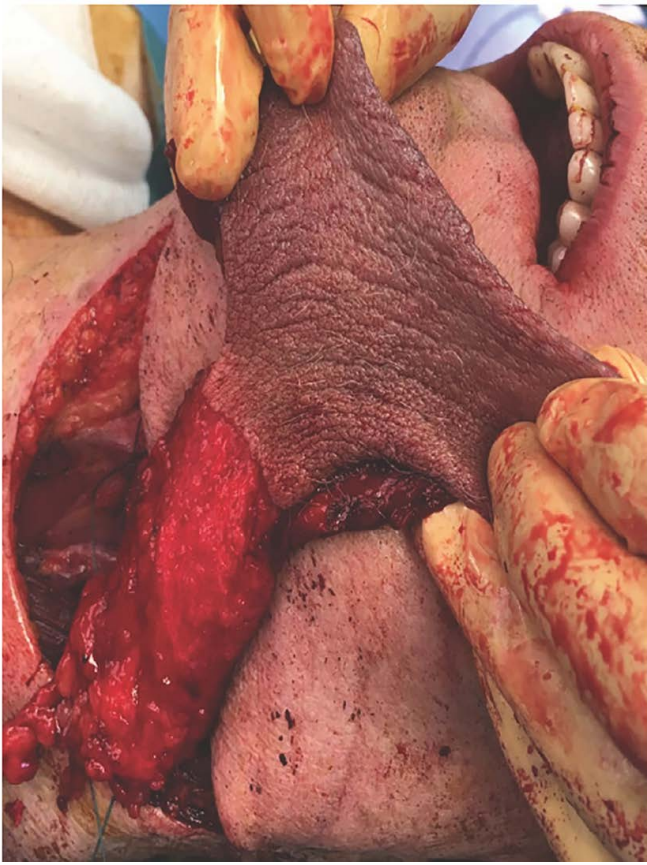


FIGURE 3 Scrotal free flap harvested, sized $9 \times 7 \text{ cm}^2$. Super thin external pudendal artery flap (STEPA) free flap after vascular ligation and before tunneling of the pedicle at the floor of the mouth

(Figure 3). Anastomoses of the external pudendal vessels (one artery and one vein) were performed by separate points of Ethilon 8.0, beginning with anastomosis of the artery with left facial artery, and then with that of the vein with the left facial vein. Then the flap was inset on the defect (Figure 4). After reintegration of the testis into the scrotum, the donor site was primarily closed without tension in two layers. The postoperative period was marked on the fourth day by a contraction of the flanks of the flap secondary to a major edema. On the 15th postoperative day, we proceeded with a surgical revision for disunion exceeding the junction of the soft palate with the flap on an irradiated area. Scarring was then obtained. Postoperative staging was pT2N0R0M0 with a supervisory guide as part of carcinological follow-up. No complication was observed at the donor site. Scarring was of good quality with a discrete scar hidden in the patient's undergarments (Figure 5). After 12 month of follow-up, the patient reports no aesthetic or sexual complaints and no erectile function impairment was recorded following the postoperative IIEF-5.

3 | DISCUSSION

Oropharyngeal or oral floor reconstruction in a carcinological situation by a STEPA Flap is promising.

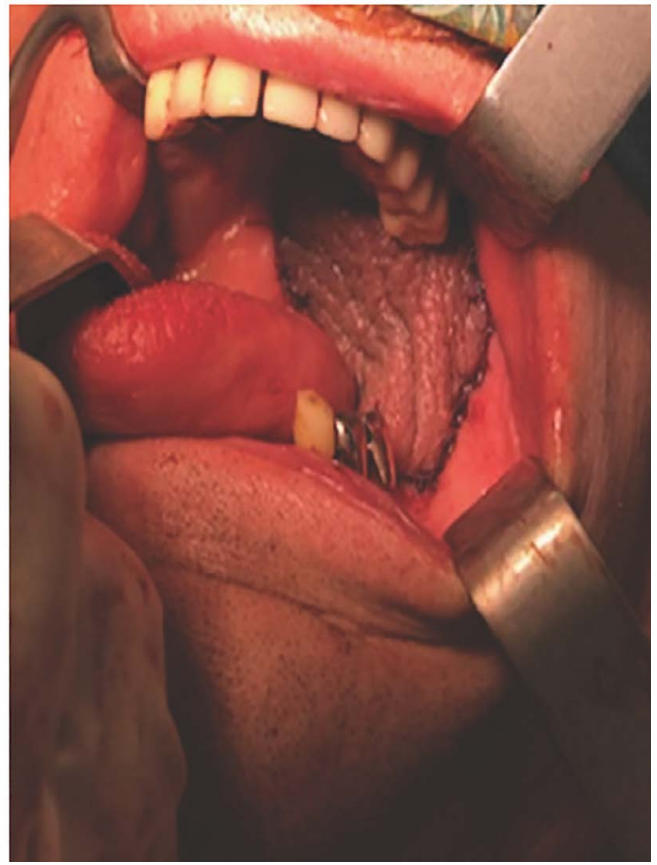


FIGURE 4 Postoperative result. Super thin external pudendal artery flap (STEPA) flap inset in the defect after sutures

The surgical technique is simple and quick. The pedicle vessels have a satisfactory diameter, 2.81 mm for the external pudendal artery at its base and 4.44 mm for the external pudendal vein, with a pedicle length up to 11 cm after dissection within the subcutaneous tissue. The skin is thin and supple, 1.1 mm thick, ideal for cervicofacial reconstructions (Phoon et al., 2014). The absence of functional complication and the aesthetic result concerning the donor site make it a flap with low morbidity in comparison to the radial forearm flap (Benateau et al., 2002).

Regarding the free radial forearm flap, its fineness, flexibility, versatility, low hair growth, pedicle length (7–12 cm; Chen et al., 2005) and reliability (>90% success; Chen et al., 2005; Soutar & Mc Gregor, 1986) make it a choice element in cervicofacial reconstruction. Its primary disadvantage is the morbidity of the donor site, both functionally and aesthetically, with an incidence of complications estimated between 6 and 53% (Bootz & Biesinger, 1991; Loeffelbein et al., 2012; Timmons, Missotten, Poole, & Davies, 1986; Toschka et al., 2001). More than 16% of patients have a functional impact on the mobility of their forearm and/or wrist, more than 28% complain of aesthetic result (Bootz & Biesinger, 1991; Loeffelbein et al., 2012; Timmons et al., 1986; Toschka et al., 2001). Closure of the donor site is carried out most frequently by skin grafting, which may become partially necrotic in 19–53% of cases, with a risk of tendon exposure ranging from 13 to 33% (Lutz, Wei, Chang, Yang, & Chen, 1999).

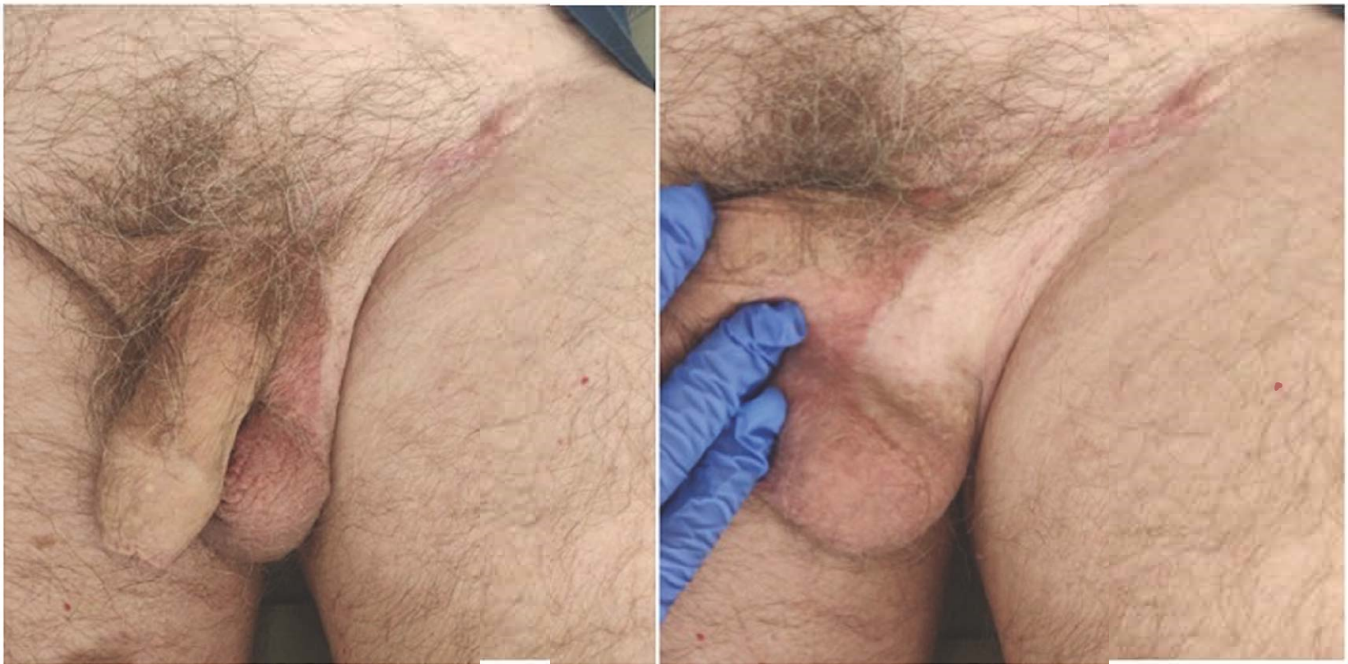

FIGURE 5 Scarring of the donor site at 6 month. Donor site with a good quality scar which is hidden

Problems with localized sensitivity at the donor site and in the sensory area of the radial nerve occur in 7.7 (Meland, Core, Hoverman, Dunet, & Leyder, 1993)–54% (Lutz et al., 1999) of cases and up to 82% at 3 months postoperative (Chen et al., 2005). Functional complications such as stiffness of the wrist with decreased joint range or grip strength may occur, respectively, in more than 26.7% of cases (Lutz et al., 1999) and in 11–40% of cases (Huang, Chen, Huang, Mardini, & Feng, 2003; Timmons et al., 1986). Patients with a radial forearm flap may also have other complications at the donor site such as wrist or hand edema or an intolerance to cold. Regarding cosmetic results, two studies report patient satisfaction in 94.3% (Toschka et al., 2001) and 98% (Lutz et al., 1999) of cases, others are more mixed with 28.4% (Richardson, Fisher, David Vaughan, & Brown, 1997), 24% (Bootz & Biesinger, 1991), and 16.7% (Swanson & MR, 1990) of patients being somewhat dissatisfied to dissatisfied.

In cervicofacial reconstruction, the execution of a radial forearm flap can be carried out simultaneously with the excision of the operative specimen but the proximity of the two sites may constrain surgeons during the ipsilateral lymph node dissection. Another advantage of the STEPA Flap is allowing for more comfortable double team work.

Various studies were carried out in order to simplify closure of the donor site and decrease its morbidity when radial forearm free flap was the procedure of choice. But these flaps designs may involve extensive scars or, as the radial forearm snake free flap, may limit flap length pedicle or skin paddle size (Garg, Wieland, Poore, Sanchez, & Hartig, 2017). The direct closure of the donor site without tension with a hidden scar is one of the main advantages of the STEPA flap.

The primary disadvantages of the STEPA flap are the hairiness of the cutaneous palette, which can hinder the patient during hair

growth, as well as the risk of inguinal lymphedemas, estimated at 10% (Phoon et al., 2014).

The scrotal flap was widely used in urology reconstruction including hypospadias reconstruction or reconstruction of penile after injury. The rate of scrotal surgery complications was well-described in the literature with reported rate of hematoma and infections in 5% and 3.6% of case (Swartz, Morgan, & Krieger, 2007). As in this case, no impairment of erectile function and no impact on testicular function is described at this point in the literature (Phoon et al., 2014; Zhao, Zhang, Yu, & Long, 2009). Although no psychological impact of moving scrotal skin in the mouth was recorded, it needs to be taken into account. Whether hyper-pigmentation could be a problem in facial reconstruction, it is not a disadvantage to be considered in the context of oral cavity reconstruction.

The STEPA flap presents the plastic qualities suitable to cervicofacial reconstruction. The authors believe it may therefore be an alternative to the radial forearm flap in the consideration of reconstruction in a carcinological context, particularly for the oropharynx and oral cavity. However, this is the first STEPA flap used in head and neck surgery. Additional cases are still required to determine the reliability of this flap compared to the radial forearm free flap in particular.

FINANCIAL DISCLOSURE STATEMENT

None.

ORCID

Agnès Dupret-Bories  <https://orcid.org/0000-0002-7068-3500>

REFERENCES

- Benateau, H., Laraba, C., Alix, T., & Compere, J. F. (2002). Radial forearm or Chinese flap. *Revue de Stomatologie et de Chirurgie Maxillo-Faciale*, 103(1), 35-40.
- Bootz, F., & Biesinger, E. (1991). Reduction of complication rate at radial forearm flap donor sites. *ORL*, 53(3), 160-164.
- Chen, C. M., Lin, G. T., Fu, Y. C., Shieh, T. Y., Huang, I. Y., Shen, Y. S., & Chen, C. H. (2005). Complications of free radial forearm flap transfers for head and neck reconstruction. *Oral Surgery, Oral Medicine, Oral Pathology, and Oral Radiology*, 99(6), 671-676.
- Garg, R. K., Wieland, A. M., Poore, S. O., Sanchez, R., & Hartig, G. K. (2017). The radial forearm snake flap: A novel approach to oral cavity and oropharyngeal reconstruction that reduces forearm donor site morbidity. *Microsurgery*, 37(1), 6-11.
- Huang, C., Chen, H., Huang, Y., Mardini, S., & Feng, G. (2003). Comparison of the radial forearm flap and the thinned anterolateral thigh cutaneous flap for reconstruction of tongue defects: An evaluation of donor-site morbidity. *Plastic and Reconstructive Surgery*, 114, 1704-1710.
- Kiranantawat, K., Yeo, M. S. W., Imaizumi, A., Sitpahul, N., Ciudad, P., Nicoli, F., ... Chatdokmaiprai, C. (2018). The scrotal free flap: First successful clinical application of a free super-thin external Pudendal artery (STEPA) flap for reconstruction of a foot defect. *Journal of Plastic, Reconstructive & Aesthetic Surgery*, 71(2), 262-264.
- Loeffelbein, D. J., Al-Benna, S., Steinsträßer, L., Satanovskij, R. M., Rohleder, N. H., Mücke, T., ... Kesting, M. R. (2012). Reduction of donor site morbidity of free radial forearm flaps: What level of evidence is available? *Eplasty*, 12, e9.
- Lutz, B. S., Wei, F. C., Chang, S. C. N., Yang, K. H., & Chen, I. (1999). Donor site morbidity after suprafascial elevation of the radial forearm flap: A prospective study in 95 consecutive cases. *Plastic and Reconstructive Surgery*, 103(1), 132-137.
- Meland, N. B., Core, G. B., Hoverman, V. R., Dunet, É., & Leyder, P. (1993). The radial forearm flap donor site. *Plastic and Reconstructive Surgery*, 91(Supplement), 865-870.
- Orlik, J. R., Horwich, P., Bartlett, C., Trites, J., Hart, R., & Taylor, S. M. (2014). Long-term functional donor site morbidity of the free radial forearm flap in head and neck cancer survivors. *Journal of Otolaryngology - Head & Neck Surgery*, 43, 1-7.
- Phoon, A. F., Shah, A. K., Cormack, G. C., & Saint-Cyr, M. (2014). The super thin external pudendal artery (STEPA) flap. *Journal of Plastic, Reconstructive & Aesthetic Surgery*, 67(10), 1397-1406.
- Richardson, D., Fisher, S. E., David Vaughan, E., & Brown, J. S. (1997). Radial forearm flap donor-site complications and morbidity: A prospective study. *Plastic and Reconstructive Surgery*, 99(1), 109-115.
- Soutar, D. S., & Mc Gregor, I. A. (1986). The radial forearm flap in intraoral reconstruction: The experience of 60 consecutive cases. *Plastic and Reconstructive Surgery*, 78(1), 1-8.
- Swanson, E., & MR, B. J. B. (1990). The radial forearm flap: Reconstructive applications and donor-site defects in 35 consecutive patients. *Plastic and Reconstructive Surgery*, 85(2), 258-266.
- Swartz, M. A., Morgan, T. M., & Krieger, J. N. (2007). Complications of scrotal surgery for benign conditions. *Urology*, 69(4), 616-619.
- Timmons, M. J., Missotten, F. E. M., Poole, M. D., & Davies, D. M. (1986). Complications of radial forearm flap donor sites. *British Journal of Plastic Surgery*, 39(2), 176-178.
- Toschka, H., Feifel, H., Eri, H., Minkenberg, R., Paar, O., Riediger, D. (2001). Aesthetic and functional results of harvesting radial forearm flap, especially with regard to hand function. *International Journal of Oral and Maxillofacial Surgery*, 30, 42-48.
- Zhao, Y. Q., Zhang, J., Yu, M. S., & Long, D. C. (2009). Functional restoration of penis with partial defect by scrotal skin flap. *The Journal of Urology*, 182(5), 2358-2361.

How to cite this article: Dupret-Bories A, Roumiguie M, De Bonnacaze G, et al. The super thin external pudendal artery (STEPA) free flap for oropharyngeal reconstruction - A case report. *Microsurgery*. 2019;39:758-762. <https://doi.org/10.1002/micr.30512>