



HAL
open science

Efficacy of low-level laser therapy in management of symptomatic oral lichen planus: a systematic review

Sadeq Ali Al-Maweri, Hashem Motahir Al-Shamiri, Mohammed Sultan Alakhali, Sadeq Ali Al-Maweri, Butchibabu Kalakonda, Walid A Al-Soneidar, Hashem Motahir Al-Shamiri, Mohammed Sultan Alakhali, Nader Alaizari

► **To cite this version:**

Sadeq Ali Al-Maweri, Hashem Motahir Al-Shamiri, Mohammed Sultan Alakhali, Sadeq Ali Al-Maweri, Butchibabu Kalakonda, et al.. Efficacy of low-level laser therapy in management of symptomatic oral lichen planus: a systematic review. *Lasers in Medical Science*, 2017, 32 (6), pp.1429-1437. 10.1007/s10103-017-2233-7 . hal-03168669

HAL Id: hal-03168669

<https://hal.science/hal-03168669v1>

Submitted on 14 Mar 2021

HAL is a multi-disciplinary open access archive for the deposit and dissemination of scientific research documents, whether they are published or not. The documents may come from teaching and research institutions in France or abroad, or from public or private research centers.

L'archive ouverte pluridisciplinaire **HAL**, est destinée au dépôt et à la diffusion de documents scientifiques de niveau recherche, publiés ou non, émanant des établissements d'enseignement et de recherche français ou étrangers, des laboratoires publics ou privés.

Efficacy of low-level laser therapy in management of symptomatic oral lichen planus: a systematic review


Sadeq Ali Al-Maweri, Butchibabu Kalakonda, Walid A. Al-Soneidar, Hashem Motahir Al-Shamiri, Mohammed Sultan Alakhali, et al

Lasers in Medical Science

ISSN 0268-8921

Lasers Med Sci

DOI 10.1007/s10103-017-2233-7



Your article is protected by copyright and all rights are held exclusively by Springer-Verlag London. This e-offprint is for personal use only and shall not be self-archived in electronic repositories. If you wish to self-archive your article, please use the accepted manuscript version for posting on your own website. You may further deposit the accepted manuscript version in any repository, provided it is only made publicly available 12 months after official publication or later and provided acknowledgement is given to the original source of publication and a link is inserted to the published article on Springer's website. The link must be accompanied by the following text: "The final publication is available at link.springer.com".

Efficacy of low-level laser therapy in management of symptomatic oral lichen planus: a systematic review

Sadeq Ali Al-Maweri^{1,2} · Butchibabu Kalakonda³ · Walid A. Al-Soneidar^{4,5} · Hashem Motahir Al-Shamiri⁶ · Mohammed Sultan Alakhali⁷ · Nader Alaizari¹

Received: 7 February 2017 / Accepted: 12 May 2017
© Springer-Verlag London 2017

Abstract Oral lichen planus (OLP) is a chronic inflammatory disease of unknown etiology and indefinite cure. This systematic review assessed the efficacy of low-level laser therapy in the treatment of symptomatic OLP. Electronic databases (PubMed, Scopus, and Web of Science) were searched from date of inception till and including December 2016, using various combinations of the following keywords: oral lichen planus, laser therapy, low-level laser therapy, and phototherapy. Owing to heterogeneity of data, no statistical analyses were conducted. Initially, 227 publications were identified. After selection, only six studies were included in this systematic review. In these studies, the laser wavelengths, power output, and duration of irradiation ranged between 630–980 nm, 20–300 mW, and 10 s–15 min, respectively. All of the included studies found laser to be effective in management of OLP, without any reported adverse effects. The results of the included studies confirm that low-level laser therapy is effective in management of symptomatic OLP and can be used as an alternative to corticosteroids. However, due to

variety of methods and substantial variations in laser parameters among these studies, more randomized clinical trials with large sample sizes are highly warranted.

Keywords Laser therapy · Oral lichen planus · Management · Efficacy

Introduction

Oral lichen planus (OLP) is a relatively common chronic mucocutaneous disorder that affects 0.5–2% of the general population [1]. It usually affects individuals between the ages of 30–65 years, with a slight female predisposition [1, 2]. Buccal mucosa is the most common site of OLP followed by tongue and gingiva, but any site of the mucosa can be affected. Clinically, OLP is classified as reticular, papule, bullous,

✉ Sadeq Ali Al-Maweri
Sadali05@hotmail.com

Butchibabu Kalakonda
docbutchi@gmail.com

Walid A. Al-Soneidar
walid.soneidar@unc.edu

Hashem Motahir Al-Shamiri
hashem_alshamiri@yahoo.com

Mohammed Sultan Alakhali
alakhali_ms@hotmail.com

Nader Alaizari
dr2007nader@yahoo.com

¹ Department of Oral Medicine and Diagnostic Sciences, Al-Farabi Colleges, Riyadh, Saudi Arabia

² Department of Oral Medicine, Faculty of Dentistry, Sana'a University, Sana'a, Yemen

³ Department of Preventive Dental Sciences, Al-Farabi Colleges, Riyadh, Saudi Arabia

⁴ Department of Epidemiology, Gillings School of Global Public Health, Chapel Hill, NC, USA

⁵ Department of Dental Ecology, School of Dentistry, University of North Carolina, Chapel Hill, NC, USA

⁶ Department of Oral and Maxillofacial Surgery, Al-Farabi Colleges, Riyadh, Saudi Arabia

⁷ Department of Periodontology, Faculty of Dentistry, Jazan University, Jazan, Saudi Arabia

plaque-type, atrophic, and erosive [2]. The reticular form is the most common form; it is mostly asymptomatic and requires no treatment. In contrast, atrophic-erosive forms usually present erythematous, ulcerative areas causing symptoms, ranging from mild burning sensation to severe pain, interfering with eating and speaking [1, 2]; it greatly affects patients' quality of life that requires medical intervention. Additionally, OLP is considered a potentially malignant disorder with estimated transformation rate of 1.09%, with higher risk among those with atrophic-erosive lesions [3].

Although the exact etiopathogenesis of OLP is still unclear, current evidence supports an inflammatory cell-mediated immune response to an unknown trigger [1]. Factors reportedly associated with OLP include dental materials, systemic diseases, as well as medications, stress, viruses and genetic susceptibility [4–6].

Given the obscure etiology, there is no specific therapy for OLP as yet and the treatment is usually symptomatic and without a definite cure. Therapies that have been used for treatment of OLP include corticosteroids such as clobetasol; topical calcineurin inhibitors such as tacrolimus; topical and systemic retinoids such as tretinoin; and immunosuppressants such as azathioprine [1, 2, 7]. Non-pharmacological modalities include cryotherapy, photodynamic therapy and surgical excision [2]. Topical and systemic corticosteroids are the most widely accepted treatment option for OLP [2]. However, due to the chronic nature of OLP, long-term use of corticosteroids has numerous disadvantages that include mucosal thinning, secondary candidiasis, adrenal insufficiency, patient compliance with the treatment, and discomfort during application [7]. Moreover, some cases remain refractory to steroid therapy.

The use of low-level laser therapy (LLLT) as an alternative modality for treatment of OLP has been of great interest in the recent years. LLLT, also known as photobiomodulation, is a non-pharmacological, non-invasive clinical application, which has potential analgesic, anti-inflammatory, immunomodulatory, and biostimulating effects, with minimum adverse effects [8–12]. Numerous studies have evaluated the efficacy of laser in treatment of symptomatic OLP [8, 13–17]. Dillenburg et al. [8] reported significantly better improvement in signs and symptoms of OLP with less recurrence rate among laser-treated group compared to clobetasol group. Additionally, Jajram et al. [5], reported that laser therapy was as effective as dexamethasone in the treatment of OLP without any reported side effects. On the other hand, Kazancioglu and Erisen [16] found that corticosteroids and ozone to be more effective in pain alleviation and clinical improvement in patients with erosive OLP than laser therapy. There seems to be some controversy regarding the efficacy of laser therapy in management of OLP. Therefore, the purpose of this review was to systematically evaluate the evidence on the efficacy of low-level laser therapy in the management of symptomatic OLP.

Materials and methods

Focused question

We constructed our research question using the guidelines of Preferred Reporting Items for Systematic Review and Meta-Analysis (PRISMA) and according to the Participants, Interventions, Control, and Outcomes (PICO) principle. The focused question of interest was “Is laser therapy effective in treatment of symptomatic OLP?”.

Eligibility criteria

The eligibility criteria were as follows: all controlled clinical studies that assessed the effects of LLLT on pain reduction and/or clinical improvement in patients with symptomatic OLP. Additionally, studies were included only if the diagnosis of OLP had been confirmed histopathologically. Case reports, case series, review papers, letters to the editor, monographs, conference papers, unpublished data, and studies published in a language other than English were excluded from the study.

Literature search

A literature search of the electronic databases (MEDLINE/PubMed, Scopus, and Web of Science [ISI]) was performed to identify relevant articles published in English up to December 2016, using combinations of the following keywords: oral lichen planus, laser therapy, laser treatment, diode laser, low level laser therapy, low-level laser therapy, low energy laser therapy, and phototherapy. Titles and abstracts of retrieved articles were screened for eligibility by two independent authors (SA and BK), and irrelevant studies were excluded. Full texts of articles obtained from the previous step were then read and assessed by the two authors for inclusion. Moreover, the reference lists of relevant articles were manually searched for additional studies. The initial aim was to conduct a meta-analysis but owing to inconsistency of data and heterogeneity of the included studies, no statistical analysis was performed.

Assessment of quality

The quality of the included studies was assessed independently by two authors according to the revised recommendation of the CONSORT statement (Table 1). After scores were calculated, an overall estimation risk of bias (low, all criteria met; moderate, one or more criteria partly met; or high, one or more criteria were not met) was performed for each selected study.

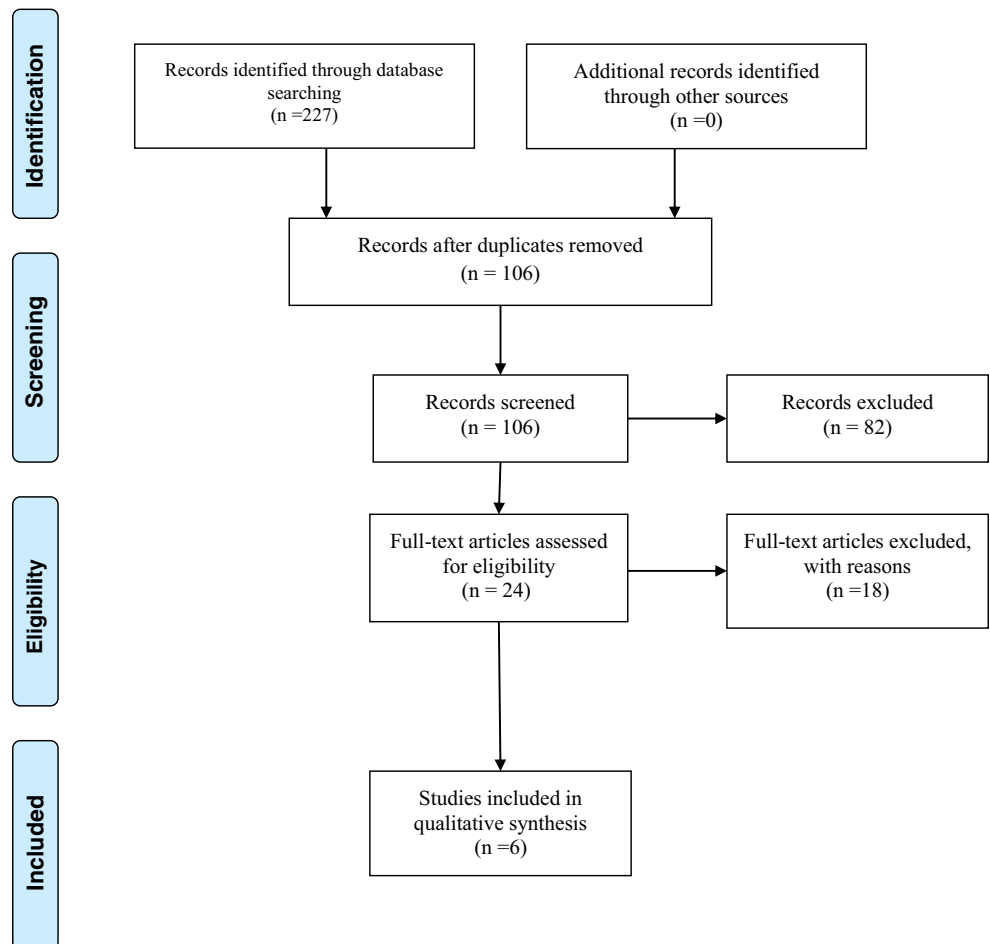
Data extraction

The following data were extracted from the included articles by two independent authors using a standardized data

Table 1 Categories for assessing the quality of selected studies

Category	Description	Grading
A	Sample size calculation, estimating the minimum number of participants required to detect a significant difference among compared groups	0 = did not exist/not mentioned/not clear 1 = reported but not confirmed 2 = reported and confirmed
B	Randomization and allocation concealment methods	0 = clearly inadequate 1 = possibly adequate 2 = clearly adequate
C	Clear definition of inclusion and/or exclusion criteria	0 = no 1 = yes
D	Completeness of follow-up (specified reasons for withdrawals and dropouts in each study group)	0 = no/not mentioned/not clear 1 = yes/no withdrawals or dropouts occurred
E	Experimental and control groups comparable at study baseline for important prognostic factors	0 = no 1 = unclear/possibly not comparable for one or more important prognostic factors 2 = clearly adequate
F	Presence of masking	0 = no 1 = unclear/not complete 2 = yes
G	Appropriate statistical analysis	0 = no 1 = unclear/possibly not the best method applied 2 = yes

Fig. 1 Flowchart of methodology according to PRISMA guidelines



collection form: authors and year of study, study design, number of patients, gender, mean age, site of lesion, outcome, type of laser, wavelength, power output, exposure time, number of sessions, follow-up, and outcomes.

Results

Study selection

Figure 1 illustrates the study search strategy flowchart according to PRISMA guidelines. The initial search resulted in 227 articles, of which 121 were duplicates and were thus excluded. After evaluation of titles and abstracts, 97 were found irrelevant and thus excluded, and a total of 24 articles were selected for thorough full text reading. Of these, 24 articles, 18 did not meet the eligibility criteria and were thus excluded. Table 1 provides a list of excluded studies and the reasons for exclusion. The remaining six studies [8, 13–17] were included in the systematic review and processed for data extraction.

General characteristics of included studies

Study design, sample size, gender distribution, type of intervention, and control of each study are summarized and illustrated in Table 2. All the included studies were controlled clinical studies comparing the effect of laser with either a placebo or another type of treatment. Among these, four were randomized clinical studies [8, 13, 15, 16]. In all studies [8,

13–17], diagnoses of lichen planus were based on clinical and histopathological findings. The buccal mucosa and tongue were the most common sites of OLP. Two studies were conducted in Egypt [14, 17], two in Iran [13, 15], one in Turkey [16], and one in Brazil [8]. The number of subjects included in the intervention ranged between 23 and 120, with mean age ranging from 42.6 to 59.7 years. One study [15] did not report gender of the subjects, while in the remaining five studies, majority of the subjects were females.

Four studies [8, 14, 15, 17] compared the efficacy of diode laser with corticosteroids; one study [16] compared diode laser to three therapies: ozone, corticosteroid, and a placebo; and one study [13] compared the efficacy of diode laser to CO₂ laser surgery. All the studies assessed the effect of LLLT on pain alleviation and clinical improvement in patients with symptomatic OLP. One study [8] also evaluated both recurrence rate of the lesion and levels of anxiety, and one study [17] assessed the serum proinflammatory mediators. In the studies that assessed symptoms [8, 13–16], pain was measured by Visual Analogue Scale (VAS). Two studies [8, 13] used Thongprasom sign scoring to evaluate the clinical improvement of OLP while three studies [15–17] used reticular, atrophic, and erosive score (RAE score). Four studies [8, 13, 15, 16] reported follow-up period, which ranged from 2 to 12 months.

Laser related characteristics of included studies

There was a great variation in the laser parameters used in the included studies. In all six studies, diode laser was used with wavelengths ranging from 630 to 970 nm (nm) and power output ranging from 10 mW to 3 W. Four studies [8, 13, 15, 16] reported fluence of laser energy that ranged from 0.3 up to 6 J/cm².

Power density was reported by three studies [8, 15, 16] that ranged between 10 and 1000 mW/cm². The reported exposure time was between 5 s and 8 min. Only three studies [8, 15, 16] reported the exposed surface area, which ranged between 0.04 to 1 cm². The number of reported laser sessions ranged from 4 to 12 sessions.

Main outcomes

All studies [8, 13–17] reported LLLT to be effective in reducing signs and symptoms of OLP. One study [8] showed significantly better improvement in signs and symptoms of OLP among laser-treated group compared to clobetasol. Another study [13] found LLLT to be more effective in pain reduction and healing of OLP as compared to CO₂ laser surgery. In contrast, in two studies [14, 16], the reported improvement in signs and symptoms of OLP was found to be significantly better among corticosteroid groups as compared to laser group, and in two other studies [15, 17], laser was found as

Table 2 List of excluded studies and reasons for exclusion

Study	Reason for exclusion
Cafaro et al. [18]	Case series
Cafaro et al. [11]	Case series
van der Hem et al. [19]	Case series
Passeron et al. [20]	Case series
Fomaini et al. [21]	Case report
Mahdavi et al. [22]	Case report
Misra et al. [23]	Case report
Fomaini [24]	Case series
Elshenawy et al. [25]	No controls
Pakfetrat et al. [26]	No controls
Kollner et al. [27]	No controls
Loh [28]	No controls
Trehan and Taylor [29]	No controls
Huerta Leteurtre et al. [30]	No controls
Hu and Liu [31]	Not in English
Pavlic et al. [32]	Review
Sharma et al. [33]	Case series
Thongprasom et al. [34]	Case report

effective as corticosteroids in reduction of signs and symptoms of OLP.

Dillenburg et al. [8] assessed the efficacy of LLLT in management of OLP. Around 42 patients with atrophic/erosive OLP were randomly allocated in two groups: one group received laser therapy (3 times/a week), while the other received topical clobetasol (clobetasol propionate gel 0.05%, 3 times/day). Laser group showed significantly better improvement in all variables (pain scores, clinical scores, functional scores, anxiety scores) compared to the clobetasol group. Moreover, complete clinical resolution at day 30 was observed in 61.9% of laser group versus 28.6% of clobetasol group, and the recurrence rate at follow-up time was significantly less in the laser group compared to the clobetasol group (4.8 versus 47.6%). Additionally, three patients of the clobetasol group reported transit local burning sensation immediately after the first 2 days of treatment and two complained of gastrointestinal disorder, for whom omeprazole was prescribed. In contrast, no side effects were reported among the laser-treated group [8].

Kazancioglu and Erisen [16] evaluated the efficacy of LLLT in management of OLP patients. One hundred and twenty patients with erosive-atrophic OLP were randomly allocated into four groups: one group received LLLT; one received topical corticosteroid; one received ozone; and the fourth group received placebo treatment. The authors found that the sign scores of OLP decreased in all scoring groups, but statistically significant improvement was found in the ozonated and corticosteroid-treated groups. Also, pain alleviation was reported after treatment with LLLT, ozone, and corticosteroids [16].

Jajram et al. [15] treated 30 patients with erosive-atrophic OLP, randomly divided into two groups: one group received laser therapy (630 nm diode laser), while the other group received corticosteroid (dexamethasone mouth wash). The results showed that the laser group and the corticosteroid group showed a significant improvement in signs and symptoms of OLP, with no significant differences between the two groups. The authors concluded that laser therapy is as effective as corticosteroids in management of OLP [15].

Othman et al. [17] evaluated the effect of laser on clinical signs and level of serum pro-inflammatory tumor necrosis factor- α (TNF- α) among OLP patients (Table 3). Subjects were divided into two groups, laser group and topical steroids group. The authors reported a great reduction in size of the lesions and serum TNF- α in both groups, with significant differences in favor of the steroid group.

Quality of the included studies

The results of the CONSORT-based quality analysis are presented in Table 4. Only one study was at moderate risk bias while the remaining five studies were at high risk bias. The

Table 3 General characteristics of the included studies

Author	Study type	Study control	NO. of subjects	Mean age (years) (range)	Gender	Type of LP	Follow-up (month)	Evaluation methods	Outcome
Othman et al. [17]	CT	Triamcinolone	24	(35–70)	F: 18 M: 6	Erosive-atrophic Reticular	NA	TNF- α , clinically	Improvement in signs of the disease, with no differences between the two groups
Kazancioglu and Erisen [16]	RCT	G1: Ozone G2: Dexamethasone	120	42.6 (28–55)	F: 64 M: 56	Erosive-atrophic	6	VAS, clinically	Improvement in all groups but significantly better in Ozone and steroid groups
Dillenburg et al. [8]	RCT	G3: Placebo G3: clobetasol	42	58.2	F: 35 M: 7	Erosive-atrophic Reticular	2	BAS, VAS, clinically FS	Laser was more effective ($P < 0.01$)
El Shenawy and Eldin [14]	CT	Triamcinolone	24	53.6	F: 18 M: 6	Erosive-atrophic	NA	VAS	A significant improvement in control group than laser group ($P < 0.05$)
Jajarm et al. [15]	RCT	Cortico-steroid	30	>20	NA	Erosive-atrophic	12	VAS, clinically	Laser was as effective as dexamethasone
Agha-Hosseini et al. [13]	RCT	CO ₂ laser surgery	28	50.7	F: 21 M: 7	Erosive-atrophic	3	VAS, clinically	Laser-treated group showed better improvement than CO ₂ group ($P < 0.01$)

CR controlled trials, RCT randomized controlled trials, BAS Beck anxiety scale, VAS Visual Analogue Scale, RR recurrence rate, FS functional scores, NA not applicable

Table 4 Laser parameters of the included studies

Author	Source	Wavelength (nm)	Energy density (fluence) (J/cm^2)	Power output (W/mW)	Power density (mW/cm^2)	Duration of irradiation	Laser schedule session/week (total sessions)	Spot size (cm^2)
Othman et al. [17]	Diode laser	970		2 W	NA	8 m	Twice a week (10 sessions)	NA
Kazancioglu and Erisen [16]	Diode laser	808	1.5	0.1 W	10	2.5 m	Twice a week (10 sessions)	1
Dillenburg et al. [8]	Diode laser (red)	660	6	40 mW	1000	6 s	3 sessions/week (12 sessions)	0.04
El Shenawy and Eldin [14]	Diode laser	970	NA	3 W	NA	8 m	Twice/week (maximum 10 sessions)	NA
Jajarm et al. [15]	Diode laser	630	1.5	10 mW	10	2.5 m	Twice/week (10 sessions)	1
Agha-Hosseini et al. [13]	Diode laser	633; 890	0.3–0.5	NA	NA	5 s	5 sessions every other day	

NA not applicable

most common unmet criteria were the lack of a sample size calculation (criterion A), unreported methods of randomization (criterion B), and lack of masking (criterion F).

Discussion

In recent years, advancement of lasers in dentistry has promoted the use of LLLT as a viable treatment modality in OLP. The present systematic review was envisioned to address a focused research question related to the efficacy of LLLT in the management of symptomatic OLP. A thorough review of the included studies revealed that LLLT was effective in management of symptomatic lichen planus. However, due to the wide heterogeneity of study designs, laser parameters, and treatment outcomes in these studies, the result of this systematic review should not be considered as a definitive conclusion and should be interpreted cautiously.

The primary objective of this systematic review was to evaluate the efficacy of LLLT in the treatment of symptomatic OLP. Efficacy of LLLT is regulated by various factors such as wavelength, power output, energy density, treatment duration, and the mode of operation. Of all these factors, dose of applied LLLT at the desired area is of paramount importance. However, considering the diversity in laser parameters, an accurate effective dose has not yet been established. Analysis of the available literature found that doses between 0.001 to 10 J/cm^2 provide the ideal therapeutic window for biostimulation [35]. Eventually, a treatment dose of 2 to 3 J/cm^2 was determined effective for gingival tissues to initiate the desired biologic effects [36]. The studies that were included as a part of this review employed doses between 0.3 and 6 J/cm^2 . Though the dose range falls within the dose suggested for biostimulation, yet there was a wide variation in the dose of LLLT used in these studies. Further, there was a substantial variation in other laser parameters, such as wavelength (630–970 nm), power output (10 mW–3 W), power density (10–1000 mW/cm^2), and duration of radiation varying from 5 s to 8 min. Despite this wide dissimilarity, all these studies have concluded LLLT to be effective in the treatment of OLP.

The relative efficacy of LLLT over other conventional methods of treatment is justified only through inclusion of studies with good methodological quality. Extensive search of literature was performed and after careful deliberation, certain studies were excluded (Table 2). Only a few studies that met the inclusion criteria were shortlisted. However, a CONSORT-based quality analysis of the included studies showed a high risk of bias (Table 5). A major drawback was that most of the studies [13–17] had failed to explain the sample size calculation and substantiate the number of participants required to detect the significant difference between

Table 5 CONSORT-based quality analysis of the included studies

Study	A (0–2)	B (0–2)	C (0–1)	D (0–1)	E (0–2)	F (0–2)	G (0–2)	Estimated risk of bias
Othman et al. [17]	0	0	1	1	2	0	2	High
Kazancioglu and Erisen [16]	0	1	1	1	2	2	2	High
El Shenawy and Eldin [14]	0	0	1	1	2	0	2	High
Dillenburg et al. [8]	1	2	1	1	2	2	2	Moderate
Jajarm et al. [15]	0	1	1	1	1	0	2	High
Agha-Hosseini et al. [13]	0	2	1	1	2	0	1	High

groups. Furthermore, unreported methods of randomization and allocation concealment could have been insufficient to yield unbiased results in these studies. These methodological shortcomings and discordance among the study designs were considered a limitation to validate the supremacy of LLLT over other conventional methods.

The primary outcome considered in this review was the relief of symptoms (pain) associated with OL. The studies included in this review have used VAS, a reliable non-verbal scale to assess pain in clinical setting. An independent analysis of the VAS scores in these studies had revealed that LLLT was effective in pain reduction in patients with OLP. The secondary outcome related to the use of LLLT in OLP was clinical improvement, reflected by a reduction in sign scores. The studies included in this review have used Thongprasom sign scoring [8, 13] and RAE score [15–17] to evaluate the clinical improvement during follow-up period. Analysis of the studies revealed that LLLT was as effective and comparable to other methods in reduction of sign scores and was supportive of clinical improvement in OLP. The reduction in sign and symptoms scores by LLLT in our review has been corroborated by successful use of LLLT in various applications: aphthous stomatitis [37], burning mouth syndrome [9], and cancer therapy-induced mucositis [38].

The potential effects of LLLTs in reduction of signs (clinical appearance) and symptoms (pain) in OLP can be credited to various mechanisms. LLLT plays a pivotal role in the production of β -endorphins and enkephalins and reduction in levels of bradykinin and histamine, thereby contributing to an analgesic effect and pain relief. The analgesic effect of LLLT is also corroborated by its action on the C fibers, decreasing their activity and leading to a reduction in conductance of pain stimuli [39]. The reduction in clinical signs of OLP after LLLT could be explained by its biological activity in enhancing increased proliferation, differentiation, and migration of fibroblasts and stimulation of epithelial cells, which are considered key contributors in the healing process of oral mucosa [37]. Additionally, LLLT plays a crucial role in immunomodulation. Modulation of mast cell function by LLLT enhances the release of leucocytes into oral tissues,

thereby playing a key role in control of oral mucosa inflammation [40].

A major advantage of LLLT over other conventional methods such as corticosteroids is its safety and the absence of any adverse effects. One of the included studies [8] that used corticosteroid has reported severe adverse effects such as burning sensation and gastrointestinal upset. The chronic nature of OLP necessitates the use of corticosteroids on a long-term basis resulting in numerous adverse effects such as mucosal atrophy, secondary candidiasis, and adrenal insufficiency and limits their use in hypertensive or diabetic patients [7, 8]. Hence, LLLT can be considered as a viable alternative in these patients.

There were certain limitations in this systematic review. The primary limitation was associated to the methodological weaknesses of the included studies such as relative small sample size, inadequate methods of randomization, and poor masking standards. The second obvious limitation was the lack of consensus on the ideal laser wavelength and uniformity related to suitable dose of LLLT among clinicians, which lead to a substantial variation of laser parameters, which in turn resulted in poor interpretive quality between these studies. Further, heterogeneity of data made it difficult to pool data from all these studies and consider this review for further meta-analysis. Another important limitation is related to follow-up period. Some of the studies [8, 13] had a short follow-up period of less than 3 months whereas other studies [14, 17] did not clearly report the follow-up period. Considering the chronic nature of OLP and its recurrence rate, some of these studies with ill-defined or short follow-up might have some degree of information bias or out-of-context conclusions.

Suggested recommendations for future research include the incorporation of well-designed randomized controlled trials with sufficient sample size and long-term follow-up along with inclusion of standard laser parameters with appropriate dose. These measures would validate the evidence of LLLT use in OLP treatment and minimize the risk of measurement bias. Future studies and further research could substantiate the role of LLLT as a viable alternative option in the treatment of OLP.

Compliance with ethical standards

Conflict of interest The authors declare that they have no conflict of interest.

Ethical approval This study was approved by the ethical committee at Al-Farabi Colleges for Dentistry and Nursing, Riyadh, Saudi Arabia. Since this is a systematic review article, no consent form was required. Moreover, this article does not comprise any studies with human subjects or animals conducted by any of the authors.

Funding This study was self-funded by the authors.

References

- Payeras MR, Cherubini K, Figueiredo MA, Salum FG (2013) Oral lichen planus: focus on etiopathogenesis. *Arch Oral Biol* 58(9):1057–1069. doi:10.1016/j.archoralbio.2013.04.004
- Yang H, Wu Y, Ma H, Jiang L, Zeng X, Dan H, Zhou Y, Chen Q (2016) Possible alternative therapies for oral lichen planus cases refractory to steroid therapies. *Oral Surg Oral Med Oral Pathol Oral Radiol* 121(5):496–509. doi:10.1016/j.oooo.2016.02.002
- Warnakulasuriya S, Johnson NW, van der Waal I (2007) Nomenclature and classification of potentially malignant disorders of the oral mucosa. *J Oral Pathol Med* 36(10):575–580. doi:10.1111/j.1600-0714.2007.00582.x
- Alaizari NA, Al-Maweri SA, Al-Shamiri HM, Tarakji B, Shugaa-Addin B (2016) Hepatitis C virus infections in oral lichen planus: a systematic review and meta-analysis. *Aust Dent J* 61(3):282–287. doi:10.1111/adj.12382
- Farhi D, Dupin N (2010) Pathophysiology, etiologic factors, and clinical management of oral lichen planus, part I: facts and controversies. *Clin Dermatol* 28(1):100–108. doi:10.1016/j.clindermatol.2009.03.004
- Saini R, Al-Maweri SA, Saini D, Ismail NM, Ismail AR (2010) Oral mucosal lesions in non oral habit diabetic patients and association of diabetes mellitus with oral precancerous lesions. *Diabetes Res Clin Pract* 89(3):320–326. doi:10.1016/j.diabres.2010.04.016
- Chamani G, Rad M, Zarei MR, Lotfi S, Sadeghi M, Ahmadi Z (2015) Efficacy of tacrolimus and clobetasol in the treatment of oral lichen planus: a systematic review and meta-analysis. *Int J Dermatol* 54(9):996–1004. doi:10.1111/ijd.12925
- Dillenburg CS, Martins MA, Munerato MC, Marques MM, Carrard VC, Sant'Ana Filho M, Castilho RM, Martins MD (2014) Efficacy of laser phototherapy in comparison to topical clobetasol for the treatment of oral lichen planus: a randomized controlled trial. *J Biomed Opt* 19(6):068002. doi:10.1117/1.jbo.19.6.068002
- Al-Maweri SA, Javed F, Kalakonda B, Alaizari NA, Al-Soneidar W, Al-Akwa A (2017) Efficacy of low level laser therapy in the treatment of burning mouth syndrome: a systematic review. *Photodiagnosis Photodyn Ther* 17:188–193. doi:10.1016/j.pdpdt.2016.11.017
- Pandeshwar P, Roa MD, Das R, Shastry SP, Kaul R, Srinivasreddy MB (2016) Photobiomodulation in oral medicine: a review. *J Investig Clin Dent* 7(2):114–126. doi:10.1111/jicd.12148
- Cafaro A, Arduino PG, Massolini G, Romagnoli E, Broccoletti R (2014) Clinical evaluation of the efficiency of low-level laser therapy for oral lichen planus: a prospective case series. *Lasers Med Sci* 29(1):185–190. doi:10.1007/s10103-013-1313-6
- Abduljabbar T, Javed F, Shah A, Samer MS, Vohra F, Akram Z (2017) Role of lasers as an adjunct to scaling and root planning in patients with type 2 diabetes mellitus: a systematic review. *Lasers Med Sci* 32(2):449–459. doi:10.1007/s10103-016-2086-5
- Agha-Hosseini F, Moslemi E, Mirzaii-Dizgah I (2012) Comparative evaluation of low-level laser and CO(2) laser in treatment of patients with oral lichen planus. *Int J Oral Maxillofac Surg* 41(10):1265–1269. doi:10.1016/j.ijom.2012.06.001
- El Shenawy HM, Eldin AM (2015) A comparative evaluation of low-level laser and topical steroid therapies for the treatment of erosive-atrophic lichen planus. *Open Access Maced J Med Sci* 3(3):462–466. doi:10.3889/oamjms.2015.072
- Jajarm HH, Falaki F, Mahdavi O (2011) A comparative pilot study of low intensity laser versus topical corticosteroids in the treatment of erosive-atrophic oral lichen planus. *Photomed Laser Surg* 29(6):421–425. doi:10.1089/pho.2010.2876
- Kazancioglu HO, Erisen M (2015) Comparison of low-level laser therapy versus ozone therapy in the treatment of oral lichen planus. *Ann Dermatol* 27(5):485–491. doi:10.5021/ad.2015.27.5.485
- Othman NA, Shaker OG, Elshenawy HM, Abd-Elmoniem W, Eldin AM, Fakhr MY (2016) The effect of diode laser and topical steroid on serum level of TNF-alpha in oral lichen planus patients. *J Clin Exp Dent* 8(5):e566–e570. doi:10.4317/jced.52665
- Cafaro A, Albanese G, Arduino PG, Mario C, Massolini G, Mozzati M, Broccoletti R (2010) Effect of low-level laser irradiation on unresponsive oral lichen planus: early preliminary results in 13 patients. *Photomed Laser Surg* 28(Suppl 2):S99–103. doi:10.1089/pho.2009.2655
- van der Hem PS, Egges M, van der Wal JE, Roodenburg JL (2008) CO2 laser evaporation of oral lichen planus. *Int J Oral Maxillofac Surg* 37(7):630–633. doi:10.1016/j.ijom.2008.04.011
- Passeron T, Zakaria W, Ostovari N, Mantoux F, Lacour JP, Ortonne JP (2004) Treatment of erosive oral lichen planus by the 308 nm excimer laser. *Lasers Surg Med* 34(3):205. doi:10.1002/lsm.20016
- Fornaini C, Raybaud H, Augros C, Rocca JP (2012) New clinical approach for use of Er:YAG laser in the surgical treatment of oral lichen planus: a report of two cases. *Photomed Laser Surg* 30(4):234–238. doi:10.1089/pho.2011.3116
- Mahdavi O, Boostani N, Jajarm H, Falaki F, Tabesh A (2013) Use of low level laser therapy for oral lichen planus: report of two cases. *J Dent (Shiraz, Iran)* 14(4):201–204
- Misra N, Chittoria N, Umapathy D, Misra P (2013) Efficacy of diode laser in the management of oral lichen planus. *BMJ Case Reports*. doi:10.1136/bcr-2012-007609
- Fornaini C (2012) LLLT in the symptomatic treatment of oral lichen planus. *Laser Ther* 21(1):51–53. doi:10.5978/islsm.12-CR-03
- Elshenawy HM, Eldin AM, Abdelmonem MA (2015) Clinical assessment of the efficiency of low level laser therapy in the treatment of oral lichen planus. *Open Access Maced J Med Sci* 3(4):717–721. doi:10.3889/oamjms.2015.112
- Pakfetrat A, Falaki F, Ahrari F, Bidad S (2014) Removal of refractory erosive-atrophic lichen planus by the CO2 laser. *Oral Health Dent Manag* 13(3):595–599
- Kollner K, Wimmershoff M, Landthaler M, Hohenleutner U (2003) Treatment of oral lichen planus with the 308-nm UVB excimer laser—early preliminary results in eight patients. *Lasers Surg Med* 33(3):158–160. doi:10.1002/lsm.10202
- Loh HS (1992) A clinical investigation of the management of oral lichen planus with CO 2 laser surgery. *J Clin Laser Med Surg* 10(6):445–449. doi:10.1089/clm.1992.10.445
- Trehan M, Taylor CR (2004) Low-dose excimer 308-nm laser for the treatment of oral lichen planus. *Arch Dermatol* 140(4):415–420. doi:10.1001/archderm.140.4.415
- Huerta Leteurtre N, Bagan Sebastian JV, Cardona Tortajada F, Lloria De Miguel E, Jimenez Soriano Y, Basterra Alegria J (1999) Oral lichen planus plaques and homogeneous leukoplasia: comparative results of treatment with CO2 laser. *Acta Otorrinolaringol Esp* 50(7):543–547
- Hu AP, Liu ZX (2016) Clinical effect of Nd:YAG laser combined with total glucosides of paeony for the treatment of erosive oral

- lichen planus. *Shanghai kou qiang yi xue* = Shanghai journal of stomatology 25(4):481–483
32. Pavlic V, Vujic-Aleksic V (2014) Phototherapy approaches in treatment of oral lichen planus. *Photodermatol Photoimmunol Photomed* 30(1):15–24. doi:[10.1111/phpp.12074](https://doi.org/10.1111/phpp.12074)
 33. Sharma S, Saimbi CS, Koirala B (2008) Erosive oral lichen planus and its management: a case series. *JNMA J Nepal Med Assoc* 47(170):86–90
 34. Thongprasom K, Sessririsombat S, Singkharotai K, Vathanasanti A, Subbalek K (2014) Topical steroids and CO2 laser in the treatment of refractory oral lichenoid drug reaction and lichenoid contact lesion: a case report. *Acta Stomatol Croat* 48(3):224–229. doi:[10.15644/asc48/3/7](https://doi.org/10.15644/asc48/3/7)
 35. Ishii J, Fujita K, Komori T (2003) Laser surgery as a treatment for oral leukoplakia. *Oral Oncol* 39(8):759–769
 36. Sun G, Tuner J (2004) Low-level laser therapy in dentistry. *Dent Clin N Am* 48(4):1061–1076, viii. doi:[10.1016/j.cden.2004.05.004](https://doi.org/10.1016/j.cden.2004.05.004)
 37. Najeeb S, Khurshid Z, Zohaib S, Najeeb B, Qasim SB, Zafar MS (2016) Management of recurrent aphthous ulcers using low-level lasers: a systematic review. *Medicina (Kaunas, Lithuania)* 52(5):263–268. doi:[10.1016/j.medici.2016.07.006](https://doi.org/10.1016/j.medici.2016.07.006)
 38. Bjordal JM, Bensadoun RJ, Tuner J, Frigo L, Gjerde K, Lopes-Martins RA (2011) A systematic review with meta-analysis of the effect of low-level laser therapy (LLLT) in cancer therapy-induced oral mucositis. *Support Care Cancer* 19(8):1069–1077. doi:[10.1007/s00520-011-1202-0](https://doi.org/10.1007/s00520-011-1202-0)
 39. Kalakonda B, Farista S, Koppolu P, Baroudi K, Uppada U, Mishra A, Savarimath A, Lingam AS (2016) Evaluation of patient perceptions after vestibuloplasty procedure: a comparison of diode laser and scalpel techniques. *J Clin Diagn Res* 10(5):Zc96–zc100. doi:[10.7860/jcdr/2016/17623.7820](https://doi.org/10.7860/jcdr/2016/17623.7820)
 40. Walsh LJ (1997) The current status of low level laser therapy in dentistry. Part 1. Soft tissue applications. *Aust Dent J* 42(4):247–254