



HAL
open science

Efficacy and Tolerance of Sirolimus (Rapamycin) for Extracranial Arteriovenous Malformations in Children and Adults

Romain Gabeff, Olivia Boccara, Véronique Soupre, Gérard Lorette, Christine Bodemer, Denis Herbreteau, Elsa Tavernier, Annabel Maruani

► **To cite this version:**

Romain Gabeff, Olivia Boccara, Véronique Soupre, Gérard Lorette, Christine Bodemer, et al.. Efficacy and Tolerance of Sirolimus (Rapamycin) for Extracranial Arteriovenous Malformations in Children and Adults. *Acta Dermato-Venereologica*, 2019, 99 (12), pp.1105-1109. 10.2340/00015555-3273 . hal-03158791

HAL Id: hal-03158791

<https://hal.science/hal-03158791v1>

Submitted on 4 Jun 2024

HAL is a multi-disciplinary open access archive for the deposit and dissemination of scientific research documents, whether they are published or not. The documents may come from teaching and research institutions in France or abroad, or from public or private research centers.

L'archive ouverte pluridisciplinaire **HAL**, est destinée au dépôt et à la diffusion de documents scientifiques de niveau recherche, publiés ou non, émanant des établissements d'enseignement et de recherche français ou étrangers, des laboratoires publics ou privés.



Efficacy and Tolerance of Sirolimus (Rapamycin) for Extracranial Arteriovenous Malformations in Children and Adults

Romain GABEFF^{1-3#}, Olivia BOCCARA^{4#}, Véronique SOUPRE⁵, Gérard LORETTE¹⁻³, Christine BODEMER⁴, Denis HERBRETEAU^{1,2,6}, Elsa TAVERNIER^{7,8} and Annabel MARUANI^{1-3,8}

¹University of Tours, ²Department of Dermatology, Unit of Pediatric Dermatology, ⁶Department of Neuroradiology and Interventional Radiology, CHRU Tours, ³Center of reference for genodermatoses and rare skin diseases (MAGEC), Tours, ⁴Department of Dermatology and Center of reference for genodermatoses and rare skin diseases (MAGEC), University Paris Descartes – Sorbonne Paris Cité, Institute Imagine, ⁵Department of Maxillo-Facial Surgery and Stomatology, University Hospital Necker-Enfants Malades, Paris, ⁷Clinical Investigation Center-INSERM 1415, Tours, and ⁸INSERM 1246-SPHERE, University of Tours and Nantes, France

[#]These authors contributed equally and should be considered as first authors.

Managing extracranial arteriovenous malformations is challenging. Sirolimus (rapamycin) is increasingly being used when surgery and embolization are not advised. Because of its anti-angiogenic properties, here we report all extracranial arteriovenous malformation cases treated with sirolimus in 2 French tertiary centers for vascular anomalies. The outcomes were efficacy (complete, partial, no response) based on arteriovenous malformation volume and necrosis/hemorrhage and side effects. We retrospectively included 10 patients (7 children). The sirolimus dose ranged from 0.6 to 3.5 mg/m². Median (interquartile range [IQR]) treatment time was 24.5 (4.5; 35) months. Five patients showed no response, and 5 showed partial response at a median (IQR) of 3 (1; 5) months, followed in 2 cases by therapeutic resistance (i.e., progressive disease after 9 and 24 months of treatment). The most frequent side effect was mouth ulcers. This study shows poor efficacy of sirolimus for treating extracranial arteriovenous malformations.

Key words: vascular anomaly; arteriovenous malformation; sirolimus; rapamycin.

Accepted Aug 6, 2019; E-published Aug 6, 2019

Acta Derm Venereol 2019; 99: 1105–1109.

Corr: Prof. Annabel Maruani, CHRU Tours, Clocheville Hospital, 9 Boulevard Béranger, FR-37044 Tours, France. E-mail: annabel.maruani@univ-tours.fr

Extracranial arteriovenous malformations (AVMs) are rare, potentially aggressive, congenital, fast-flow vascular anomalies (1). They are characterized by a red, warm, pulsative swelling, mostly located on the extremities and head and neck and that might be asymptomatic or painful (2). The degree of severity is classified by Schöbinger stages: stage I, quiescent forms; stage II, growing phase; stage III, tissue destruction, ulceration, pain and hemorrhage; and stage IV, cardiac overload (3).

Management of extracranial AVMs is challenging, and we lack guidelines for treatment. The evolution of AVMs is unpredictable, even though trauma and hormonal changes during life are risk factors for rapid aggravation (2). When AVMs are not complicated, the “wait and

SIGNIFICANCE

Managing extracranial arteriovenous malformations is challenging. Sirolimus (rapamycin) is increasingly being used in all kinds of vascular anomalies. In this study, we report the largest series of arteriovenous malformations treated with sirolimus, which included 10 patients (7 children). Results suggest a poor efficacy of sirolimus for this condition, with only partial response in 50% of patients, which was transient and lasted several months in 2 of 5 patients, with further worsening.

see” attitude might be relevant. If necessary, therapeutic management results, at best, after multidisciplinary consultations (4, 5), considering arterial embolization alone or followed by radical surgery of the lesion (5, 6). In some cases, embolization and surgical intervention are not possible or are not sufficiently effective, and we lack efficient background drugs.

Sirolimus (rapamycin) is an inhibitor of mammalian target of rapamycin (mTOR), a serine/threonine kinase regulated by phosphoinositide-3-kinase (PI3K) and AKT. Once activated, the PI3K-AKT-mTOR pathway stimulates protein synthesis, cell proliferation and angiogenesis (7, 8). Sirolimus was tried in almost 170 published cases of vascular anomalies, mainly lymphatic and/or venous malformations and also tumors complicated by Kasabach–Merritt phenomenon (9–11). Sirolimus was efficient in most cases. Very few cases of AVMs treated with sirolimus have been reported, with controversial results (9, 10, 12).

In this study, we assessed the efficacy and tolerance of oral sirolimus for extracranial superficial AVMs in children and adults.

METHODS

Study design and setting

This retrospective, observational study was performed in 2 French tertiary centers for vascular anomalies (university hospitals of Paris-Necker and Tours) and was conducted according to the Declaration of Helsinki ethical guidelines.

Participants

We included data for all children and adults with superficial AVMs in whom treatment with sirolimus was initiated from January 2010 to December 2018. AVM was diagnosed by clinical and MRI signs and by consensus of our multidisciplinary consultations dedicated to vascular anomalies (involving a dermatologist, a radiologist and a surgeon). Imaging criteria for diagnosing AVM included color Doppler ultrasonography showing arteriovenous waveforms and high vascular flow as well as MRI and magnetic resonance angiography, which were systematically performed and allowed for visualizing flow voids without parenchymal staining, enlarged feeding and draining veins and early contrast enhance (13). Sirolimus had been proposed to patients for pain, ulceration or evolution of the AVM and when embolization and/or surgical intervention were not possible or sufficiently effective or not accepted by patients.

Data collected

We collected the following data from clinical records: demographic data, characteristics of the AVM (location, Schöbinger stage, triggering factors for worsening), associated signs, modalities of sirolimus management, previous treatments, and clinical and imaging data on AVM evolution.

Outcomes

Efficacy of treatment was classified by the investigators of each center (RG, AM, OB) as complete response (the condition was considered resolved or almost resolved; i.e. >90% decrease in AVM volume on clinical and imaging assessments), partial response (>25% decrease in AVM volume and/or healing of hemorrhage and necrosis) or no response (stabilization, <25% decrease in AVM volume or worsening). Time to response was collected. Also, the patients subjectively assessed the overall evolution of the AVM on a 5-point Likert scale: 1, major improvement; 2, minimal improvement; 3, stabilization; 4, minor worsening; 5, major worsening. Side effects were collected and classified by the toxicity grading scale, defined as 1, mild; 2, moderate; 3, severe; or 4, potentially life-threatening (14).

Statistical analyses

Continuous variables were described with median (interquartile range [IQR]). Categorical variables are summarized with number (%).

RESULTS

Participants and descriptive data

We included 10 patients (7 children, including 6 boys); all 3 adults were women. No patients were excluded from the analysis. Characteristics of patients and AVMs are summarized in **Table I**. The median (IQR) age at diagnosis was 7 years (2; 12.5). Seven patients had Schöbinger stage III AVM at the time of sirolimus onset. AVMs were located on the face in 5 patients and a limb in 4 and genital organs in 1 patient (**Fig. 1**). Patient 1 presented a syndromic segmental AVM associated with epidermal nevus syndrome (segmental epidermal nevus, aortic coarctation, and scattered lymphangiectasias). Triggering factors for AVM worsening included puberty in 5 children and pregnancy in 1 adult. Four patients had received arterial embolization and 1 had undergone surgery.

Sirolimus treatment

The median (IQR) age at sirolimus onset was 13.5 (13; 40.5) years. The starting dose of sirolimus ranged from 0.6 to 3.5 mg/m². For 8 patients, the residual blood level of sirolimus ranged from 5 to 10 ng/ml; for 1 patient, the level was <5 ng/ml (no available data for 1 patient). The median (IQR) treatment time was 24.5 (4.5; 35) months. Two patients were still receiving treatment at last follow-up, after 6 and 36 months of treatment.

Efficacy outcome

Among the 10 patients, none showed complete response (decrease >90% of volume), 5 partial response and 5 no response (<25% of decrease of volume). Among patients who showed partial response, 4 were children; AVMs were Schöbinger stage II in 2 patients and stage III in 3. Three of these AVMs were located on the face. The median (IQR) time to response was 3 (1; 5) months (range 1 to 12) (**Fig. 2**). Patients 2 and 4 experienced a

Table I. Characteristics of patients with superficial arteriovenous malformations (AVMs) and response to sirolimus

Patients	Sex	Age at onset of sirolimus (years)	Age at diagnosis (years)	Duration from diagnosis to sirolimus onset (years)	Location of the AVM	Schöbinger stage	Previous treatment	First response to sirolimus (time to response, months)	Duration of treatment (months)	Follow-up (months)
1	M	12	3	9	Left arm and thorax	III	—	NR	3	36
2	M	14	12	2	Right foot	III	—	PR (M3)*	19	29
3	M	13	7	6	Left leg	III	—	NR	4	18
4	F	13	0	13	Vulva	III	Embolization	PR (M1)*,**	30	44
5	M	13	6	7	Left cheek	I	—	NR	36	36
6	M	13	7	6	Left cheek	III	Embolization	PR (M12)**	72	79
7	M	2	1	1	Mouth and mandible	II	—	PR (M1)***	6 (ongoing)	6
8	F	35	13	22	Left arm	III	Embolization	NR	12	12
9	F	46	12	34	Left hemiface	III	Embolization	NR	34	34
10	F	47	36	11	Lower lip	II	Surgery	PR (M5)*	36 (ongoing)	36

*Decrease in volume, **Healing of necrosis, ***Stopping of hemorrhage

Schöbinger stage: stage I, quiescent forms; stage II, growing phase; stage III, tissue destruction, ulceration, pain and hemorrhage; stage IV, cardiac overload; M: month; CR: complete response; PR: partial response; NR: no response.

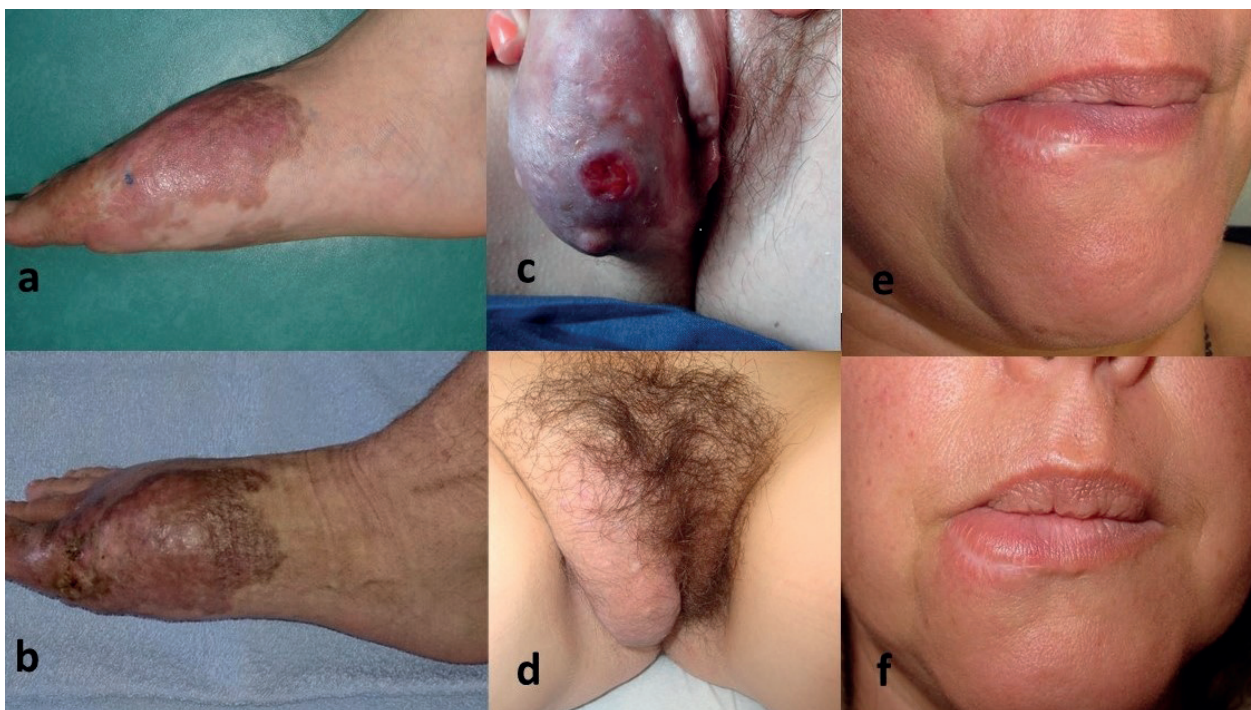


Fig. 1. Arteriovenous malformations (AVM): clinical features in patients 2 (a, b), patient 4 (c, d) and patient 10 (e, f). a (M2) and b (M10): AVM of the right foot that first showed partial response to sirolimus, then a worsening (increase in volume and necrosis after 9 months' treatment). c (month [M] 0) and d (M2): AVM of the vulva that showed major improvement after sirolimus (decrease in volume and healing of necrosis). e (M0) and f (M5): AVM of the lower lip that showed minor improvement after sirolimus (slight decrease in volume).

relapse after 9 and 24 months, respectively, characterized by an increase in volume of the AVM and skin necrosis; 1 patient reported major improvement of the AVM on the 5-point Likert scale and 4 minor improvement (Fig. 2). Among the 5 non-responders, AVMs were first stabilized in 3 cases, then showed progressive worsening, and for 2, AVMs immediately became worse.

Tolerance outcome

All 7 children experienced side effects ($n=8$), graded 1 or 2, which were attributed to sirolimus and consisted of mouth ulcers or oral mucositis ($n=6$), acne ($n=1$), and transient proteinuria ($n=1$). After 18 months of treatment, lymphedema developed on the left lower limb in

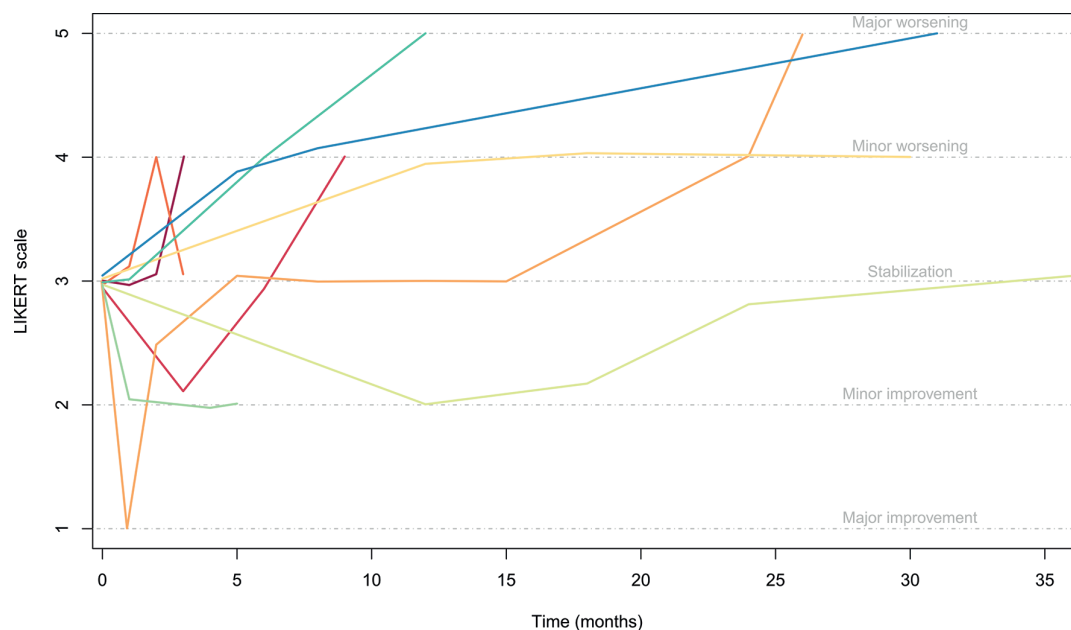


Fig. 2. Patients' subjective assessment of efficacy of sirolimus over time on a 5-point Likert scale: 1, major improvement; 2, minor improvement; 3, stabilization; 4, minor worsening; 5, major worsening.

one adult. We found no infections, no cytopenia and no significant biologic anomalies.

DISCUSSION

Main results

This study of 10 patients suggests that sirolimus is poorly effective for superficial AVMs, with partial response in 50% of patients, which was transient in 2 of the 5 patients. This is the largest series because the condition is very rare.

Limitations

Limitations are linked to the retrospective design of the study: missing data, heterogeneous times to assessment of efficacy, and assessments of efficacy based on radiological and clinical data mentioned in patient records.

Interpretation

Although a therapeutic response to sirolimus was reported for half of the patients, the qualitative responsiveness was low, with partial response only, and considered minor for 4 patients, with heterogeneous time to treatment response. AVMs were treated at advanced stages (\geq stage II in all patients), so these results cannot be extrapolated to patients with early-stage AVM.

To our knowledge, among more than 100 vascular malformations treated with sirolimus reported in the literature, 6 were extracranial AVMs (9, 10, 12, 15). Their characteristics are summarized in **Table II**. In the 6 cases, efficacy of sirolimus was heterogeneous (partial response in 3 cases, no response in the 3 others). The criteria for assessing efficacy were based on symptoms (pain), physician assessment of the decrease in volume AVM and/or imaging; time to assessment ranged from 1 to 6 months. The starting dosage of sirolimus was close to ours and was homogeneous in the 6 cases (1.6 mg/m²/day); however, the target levels of serum sirolimus were slightly higher in the 3 cases showing partial response. We hypothesize that this slight difference

in dosage was not significant and was not responsible for the difference in response to treatment because as in other VMs, target levels of about 5 ng/ml seem efficient (9, 10). The reason for the efficacy of sirolimus in some cases is more probably linked to differences in molecular basis. In all AVMs for which sirolimus seemed efficient, the AVM was associated with phosphatase and tensin homolog (PTEN) hamartoma syndrome. PTEN is a strong inhibitor of the PI3K-AKT-mTOR pathway and its mutation allows for uncontrolled activation of the pathway leading to the development of hamartomas (16). Sirolimus would partially restore control over the pathway.

In sporadic AVMs, as in the 10 cases we report, somatic variants of several genes of the renin-angiotensin system-mitogen-activated protein kinase (RAS-MAPK) pathway were recently identified (17, 18). This pathway interacts via RAS with the PI3K-AKT-mTOR pathway; while inhibiting the latter, sirolimus may lead to over-activation of the RAS-MAPK pathway, which explains the clinical worsening we observed. Thus, therapies targeting the RAS-MAPK pathway might have potential for superficial AVMs (18).

Conclusions

Sirolimus was only slightly efficient in half of our patients with AVMs. None of our 10 patients experienced severe side effects. New drugs targeting other pathways need to be developed for this rare and aggressive condition.

REFERENCES

1. Wassef M, Blei F, Adams D, Alomari A, Baselga E, Berenstein A, et al. Vascular anomalies classification: recommendations from the International Society for the Study of Vascular Anomalies. *Pediatrics* 2015; 136: e203–214.
2. Guillet A, Connault J, Perrot P, Perret C, Herbreteau D, Berton M, et al. Early symptoms and long-term clinical outcomes of distal limb's cutaneous arterio-venous malformations: a retrospective multicentre study of 19 adult patients. *J Eur Acad Dermatol Venereol* 2016; 30: 36–40.
3. Garzon MC, Huang JT, Enjolras O, Frieden IJ. Vascular malformations: Part I. *J Am Acad Dermatol* 2007; 56: 353–370.

Table II. Characteristics of patients with arteriovenous malformation (AVM) and response to sirolimus in previous publications

Authors, year of publication	Sex, age at onset of sirolimus (years)	PTEN mutation	Location of AVM	Schöbinger stage	Previous treatment	Starting dosage (mg/m ² /day)	Target serum level of sirolimus (ng/ml)	First response to sirolimus* (time to response, months)	Follow-up (months)
Iacobas et al., 2011	M, 6	+	Left hand	III	Surgery embolization	1.2	10–15	PR (M1)	>12
Adams et al., 2016	NA	+	NA	NA	NA	1.2	10–15	PR (M6)	NA
	NA	+	NA	NA	NA	1.2	10–15	PR (M6)	12
Triana et al., 2017	F, NA	–	Face	III	NA	1.2	5–15	NR	NA
	M, NA	–	Upper limb	III	NA	1.2	5–15	NR	NA
	F, NA	–	Lower limb	III	NA	1.2	5–15	NR	NA

*Criteria for response were heterogeneous, based on symptoms (pain), physical examination and/or imaging, and response was classified as CR (complete response), PR (partial response), NR (no response). Schöbinger stage: stage I, quiescent forms; stage II, growing phase; stage III, tissue destruction, ulceration, pain and hemorrhage; stage IV, cardiac overload.

PTEN: phosphatase and tensin homolog deleted on chromosome 10; NA: not available.

4. Rochon PJ. Importance of multidisciplinary approach to vascular malformation management. *Semin Intervent Radiol* 2017; 34: 301–302.
5. Ranieri M, Wohlgemuth W, Müller-Wille R, Prantl L, Kehrer A, Geis S, et al. Vascular malformations of upper and lower extremity - from radiological interventional therapy to surgical soft tissue reconstruction – an interdisciplinary treatment. *Clin Hemorheol Microcirc* 2017; 67: 355–372.
6. Le Fourn É, Herbreteau D, Papagiannaki C, Lorette G, Sirinelli D, Goga D, et al. Efficacy and safety of embolization in arteriovenous malformations of the extremities and head and neck: a retrospective study of 32 cases. *Eur J Dermatol* 2015; 25: 52–56.
7. Lee DF, Hung MC. All roads lead to mTOR: integrating inflammation and tumor angiogenesis. *Cell Cycle Georget Tex* 2007; 6: 3011–3014.
8. Jiang B-H, Liu L-Z. AKT signaling in regulating angiogenesis. *Curr Cancer Drug Targets* 2008; 8: 19–26.
9. Nadal M, Giraudeau B, Tavernier E, Jonville-Bera AP, Lorette G, Maruani A. Efficacy and safety of mammalian target of rapamycin inhibitors in vascular anomalies: a systematic review. *Acta Derm Venereol* 2016; 96: 448–452.
10. Adams DM, Trenor CC, Hammill AM, Vinks AA, Patel MN, Chaudry G, et al. Efficacy and safety of sirolimus in the treatment of complicated vascular anomalies. *Pediatrics* 2016; 137: e20153257.
11. Boccarda O, Puzenat E, Proust S, Leblanc T, Lasne D, Hadj-Rabia S, et al. Sirolimus effects on Kasabach-Merritt phenomenon coagulopathy. *Br J Dermatol* 2018;178: e114–116.
12. Iacobas I, Burrows PE, Adams DM, Sutton VR, Hollier LH, Chintagumpala MM. Oral rapamycin in the treatment of patients with hamartoma syndromes and PTEN mutation. *Pediatr Blood Cancer* 2011; 57: 321–323.
13. Rosenberg TL, Suen JY, Richter GT. Arteriovenous malformations of the head and neck. *Otolaryngol Clin North Am* 2018; 51: 185–195.
14. National Cancer Institute. Common Terminology Criteria for Adverse Events (CTCAE), version 5.0 [internet]. National Institutes of Health; 2017 [cited 3 Jan 2018]. Available from: https://ctep.cancer.gov/protocoldevelopment/electronic_applications/docs/CTCAE_v5_Quick_Reference_5x7.pdf.
15. Triana P, Dore M, Cerezo VN, Cervantes M, Sánchez AV, Ferrero MM, et al. Sirolimus in the treatment of vascular anomalies. *Eur J Pediatr Surg* 2017; 27: 86–90.
16. Luks VL, Kamitaki N, Vivero MP, Uller W, Rab R, Bovée JV, et al. Lymphatic and other vascular malformative/overgrowth disorders are caused by somatic mutations in PIK3CA. *J Pediatr* 2015; 166: 1048–1054.
17. Couto JA, Huang AY, Konczyk DJ, Goss JA, Fishman SJ, Mulliken JB, et al. Somatic MAP2K1 mutations are associated with extracranial arteriovenous malformation. *J Hum Genet* 2017; 100: 546–554.
18. Al Olabi L, Polubothu S, Dowsett K, Andrews KA, Stadnik P, Joseph AP, et al. Mosaic RAS/MAPK variants cause sporadic vascular malformations which respond to targeted therapy. *J Clin Invest* 2018; 128: 1496–1508.