



**HAL**  
open science

# Understanding Enteseal Changes: Definition and Life Course Changes

Sébastien Villotte, Christopher J. Knüsel

► **To cite this version:**

Sébastien Villotte, Christopher J. Knüsel. Understanding Enteseal Changes: Definition and Life Course Changes. *International Journal of Osteoarchaeology*, 2013, Enteseal Changes and Occupation: Technical and Theoretical Advances and Their Applications, 23 (2), pp.135-146. 10.1002/oa.2289 . hal-03147090

**HAL Id: hal-03147090**

**<https://hal.science/hal-03147090v1>**

Submitted on 19 Feb 2021

**HAL** is a multi-disciplinary open access archive for the deposit and dissemination of scientific research documents, whether they are published or not. The documents may come from teaching and research institutions in France or abroad, or from public or private research centers.

L'archive ouverte pluridisciplinaire **HAL**, est destinée au dépôt et à la diffusion de documents scientifiques de niveau recherche, publiés ou non, émanant des établissements d'enseignement et de recherche français ou étrangers, des laboratoires publics ou privés.

## Understanding Enthesal Changes: Definition and Life Course Changes

Journal:	<i>International Journal of Osteoarchaeology</i>
Manuscript ID:	OA-12-0089.R1
Wiley - Manuscript type:	Commentary
Date Submitted by the Author:	n/a
Complete List of Authors:	Villotte, Sébastien; University of Bradford, AGES Knusel, Chris; University of Exeter, Department of Archaeology
Keywords:	entheses, enthesopathy, Musculoskeletal Stress Markers (MSM), senescence, activity, hormones, animal models, clinical studies

SCHOLARONE™  
Manuscripts

Review

1  
2  
3 Title:

4 Understanding Enteseal Changes: Definition and Life Course Changes  
5  
6

7  
8 Short title:

9 Understanding Enteseal Changes  
10  
11

12  
13 Keywords: entheses; enthesopathy; Musculoskeletal Stress Markers (MSM); senescence;  
14 activity; hormones; animal models; clinical studies  
15  
16

17  
18 Authors:

19 Villotte S.

20 Biological Anthropology Research Centre

21 Division of Archaeological, Geographical & Environmental Sciences

22 Phoenix SW Building

23 University of Bradford

24 Bradford, West Yorkshire, BD7 1DP, UK

25 Telephone: +44 (0)1274233550

26 Emil Address: s.villotte@bradford.ac.uk  
27  
28

29  
30  
31  
32  
33  
34 and  
35  
36

37 Knüsel C.J.

38 Department of Archaeology,

39 University of Exeter,

40 Laver Building,

41 North Park Road,

42 Exeter, Devon, EX4 4QE, UK

43 Telephone: +44 (0)1392 262491

44 E-mail Address: c.j.knusel@exeter.ac.uk  
45  
46  
47  
48  
49  
50  
51  
52  
53  
54  
55  
56  
57  
58  
59  
60

1  
2  
3 Abstract:

4 Over the past two decades, many articles have been published on enthesal changes (usually  
5 called “Musculoskeletal Stress Markers”) as activity markers in past societies. Over-  
6 simplified methods and over-interpretation of past activities have generated robust critiques of  
7 research results in this area of enquiry. While some significant improvements regarding the  
8 recording systems for enthesal changes have been applied more recently, many  
9 bioarchaeologists appear not yet to be fully aware of the multi-factorial aetiology of these  
10 alterations. In this article, we review the anatomical and clinical literature to discuss some of  
11 the difficulties associated with the recording of enthesal changes and the multiple factors  
12 leading to their appearance in the human skeleton. Thus far fibrocartilagenous entheses appear  
13 to hold more promise for activity-related reconstruction than do fibrous ones, but these  
14 relationships remain an area of active research interest.  
15  
16  
17  
18  
19  
20  
21  
22  
23

24 Introduction

25  
26  
27  
28 La Cava (1959) appears to have been first to use the term "enthesis" for creating the word  
29 "enthesitis" to designate the inflammation of tendinous attachments. Subsequently, Ball  
30 (1971) and Niepel and Sit'Aj (1979) suggested using the words "enthesis" to designate the  
31 area where a tendon, a capsule or a ligament attaches to bone and "enthesopathy" to indicate  
32 pathological changes of this structure. “Enthesis” and “enthesopathy” are commonly used  
33 today in biomedical sciences, but other terms can also be found in the literature (table 1).  
34  
35  
36  
37  
38  
39  
40  
41  
42  
43  
44  
45  
46  
47  
48  
49  
50  
51  
52  
53  
54  
55  
56  
57  
58  
59  
60

TABLE 1

An enthesopathy can be a radiological, clinical, histological or osteological finding, and the  
notion of pain is not necessarily associated with its occurrence (e.g. Ball, 1971; Resnick and  
Niwayama, 1983; François *et al.*, 2001). In biological anthropology, several terms are used to  
designate the osteological changes seen in entheses: enthesopathies (e.g. Dutour, 1986;  
Hawkey, 1988), muscle crests (Angel *et al.*, 1987), musculoskeletal stress markers (Hawkey  
and Merbs, 1995), or muscle markings (Robb, 1998). Recently, Jurmain and Villotte (2010)

1  
2  
3 proposed the generic and more neutral term “entheseal changes” to designate all “particular”  
4 aspects of entheses seen in skeletal material.  
5

6 The interest of biological anthropologists in entheseal changes of the human skeleton is older  
7 than a century (e.g. Lane, 1887, 1888; Testut, 1889). Three main factors account for this  
8 interest. First, the areas of tendon or ligament attachment are usually easily visible on dry  
9 bones. Second, entheses exhibit a number of morphological variations, with more or less  
10 pronounced changes, such as irregularity and porosity, so changes can be scored. Finally, as  
11 entheses are regularly under heavy strain during physical activity, changes can,  
12 hypothetically, be used to reconstruct past physical activities. This type of study also has a  
13 long and contentious disciplinary history (for reviews, see Kennedy, 1989; Dutour, 2000;  
14 Jurmain *et al.*, 2012), with some notable detractors (e.g. Jurmain, 1999; Zumwalt, 2006;  
15 Jurmain and Roberts, 2008; Alves Cardoso and Henderson, 2010) as well as supporters (e.g.  
16 Dutour, 1986; Hawkey and Merbs, 1995; Molnar, 2006; Villotte *et al.*, 2010a, 2010b;  
17 Havelková *et al.*, 2011).  
18  
19  
20  
21  
22  
23  
24  
25  
26  
27

28 Methodological research recently carried out by several scholars (Mariotti *et al.*, 2004, 2007;  
29 Zumwalt, 2005; Villotte, 2006, 2009; Henderson and Gallant, 2007; Henderson *et al.*, 2010;  
30 Villotte *et al.*, 2010a) provides a renewed interest for the study of entheseal changes as  
31 potential markers of activity, as it can be seen, for instance, by the success of the *Workshop in*  
32 *Musculoskeletal Stress Markers (MSM): limitations and achievements in the reconstruction of*  
33 *past activity patterns*, held at the University of Coimbra, in Portugal (2<sup>nd</sup> - 3<sup>rd</sup> July 2009)  
34 (Santos *et al.*, 2011). However, this relative success could turn against itself, and one cannot  
35 entirely dismiss previous remarks on the limitations and pitfalls of this kind of study.  
36  
37  
38  
39  
40  
41  
42

43 The purpose of this article is not to discuss the reliability of entheseal changes for the  
44 reconstruction of past activities, nor the strictly methodological aspects of this kind of study  
45 because those considerations have been largely discussed elsewhere (Dutour, 1992; Robb,  
46 1998; Jurmain, 1999; Mariotti *et al.*, 2004, 2007; Villotte, 2006, 2008a, 2009; Henderson and  
47 Gallant, 2007; Alves Cardoso and Henderson, 2010; Villotte *et al.*, 2010a; Jurmain *et al.*,  
48 2012; Millela *et al.*, n.d.). The goal here is rather to attempt to clarify several points to  
49 anticipate continued use of entheseal changes as potential markers of activity in past  
50 populations. This perspective is based on the following premises: the most reliable data on  
51 entheses and entheseal changes are provided by their use in the biomedical sciences (even if  
52 some studies, as case reports, have apparently little broader application), and data from  
53  
54  
55  
56  
57  
58  
59  
60

1  
2  
3 identified skeletal collections are far better than those provided by archaeological samples  
4 because of numerous inherent biases (e.g. the effect of age and the difficulty to assess the age-  
5 at-death in archaeological samples, their unknown genetic background).  
6  
7

## 8 9 Anatomical background 10

### 11 12 1) Types of entheses: a brief presentation 13 14

15  
16 Two groups of entheses can be distinguished according to the tissue type present at the  
17 skeletal attachment site: fibrocartilaginous and fibrous (Benjamin and McGonagle, 2001;  
18 Benjamin *et al.*, 2002). Recently, the importance of this anatomical distinction for recording  
19 enthesal changes in skeletal material has been highlighted, independently, by Henderson  
20 (Henderson and Gallant, 2007; Alves Cardoso and Henderson, 2010) and by Villotte (2006,  
21 2008a, 2009; Villotte *et al.*, 2010a).  
22  
23  
24  
25  
26

27  
28 Briefly, fibrocartilaginous entheses occur close to joints of the long bones, but also on short  
29 bones and some parts of vertebrae; fibrous entheses occur on the diaphysis of long bones and  
30 also on the vertebral column (see tables A1 and A2 in Villotte *et al.*, 2010a for a list of the  
31 main post-cranial fibrous and fibrocartilaginous entheses). Four histological zones are  
32 distinguished in fibrocartilaginous entheses (Cooper and Misol, 1970; Benjamin *et al.*, 1986):  
33 1) tendon or ligament, 2) uncalcified fibrocartilage, 3) calcified fibrocartilage, and 4)  
34 subchondral bone. Zones 2 and 3 are separated by a regular calcification front called the  
35 “tidemark”. The tidemark, which is relatively rectilinear and not crossed by blood vessels, is  
36 the point at which soft tissues are removed during maceration (Benjamin *et al.*, 1986).  
37  
38 Contrary to fibrocartilaginous attachments, anatomical and anatomo-pathological descriptions  
39 for fibrous entheses are extremely rare. They attach soft tissues to bone directly or via a  
40 mediating layer of periosteum (Benjamin *et al.*, 2002). The anchorage is achieved through  
41 collagen fibers from periosteum, tendon, or ligament, which are embedded into bone  
42 (François *et al.*, 2001; de Pinieu and Forest, 2003). At fibrous entheses, blood vessels from  
43 the tendon or the ligament may anastomose with those of the bone (Dörfl, 1969).  
44  
45  
46  
47  
48  
49  
50  
51  
52

### 53 54 2) Defining a “normal” and a “changed” enthesis, is it simple? 55 56 57 58 59 60

1  
2  
3 The characteristic aspect of a healthy fibrocartilaginous enthesis is described by Benjamin and  
4 colleagues (2002: 939) in the following manner: “as the tidemark is relatively straight and the  
5 fibrocartilage zones avascular, the site of attachment in a healthy enthesis is smooth, well  
6 circumscribed and devoid of vascular foramina.” This description fits well with the  
7 appearance of several attachment sites seen on the skeleton (Fig. 1). Moreover, the accurate  
8 and numerous descriptions of changes that occur in enthesopathies in living people - erosion  
9 of the calcified fibrocartilage and subchondral bone, tidemark irregularity, vascularization of  
10 the fibrocartilage, calcification and ossification of soft tissues, cysts, and avulsions can be  
11 observed in skeletal material (Villotte, 2006, 2009; Villotte *et al.*, 2010a and clinical  
12 references therein). Thus, it seems conceivable to define a “healthy” (or “normal”) fibrocartilaginous  
13 enthesis in skeletal material as a smooth, well-defined imprint on the bone, without vascular foramina,  
14 and with a regular margin, and an enthesopathy in the other cases (Villotte, 2006, 2009, Villotte  
15 *et al.*, 2010a). However, this definition can be applied for only some fibrocartilaginous  
16 attachments; it does not work as well, for instance, for the entheses of  
17 *ligamenta flava* on the vertebral column (Villotte, 2006) or for small attachment sites like the  
18 insertion of the *M. brachialis* (pers. obs., and Mariotti, pers. comm.). In the case of the *M.*  
19 *brachialis*, this may be related to the relatively thin layer of uncalcified fibrocartilage at the  
20 insertion, and the fact that this muscle is already attached to the bone at birth (cf. Benjamin *et*  
21 *al.*, 1992).  
22  
23  
24  
25  
26  
27  
28  
29  
30  
31  
32  
33  
34  
35

### 36 FIGURE 1

37  
38  
39 Regarding the paucity of clinical and anatomical data for fibrous entheses, the definition of a  
40 “normal” type is far more complex (Villotte, 2006, 2009; Alves Cardoso and Henderson,  
41 2010). Osseous irregularity in the area of fibrous attachments is common in human skeletal  
42 remains, even in the first decades of adulthood (Villotte, 2009). Since the term  
43 “enthesopathy” implies a pathological condition, it is not appropriate to designate all of these  
44 very common and probably asymptomatic changes as pathological (Jurmain and Villotte,  
45 2010).  
46  
47  
48  
49  
50

### 51 3) Possible pitfalls of anatomical over-simplification

52  
53  
54  
55  
56 Changes in the two types of enthesis do not indicate the same phenomena, and it is to be  
57 expected that biological anthropologists will no longer combine them in a single study.  
58  
59  
60

1  
2  
3 Although the distinction between fibrous and fibrocartilaginous entheses seems clear enough,  
4 one should not forget that some amendments to their apparent distinctiveness have been  
5 made. First, some attachments are "mixed." Hems and Tillmann (2000) showed that the  
6 majority of the entheses of the masticatory muscles are of this type. Thus, the insertion of *M.*  
7 *masseter* is partly periosteal, partly osseous and partly fibrocartilaginous. Second, in a  
8 fibrocartilaginous enthesis, the periphery has little or no fibrocartilage (Benjamin *et al.*, 1986,  
9 2002). Third, fibrocartilage may exist in a small quantity at a fibrous enthesis, particularly on  
10 the metaphysis, an example of which is the *M. pectoralis major* insertion on the humerus  
11 (Benjamin *et al.*, 1986, 2002). Finally, one should not forget the morphological diversity in  
12 our species. For example, the most distal part of the insertion of the *M. iliopsoas*, at the  
13 junction between the lesser trochanter and the femoral shaft, may correspond to the inconstant  
14 fibrous insertion of the *M. iliacus* (Polster *et al.*, 2008) and this region is highly variable as a  
15 consequence (Fig. 2).  
16  
17  
18  
19  
20  
21  
22  
23  
24  
25  
26

## 27 FIGURE 2

28  
29 Several authors have discussed the boundaries of the concept of enthesis (for  
30 fibrocartilaginous attachments), and all agree that it cannot be reduced to the attachment of a  
31 tendon or ligament.<sup>1</sup> In addition to the attachment zone, Niepel and Sit'Aj (1979) include  
32 under the term "enthesis", all of the following: peritenon, associated bursae, fibrous tissues,  
33 fat-pads and sesamoid bones. Benjamin and colleagues (2001, 2002, 2004) formalized this  
34 concept and suggest using "enthesis organ" for the complex consisting of these anatomical  
35 structures around the fibrocartilaginous entheses *sensu stricto* because fibrocartilage is almost  
36 systematically observed in these structures. It is important that biological anthropologists  
37 consider this point before scoring enthesal changes. For instance, recent methodological  
38 papers (Mariotti *et al.*, 2004, 2007; Villotte, 2006; Henderson and Gallant, 2007; Henderson  
39 *et al.*, 2010; Villotte *et al.*, 2010a) do not mention bursae and whether or not bursopathies are  
40 scored. Admittedly, this is a thorny problem. Villotte (2009), perhaps wrongly, did not score  
41 bone changes that can occur at the location of bursae (Fig. 3) for several reasons: at present,  
42 data on bursopathies are still too scarce to accurately analyze the consequences on the  
43  
44  
45  
46  
47  
48  
49  
50  
51  
52  
53

---

54  
55 <sup>1</sup> Opinions differ on the structures to be associated with the enthesis *sensu stricto*. For instance, Fournié proposed  
56 the extension of the concept of enthesis to include amphiarthroses and diarthro-amphiarthroses (Fournié and  
57 Fournié, 1991; Fournié, 2004). First, in histological and functional terms, these joints are closer to  
58 fibrocartilaginous entheses than to true diarthroses. Second, these joints and fibrocartilaginous entheses are  
59 predilected in seronegative spondyloarthropathies.  
60



1  
2  
3 skeleton, the presence of bursae is inconstant, and their exact location varies. However, these  
4 data may be of interest in the discussion of past activities - bursae, as a part of the “enthesis  
5 organ”, participate actively in the dissipation of mechanical stresses. Moreover, it should be  
6 noted that sometimes the distinction between a bony involvement of the tendon attachment  
7 site or of the bursa is difficult to establish.  
8  
9  
10

### 11 12 13 14 15 16 17 18 19 20 21 22 23 24 25 26 27 28 29 30 31 32 33 34 35 36 37 38 39 40 41 42 43 44 45 46 47 48 49 50 51 52 53 54 55 56 57 58 59 60

FIGURE 3

Enthesal changes through life: the effects of age, hormones and activity

Trauma and micro-trauma can produce enthesal changes, among numerous others factors (Resnick and Niwayama, 1983). Clinical literature also reports the presence of enthesal changes in many diseases. The goal is not to present these conditions in detail here (listed in Henderson, 2008; Villotte, 2009), but rather to focus on lesser-known aspects of enthesal changes related to age, hormones and physical activities. However, it seems necessary to present briefly the two main causes of non-degenerative enthesopathies: spondyloarthropathies and diffuse idiopathic skeletal hyperostosis (DISH or hyperostotic disease). DISH is characterized by para-articular bridging osteophytes in the anterolateral aspect of the spine (Forestier and Rotes-Querol, 1950; Resnick *et al.*, 1975). Exuberant bone production is seen at extra-spinal fibrocartilaginous *and* fibrous entheses (Resnick *et al.*, 1975). Very early on, researchers recognized the enthesis as a primary target in ankylosing spondylitis and other spondyloarthropathies (Ball, 1971; Paolaggi *et al.*, 1984a, 1984b). The inflammation occurs at the level of fibrocartilaginous entheses, leading to erosion of the fibrocartilage (Benjamin and McGonagle, 2001; Fournié, 2004). This erosive process is followed by deposition of reactive bone and the formation of an enthesophyte (Ball, 1971; Resnick and Niwayama, 1983). It is noteworthy that enthesal changes seen in cases of spondyloarthropathy are characterized, at least for some fibrocartilaginous entheses, by erosive lesions uncommonly seen in other individuals (Villotte and Kacki, 2009).

In studies of enthesal changes in skeletal samples with known age-at-death, age is *the* main etiological factor identified (Shaibani *et al.*, 1993; Cunha and Umbelino, 1995; Mariotti *et al.*,

2004, 2007; Villotte, 2009; Alves Cardoso and Henderson, 2010; Villotte *et al.*, 2010a; Niinimäki, 2011; Milella *et al.*, 2012). However, the precise relation between age and enthesal changes remains poorly described (and in some aspects poorly understood). Properties of the entheses during skeletal immaturity are mainly described in studies of animal models and, to a lesser extent, in studies of human cadavers. For adulthood, data derive mainly from sports medicine or that associated with the aged, though the study of identified skeletal collections provides informative results.

#### 1) Secondary ossification centres

In early development of humans and other mammals, the tendon or ligament attaches to the perichondrium (Hurov, 1986; Gao *et al.*, 1996; Wei and Messner, 1996; Shaw *et al.*, 2008). During growth, entheses seem to act as growth plates; the cartilage is resorbed at the inner side and produced at the outer side, possibly by metaplasia (Gao *et al.*, 1996; Nawata *et al.*, 2002). The classic appearance of a fibrocartilaginous enthesis (i.e. the four histological zones, see *supra*) appears in non-human mammals when growth slows or stops (Wei and Messner, 1996; Nawata *et al.*, 2002; Wang *et al.*, 2006). For instance, in the attachment zones in the rat anterior cruciate ligament, the boundary between uncalcified and calcified fibrocartilage is not clearly distinguishable before growth slows (Nawata *et al.*, 2002). The process is not described for humans, but this progressive organization of the enthesis during growth and development could explain the lack of a clearly distinguishable area of attachment in juvenile human skeletons (Fig 4, compare with Fig. 1). Indeed, in skeletal remains, the classic appearance of a fibrocartilaginous enthesis is seen when epiphyses of short and flat bones (also called apophyses) and long bones are partially or fully fused. The most common activity-related change occurring before the complete fusion of the epiphysis is a total or a partial bony avulsion (e.g. Resnick and Niwayama, 1983; Nakanishi *et al.*, 1996; Stevens *et al.*, 1999; Adirim and Cheng, 2003). Consequences of these avulsions (total or partial) can be observed on the adult skeleton (Villotte *et al.*, 2010b; Knüsel, 2012).

#### FIGURE 4

During adulthood, the degenerative process related to age and mechanical demands affects both the tendon and the fibrocartilaginous enthesis. Within the aging tendons, the amount of denatured collagen and proteolytic cleavage of matrix components increase (Riley, 2004).

1  
2  
3 These changes lead to deterioration in the physical properties of the tendon (Riley, 2004),  
4 which, in turn, may favour the occurrence of mechanically induced alterations in the enthesis  
5 (Rodineau, 1991; Bard, 2003). From the sixth decade onwards, the fibrocartilaginous enthesis  
6 itself is the target of the degenerative process (Durigon and Paolaggi, 1991; Rodineau, 1991;  
7 Bard, 2003). Those degenerative changes are well described (Durigon and Paolaggi, 1991;  
8 Lagier, 1991; Kumagai *et al.*, 1994; Jiang *et al.*, 2002; Milz *et al.*, 2004; Benjamin *et al.*,  
9 2007, 2009). They are:

- 14 - Microtears or microdamage of one of the four histological zones of the enthesis (tendon,  
15 uncalcified and calcified fibrocartilage, bone);
- 16 - Formation of enthesophytes (bony spurs at the enthesis), induced by the healing process,  
17 after microtears;
- 18 - Disturbance of collagen fibers and of the organization of cell columns;
- 19 - Calcific deposits;
- 20 - Increase of the thickness of the calcified fibrocartilage layer;
- 21 - Vascularization of the calcified and uncalcified fibrocartilage layers;
- 22 - Erosion of the surface and bone resorption beneath the enthesis.

23  
24  
25  
26  
27  
28  
29  
30  
31 Disturbance of enthesis organization and subsequent healing processes are visible on skeletal  
32 remains: vascularization, enthesophytes, calcific deposits, cysts, and irregularity of the surface  
33 are common in the skeletons of old individuals (Shaibani *et al.*, 1993; Cunha and Umbelino,  
34 1995; Mariotti *et al.*, 2004, 2007; Villotte, 2009; Alves Cardoso and Henderson, 2010;  
35 Villotte *et al.*, 2010a; Milella *et al.*, 2012. Bony spur formation typically occurs in the most  
36 fibrous part of an enthesis (Villotte, 2006; Benjamin *et al.*, 2009). It should be noted that,  
37 contrary to other fibrocartilaginous entheses, there is no correlation between frequency and  
38 size of enthesophytes at the *ligamenta flava* attachment sites and age-at-death (Cunha and  
39 Umbelino, 1995; Villotte, 2009).

40  
41  
42  
43  
44  
45  
46  
47  
48 Excessive mechanical stress in terms of frequency, speed and/or intensity can cause a series of  
49 micro-traumatic insults that tend to disturb the tissue structure of the fibrocartilaginous  
50 enthesis (Husson *et al.*, 1991; Khan *et al.*, 1999; Benjamin *et al.*, 2006). In young adults, these  
51 mechanical stresses are the main factor in the occurrence of an activity-related enthesopathy  
52 (Rodineau, 1991). In the older individual, on the contrary, it is the gradual depletion of tendon  
53 vascularity close to the insertion that favours the occurrence of lesions (Rodineau 1991).  
54 Biomechanical parameters are, in this case, a secondary factor. Other factors may increase the  
55  
56  
57  
58  
59  
60

1  
2  
3 risk of developing enthesopathy, for instance cold temperatures, the use of unsuitable  
4 equipment, very heavy muscular stresses endured without training or appropriate warm-up,  
5 and abnormal structures disrupting joint biomechanics (Commandré, 1977; Rodineau, 1991;  
6 Bard 2003). The work of several authors, including Khan and collaborators (1999) and Milz  
7 and collaborators (2004), clearly indicate that overuse enthesopathies are similar to  
8 degenerative ones described in older individuals. Thus, micro- and macro-bony avulsions,  
9 tidemark irregularity (disorganization of the layer of calcified fibrocartilage), vascularisation  
10 of the fibrocartilage, calcification, and ossification of soft tissues can be observed in cases of  
11 overuse enthesopathy (Dupont *et al.*, 1983; Husson *et al.*, 1991; Saillant *et al.*, 1991; Potter *et*  
12 *al.*, 1995; Selvanetti *et al.*, 1997). It is noteworthy that in these sports medicine reports,  
13 skeletal alterations are, in most cases, inconspicuous.  
14  
15  
16  
17  
18  
19  
20  
21

22  
23 Sports and occupational injuries at tendons and entheses seem, at present, more common in  
24 women (Punnett and Herbert, 2000; Bard, 2003). However, these differences are not observed  
25 for all anatomical sites and many sex-related parameters (e.g. muscle mass, fat mass, size,  
26 morphology), may interact (e.g. Punnett and Herbert, 2000; Bard, 2003). Among the factors  
27 involved, ovarian hormones, including estradiol and relaxin, could play an important role. The  
28 contribution of these hormones in reducing the amount of glycosaminoglycans and collagen  
29 has been demonstrated for fibrocartilaginous joints (Naqvi *et al.*, 2005; Hashem *et al.*, 2006).  
30 Moreover, these hormones promote hyper-laxity and increase the risk of intrinsic mechanical  
31 lesions (Punnett and Herbert, 2000; Bard, 2003). At the menopause, blood levels of estrogen  
32 drop significantly (Sowers, 2000). This decrease causes a change in the composition of  
33 collagen connective tissue, including ligaments, associated with loss of elasticity (Falconer *et*  
34 *al.*, 1996; Ewies *et al.*, 2003).  
35  
36  
37  
38  
39  
40  
41  
42  
43

## 44 2) Diaphyses

45  
46 As for fibrocartilaginous entheses, the following discussion on properties of fibrous entheses  
47 during skeletal immaturity is based on animal models. These models are of two kinds: those  
48 focusing on gross anatomy and those studying the histological properties of these entheses.  
49 The first type indicates that during growth, there is a relationship between muscle  
50 activity/properties and the morphology of attachment sites. For instance, Dyzart and  
51 colleagues (1989) demonstrated that denervation of the rat forelimb is followed by an  
52 abnormally formed humerus, notably a smaller and less curved deltoid tuberosity. Based on  
53 these findings they postulated “that muscle pull affects periosteal tension and consequently  
54  
55  
56  
57  
58  
59  
60

1  
2  
3 bone form and growth in length” (Dyzart *et al.*, 1989: 158). In a study of mutant strains of  
4 mice, Montgomery and colleagues (2005: 819) reached a slightly different conclusion: “These  
5 findings suggest that muscle attachment sites expand during growth in order to accommodate  
6 increases in muscle size and mass, but that expansion of these bony regions is not necessarily  
7 dependent on increases in muscle contractile strength [...]”.

8  
9  
10  
11 If these experiments provide interesting insights into the effects of muscle properties and  
12 activity on bone morphology, the study of histological properties of attachment sites appears  
13 more informative for a better understanding of the “normal” appearance of fibrous entheses in  
14 the immature human skeleton. In dog, rabbit and rat studies on diaphyseal entheses, tendons  
15 and ligaments attach via periosteum during growth (Laros *et al.*, 1971; Dörfl, 1980a, 1980b;  
16 Hurov, 1986; Matyas *et al.*, 1990; Gao *et al.*, 1996; Wei and Messner, 1996). Both  
17 osteoclastic and osteoblastic activity are seen at fibrous attachment sites during this period  
18 and appear to be mainly related to the migration of the attachments of tendons and ligaments  
19 during the growth in length of long bones (Hoyte and Enlow, 1966; Dörfl, 1980a, 1980b;  
20 Hurov, 1986). It is noteworthy that muscular traction plays no role in this migration (Dörfl,  
21 1980a, 1980b; Grant *et al.*, 1981). All these animal model studies included the tibial insertion  
22 of the medial collateral ligament. This ligament attaches to the tibia of growing individuals in  
23 an area called the “metaphyseal depression”, where growth-related osteoclastic resorption is  
24 more predominant than osteoblastic activity (Dörfl, 1980a; Matyas *et al.*, 1990; Wei and  
25 Messner, 1996). Osteoclasts are most obvious at the periosteal side of the bone but they are  
26 also seen at the endosteal or marrow side (Wei and Messner, 1996). It is noteworthy that the  
27 “metaphyseal depression” disappears in mature rabbits (Matyas *et al.*, 1990), but a shallow  
28 depression persists in rats up to 120 days of age, which was interpreted by Wei and Messner  
29 (1996) as a sign of continuing growth. Many biological anthropologists (e.g. Saunders, 1978;  
30 Castex, 1990; Stirland, 1996; Mariotti *et al.*, 2004) reported high frequencies of a “fossa” in  
31 juveniles and young adults for several metaphyseal attachment sites (e.g. humeral insertions  
32 of the *Mm. pectoralis major* and *teres major* and the femoral insertion of the *M. gluteus*  
33 *maximus*). Actually, these grooves or “fossae” are very common in immature human  
34 skeletons, in frequency but also in their distribution in the body (Fig. 5), and it may be  
35 tentatively suggested that they are related to a process similar to that described for the tibial  
36 “metaphyseal depression” in rats and rabbits. These changes, especially for the humeral  
37 insertion of the *M. pectoralis major*, seem to be more dramatic in males during late  
38 adolescence and early adulthood, before the complete fusion of the epiphysis (Mariotti *et al.*,  
39 2004). Consequently, linking these erosions in young adult males solely to mechanical  
40  
41  
42  
43  
44  
45  
46  
47  
48  
49  
50  
51  
52  
53  
54  
55  
56  
57  
58  
59  
60

1  
2  
3 stresses (e.g. Hawkey and Merbs, 1995) appears, at least, highly hazardous (see Villotte,  
4 2008b for a review of the possible causes of a “fossa” at the humeral insertion of the *M.*  
5 *pectoralis major* in adults). Moreover, the bottom of these grooves is usually not smooth in  
6 juvenile human skeletons: marked porosity, short striae and small asperities are often present  
7 (Villotte, 2006). One could speculate that those changes are related to the irregularity of the  
8 mineralization front (i.e. the superficial cortex) before skeletal maturity in other mammals  
9 (Matyas *et al.*, 1990; Wei and Messner, 1996).  
10  
11  
12  
13  
14  
15

#### 16 FIGURE 5

17  
18  
19 In mature animals the periosteal layer may or may not disappear, depending on the species  
20 and the enthesis. In adult humans, periosteal fibrous entheses are seen where muscles attach to  
21 a large area by short fibrous ends (Kenesi and Tallineau, 1991), and for some masticatory  
22 muscles (Hems and Tillmann, 2000). As the mediating layer of periosteum often disappears  
23 with age and leaves the soft tissue attaching directly to bone (Benjamin *et al.*, 2002), it has  
24 been hypothesized that the physiological transition from a periosteal to a bony attachment in  
25 early adulthood may explain the high frequency of skeletal changes (i.e. irregularity) seen in  
26 young/middle-aged adults (Villotte 2009).  
27  
28  
29  
30  
31  
32  
33

34 Benjamin and collaborators (2002: 934) note that “relatively little attention has been paid to  
35 fibrous entheses, even though they are associated with some of the largest and most powerful  
36 muscles in the body [...]. This partly reflects a clinical bias toward fibrocartilaginous entheses  
37 – which are more vulnerable to overuse injuries, but also the attraction of working with a  
38 richer variety of tissues that such entheses can offer.” In a study that focuses mainly on  
39 fibrocartilaginous entheses, Benjamin and collaborators (2007) briefly describe two  
40 modifications observed in elderly subjects at the fibrous insertion of *M. pronator teres*: a bony  
41 production and a vascular invasion of the fibrous tissue. Micro-trauma at fibrous entheses are  
42 described mainly for periosteal attachment sites (e.g. Condouret and Pujol, 1985); they lead to  
43 a periostitis. Only a few cases were reported for bony ones: enthesopathy at the *M. deltoideus*  
44 insertion on the humerus in golfers and “pala” players (Commandré, 1977: 67) and small  
45 resorptive areas at the humeral insertion of the *M. pectoralis major* in gymnasts (Fulton *et al.*,  
46 1979).  
47  
48  
49  
50  
51  
52  
53  
54  
55  
56  
57  
58  
59  
60

1  
2  
3 To conclude this section, it seems important to report an interesting study on the effect of  
4 inactivity for several entheses in dogs (Laros *et al.*, 1971). In active immature dogs, normal  
5 metaphyseal remodelling was seen with a marked bone resorption at the tibial insertion of the  
6 medial collateral ligament (i.e. a normal appearance, cf. *supra*). In inactive adolescent dogs,  
7 the reaction was more generalized. Contrary to the other entheses under study, simple caging  
8 for six weeks produced resorption at the tibial insertion of the medial collateral ligament in  
9 adult dogs. Moreover, after several weeks of immobilization in a plaster cast, resorptive  
10 changes at this enthesis were seen for the immobilized limb of adult dogs, but also in a lesser  
11 extent for the non-immobilized limb, free for activity and weight-bearing! With continued  
12 caging (over a period of six months or more) and in dogs sacrificed twelve weeks after  
13 removal of plaster immobilization, bone resorption healed as fibrous tissue replaced resorbed  
14 bone and then became mineralized.  
15  
16  
17  
18  
19  
20  
21  
22  
23

## 24 Conclusion

25  
26  
27  
28 In the last twenty years, researchers have published important works on the limits and pitfalls  
29 of interpretations of enthesal changes as activity markers (e.g. Dutour, 1992; Jurmain, 1999;  
30 Jurmain *et al.*, 2012), mainly related to the problem of false positives (in our case, an  
31 enthesal change not related to physical activity). Based on our experience, exuberant bone  
32 production is mainly seen in older individuals, individuals with systemic disease or, locally, in  
33 cases of trauma. In many cases major enthesal changes are probably not directly related to  
34 physical activity, and certainly not *only* to micro-trauma at the enthesis.  
35  
36  
37  
38

39 While some biological anthropologists seem to have been completely unaware of these  
40 problems, others, notably Weiss (2003, 2004; Weiss *et al.*, 2012), have attempted to identify  
41 the “confounding” factors, but without adequately documented material. The archaeological  
42 record does not represent the best samples from which to identify the processes that produce  
43 alterations of an attachment site, for at least one good reason: the age-at-death assessment.  
44 This contribution illustrates the usefulness of clinical studies and studies based on identified  
45 skeletal collections for the understanding of enthesal changes. Based on the data obtained  
46 thus far, it seems that most of the changes seen for fibrous entheses cannot be directly  
47 associated with activity. In fact, some of the most common changes considered in biological  
48 anthropology – cortical defects at metaphyseal sites – may be related to growth and  
49 development, or even to inactivity. This hypothesis was formulated previously by Mafart  
50 (1996), though on archaeological criteria. If the study of enthesopathies for fibrocartilaginous  
51  
52  
53  
54  
55  
56  
57  
58  
59  
60

1  
2  
3 sites appears more promising to attempt to reconstruct past activities, one cannot deny the  
4 numerous difficulties associated with their recording and the multiple factors leading to their  
5 appearance in the human skeleton.  
6  
7

#### 8 9 Acknowledgements

10  
11  
12 The authors thank Charlotte Henderson and Francisca Alves-Cardoso for the invitation to  
13 participate in the Symposium and the two reviewers for their useful comments.  
14  
15  
16

#### 17 18 References cited

- 19  
20  
21 Adirim T, and Cheng T. 2003. Overview of injuries in the young athlete. *Sports Medicine* 33 :  
22 75-81.  
23 Alves Cardoso F, and Henderson CY. 2010. Enthesopathy formation in the humerus: Data  
24 from known age-at-death and known occupation skeletal collections. *American Journal of*  
25 *Physical Anthropology* 141 : 550-560.  
26 Angel JL, Kelley JO, Parrington M, and Pinter S. 1987. Life stresses of the free Black  
27 community as represented by the First African Baptist Church, Philadelphia, 1823-1841.  
28 *American Journal of Physical Anthropology* 74 : 213-229.  
29 Ball J. 1971. Enthesopathy of rheumatoid and ankylosing spondylitis. *Annals of the*  
30 *Rheumatic Diseases* 30 : 213-223.  
31 Bard H. 2003. Physiopathologie, réparation, classification des tendinopathies mécaniques. In  
32 *Tendons et enthèses*, Bard H, Cotten A, Rodineau J, Saillant G, and Railhac J-J (eds).  
33 Sauramps Médical: Montpellier; 165-178.  
34 Benjamin M, Evans EJ, and Copp L. 1986. The histology of tendon attachments to bone in  
35 man. *Journal of Anatomy* 149 : 89-100.  
36 Benjamin M, Newell RL, Evans EJ, Ralphs JR, and Pemberton DJ. 1992. The structure of the  
37 insertions of the tendons of biceps brachii, triceps and brachialis in elderly dissecting room  
38 cadavers. *Journal of Anatomy* 180 : 327-332.  
39 Benjamin M, Kumai T, Milz S, Boszczyk BM, Boszczyk AA, and Ralphs JR. 2002. The  
40 skeletal attachment of tendons - tendon "enthèses". *Comparative Biochemistry and*  
41 *Physiology, Part A: Molecular & Integrative Physiology* 133 : 931-945.  
42 Benjamin M, and McGonagle D. 2001. The anatomical basis for disease localisation in  
43 seronegative spondyloarthropathy at entheses and related sites. *Journal of Anatomy* 199 : 503-  
44 526.  
45 Benjamin M, Moriggl B, Brenner E, Emery P, McGonagle D, and Redman S. 2004. The  
46 "enthesis organ" concept: why enthesopathies may not present as focal insertional disorders.  
47 *Arthritis & Rheumatism* 50 : 3306-3313.  
48 Benjamin M, Toumi H, Ralphs JR, Bydder G, Best TM, and Milz S. 2006. Where tendons  
49 and ligaments meet bone: attachment sites ("enthèses") in relation to exercise and/or  
50 mechanical load. *Journal of Anatomy* 208 : 471-490.  
51 Benjamin M, Toumi H, Suzuki D, Redman S, Emery P, and McGonagle D. 2007.  
52 Microdamage and altered vascularity at the enthesis-bone interface provides an anatomic  
53 explanation for bone involvement in the HLA-B27-associated spondylarthritides and allied  
54 disorders. *Arthritis & Rheumatism* 56 : 224-233.  
55  
56  
57  
58  
59  
60



- 1  
2  
3 Benjamin M, Toumi H, Suzuki D, Hayashi K, and McGonagle D. 2009. Evidence for a  
4 distinctive pattern of bone formation in enthesophytes. *Annals of the Rheumatic Diseases* 68 :  
5 1003-1010.
- 6 Castex D. 1990. Insertion du grand pectoral et du grand rond sous forme de fosse. *Bulletins et*  
7 *Mémoires de la Société d'Anthropologie de Paris* n.s., 2 : 185-190.
- 8 Condouret J, and Pujol M. 1985. Périostites tibiales. In *Muscles, tendons et sport*, Bénézis C,  
9 Simeray J, and Simon L (eds). Masson: Paris; 113-119.
- 10 Cooper RR, and Misol S. 1970. Tendon and ligament insertion. A light and electron  
11 microscopic study. *The Journal of Bone and Joint Surgery [Am]* 52 : 1-20.
- 12 Cunha E, and Umbelino C. 1995. What can bones tell about labour and occupation: the  
13 analysis of skeletal markers of occupational stress in the Identified Skeletal Collection of the  
14 Anthropological Museum of the University of Coimbra (preliminary results). *Antropologia*  
15 *Portuguesa* 13 : 49-68.
- 16 de Pinieu G, and Forest M. 2003. Qu'est-ce qu'une enthèse ? In *Tendons et enthèses*, Bard H,  
17 Cotten A, Rodineau J, Saillant G, and Railhac J-J (eds). Sauramps Médical: Montpellier; 15-  
18 17.
- 19 Dörfel J. 1969. Vessels in the region of tendinous insertions. II. Diaphysoperiosteal insertion.  
20 *Folia Morphologica* 17 : 79-82.
- 21 Dörfel J. 1980a. Migration of tendinous insertions. I. Cause and mechanism. *Journal of*  
22 *Anatomy* 131 : 179-195.
- 23 Dörfel J. 1980b. Migration of tendinous insertions. II. Experimental modifications. *Journal of*  
24 *Anatomy* 131 : 229-237.
- 25 Dupont M, Pasteels JL, Duchateau M, and Szpalski M. 1983. Tendinites corporéales et  
26 ostéotendinites, essai de définition des lésions et de leur traitement chirurgical. *Acta*  
27 *Orthopædica Belgica* 49 : 30-41.
- 28 Durigon M, and Paolaggi J-B. 1991. Enthèse au cours de la vie. In *Pathologie des insertions*  
29 *et enthésopathies*, Simon L, Hérisson C, and Rodineau J (eds). Masson: Paris; 12-17.
- 30 Dutour O. 1986. Enthesopathies (lesions of muscular insertions) as indicators of the activities  
31 of Neolithic Saharan populations. *American Journal of Physical Anthropology* 71 : 221-224.
- 32 Dutour O. 1992. Activités physiques et squelette humain : le difficile passage de l'actuel au  
33 fossile. *Bulletins et Mémoires de la Société d'Anthropologie de Paris* n.s., 4 : 233-241.
- 34 Dutour O. 2000. Chasse et activités physiques dans la Préhistoire : les marqueurs osseux  
35 d'activités chez l'homme fossile. *Anthropologie et Préhistoire* 111 : 156-165.
- 36 Dysart PS, Harkness EM, and Herbison GP. 1989. Growth of the humerus after denervation.  
37 An experimental study in the rat. *Journal of Anatomy* 167 : 147-159.
- 38 Ewies AAA, Al-Azzawi F, and Thompson J. 2003. Changes in extracellular matrix proteins in  
39 the cardinal ligaments of post-menopausal women with or without prolapse: a computerized  
40 immunohistomorphometric analysis. *Human Reproduction* 18 : 2189-2195.
- 41 Falconer C, Ekman-Ordeberg G, Ulmsten U, Westergren-Thorsson G, Barchan K, and  
42 Malmström A. 1996. Changes in paraurethral connective tissue at menopause are  
43 counteracted by estrogen. *Maturitas* 24 : 197-204.
- 44 Forestier J, and Rotes-Querol J. 1950. Senile Ankylosing Hyperostosis of the Spine. *Annals of*  
45 *the Rheumatic Diseases* 9 : 321-330.
- 46 Fournié B. 2004. Pathology and clinico-pathologic correlations in spondyloarthropathies.  
47 *Joint Bone Spine* 71 : 525-529.
- 48 Fournié B, and Fournié A. 1991. Elargissement du concept d'enthèse. In *Pathologie des*  
49 *insertions et enthésopathies*, Simon L, Hérisson C, and Rodineau J (eds). Masson: Paris; 18-  
50 21.
- 51 François RJ, Braun J, and Khan MA. 2001. Entheses and enthesitis: a histopathologic review  
52 and relevance to spondyloarthritides. *Current Opinion in Rheumatology* 13 : 255-264.
- 53  
54  
55  
56  
57  
58  
59  
60

- 1  
2  
3  
4  
5  
6  
7  
8  
9  
10  
11  
12  
13  
14  
15  
16  
17  
18  
19  
20  
21  
22  
23  
24  
25  
26  
27  
28  
29  
30  
31  
32  
33  
34  
35  
36  
37  
38  
39  
40  
41  
42  
43  
44  
45  
46  
47  
48  
49  
50  
51  
52  
53  
54  
55  
56  
57  
58  
59  
60
- Fulton MN, Albright JP, and El-Khoury GY. 1979. Cortical desmoid-like lesion of the proximal humerus and its occurrence in gymnasts (ringman's shoulder lesion). *The American Journal of Sports Medicine* 7 : 57-61.
- Gao J, Messner K, Ralphs JR, and Benjamin M. 1996. An immunohistochemical study of enthesis development in the medial collateral ligament of the rat knee joint. *Anatomy and Embryology* 194 : 399-406.
- Grant PG, Bushang PH, Drolet DW, and Pickerell C. 1981. The effect of changes in muscle function and bone growth on muscle migration. *American Journal of Physical Anthropology* 54 : 547-553.
- Hashem G, Zhang Q, Hayami T, Chen J, Wang W, and Kapila S. 2006. Relaxin and beta-estradiol modulate targeted matrix degradation in specific synovial joint fibrocartilages: progesterone prevents matrix loss. *Arthritis Research & Therapy* 8 : R98.
- Havelková P, Villotte S, Velemínský P, Poláček L, and Dobisíková M. 2011. Enthesopathies and activity patterns in the Early Medieval Great Moravian population: Evidence of division of labour. *International Journal of Osteoarchaeology* 21 : 487-504.
- Hawkey DE. 1988. *Use of upper extremity enthesopathies to indicate habitual activity patterns*. M.A. thesis: Arizona State University.
- Hawkey DE, and Merbs CF. 1995. Activity-induced musculoskeletal stress markers (MSM) and subsistence strategy changes among ancient Hudson Bay Eskimos. *International Journal of Osteoarchaeology* 5 : 324-338.
- Hems T, and Tillmann B. 2000. Tendon entheses of the human masticatory muscles. *Anatomy and Embryology* 202 : 201-208.
- Henderson CY. 2008. When hard work is disease: the interpretation of enthesopathies. In *Proceedings of the 8th annual conference of the British Association of Biological Anthropology and Osteoarchaeology*, Brickley M, and Smith M (eds). Archaeopress: Oxford; 17-25.
- Henderson CY, and Gallant AJ. 2007. Quantitative recording of entheses. *Paleopathology Newsletter* 137 : 7-12.
- Henderson CY, Mariotti V, Pany-Kucera D, Perréard-Lopreno G, Villotte S, and Wilczak CA. 2010. Scoring enthesal changes: proposal of a new standardised method for fibrocartilaginous entheses. Poster presented at the 18th European Meeting of the Paleopathology Association, Vienna, Austria 23rd–26th of August 2010. Consulted in 25th May 2012. Available from: <https://www.uc.pt/en/cia/msm/Vienna2010.pdf>.
- Hoyte DAN, and Enlow DH. 1966. Wolff's law and the problem of muscle attachment on resorptive surface of bone. *American Journal of Physical Anthropology* 24 : 205-214.
- Hurov JR. 1986. Soft-tissue bone interface: How do attachments of muscles, tendons, and ligaments change during growth? A light microscopic study. *Journal of Morphology* 189 : 313-325.
- Husson JL, Chauveaux D, Rochcongar P, and Lancien G. 1991. Physiopathologie et anatomopathologie des enthésopathies d'insertion par sollicitations mécaniques du système tendino-musculaire. In *Pathologie des insertions et enthésopathies*, Simon L, Hérisson C, and Rodineau J (eds). Masson: Paris; 156-166.
- Jiang Y, Zhao J, van Holsbeeck MT, Flynn MJ, Ouyang X, and Genant HK. 2002. Trabecular microstructure and surface changes in the greater tuberosity in rotator cuff tears. *Skeletal Radiology* 31 : 522-528.
- Jurmain R. 1999. *Story from the skeleton*. Gordon and Breach Publishers: Amsterdam.
- Jurmain R, Alves Cardoso F, Henderson CY, and Villotte S. 2012. Bioarchaeology's Holy Grail: The Reconstruction of Activity. In *A Companion to Paleopathology*, Grauer AL (ed.). Wiley-Blackell: New-York; 531-552.

- 1  
2  
3 Jurmain R, and Roberts C. 2008. Juggling the evidence: the purported 'acrobat' from Tell  
4 Brak. *Antiquity* 82. Consulted in 29th May 2012. Available from:  
5 <http://www.antiquity.ac.uk/ProjGall/jurmain/index.html>  
6  
7 Jurmain R, and Villotte S. 2010. Terminology. Entheses in medical literature and physical  
8 anthropology: a brief review. Document published online in 4th February following the  
9 Workshop in Musculoskeletal Stress Markers (MSM): limitations and achievements in the  
10 reconstruction of past activity patterns, University of Coimbra, July 2-3, 2009. Coimbra,  
11 CIAS – Centro de Investigação em Antropologia e Saúde. Consulted in 29th May 2012.  
12 Available from: [http://www.uc.pt/en/cia/msm/MSM\\_terminology3.pdf](http://www.uc.pt/en/cia/msm/MSM_terminology3.pdf)  
13  
14 Kenesi C, and Tallineau C. 1991. Anatomie et biomécanique des enthèses. In *Pathologie des*  
15 *insertions et enthésopathies*, Simon L, Hérisson C, and Rodineau J (eds). Masson: Paris; 8-12.  
16  
17 Kennedy KAR. 1989. Skeletal markers of occupational stress. In *Reconstruction of life from*  
18 *the skeleton*, Iscan MY, and Kennedy KAR (eds). Liss: New York; 130-160.  
19  
20 Khan KM, Cook JL, Bonar F, Harcourt P, and Åstrom M. 1999. Histopathology of common  
21 tendinopathies. Update and implications for clinical management. *Sports Medicine* 27 : 393-  
22 408.  
23  
24 Knüsel CJ. 2012. Men Take Up Arms for War: Sex and Status Distinctions of Humeral  
25 Medial Epicondylar Avulsion Fractures in the Archaeological Record. In *Breathing New Life*  
26 *into the Evidence of Death Contemporary Approaches to Bioarchaeology*, Baadsgaard A,  
27 Boutin AT, and Buikstra JE (eds). School for Advanced Research Press: New Mexico; 223-  
28 251.  
29  
30 Kumagai J, Sarkar K, and Uthoff HK. 1994. The collagen types in the attachment zone of  
31 rotator cuff tendons in the elderly: an immunohistochemical study. *Journal of Rheumatology*  
32 21 : 2096-2100.  
33  
34 La Cava G. 1959. Enthesitis-traumatic disease of insertions. *Journal of the American Medical*  
35 *Association* 169 : 254-255.  
36  
37 Lagier R. 1991. Entèses normales et enthésopathies. In *Pathologie des insertions et*  
38 *enthésopathies*, Simon L, Hérisson C, and Rodineau J (eds). Masson: Paris; 1-6.  
39  
40 Lane WA. 1887. A remarkable example of the manner in which pressure-changes in the  
41 skeleton may reveal the labour history of the individual. *Journal of Anatomical Physiology* 21  
42 : 385-406.  
43  
44 Lane WA. 1888. Anatomy and physiology of the shoemaker. *Journal of Anatomical*  
45 *Physiology* 22 : 592-628.  
46  
47 Laros GS, Tipton CM, and Cooper RR. 1971. Influence of physical activity on ligament  
48 insertions in the knees of dogs. *The Journal of Bone and Joint Surgery [Am]* 53 : 275-286.  
49  
50 Mafart B-Y. 1996. Quelques particularités anthropologiques et paléopathologiques d'une  
51 population de moniales médiévales de l'abbaye de Saint-Pierre de l'Almanarre (XIIIe-XIVe  
52 siècles, Hyères, Var). In *L'identité des populations archéologiques. Actes des XVIe rencontres*  
53 *internationales d'archéologie et d'histoire d'Antibes*, L. Buchet (ed.). Éditions APDCA:  
54 Sophia-Antipolis ; 271-286.  
55  
56 Mariotti V, Facchini F, and Belcastro MG. 2004. Enthesopathies - Proposal of a standardized  
57 scoring method and applications. *Collegium Antropologicum* 28 : 145-159.  
58  
59 Mariotti V, Facchini F, and Belcastro MG. 2007. The study of entheses: proposal of a  
60 standardised scoring method for twenty-three entheses of the postcranial skeleton. *Collegium*  
*Antropologicum* 31 : 191-313.  
61  
62 Matyas JR, Bodie D, Andersen M, and Frank CB. 1990. The development morphology of a  
63 "periosteal" ligament insertion: Growth and maturation of the tibial insertion of the rabbit  
64 medial collateral ligament. *Journal of Orthopaedic Research* 8 : 412-424.

- 1  
2  
3 Milella M, Giovanna Belcastro M, Zollikofer CPE, and Mariotti V. 2012. The effect of age,  
4 sex, and physical activity on enthesal morphology in a contemporary Italian skeletal  
5 collection. *American Journal of Physical Anthropology* 148: 379-388.
- 6 Milz S, Tischer T, Buettner A, Schieker M, Maier M, Redman S, Emery P, McGonagle D,  
7 and Benjamin M. 2004. Molecular composition and pathology of entheses on the medial and  
8 lateral epicondyles of the humerus: a structural basis for epicondylitis. *Annals of the*  
9 *Rheumatic Diseases* 63 : 1015-1021.
- 10 Molnar P. 2006. Tracing prehistoric activities: musculoskeletal stress marker analysis of a  
11 stone-age population on the Island of Gotland in the Baltic sea. *American Journal of Physical*  
12 *Anthropology* 129 : 12-23.
- 13 Montgomery E, Pennington C, Isales CM, and Hamrick MW. 2005. Muscle-bone interactions  
14 in dystrophin-deficient and myostatin-deficient mice. *The Anatomical Record Part A:*  
15 *Discoveries in Molecular, Cellular, and Evolutionary Biology* 286A : 814-822.
- 16 Nakanishi K, Masatomi T, Ochi T, Ishida T, Hori S, Ikezoe J, and Nakamura H. 1996. MR  
17 arthrography of elbow: evaluation of the ulnar collateral ligament of elbow. *Skeletal*  
18 *Radiology* 25 : 629-634.
- 19 Naqvi T, Duong TT, Hashem G, Shiga M, Zhang Q, and Kapila S. 2005. Relaxin's induction  
20 of metalloproteinases is associated with the loss of collagen and glycosaminoglycans in  
21 synovial joint fibrocartilaginous explants. *Arthritis Research & Therapy* 7 : R1 - R11.
- 22 Nawata K, Minamizaki T, Yamashita Y, and Teshima R. 2002. Development of the  
23 attachment zones in the rat anterior cruciate ligament: changes in the distributions of  
24 proliferating cells and fibrillar collagens during postnatal growth. *Journal of Orthopaedic*  
25 *Research* 20 : 1339-1344.
- 26 Niepel GA, and Sit'aj S. 1979. Enthesopathy. *Clinics in Rheumatic Diseases* 5 : 857-872.
- 27 Niinimäki S. 2011. What do muscle marker ruggedness scores actually tell us? *International*  
28 *Journal of Osteoarchaeology* 21 : 292-299.
- 29 Paolaggi J-B, Struz P, Goutet MC, Le Parc JM, Siaud JR, and Auquier L. 1984a. Recherche  
30 systématique des enthésopathies au cours des rhumatismes chroniques. Résultats et  
31 signification pathologique. *Revue du Rhumatisme et des Maladies Ostéo-articulaires* 51 :  
32 451-456.
- 33 Paolaggi J-B, Struz P, Siaud JR, Le Parc JM, and Auquier L. 1984b. Les enthésopathies des  
34 spondyloarthropathies inflammatoires. *Revue du Rhumatisme et des Maladies Ostéo-*  
35 *articulaires* 51 : 457-462.
- 36 Polster J, Elgabaly M, Lee H, Klika A, Drake R, and Barsoum W. 2008. MRI and gross  
37 anatomy of the iliopsoas tendon complex. *Skeletal Radiology* 37 : 55-58.
- 38 Potter HG, Hannafin JA, Morwessel RM, DiCarlo EF, O'Brien SJ, and Altchek DW. 1995.  
39 Lateral epicondylitis: correlation of MR imaging, surgical and histopathologic findings.  
40 *Radiology* 196 : 43-46.
- 41 Punnett L, and Herbert R. 2000. Work-related musculoskeletal disorders: is there a gender  
42 differential, and if so, what does it mean? In *Women and Health*, Goldman MB, and Hatch M,  
43 (eds). Academic Press: San Diego; 474-492.
- 44 Resnick D, Shaul S, and Robins JM. 1975. Diffuse idiopathic skeletal hyperostosis (DISH):  
45 Forestier's disease with extraspinal manifestations. *Radiology* 115 : 513-524.
- 46 Resnick D, and Niwayama G. 1983. Entheses and enthesopathy. *Radiology* 146 : 1-9.
- 47 Riley G. 2004. The pathogenesis of tendinopathy. A molecular perspective. *Rheumatology* 43  
48 : 131-142.
- 49 Robb JE. 1998. The interpretation of skeletal muscle sites: a statistical approach. *International*  
50 *Journal of Osteoarchaeology* 8 : 363-377.
- 51  
52  
53  
54  
55  
56  
57  
58  
59  
60

- 1  
2  
3 Rodineau J. 1991. Pathogénie des enthésopathies du membre supérieur. In *Pathologie des*  
4 *insertions et enthésopathies*, Simon L, Hérisson C, and Rodineau J (eds). Masson: Paris; 166-  
5 171.
- 6 Saillant G, Thoreux P, Vandenbussche E, and Roy-Camille R. 1991. Aspect macroscopique  
7 des enthésites. Rapport avec le socle osseux. Bursites associés. In *Pathologie des insertions et*  
8 *enthésopathies*, Simon L, Hérisson C, and Rodineau J (eds). Masson: Paris; 149-151.
- 9 Santos AL, Alves Cardoso F, Assis S, and Villotte S. 2011. The Coimbra Workshop in  
10 Musculoskeletal Stress Markers (MSM): an annotated review. *Antropologia Portuguesa* 28 :  
11 135-161.
- 12 Saunders SR. 1978. *The development and distribution of discontinuous morphological*  
13 *variation of the human infracranial skeleton*. National Museums of Canada, Archaeological  
14 Survey of Canada: Ottawa.
- 15 Selvanetti A, Cipolla M, and Puddu G. 1997. Overuse tendon injuries: basic science and  
16 classification. *Operative Techniques in Sports Medicine* 5 : 110-117.
- 17 Shaibani A, Workman R, and Rothschild BM. 1993. The significance of enthesopathy as a  
18 skeletal phenomenon. *Clinical and Experimental Rheumatology* 11 : 399-403.
- 19 Shaw HM, Vázquez OT, McGonagle D, Bydder G, Santer RM, and Benjamin M. 2008.  
20 Development of the human Achilles tendon enthesis organ. *Journal of Anatomy* 213 : 718-  
21 724.
- 22 Sowers MR. 2000. Menopause: its epidemiology. In *Women and health*, Goldman MB, and  
23 Hatch M (eds). Academic Press: San Diego; 1155 -1168.
- 24 Stevens MA, El-Khoury GY, Kathol MH, Brandser EA, and Chow S. 1999. Imaging features  
25 of avulsion injuries. *Radiographics* 19 : 655-672.
- 26 Stirland AJ. 1996. Femoral non-metric traits reconsidered. *Anthropologie* 34 : 249-252.
- 27 Testut L. 1889. *Recherches anthropologiques sur le squelette quaternaire de Chancelade*  
28 *(Dordogne)*. Pitrat aîné: Lyon.
- 29 Villotte S. 2006. Connaissances médicales actuelles, cotation des enthésopathies : nouvelle  
30 méthode. *Bulletins et Mémoires de la Société d'Anthropologie de Paris* n.s., 18 : 65-85.
- 31 Villotte S. 2008a. Les marqueurs ostéoarticulaires d'activité. In *Ostéo-archéologie et*  
32 *techniques médico-légales : tendances et perspectives*, Charlier P (ed.). Editions De Boccard:  
33 Paris; 383-389.
- 34 Villotte S. 2008b. L'insertion humérale « en fosse » du muscle grand pectoral. In *Ostéo-*  
35 *archéologie et techniques médico-légales : tendances et perspectives*, Charlier P (ed.).  
36 Editions De Boccard: Paris; 391-392.
- 37 Villotte S. 2009. *Enthésopathies et activités des Hommes préhistoriques - Recherche*  
38 *méthodologique et application aux fossiles européens du Paléolithique supérieur et du*  
39 *Mésolithique*. Archaeopress: Oxford.
- 40 Villotte S, and Kacki S. 2009. Remodelages des enthèses fibrocartilagineuses dans les  
41 spondylarthropathies inflammatoires *Bulletins et Mémoires de la Société d'Anthropologie de*  
42 *Paris, ns* 21 : 159-169.
- 43 Villotte S, Castex D, Couallier V, Dutour O, Knüsel CJ, and Henry-Gambier D. 2010a.  
44 Enthesopathies as occupational stress markers: evidence from the upper limb. *American*  
45 *Journal of Physical Anthropology* 142 : 224-234.
- 46 Villotte S, Churchill SE, Dutour O, Henry-Gambier D. 2010b. Subsistence activities and the  
47 sexual division of labor in the European Upper Paleolithic and Mesolithic: evidence from  
48 upper limb enthesopathies. *Journal of Human Evolution* 59 : 35-43.
- 49 Wang INE, Mitroo S, Chen FH, Lu HH, and Doty SB. 2006. Age-dependent changes in  
50 matrix composition and organization at the ligament-to-bone insertion. *Journal of*  
51 *Orthopaedic Research* 24 : 1745-1755.
- 52  
53  
54  
55  
56  
57  
58  
59  
60

1  
2  
3 Wei X, and Messner K. 1996. The postnatal development of the insertions of the medial  
4 collateral ligament in the rat knee. *Anatomy and Embryology* 193 : 53-59.

5 Weiss E. 2003. Understanding muscle markers: aggregation and construct validity. *American*  
6 *Journal of Physical Anthropology* 121 : 230-240.

7 Weiss E. 2004. Understanding muscle markers: lower limbs. *American Journal of Physical*  
8 *Anthropology* 125 : 232-238.

9 Weiss E, Corona L, and Schultz B. 2012. Sex differences in musculoskeletal stress markers:  
10 Problems with activity pattern reconstructions. *International Journal of Osteoarchaeology* 22  
11 : 70-80.

12 Zumwalt A. 2005. A new method for quantifying the complexity of muscle attachment sites.  
13 *The Anatomical Record Part B: The New Anatomist* 286B : 21-28.

14 Zumwalt A. 2006. The effect of endurance exercise on the morphology of muscle attachment  
15 sites. *The Journal of Experimental Biology* 209 : 444-454.  
16  
17  
18  
19  
20  
21  
22  
23  
24  
25  
26  
27  
28  
29  
30  
31  
32  
33  
34  
35  
36  
37  
38  
39  
40  
41  
42  
43  
44  
45  
46  
47  
48  
49  
50  
51  
52  
53  
54  
55  
56  
57  
58  
59  
60

Most common terms in biomedical sciences	"Synonyms"
Enthesis (plural: entheses)	Insertion site / Attachment site Insertion area / Attachment area Tendon-to-bone insertion / Ligament-to-bone insertion Zone of insertion / Zone of attachment
Entheseal (adj.)	Enthesial* Enthesal
Enthesopathy (plural: enthesopathies)	Enthesiopathy Insertiopathy Insertional tendinopathy Enthesopathic change
Enthesitis (i.e. inflammation)	Insertitis Insertional tendinitis / Insertional tendonitis Insertional periostitis

Table 1. Common terminology used in biomedical sciences.

\*: There is no consensus in favour of either “enthesal” or “enthesial” and both are in standard use.

### Figure Captions

Figure 1. Greater trochanter, insertion of the *M. gluteus medius*. Smooth imprint with regular margins. Scale: 1 cm.

Figure 2. Lesser trochanter, insertion of the *M. iliopsoas*. White arrow: salient margin at the trochanter, taken into account in Villotte (2006). Black arrow: salient margin at the junction between the lesser trochanter and the femoral shaft, which can occur independently and was not taken into account in the same scoring system. Scale: 1 cm.

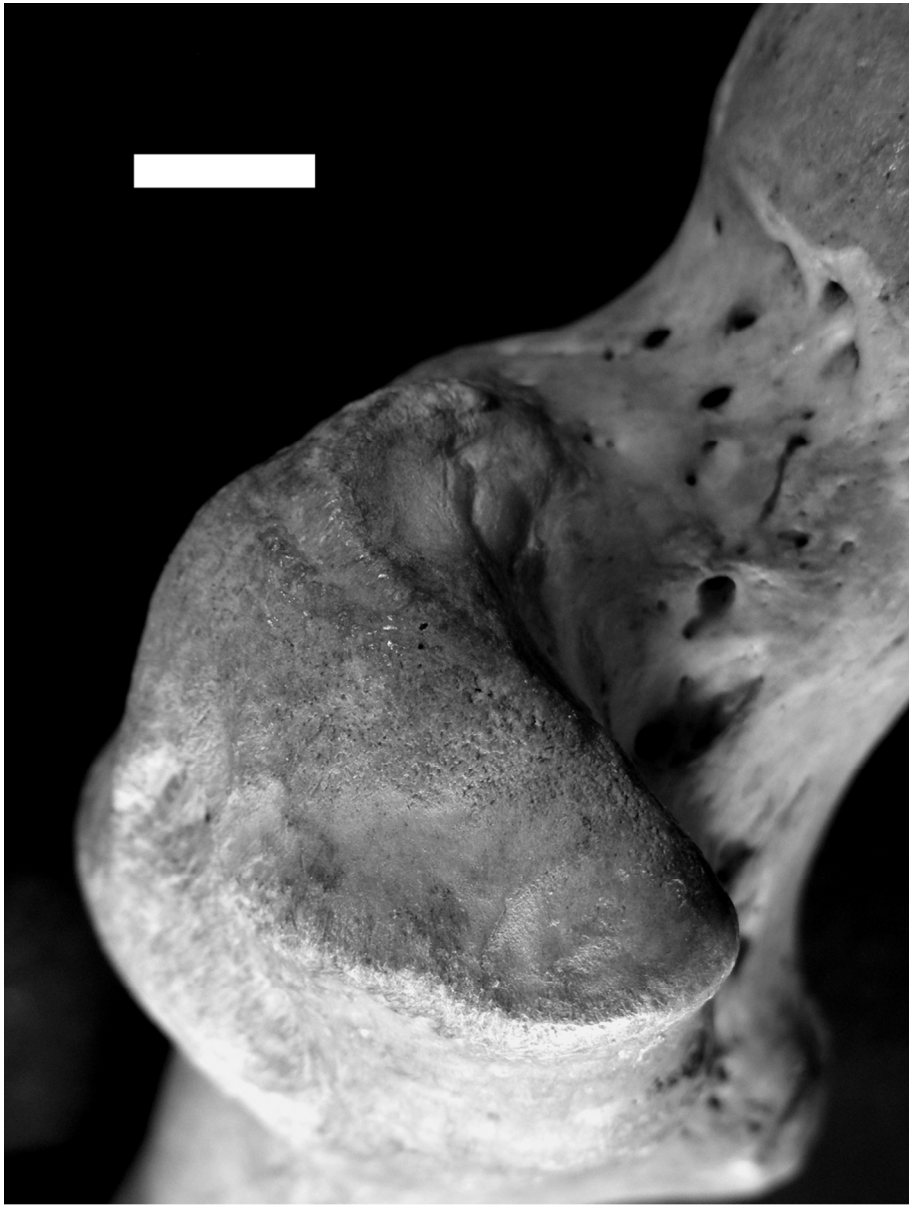Figure 3. Radial tuberosity. Changes occur at the medial part of the tuberosity – i.e. the attachment of the distal tendon of the *M. biceps brachii* (white arrow), and the lateral part that is the location of the bursa associated with this tendon (black arrow). Scale: 1 cm.

Figure 4. Proximal humeral epiphysis of an immature individual (6-9 years old). The area of attachment of the *M. supraspinatus* and *M. infraspinatus* on the greater tubercle (white arrow) is not clearly distinguishable. Scale: 1 cm.

Figure 5. Proximal tibial shaft of an immature individual (6-9 years old). The area of attachment of the *M. soleus* displays the classic appearance of immature metaphyseal entheses, a “fossa” with porosity, short striae and small asperities/irregularities at its bottom. Scale: 1 cm.

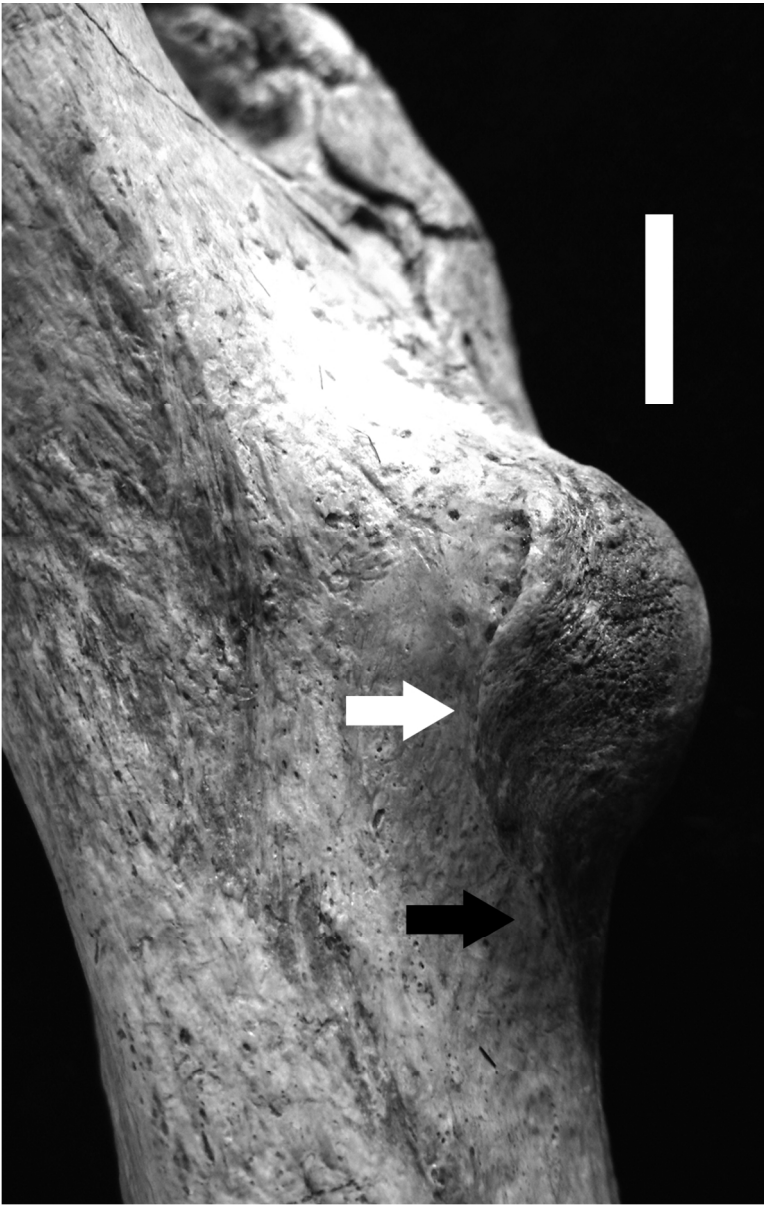


1  
2  
3  
4  
5  
6  
7  
8  
9  
10  
11  
12  
13  
14  
15  
16  
17  
18  
19  
20  
21  
22  
23  
24  
25  
26  
27  
28  
29  
30  
31  
32  
33  
34  
35  
36  
37  
38  
39  
40  
41  
42  
43  
44  
45  
46  
47  
48  
49  
50  
51  
52  
53  
54  
55  
56  
57  
58  
59  
60



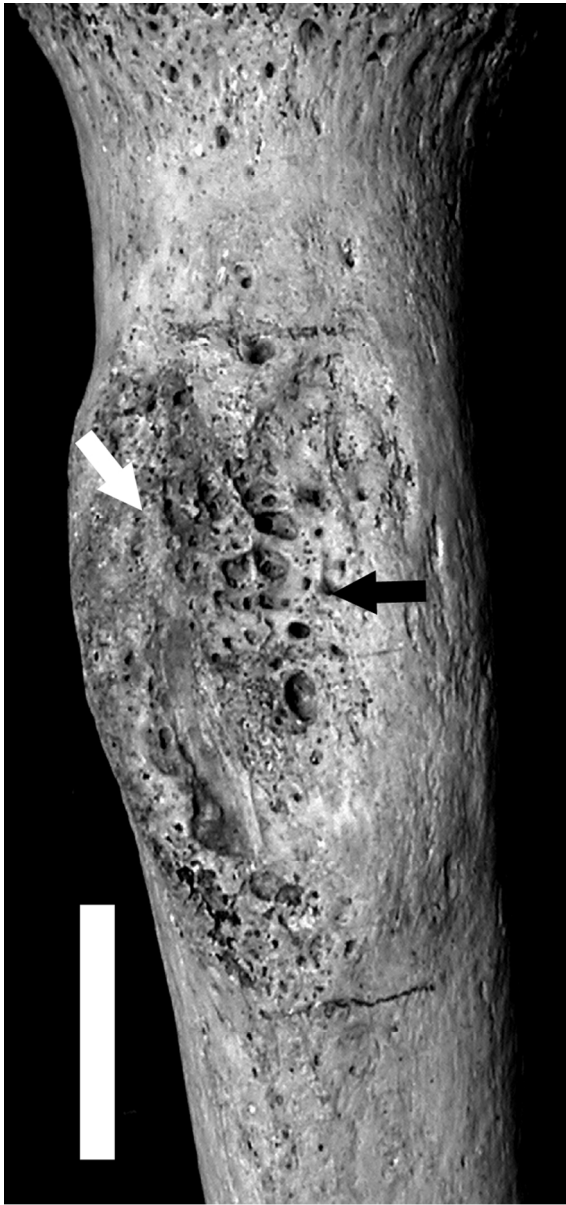
119x157mm (300 x 300 DPI)

1  
2  
3  
4  
5  
6  
7  
8  
9  
10  
11  
12  
13  
14  
15  
16  
17  
18  
19  
20  
21  
22  
23  
24  
25  
26  
27  
28  
29  
30  
31  
32  
33  
34  
35  
36  
37  
38  
39  
40  
41  
42  
43  
44  
45  
46  
47  
48  
49  
50  
51  
52  
53  
54  
55  
56  
57  
58  
59  
60



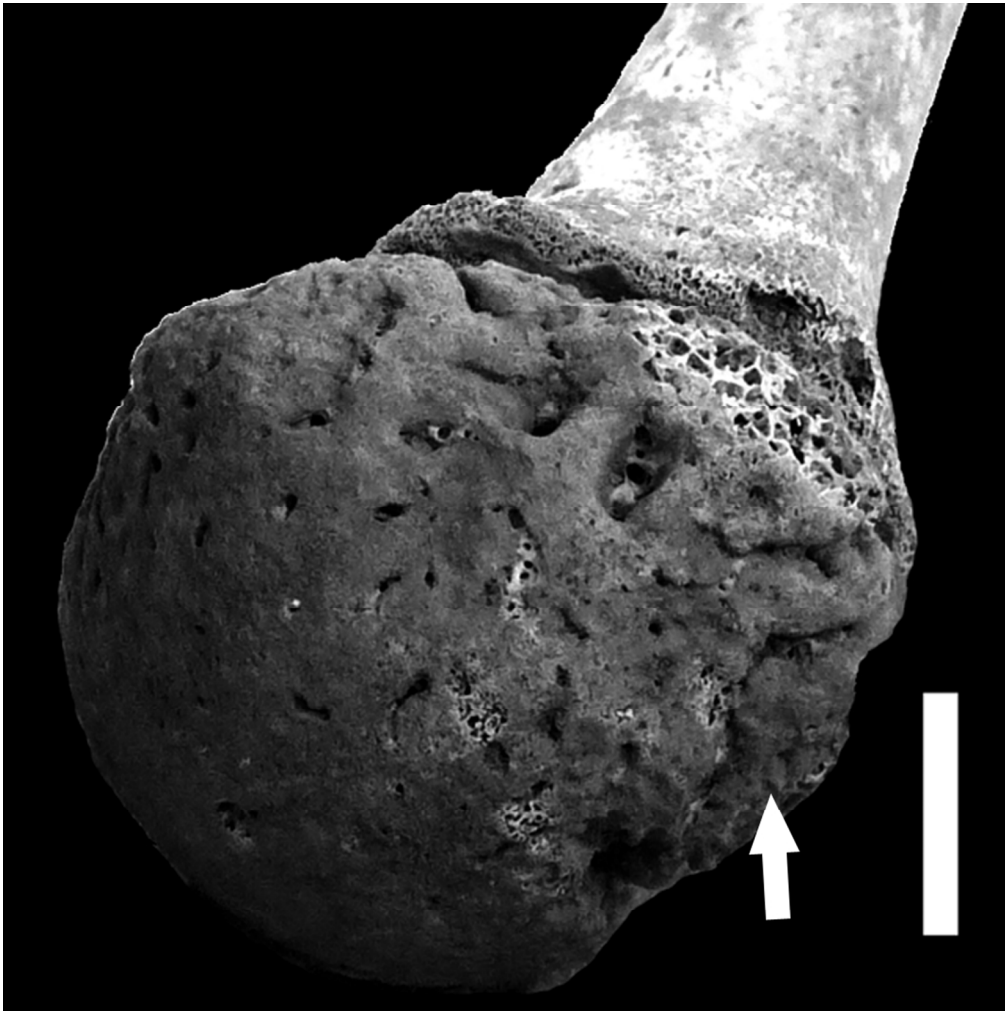
90x141mm (300 x 300 DPI)

1  
2  
3  
4  
5  
6  
7  
8  
9  
10  
11  
12  
13  
14  
15  
16  
17  
18  
19  
20  
21  
22  
23  
24  
25  
26  
27  
28  
29  
30  
31  
32  
33  
34  
35  
36  
37  
38  
39  
40  
41  
42  
43  
44  
45  
46  
47  
48  
49  
50  
51  
52  
53  
54  
55  
56  
57  
58  
59  
60



60x128mm (300 x 300 DPI)

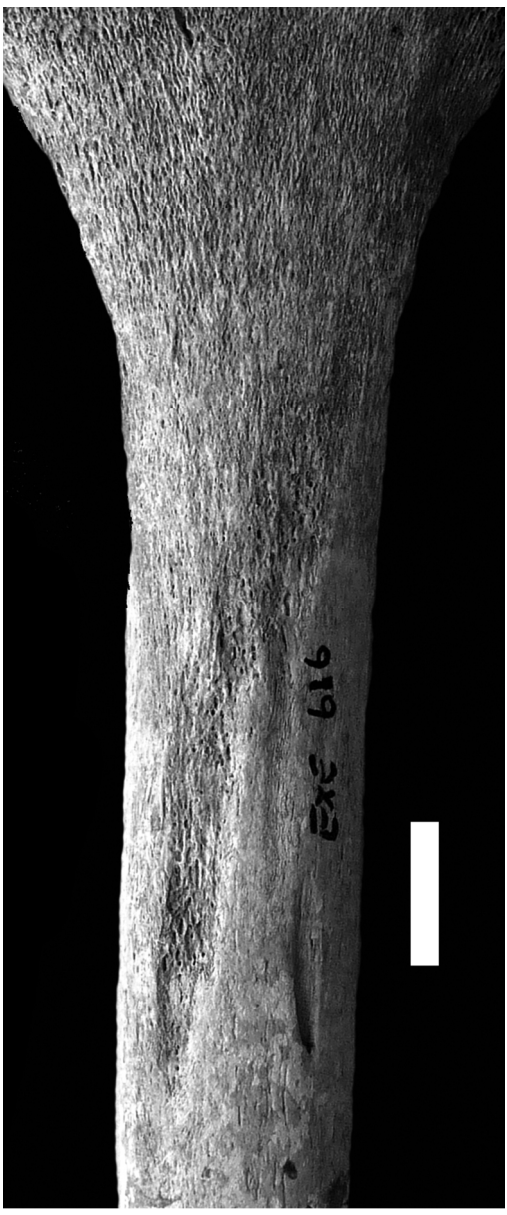1  
2  
3  
4  
5  
6  
7  
8  
9  
10  
11  
12  
13  
14  
15  
16  
17  
18  
19  
20  
21  
22  
23  
24  
25  
26  
27  
28  
29  
30  
31  
32  
33  
34  
35  
36  
37  
38  
39  
40  
41  
42  
43  
44  
45  
46  
47  
48  
49  
50  
51  
52  
53  
54  
55  
56  
57  
58  
59  
60



90x90mm (300 x 300 DPI)



1  
2  
3  
4  
5  
6  
7  
8  
9  
10  
11  
12  
13  
14  
15  
16  
17  
18  
19  
20  
21  
22  
23  
24  
25  
26  
27  
28  
29  
30  
31  
32  
33  
34  
35  
36  
37  
38  
39  
40  
41  
42  
43  
44  
45  
46  
47  
48  
49  
50  
51  
52  
53  
54  
55  
56  
57  
58  
59  
60



119x285mm (300 x 300 DPI)