



**HAL**  
open science

# The new "Coimbra method": a biologically appropriate method for recording specific features of fibrocartilaginous enthesal changes

Charlotte Yvette Henderson, Valentina Mariotti, Doris Pany-Kucera,  
Sébastien Villotte, Cynthia Wilczak

## ► To cite this version:

Charlotte Yvette Henderson, Valentina Mariotti, Doris Pany-Kucera, Sébastien Villotte, Cynthia Wilczak. The new "Coimbra method": a biologically appropriate method for recording specific features of fibrocartilaginous enthesal changes. *International Journal of Osteoarchaeology*, 2016, 26 (5), pp.925-932. 10.1002/oa.2477. hal-03147020

**HAL Id: hal-03147020**

**<https://hal.science/hal-03147020v1>**

Submitted on 22 Feb 2021

**HAL** is a multi-disciplinary open access archive for the deposit and dissemination of scientific research documents, whether they are published or not. The documents may come from teaching and research institutions in France or abroad, or from public or private research centers.

L'archive ouverte pluridisciplinaire **HAL**, est destinée au dépôt et à la diffusion de documents scientifiques de niveau recherche, publiés ou non, émanant des établissements d'enseignement et de recherche français ou étrangers, des laboratoires publics ou privés.

Title: The new “Coimbra method”: a biologically appropriate method for recording specific features of fibrocartilaginous enthesal changes.

Running title: The new “Coimbra method”

Authors: Henderson, C.Y.<sup>1</sup>, Mariotti V<sup>2,3</sup>, Pany-Kucera D<sup>4,5</sup>, Villotte S<sup>6</sup>, Wilczak C<sup>7</sup>.

Affiliations: 1. CIAS – Research Centre for Anthropology and Health, University of Coimbra, Portugal.

2. Laboratory of Bioarchaeology and Forensic Osteology, Department BiGeA, University of Bologna, Italy

3. UMR 7268 ADÉS - Anthropologie Bioculturelle, Droit, Ethique et Santé, CNRS / Université d'Aix-Marseille / EFS, Faculté de Médecine - Secteur Nord, CS80011, Boulevard Pierre Dramard, 13344 Marseille Cedex, 15, France.

4. Natural History Museum, Department of Anthropology, Vienna, Austria.

5. University of Vienna, Department of Anthropology, Vienna, Austria

6. PACEA, UMR 5199, Anthropologie des Populations Passées et Présentes, Université de Bordeaux, Bâtiment B8, Allée Geoffroy St Hilaire, CS 50023, 33615 Pessac Cedex, France

7. Department of Anthropology, San Francisco State University, USA.

Corresponding author: Henderson, C.Y.

Corresponding author address: CIAS – Research Centre for Anthropology and Health, Department of Life Sciences, University of Coimbra, Calçada Martim de Freitas, 3000-456. Portugal. Email: c.y.henderson@uc.pt or permanent email address:

c.y.henderson@dunelm.org.uk.

Accepted

This article has been accepted for publication and undergone full peer review but has not been through the copyediting, typesetting, pagination and proofreading process, which may lead to differences between this version and the Version of Record. Please cite this article as doi: 10.1002/oa.2477

## **Abstract**

This paper presents a revised version of the Coimbra method for recording fibrocartilaginous entheses. The method itself is the only biologically appropriate recording method for fibrocartilaginous entheses that scores features separately, thereby ensuring that the aetiology of individual features can be studied. The method divides the enthesis into two zones, scoring the relevant features in each zone. These features represent either bone formation or bone destruction and include erosive lesions, fine and macroporosity, and cavitations. The revised method includes a new feature, textural change, which is scored as absent or present when it involves 50% or more of the surface. All other features are now scored as zero (absent), one or two with the higher score representing greater expression of the feature. This change in scoring has led to the reduction of inter-observer error with approximately 80% agreement for overall feature scores for both the common extensor origin and subscapularis insertion. The simplification of the scores and the reduction in inter-observer error mean that the method is now recommended for widespread use.

## **Keywords**

Enthesis, entheses, musculoskeletal stress markers (MSM), activity markers

Accepted Article

## Introduction

The recording of enthesal changes (EC) remains a widely used method for inferring activity patterns in past populations (Cough, 2013; Havelková *et al.*, 2013; Henderson 2013; Lieveise *et al.*, 2013; Palmer *et al.*, 2014; Takigawa, 2014; Thomas, 2014). For this reason, developing a standard recording method encompassing both the biology and the variation in EC was deemed necessary at the 2009 Workshop on Musculoskeletal Stress Markers (MSM) held in Coimbra, Portugal (Santos *et al.*, 2011). The working group established to achieve this goal has already reported their initial results, referred to forthwith as the “Preliminary Coimbra Method” (Henderson *et al.*, 2013). However, repeatability was lower than is appropriate for a standard method. A meeting was held in Coimbra in 2013 enabling the international working group on methodology to interact in person with real human remains to improve the new recording method. After in depth discussion on every feature and several inter-observer error tests, the method was judged to be suitable for final publication and use to describe the variability and distribution of EC. This paper describes revisions to the Coimbra method for recording EC followed by a brief summary of the repeatability of the revised method.

### Revision of the Preliminary Coimbra Method

Discussions to determine the underlying causes of low repeatability began on-line using photographs and continued during the face-to-face meeting using human remains from the Coimbra identified skeletal collection. The main sources of error identified can be broadly categorized as differences in observational conditions, differences in interpretation of the definition of enthesis features and differences in individual experience with other recording methods (Wilczak *et al.* manuscript in preparation). While it is impossible to eliminate differences in some observational conditions such as individual variation in visual acuity, others such as lighting source can be standardized. Revisions to the definitions and terminology focused on the refinement of feature descriptions to reduce errors of interpretation, clarification of the transition points between scores and improvements in the delineation of the enthesis area to be scored.

The revised method retains the division of the enthesis into two zones from the previous method (Henderson *et al.*, 2013). Six features are recorded in total. Two features, bone formation and erosions, are scored in both zones. The remaining four features are scored in Zone 2 only. All features, except for textural change (TC), are recorded with two degrees of expression. The scoring criteria for the revised method can be found in Table 1.

*Observational Standards:* The maximum extent of the fibrocartilaginous portion of the enthesis should be recorded (Fig. 1). In some cases, the area of the enthesis may appear to have retracted from or extended beyond the original outline, making it important to identify

the maximum area prior to observation. Entheses should be observed without additional magnification (apart from the use of magnification to identify post-mortem damage) and should be held 20-30 cm from the eye. Strong natural daylight or full spectrum lighting should be used whenever possible otherwise oblique lighting is recommended. The bone should be fully rotated to enable all aspects to be observed from different angles. To avoid observer fatigue, frequent breaks are recommended.

*Discrimination of Zone 1 and Zone 2:* Zone 1 is the margin of the enthesis at which fibres attach most obliquely to the bone as has previously been described (Henderson *et al.*, 2013 and Villotte *et al.*, 2010). Zone 2 encompasses the remaining fibrocartilaginous footprint of the enthesis and the remaining margin. In most entheses Zone 2 is closest to the joint surface. Figure 1 demonstrates the location of zones one and two for the subscapularis insertion and common extensor origin (see also Figs.1, 2 in Henderson *et al.*, 2013). While the discrimination of Zone 1 and Zone 2 can be broadly defined for all insertions, idiosyncrasies of individual enthesis morphology are a source of error in zone discrimination. Before the final repeatability testing of the new method, agreement was reached on the delineation of zones for the entheses scored. In consultation with the relevant literature from medical and anatomical studies, we are in the process of developing standard illustrations of the zones in all fibrocartilaginous entheses, including common variants, for on-line publication.

*Definitions and Feature Scoring:* Revisions to the Coimbra method for EC scoring (Henderson *et al.* 2013, Table 1) include: reduction in the number of categories for some features; Zone 2 bone formation = 1 is now scored as a new, separate feature called textural change (TC); and changes in the definition of bone formation to emphasize distinct demarcation and eliminate scoring of rounded prominences that are more consistent with normal surface variation (Table 1 and Fig. 1C).

In Zone 1, only two features are scored: bone formation and erosion. Bone formation in Zone 1 is recorded when it is distinct, sharp and demarcated (Fig. 2A and B), as opposed to the smooth-rounded or mound-like features which are part of normal morphology (Fig. 1C). Erosions are excavations of any shape, which involve discontinuity at the base of the lesion of greater width than depth. In Zone 1 these should only be scored if their maximum width is greater than 1 mm as measured with sliding calipers (Fig. 2C). When an erosion spans both zones, it is recorded as present in the zone containing the greater percentage of the erosion area only. When the area of erosion is equally present in both zones, it is preferentially scored as Zone 1.

Six features are scored in Zone 2. Textural change is the only feature with a single degree of expression. This feature is seen as a non-smooth, granular surface visually similar to the surface of fine grained sandpaper (Fig. 3A). Unlike Zone 1, bone formation in Zone 2 does

not have to be sharp but should have a distinct margin to distinguish it from very rounded ridges that are part of normal surface shape variation (Fig. 1C). Erosions, as in Zone 1, must be wider than they are deep, but the width must be greater than 2 mm to be scored (Fig. 4A and B). It is important to distinguish erosions from post-mortem damage by checking the colour and appearance of all edges using magnification as necessary.

In Zone 2, three types of pore or cavitation features are also scored. The smallest of these is fine porosity. Fine porosity takes the form of small, round or oval perforations with smooth margins that are less than 1 mm in diameter (Fig. 4A and 4B). Pores of this nature are only scored if there are several in a localized area, i.e., single or isolated pores are not scored. They must be visible to the naked eye and will be over-scored if magnification is used. Pores should not be scored as a separate feature if they occur in conjunction with woven bone or if they are at the base of an erosion. Larger pores, or macro-porosity, are of the same shape but are 1 mm or larger in size and have the appearance of a channel (although the internal aspect is rarely visible) (Figs. 2C and 4B). As with fine porosity, these should not be scored if they occur at the base of an erosion. The final feature is a subcortical cavitation, which has a clear base or floor and is not a channel but an expanded chamber (Fig. 2B). The whole floor of the cavity must be visible and therefore only cavitations with an external opening greater than 2 mm can be scored. Figure 5 clarifies the difference between the channel-like macro-pores and bowl-shaped cavitations.

### **Repeatability**

Humerii, ulnae, radii, femora and calcanei from adult (18 years of age and over) males listed as labourers (“*trabalhadores*”) were taken from the Coimbra identified skeletal collection (n=59) for the meeting. Two subsets were created: 1) for initial interobserver repeatability tests and general study (n = 39 right and left) and 2) for post-discussion interobserver repeatability tests (n=20, right sides used first time, second time n=20, left sides used). Bones from the second subset were excluded from any general discussions of scores or features to avoid influencing the repeatability studies. Time limitations meant that repeatability was only tested on the subscapularis insertion and common extensor origin.

The first interobserver repeatability study was undertaken upon arrival in Coimbra. Minor revisions in the descriptions of features had been made following the on-line discussions, but there was little to no improvement over the published interobserver error rates (Henderson *et al.*, 2013). This initial test did highlight differences in observational practices such as the use of magnification and alternative light sources and problems with the identification of the enthesis footprints. In addition to standardizing the observational methods and reaching agreement on the area scored, entheses were seriated by feature scores, leading to some redefinitions and clarification of the feature descriptions.

The new definitions and standardized observation conditions were tested on the subscapularis insertion and common extensor origin using right side humeri from subset two. Interobserver repeatability was lower than anticipated caused by disagreement regarding the extent of Zone 2 and some remaining confusion regarding the feature definitions. These were resolved by reviewing those entheses causing problems to clarify the extent of the zones and by rewording the feature definitions, resulting in the final version of the recording method described in the previous section. Left side humeri from subset two that had not been previously observed were selected on the penultimate day of the workshop for the third and final interobserver repeatability test on the subscapularis and common extensor origin using the revised method.

Final overall repeatability, calculated by comparing all pairs of four scorers' results for two entheses on 10 bones, was high; for the subscapularis the overall repeatability was 81.9% and for the common extensor origin it was 79.4%. Repeatability by feature can be seen in Table 2. This compares well with other visual recording methods, which report interobserver error rates ranging from under 5% to over 50% (Davis *et al.*, 2013; Havelková and Villotte, 2007; Hawkey and Merbs, 1995; Mariotti *et al.*, 2004; Mariotti *et al.*, 2007; Villotte, 2006). The lowest score was for bone formation in Zone 1 of the subscapularis insertion. In over 70% of cases, all four observers agreed on the presence or absence of this feature at this site, indicating some of the variation was between scores of 1 and 2.

## Conclusion

Entheseal changes are widely recorded but often using different methods, which makes inter-sample comparison difficult (Henderson, 2013). The aim of this paper is to refine our recording method for fibrocartilaginous entheses so it can be recommended for widespread use. However, two notes of caution must be sounded. Firstly, the authors are aware that studying photographs alone is insufficient for learning this new method. Photographs, depending on their lighting and perspective, can exaggerate or minimize features, a fact which has made on-line collaboration for this working group extremely difficult. For this reason, the authors recommend in-person training directly from the authors with real human bones. The photographs in this publication are therefore meant purely for illustrative purposes and as aide memoirs.

The second note of caution is that the authors have yet to test the impact of age and activity-pattern on these features. Direct inferences from the presence of these features to activity-patterns are therefore inappropriate until the impact of confounding factors on the presence and expression of these features is adequately tested. Nor should the presence of the same feature at different entheses be taken to indicate the same cause. It was noticed during testing

that some features are more common at some entheses, e.g. textural change on the biceps brachii insertion, and this may relate to normal biology. Again this requires further testing. However, the method is appropriate to document variability and distribution of EC which both require further study to better understand their aetiology.

### **Authors' contribution**

All the authors contributed equally to the research design and data collection. CH drafted the paper. CH, VM, DP-K and CW scored the bones for the repeatability tests. All the authors critically revised the paper and contributed to the final version. The authors have no conflicts of interest.

### **Acknowledgements**

The authors would like to thank the Wenner-Gren Foundation (grant number Gr. CONF-632) for funding the workshop entitled "Enteseal Changes and Reconstruction of Human Behavior: Towards Standardization" hosted by CIAS (Research Centre for Anthropology and Health, University of Coimbra, Portugal) with support from CRIA (Centro em Rede de Investigação em Antropologia, Universidade de Nova, Lisbon, Portugal). We wish to extend our thanks to the members of the other working groups for their contributions to our discussions: R. Jurmain, M. Millella, F. Alves Cardoso, S. Assis and N. Speith. A final thank you to the student volunteer, Joana Dinis, who provided assistance throughout the workshop. We also wish to thank the Department of Life Sciences at the University of Coimbra for allowing access to the identified skeletal collection. We further thank W. Reichmann, who took the pictures of EC in this paper together with D. Pany-Kucera after the workshop "Scoring enteseal changes" at the 18<sup>th</sup> Paleopathology Association meeting in Vienna, Austria, with the permission of M. Teschler-Nicola. The copyright of the pictures is retained by the Natural History Museum Vienna, Austria.

The first author's (C. Henderson) contribution to this paper is funded by Portuguese national funds from FCT – Fundação para a Ciência e a Tecnologia SFRH/BPD82559/2011 and their research centre funding to CIAS (FCT/Pest-OE/SADG/UI0283/20113).



## References

- Couoh LR. 2013. Bioarchaeological analysis of a royal burial from the oldest Maya tomb in Palenque, Mexico. *International Journal of Osteoarchaeology*. DOI: 10.1002/oa.2338
- Davis CB, Shuler KA, Danforth ME, Herndon KE. 2013. Patterns of interobserver error in the scoring of enthesal changes. *International Journal of Osteoarchaeology* 23:147-151. DOI: 10.1002/oa.2277
- Havelková P, Hladík M, Velemínský P. 2013. Enthesal changes: Do they reflect socioeconomic status in the Early Medieval Central European population? (Mikulčice–Klášteřisko, Great Moravian Empire, 9th–10th century). *International Journal of Osteoarchaeology* 23:237-251. DOI: 10.1002/oa.2294
- Havelková P, Villotte S. 2007. Enthesopathies: Test of reproducibility of the new scoring system based on current medical data. *Slovenská Antropológia* 10:51-57
- Hawkey DE, Merbs CF. 1995. Activity-induced musculoskeletal stress markers (MSM) and subsistence strategy changes among ancient Hudson Bay Eskimos. *International Journal of Osteoarchaeology* 5:324-338. DOI: 10.1002/oa.1390050403
- Henderson C. 2013. Subsistence strategy changes: The evidence of enthesal changes. *HOMO-Journal of Comparative Human Biology* 64:491-508. DOI: 10.1016/j.quaint.2013.07.032
- Henderson CY, Mariotti V, Pany-Kucera D, Villotte S, Wilczak CA. 2013. Recording specific features of fibrocartilaginous entheses: Preliminary results of the Coimbra standard method. *International Journal of Osteoarchaeology* 23:152-162. DOI: 10.1002/oa.2287
- Lieverse AR, Bazaliiskii VI, Goriunova OI, Weber AW. 2013. Lower limb activity in the Cis-Baikal: Enthesal changes among middle Holocene Siberian foragers. *American Journal of Physical Anthropology* 150:421-432. DOI: 10.1002/ajpa.22217
- Mariotti V, Facchini F, Belcastro MG. 2004. Enthesopathies - Proposal of a standardized scoring method and applications. *Collegium Anthropologicum* 28:145-159.
- Mariotti V, Facchini F, Belcastro MG. 2007. The study of entheses: Proposal of a standardised scoring method for twenty-three entheses of the postcranial skeleton. *Collegium Anthropologicum* 31:291-313.
- Palmer JLA, Hoogland MHL, Waters-Rist AL. 2014. Activity reconstruction of post-Medieval Dutch rural villagers from upper limb osteoarthritis and enthesal changes. *International Journal of Osteoarchaeology*. DOI: 10.1002/oa.2397.
- Santos AL, Alves-Cardoso F, Assis S, and Villotte S. 2011. The Coimbra workshop in musculoskeletal stress markers (MSM): An annotated review. *Antropologia Portuguesa* 28:135-161.
- Takigawa W. 2014. Age changes of musculoskeletal stress markers and their inter-period comparisons. *Anthropological Science* 122:7-22. DOI: 10.1537/ase.131207.
- Thomas A. 2014. Bioarchaeology of the middle Neolithic: Evidence for archery among early European farmers. *Am J Phys Anthropol* 154:279-290. DOI: 10.1002/ajpa.22504.
- Villotte S. 2006. Connaissances médicales actuelles, cotation des enthésopathies: Nouvelle méthode. *Bulletins et Mémoires de la Société d'Anthropologie de Paris* 18:65-85.
- Villotte S, Castex D, Couallier V, Dutour O, Knüsel CJ, and Henry-Gambier D. 2010. Enthesopathies as occupational stress markers: evidence from the upper limb. *American Journal of Physical Anthropology* 142: 224–34. DOI:10.1002/ajpa.21217.

Table 1. This table is a summary of the method. Absence of changes should be scored as zero. Score the maximum extent of the fibrocartilaginous enthesis footprint. Please consult photographs in conjunction with this table. If changes could be due to taphonomy and you are not able to decide score as unobservable.

Zone	Feature	Abbrev.	Definition	Degrees of expression
Zone 1	Bone Formation	BF (Z1)	See degrees of expression. Normal morphological smooth rounded or mound-like (check by touching) margins, even if the margin is elevated, should be scored as 0 (Fig. 1C).	1= distinct sharp demarcated new bone formation along the margin or other enthesophyte which does not meet the criteria for stage 2 in terms of size or extent (Fig. 2A) 2= distinct sharp demarcated new bone formation along the margin or other enthesophyte $\geq 1$ mm in elevation and $\geq 50\%$ of margin affected by new bone formation (Fig. 2B)
	Erosion	ER (Z1)	Depressions or excavations of any shape and involving discontinuity of the floor of the lesion greater in width than depth with irregular margins. Only erosions $>1$ mm, where you can clearly see the floor, were recorded. This does not include pores (i.e. rounded margins). Score erosions if they occur on bone formation.	1= $<25\%$ of margin (Fig. 2C) 2= $\geq 25\%$ of margin
	Textural change	TC	A non-smooth, diffuse granular texture (with the appearance of fine grained sandpaper)	1= covering $>50\%$ of surface (Fig. 3A)
	Bone Formation	BF (Z2)	Any bone production from roughness of surface to true exostoses (e.g. distinct bone projections of any form, like bony spurs, bony nodules and amorphous bone formation).	1= distinct bone formation $>1$ mm in size in any direction and affecting $<50\%$ of surface (Fig. 2B) 2= distinct bone formation $>1$ mm in size in any direction and affecting $\geq 50\%$ of surface (Fig. 3B)
Zone 2	Erosion	ER (Z2)	Depressions or excavations of any shape (but not covered by the definition of macro-porosity) and involving discontinuity of the floor of the lesion greater in width than depth with irregular margins. Only erosions $>2$ mm were recorded. MPO or FPO occurring within an erosion should not be recorded separately. Bone formation is only scored if it exceeds the height of the depression (do not score woven bone). Score erosions if they occur on bone formation.	1= $<25\%$ of surface (Fig. 4A) 2= $\geq 25\%$ of surface (Fig. 4B)
	Fine Porosity	FPO	Small, round to oval perforations with smooth, rounded margins $<1$ mm. These should be visible to the naked eye and be in a localised area. Do not score if they are at the base of an erosion or if they occur as part of woven bone.	1= $<50\%$ of surface (Figs. 4A, 4B) 2= $\geq 50\%$ of surface
	Macro-porosity	MPO	Small, round to oval perforations with smooth, rounded margins about $1$ mm or larger in size with the appearance of a channel, but the internal aspect is rarely visible (Fig. 5). Do not score if they are at the base of an erosion.	1= one or two pores (Fig. 2C) 2= $>2$ pores (Fig. 4B)
	Cavitation	CA	Subcortical cavity with a clear floor which is not a channel (Fig. 5). The opening should be $>2$ mm and the whole floor must be visible.	1= 1 cavitation (Fig. 2B) 2= $>1$ cavitation

Table 2. Repeatability by feature and enthesis. Percentage agreement is given for each score and for presence/absence, where presence is a score >0.

	BF(Z1)	ER(Z1)	BF(Z2)	FPO	MPO	ER(Z2)	CA	DGT	Overall
Subscapularis	61.7%	95.0%	83.3%	68.3%	90.0%	76.7%	85.0%	95.0%	81.9%
Presence/absence	73.3%	95.0%	88.3%	73.3%	90.0%	83.3%	85.0%	95.0%	85.4%
CEO	86.7%	91.7%	68.3%	71.7%	76.7%	70.0%	85.0%	85.0%	79.4%
Presence/absence	86.7%	91.7%	68.3%	71.7%	76.7%	70.0%	85.0%	85.0%	79.4%

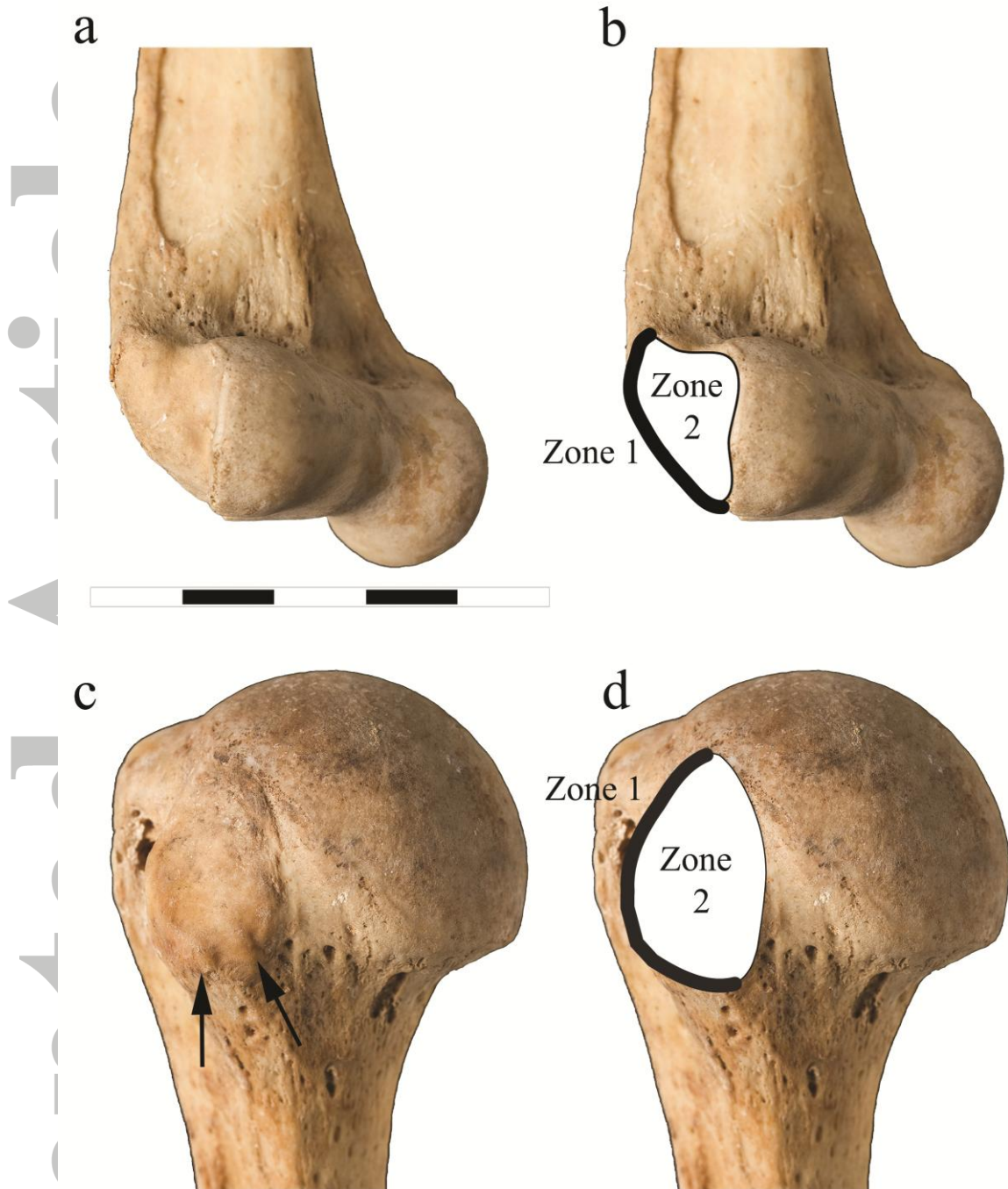


Figure 1. Extent of the enthesis and zone demarcations. 1A and B show the demarcation of Zones 1 and 2 on the right common extensor origin. 1C and D show the same on the right subscapularis insertion. Filled arrow shows normal surface morphology not to be confused with bone formation in Zone 1.

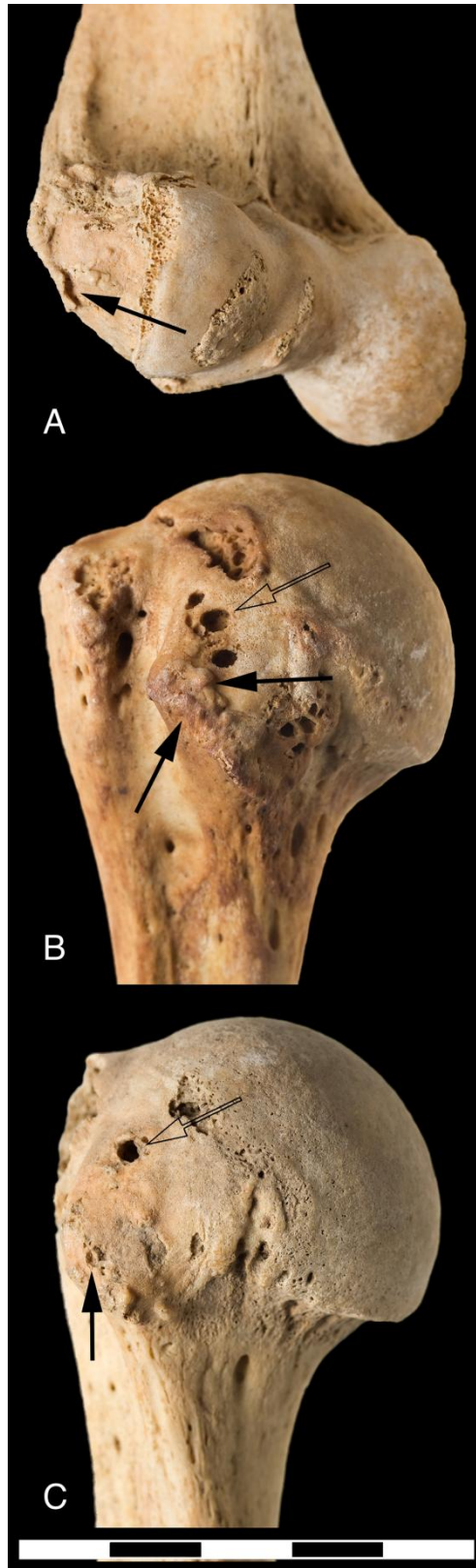


Figure 2. Changes in Zone 1. A. Bone formation in Zone 1 of the right common extensor origin score 1 (filled arrow). B. Bone formation in Zone 1 of the right subscapularis score 2 (filled arrow) with bone formation in Zone 2 score 1 (middle arrow) and cavitation score 1 (unfilled arrow). C. Right subscapularis insertion with an erosion in Zone 1 score 1 (filled arrow) and macro-porosity in Zone 2 score 1 (unfilled arrow).

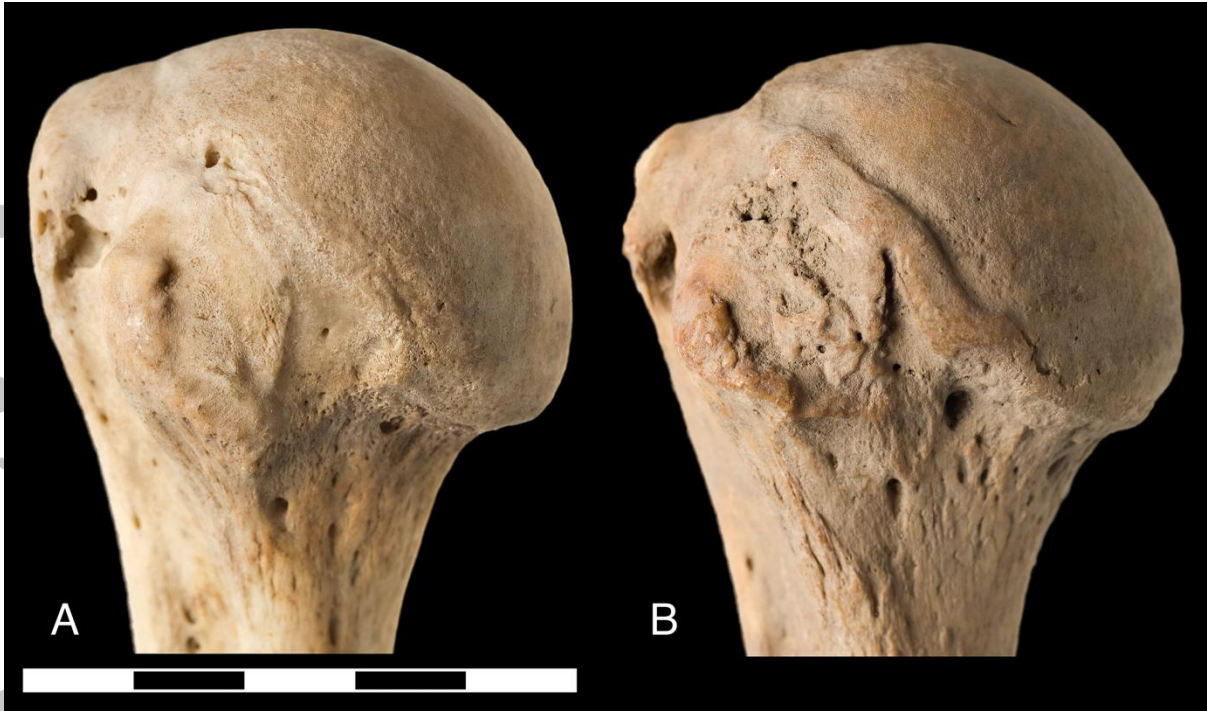


Figure 3. Bone formation in Zone 2. A. Right subscapularis insertion with textural change, NB to be scored this needs to cover a minimum of 50% of Zone 2. B. Right subscapularis insertion in Zone 2, score 2.

Accepted

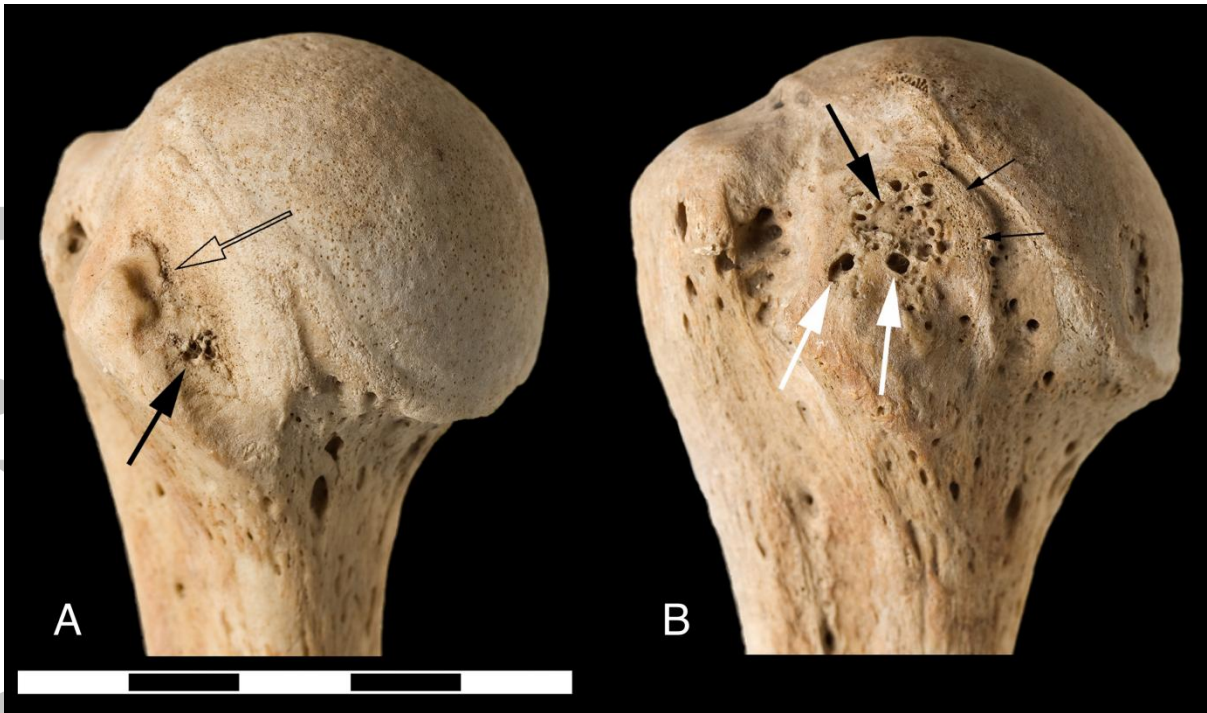


Figure 4. Erosions and porosity in Zone 2. A. Right subscapularis insertion with erosion, score 1 in Zone 2 (filled arrow) and fine porosity score 1 (unfilled arrow). B. Right subscapularis insertion with erosion in Zone 2, score 2 (large black filled arrow), macro-porosity, score 2 (white filled arrows), and fine porosity, score 1 (small filled arrows).

Accepted

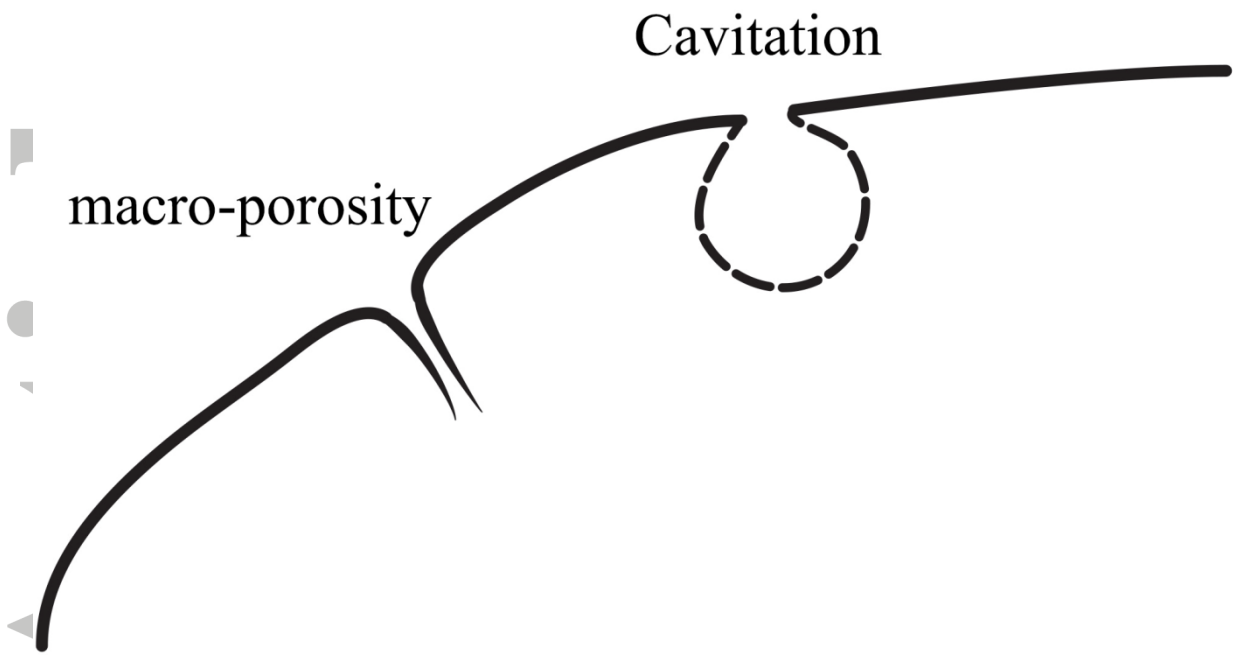


Figure 5. Illustration of the difference between macro-porosity (a channel-like structure) and a cavitation (a bowl-like structure with a clear floor).

Accepted