



HAL
open science

Amyloid-PET and 18F-FDG-PET in the diagnostic investigation of Alzheimer's disease and other dementias

Gaël Chételat, Javier Arbizu, Henryk Barthel, Valentina Garibotto, Ian Law, Silvia Morbelli, Elsmarieke van de Giessen, Federica Agosta, Frederik Barkhof, David Brooks, et al.

► To cite this version:

Gaël Chételat, Javier Arbizu, Henryk Barthel, Valentina Garibotto, Ian Law, et al.. Amyloid-PET and 18F-FDG-PET in the diagnostic investigation of Alzheimer's disease and other dementias. The Lancet Neurology, 2020, 19 (11), pp.951-962. 10.1016/S1474-4422(20)30314-8 . hal-03144347

HAL Id: hal-03144347

<https://hal.science/hal-03144347>

Submitted on 24 Oct 2022

HAL is a multi-disciplinary open access archive for the deposit and dissemination of scientific research documents, whether they are published or not. The documents may come from teaching and research institutions in France or abroad, or from public or private research centers.

L'archive ouverte pluridisciplinaire **HAL**, est destinée au dépôt et à la diffusion de documents scientifiques de niveau recherche, publiés ou non, émanant des établissements d'enseignement et de recherche français ou étrangers, des laboratoires publics ou privés.



Distributed under a Creative Commons Attribution - NonCommercial 4.0 International License

Amyloid and FDG-PET in the diagnostic work-up of Alzheimer's disease and other dementias

Authors

Gaël Chételat, Javier Arbizu, Henryk Barthel, Valentina Garibotto, Ian Law, Silvia Morbelli, Elsmarieke van de Giessen, Federica Agosta, Frederik Barkhof, David J Brooks, Maria C Carrillo, Bruno Dubois, Anders M Fjell, Giovanni B Frisoni, Oskar Hansson, Karl Herholz, Brian F Hutton, Clifford R Jack Jr, Adriaan A Lammertsma, Susan M Landau, Satoshi Minoshima, Flavio Nobili, Agneta Nordberg, Rik Ossenkoppele, Wim JG Oyen, Daniela Perani, Gil D Rabinovici, Philip Scheltens, Victor L Villemagne, Henrik Zetterberg, and Alexander Drzezga

Affiliations

Université Normandie, Inserm, Université de Caen-Normandie, Inserm UMR-S U1237, GIP Cyceron, Caen, France. (G Chételat PhD); Department of Nuclear Medicine, University of Navarra Clinic, Pamplona, Spain (Prof J Arbizu MD, PhD); Department of Nuclear Medicine, University Hospital of Leipzig, Leipzig, Germany (Prof. H Barthel MD PhD); Division of Nuclear Medicine and Molecular Imaging, Geneva University Hospitals and NIMTlab, Geneva University, Geneva, Switzerland (V Garibotto MD); Department of Clinical Physiology, Nuclear Medicine and PET, Copenhagen University Hospital, Rigshospitalet, Copenhagen, Denmark (Prof I Law MD DMSc); Nuclear Medicine Unit, IRCCS Ospedale Policlinico San Martino, Genova, Italy (Prof S Morbelli MD PhD); AMC Department of Radiology and Nuclear Medicine, Amsterdam University Medical Centers, Amsterdam, The Netherlands (E Van de Giessen MD PhD); Neuroimaging Research Unit, Institute of Experimental Neurology, Division of Neuroscience, San Raffaele Scientific Institute, Vita-Salute San Raffaele University, Milan, Italy (F Agosta PhD); Department of Radiology & Nuclear Medicine, Amsterdam University

Lancet Neurology
Green section, Personal View

Medical Center, Vrije Universiteit, Amsterdam, The Netherlands (Prof F Barkhof MD PhD); UCL Institutes of Neurology and Healthcare Engineering, London, UK (Barkhof); Institute of Neuroscience, Newcastle University and Department of Nuclear Medicine and PET Centre, Aarhus University Hospital, Aarhus, Denmark (Prof D Brooks MD DSc); Alzheimer's Association, Chicago, Illinois, United States of America (M Carrillo PhD); Centre des Maladies Cognitives et Comportementales (IM2A), University Hospital of Pitié Salpêtrière, AP-HP, Sorbonne-Université, Paris, France (Prof B Dubois MD); Center for Lifespan Changes in Brain and Cognition, Department of Psychology, University of Oslo and Department of Radiology and Nuclear Medicine, Oslo University Hospital, Oslo, Norway (Prof AM Fjell PhD); Memory Clinic, Department of Rehabilitation and Geriatrics, Geneva University and University Hospitals, Geneva, Switzerland (Prof GB Frisoni MD); Clinical Memory Research Unit, Lund University, Malmö, Sweden; Memory Clinic, Skåne University Hospital, Malmö, Sweden (O Hansson MD PhD); Wolfson Molecular Imaging Centre, Division of Neuroscience and Experimental Psychology, University of Manchester, Manchester, United Kingdom (Prof K Herholz MD); Institute of Nuclear Medicine, University College London, London, United Kingdom (Prof B Hutton PhD); Department of Radiology, Mayo Clinic, Rochester, Minnesota, United States of America (Prof C Jack MD); VUmc Department of Radiology & Nuclear Medicine, Amsterdam Neuroscience, Amsterdam University Medical Centers, Amsterdam, The Netherlands (Prof A A Lammertsma PhD); Helen Wills Neuroscience Institute, University of California, Berkeley, Berkeley, California, United States of America (Prof S Landau PhD); Department of Radiology and Imaging Sciences, University of Utah, Salt Lake City, Utah, United States of America (Prof S Minoshima MD PhD); Department of Neuroscience (DINO GMI), University of Genoa (Prof F Nobili MD); U.O. Clinica Neurologica, IRCCS Ospedale Policlinico San Martino, Genova, Italy (Prof F Nobili MD); Karolinska Institutet, Department NVS, Clinical Geriatrics, Center for Alzheimer Research, Stockholm, Theme Aging, Karolinska University Hospital, Sweden (Prof A Nordberg MD PhD); Alzheimer Center, Amsterdam University Medical Center, Amsterdam, The Netherlands and Clinical Memory Research Unit, Lund University, Lund, Sweden (R Ossenkoppele PhD); Rijnstate Hospital, Department of Nuclear Medicine, Arnhem, The Netherlands (Prof W J G Oyen MD); Vita-Salute San Raffaele University, Nuclear Medicine Unit San Raffaele Hospital and Division of Neuroscience San Raffaele Scientific Institute, Milan, Italy (Prof D Perani MD); Departments of Neurology, Radiology and Biomedical Imaging, University of California San Francisco, San Francisco, California, United

Lancet Neurology
Green section, Personal View

States of America (Prof G Rabinovici MD); Alzheimer Center, Amsterdam University Medical Centers, Amsterdam, The Netherlands (Prof P Scheltens MD); Department of Molecular Imaging and Therapy, Centre for PET, Austin Health & Department of Medicine, University of Melbourne, Austin Health, Heidelberg, Australia (A/Prof V Villemagne MD); Department of Psychiatry and Neurochemistry, Institute of Neuroscience and Physiology, the Sahlgrenska Academy at the University of Gothenburg, Mölndal, Sweden; Clinical Neurochemistry Laboratory, Sahlgrenska University Hospital, Mölndal, Sweden; Department of Neurodegenerative Disease, UCL Institute of Neurology, London, United Kingdom; UK Dementia Research Institute at UCL, London, United Kingdom (Prof H Zetterberg MD, PhD); Department of Nuclear Medicine, Medical Faculty and University Hospital Cologne, University of Cologne, Cologne, Germany & German Center for Neurodegenerative Diseases (DZNE), Bonn/Köln, Germany & Institute of Neuroscience and Medicine, Molecular Organization of the Brain (INM-2), Forschungszentrum Jülich, Jülich, Germany (Prof A Drzezga MD).

Corresponding author

Gaël Chételat, Université Normandie, Inserm, Université de Caen-Normandie, Inserm UMR-S U1237, GIP Cyceron, Caen, France.

chetelat@cyceron.fr

Summary

Various biomarkers are available to support diagnosis of neurodegenerative diseases in clinical and research settings. Among those are molecular imaging biomarkers, such as amyloid-PET and [¹⁸F]fluorodeoxyglucose (FDG)-PET that assess brain amyloid deposition and glucose metabolism, respectively. However, because evidence is not conclusive yet, there is confusion in the field regarding the optimal timepoint, combination, and order of these PET-biomarkers in the diagnostic work-up. After an agreement achieved among interdisciplinary experts in the field, weighting the specific utility of the individual biomarkers based on available evidence and clinical expertise, we propose a diagnostic algorithm suggesting the optimal timepoint for these PET-biomarkers, taking into account the other available established biomarkers, for early and differential diagnosis of neurodegenerative diseases that can lead to dementia. We propose three main diagnostic pathways with distinct biomarker sequences, in which amyloid and FDG-PET are placed at different positions in the diagnostic work-up, depending on the clinical presentation. Our proposal could maximize the information provided by each PET biomarker while considering their complementary strengths, i.e. proof of amyloidopathy for the former and assessment of the pattern and extent of neurodegeneration for the later. This proposed algorithm could support diagnostic decision making in specialist clinical settings with access to these biomarkers and should stimulate further research towards optimal diagnosis.

I. Introduction

The early and differential diagnosis of neurodegenerative diseases leading to dementia is still challenging.¹ The field is moving toward a biological definition of dementia, so that the role of biomarkers in diagnosis is becoming predominant.²⁻⁵ Considering other biomarkers, amyloid-PET and FDG-PET imaging provide valuable and complementary information.⁶⁻¹⁴ Therefore, these biomarkers are being used extensively for diagnosis of neurodegenerative diseases in research studies and are recommended by some guidelines for the diagnosis of AD and several non-AD neurodegenerative diseases.^{2,4,15,10,11} For various reasons, including cost, availability, and reimbursement (see below section IV on practical issues), the generalization of this use in all clinical settings is not feasible yet. However, many academic memory clinics already use these biomarkers to support assessment and management of patients.^{6,9} There is widespread evidence that combining biomarkers improves diagnostic accuracy.^{8,9} However, faced with an arsenal of biomarkers (Figure 1), uncertainty has arisen regarding appropriate combination and/or order of application of PET imaging for differential diagnosis of dementias, as there is no commonly accepted consensus or theoretical framework concerning how they should be combined. Recommendations for the ordering of these biomarkers into a meaningful sequence or combination are thus needed, since they are already in use.

This Personal View summarises recommendations and conclusions from an interdisciplinary group of experts comprised of nuclear medicine physicians, radiologists, neurologists, geriatricians, psychiatrists, clinical and basic neuroscientists and patient-advocates. These experts met at the European Association of Nuclear Medicine (EANM) Focus Meeting 2 (January 2019, Cannes, France) to discuss the role of PET imaging for early and differential diagnosis of neurodegenerative diseases leading to dementia (referred to as neurodegenerative diseases in what follows) and to converge on a diagnostic algorithm indicating the recommended order of tests depending on the clinical presentation. Our aim is not to provide an exhaustive review of the available evidence on the utility of PET imaging in dementia. Instead, we provide a consensual assessment of the optimal use of PET in the diagnostic process from the perspective of a group of experts, including clinicians involved in the care of patients with dementia. We judged biomarkers exclusively on the basis of their diagnostic qualities, while other

factors, such as regional differences in their availability or national differences in their reimbursement, are discussed (section IV) but not taken into account. As such, our recommendations are not intended to replace national or other guidelines. Rather, they aim at providing a decision aid for situations in which thorough etiological and biomarker-supported diagnostic assessment is desired and considered meaningful for individual clinical reasons. More specifically, these recommendations are designed to facilitate the decisions on when in the diagnostic workup each of the biomarkers can be used and combined in a meaningful way. Also, as this algorithm focusses on the most validated PET imaging biomarkers for dementia, it remains to be seen how the scenario will change in the future, once new PET markers such as tau-PET, new MRI techniques, or fluid biomarkers advance. Consequently, we first outline the current state of evidence on the complementary role of PET imaging in the diagnostic workup of neurodegenerative diseases and then propose a diagnostic algorithm. We also highlight the main challenges towards the clinical implementation of this algorithm, and indicate the main future research directions.

II. PET biomarkers in the differential diagnosis of mild cognitive impairment and dementia

Diagnosis of dementia is particularly difficult in the prodromal stages (when neuropathological changes may already be present but symptoms still mild), and also in atypical clinical presentations. In particular, the differential diagnosis between AD and either frontotemporal lobar degeneration (FTLD) or neurodegenerative parkinsonian syndromes (PS) may be very challenging, due to overlapping symptoms. Several lines of evidence support the use of PET neuroimaging within the framework of available biomarkers.^{5,10–13} In the following sections, we assess the advantages and disadvantages of the PET biomarkers – which provide the rationale for the diagnostic algorithm.

II.1. CSF biomarkers

The utility of PET imaging, and imaging biomarkers in general, has to face comparison with that of available and established cerebrospinal fluid (CSF) biomarkers. The diagnostic utility of core CSF biomarkers for AD pathology (A β 42/A β 40 ratio, total, and phosphorylated tau) is recognised by research guidelines,¹⁶ and these biomarkers are already in clinical use in many European countries in accordance with country-specific regulations. Reference methods and materials for CSF A β 42 assay standardization, as well as high precision clinical chemistry tests on fully automated instruments, are in place, which bodes well for full implementation with uniform reference limits in clinical practice.¹⁷ As compared to PET imaging biomarkers, the diagnostic information derived from CSF analysis is in part overlapping, in part complementary. Both methods provide insights on neurodegeneration, tau, and amyloid pathology. With regard to amyloid detection, both approaches are similarly validated and agreement between CSF and PET amyloid results is usually good, but not perfect.¹⁸ While CSF assessment is less expensive, PET allows better staging and monitoring of the extent and location of pathology. A list of advantages and disadvantages of CSF versus PET amyloid measures and recommendations for their use are summarised in Table 1. In greater detail, this question has been previously discussed elsewhere.¹⁹

II.2 FDG-PET imaging

In dementia, brain hypometabolism detected with FDG-PET is a marker of neurodegeneration (Table 1). FDG-PET is particularly useful for early diagnosis, since it can show characteristic patterns of AD neurodegeneration earlier than MRI in individuals with MCI who will convert to the Alzheimer's dementia.^{8,20,21} Previous studies have shown added value of FDG-PET over routine CSF or MRI tests to predict conversion to AD dementia in people with MCI, especially short term progression,^{8,22,23} with a drop in the misclassification rate from 32% (for CSF or MRI alone) to 20% for FDG-PET alone, and from 27% for CSF and MRI to 9% when adding FDG-PET.²² Insight on short-term (2-3 years) clinical progression is crucial for patients and families to plan the future and for the clinician to adapt the clinical monitoring, and to target those patients more suitable to undergo therapeutic interventions. Based on the typical temporoparietal pattern of hypometabolism, its negative predictive value, ranging from 77% (CI: 64-87%) to 95% (CI: 75-100%),^{24,25} and evidence supporting its validity for clinical use,^{9,24,26,27} FDG-PET is recommended for evaluating people with MCI suspected of having underlying

AD. FDG-PET has also proven to be useful to predict clinical outcome, at the individual level, in people with MCI who already had amyloid-PET. Thus, a normal FDG-PET scan would predict clinical stability during follow-up of several years (even in amyloid-positive cases)²⁸ while abnormal FDG-PET would be associated with increased risk of progressive cognitive deterioration (including in amyloid-negative cases).²⁹

FDG-PET is also useful for staging of disease and for differential diagnosis, because the patterns of brain hypometabolism are closely associated with type and severity of cognitive deficits, and relatively distinct in different neurodegenerative diseases and even among their variants.⁸ Characteristic patterns include posterior cingulate and temporal-parietal involvement in Alzheimer's disease (AD), and predominant frontal, peri-sylvian, and anterior temporal hypometabolism in the behavioural, non-fluent, and semantic variants of frontotemporal lobar degeneration (FTLD), respectively.^{8,22,30,31} Specific FDG-PET hypometabolism patterns also include atypical AD variants, primary progressive aphasias, and atypical parkinsonisms. FDG-PET is, therefore, included in the diagnostic criteria of several neurodegenerative diseases: 1) behavioural variant of FTLD;¹⁰ 2) primary progressive aphasias;¹¹ 3) dementia with Lewy bodies (DLB);¹² 4) progressive supranuclear palsy (PSP).³² The use of FDG-PET remains limited, however, with regard to definite validation of the neuropathology underlying the detected patterns of hypometabolism.

According to the 5-phase strategic roadmap defined to foster clinical validation of biomarkers, FDG-PET is the PET biomarker that has reached the most advanced phase of validation.⁹ Analytical validity (phase 1) is completed, clinical validity (phases 2 and 3) almost achieved, and preliminary evidence for clinical utility (phase 4 and 5) is available.⁹

II.3. Amyloid-PET imaging

Amyloid-PET is an established neuroimaging technique with standardised tracer-specific visual reading procedures, and documented high reproducibility across PET centres. It allows non-invasive *in vivo* detection of amyloid plaques, one of the main neuropathological landmarks of Alzheimer's disease with very high sensitivity and specificity in patients with confirmed AD (96%, CI 80-100% and 100%, CI 78-100 respectively in people who had autopsy within 1 year of PET imaging).³³ Amyloid-PET also allows detection of amyloid-pathology in the clinically atypical variants of AD such as posterior cortical atrophy, the frontal-executive variant or in the

logopenic variant.^{31,34} It does however not allow to differentiate between distinct amyloid-positive disorders which may show similar amyloid-deposition patterns.

Many amyloid tracers have been developed,³⁵ three of which have reached clinical approval and commercial availability: ¹⁸F-florbetapir (Amyvid™), ¹⁸F-florbetaben (NeuraCeq®), and ¹⁸F-flutemetamol (Vizamyl™). They are essentially equivalent in clinical practice,^{8,35} and standardisation approaches have been developed to allow for direct quantitative comparison between the different tracers.³⁶ A meta-analysis of studies evaluating amyloid-PET's ability to predict MCI conversion to the Alzheimer's clinical syndrome of dementia demonstrated a sensitivity of 93% (CI: 71.3-99.9%) and a specificity of 56% (CI: 47.2-64.8%).⁷ When comparing the ability to predict progression to Alzheimer's clinical syndrome of dementia, a slightly higher sensitivity has been reported for amyloid-PET over FDG-PET, although FDG-PET has a higher specificity and a better accuracy for predicting short-term progression.^{23,37} A recent report shows that in amyloid positive cognitively unimpaired and MCI individuals, a negative FDG-PET was associated with clinical stability for several years.²⁸ This may be due to the fact that amyloid-pathology may appear long before onset of clinical symptoms. Indeed, positive amyloid scans are found in 10% to 44% of cognitively unimpaired elderly aged 50 to 90 years old, with yet unknown clinical relevance.³⁸ Currently, amyloid imaging alone is considered insufficient to predict time to clinical conversion in prodromal and asymptomatic stages. Also, the value of amyloid-imaging for disease staging may be limited, as it does not show close correlation with symptom severity and develops a plateau in later disease stages.^{37,39}

Amyloid imaging has almost achieved analytical validity (phase 1) and clinical validity (phases 2 and 3).⁹ Yet, more data is needed using the harmonised procedure to improve reliability of results across tracers and on the effects of covariates (e.g. age, sex, *APOE* genotype, disease duration, comorbidities) on controls and patients. Regarding the clinical utility of amyloid-PET, meta-analyses have consistently shown that amyloid imaging is associated with changes in aetiological diagnosis, increases in diagnostic confidence, and changes in patient management in up to 60% of subjects.^{40,41} These changes are more often due to a negative amyloid-PET result and more frequently in older (>65 years) patients. Such a case study is illustrated in Panel 3.⁴² Appropriate use criteria for amyloid-PET have been proposed, identifying the following patient populations as the most likely to benefit from the procedure:⁴³ (1) people with MCI in which clinical uncertainty exists (2) patients with a dementia syndrome suggestive of AD, but with an atypical presentation or suspected mixed etiology; and (3) patients with

early-onset progressive cognitive decline. A very large prospective multicentre trial (IDEAS), including already more than 11 000 participants, recently demonstrated that amyloid-PET performed in patients selected according to the AUC-criteria resulted in a change in management in a relevant proportion (about 60% of patients)⁴⁴ – which strongly justifies the application of this method in the corresponding population. Other studies have shown that amyloid imaging can also have clinical utility in individuals not fulfilling the AUC criteria.^{42,45,46} This includes subjects with clinical probable AD (who may be amyloid-negative), patients with atypical non-amnesic phenotypes of cognitive impairment who do not fulfil criteria for “possible” AD and subjects with subjective cognitive decline.^{34,47,48} Another large multicentre study (AMYPAD-DPMS; registration number EudraCT: 2017-002527-21)⁴⁹ is ongoing including patients beyond AUC criteria, e.g. fulfilling criteria for probable AD or for subjective cognitive decline, that would allow provide answers regarding the clinical impact and utility of amyloid imaging in these populations (see supplementary materials).

II.4. PET biomarkers in the FTLD spectrum

The complexity of dementia clinical diagnosis is well illustrated within the FTLD spectrum, the family of clinically and neuropathologically heterogeneous disorders characterised by progressive degeneration of the frontal or anterior temporal lobes.⁴⁸ Symptoms of FTLD may notably resemble those of AD particularly of its atypical forms. FDG-PET has a long-standing role in the diagnosis of FTLD based on signature patterns of hypometabolism associated with specific clinical syndromes.^{49–51} Recently, amyloid-PET has proven useful in discriminating AD from FTLD aetiologies, since amyloid plaques are a core feature of AD neuropathology but typically not part of the FTLD neuropathological spectrum.^{50,52} The major advantage of amyloid-PET over FDG-PET is that it can highlight a specific pathology when FDG-PET cannot inform on the pathological aetiology underlying a metabolic abnormality.⁵³ Because of its high sensitivity to detect fibrillar amyloid pathology, a negative amyloid-PET scan can also be used to reliably rule out AD as the underlying aetiology in patients with complex presentations such as primary progressive aphasia variants (or corticobasal syndrome – see below).^{54,55} In general, amyloid-PET is useful when a differential diagnosis between AD and non-AD causes of dementia is needed. FDG-PET can further address differential diagnosis within the FTLD spectrum in amyloid negative

patients, or when the final diagnosis is still unclear after amyloid-PET and/or CSF analyses, (e.g. in patients with mixed pathological features).

II.5. Neuroimaging biomarkers in parkinsonian syndromes with cognitive decline

Parkinsonian syndromes causing dementia include Parkinson's disease (PD), DLB, PSP, and corticobasal degeneration. The assessment of integrity of the nigrostriatal dopaminergic pathway with DaT-SPECT has been approved by the United States Food & Drug Administration and the European Medicines Agency to support the differential diagnosis between DLB and AD. The availability of this tool has increased the diagnostic accuracy for DLB, which is usually difficult due to overlapping symptoms with AD, vascular cognitive impairment, and even FTLT.¹² Some DLB patients may not show all of the core clinical symptoms (e.g. they may present with minor or even no apparent PS). The use of DaT-SPECT should also be considered in these cases, e.g. if other core clinical features of DLB such as fluctuation, visual hallucinations or REM sleep behaviour disorder are observed, especially given the side effects observed in DLB patients to neuroleptics sometimes prescribed in patients with dementia.⁵⁸ Since dopaminergic deficits can be present in all neurodegenerative PS, DaT-SPECT cannot be used for the differential diagnosis between these diseases. In contrast, FDG-PET can distinguish between specific patterns of hypometabolism of PD/DLB and all other neurodegenerative PS. FDG-PET has thus been recommended for differential diagnosis within neurodegenerative PS by the EANM-EAN taskforce.^{59,60} PS are also systemic disorders, and in particular, [¹²³I]meta-iodobenzylguanidine (mIBG) myocardial scintigraphy assessing cardiac sympathetic nerve endings has been included in the clinical flow chart for the differential diagnosis between AD and DLB, as well as between PD and other neurodegenerative PS.^{12,61} When neurodegenerative PS is suspected, either mIBG scanning or FDG-PET could be considered depending on experience and availability (see Figure 2 for details).⁵⁹

III. Proposed algorithm for differential diagnosis

Based on the evidence summarised above on the relative strengths and limitations of each biomarker and their complementarity, but also relying on pragmatic considerations on how to reach a conclusion in a specific clinical situation, we propose a diagnostic algorithm reflecting the optimal combination of biomarkers according to different clinical situations (Figure 2). Further information concerning methodology used for reaching agreement among the co-authors of this Personal View are provided as supplementary materials. In addition to potentially supporting diagnostic decision making in specialized centers, this diagnostic algorithm is proposed as a theoretical framework to guide research and to establish a standard for comparison with alternative algorithms (see validation section IV.1.)

III.1. Structural imaging as a first step

In situations when biomarker-based diagnostic work-up is clinically needed to establish a reliable etiological diagnosis, structural imaging is recommended as the very first step following clinical and neuropsychological evaluation, before other imaging biomarkers. Indeed, structural neuroimaging allows detecting other pathologies that might be responsible for cognitive decline (e.g. hydrocephalus, tumours, or vascular lesions, although the contribution of vascular lesions to the observed cognitive deficits cannot be determined with structural imaging).⁶² Furthermore, structural imaging can help assess the presence and degree of co-morbidities (e.g. vascular) frequently found in neurodegenerative disorders, which can affect the clinical manifestation and may be treatable. In addition, topographical patterns of atrophy assessed by structural imaging are associated with specific neurodegenerative conditions,⁶³ whereas the overall degree of atrophy is associated with disease-specific clinical features and severity, and tracks the progression of neurodegeneration.^{62,64} Regarding the structural imaging modality, MRI has frequently been considered as a superior tool, as compared with computed tomography (CT) for dementia workup.⁶⁵ However to date there is no strong evidence towards recommending the one or the other.

III.2. A three-pathway algorithm

In general, after the clinical/neuropsychological evaluation and structural imaging, the added value of other diagnostic biomarkers may be especially high in cases with clinical diagnostic uncertainty (e.g. atypical appearance or mixed presentation such as combined cognitive, behavioural, and motor symptoms).^{8,9} Moreover, the choice of further diagnostic assessment should account for factors influencing pre-test probability (*APOE* genotype, family history, etc.) as well as the potential consequences of the diagnosis. If consequences of the diagnosis are limited (e.g. other comorbidities dominating patient prognosis or lack of therapeutic alternatives in patients presenting with severe dementia) and once treatable conditions are excluded, there might not be a strong reason to further strive to obtain an aetiological diagnosis with molecular imaging. Also, the diagnostic benefits of additional biomarker tests in the individual situation should be considered. For example, rates of amyloid positivity increase with age in *APOE* $\epsilon 4$ carriers, and the likelihood that the presence of amyloid is not responsible for cognitive decline or predictive of cognitive decline increases in very old *APOE* $\epsilon 4$ carriers.⁵⁷ By contrast, a positive amyloid-PET scan is particularly helpful for ruling in AD in the differential diagnosis of early-onset dementia patients, since the a priori risk of incidental age-related amyloid pathology is low in young patients. These considerations are taken into account in the proposed algorithm indicating three different pathways with distinct sequences of tests for situations in which additional biomarker assessment is required after clinical assessment and structural imaging, with amyloid biomarkers, FDG-PET, or dopamine transporter (DaT)-SPECT being the preferred subsequent step depending on the clinical presentation. These different pathways are detailed in Figure 2.

IV. Practical challenges and limitations of the algorithm

The suggested algorithm is based on existing evidence but also on several assumptions and expert opinions. Thus, several aspects will require further clarification and additional research in the future and some controversies also remained among the authors. These aspects are further discussed below.

IV.1. Validation

The algorithm is a theoretical proposal based on evidence and pragmatic considerations on how to reach a conclusion in a specific clinical situation, reflecting in depth discussions and converging agreement of experts from various disciplines. It is proposed as a timely model to support and potentially homogenize heterogeneous clinical practice, and to structure research and serve as a basis to future development and comparison to alternative models. There is extensive evidence of analytical and early clinical validity for individual biomarkers, but more evidence is needed on multimodal imaging approaches and, particularly, the order of tests. The systematic validation of each arm of the algorithm will be challenging given the high number of possible combinations. However, the added value for diagnosis of the specific combinations shown in the proposed algorithm will have to be demonstrated and compared to alternative algorithms that might arise based on new evidence and/or possible distinct pragmatic considerations.

IV.2. Practical issues: availability, adverse effects, cost-effectiveness and sustainability

The widespread and consistent use of biomarkers not only relies on their performance for early and differential diagnoses, but also on more practical issues such as training status, availability of and distance to PET scanners and cyclotrons, and adverse effects (as listed in Table 2). These considerations have not been taken into account in this Personal View, because our focus has been purely on the diagnostic value of the individual biomarkers. Thus, these questions will require attention in future studies.

Because PET imaging can be relatively expensive (the cost of an amyloid-PET scan for instance is 2000–2500 € in Europe and 3000–4500 US\$ in the United States), the issue of cost-effectiveness is particularly relevant in the context of lacking effective treatment. There is no sufficient evidence available yet on the impact of biomarkers on disease burden or cost-effectiveness (Phase 5 secondary aim).⁹ Overall, an examination with high sensitivity and specificity enhances diagnostic confidence and might reduce costs and the number of patient visits and additional tests, as it has been demonstrated for amyloid PET imaging.^{66,67} Objective evidence from health economic studies is needed to systematically assess cost-effectiveness and ideally considering various situations of treatment availability and efficacy. In addition to cost-effectiveness, medical diagnostic tools in the future may have to face discussion with regard to sustainability. Indeed, imaging instrumentations require considerable amount of energy with regard to operation, cooling and computer technology.⁶⁸

IV.3. Reimbursement

Reimbursement of imaging tests from payers varies considerably across the world.⁹ The right-to-know of the patients may need to be balanced against the economic circumstances and possibilities of the respective health care systems. Reimbursement of FDG-PET is mainly provided for the differential diagnosis of AD versus FTD in the US and many European countries. Amyloid PET is available in most high-income countries but reimbursement is limited.⁹ In 2013, the US Centers for Medicare & Medicaid Services issued a National Coverage Decision concluding yet insufficient evidence of clinical utility to justify general reimbursement for amyloid-PET.⁶⁹ However, they agreed to cover scans in clinical studies investigating whether amyloid-PET improves health outcomes. Understandably, health systems are extremely cautious to endorse any expensive test which might be indicated in a large segment of the population. This could change dramatically, once disease-modifying drugs become available.

IV.4. Ethical aspects of early diagnosis and disclosure of biomarker information

Disclosing information on early ongoing neurodegenerative disease or even prediction is linked to major ethical considerations. From the patient perspective, the right-to-know and the right not to know should be taken into account. On the one hand disclosing such serious information may cause anxiety and worry, potentially even long before symptomatic onset of disease and without access to therapy options. On the other hand, early and accurate diagnosis allows people with dementia diseases and their families to build a care team and seek education and support services. It provides an opportunity for creating advance directives and financial planning, enables earlier access to appropriate treatments, and opens opportunities for enrolment in clinical trials. A recent study concerning the potential benefits of the clinical use of amyloid-PET showed that over 80% of patients and caregivers would support use and reimbursement of the test to inform legal, financial, and long-term health care choices.⁷⁰ Further research is required in this area and in ongoing studies, the context for appropriately disclosing the results of the test to patients and families are being defined.⁷¹

IV.5. Alternatives to the diagnostic algorithm

It needs to be emphasized that the in part cost- and energy-expensive biomarker tests discussed here will not in all cases be able to solve the diagnostic problem, even when applied in a systematic order or combination.

Furthermore, the potential benefit for the individual patient needs to be carefully reflected, when considering the available options for biomarker-supported diagnosis. Depending on the situation of the patient with regard to age, stage of disease, psychological constitution, comorbidities, etc., the diagnostic strategies may considerably deviate from a standardized pathway. It is essential to involve patients and their caregivers into this decision. Thus, in the clinical work-up of neurodegenerative disorders, the most important factor remains to be the discussion with the patients and their caregivers about the meaning of the symptoms, the prognosis and the therapeutic options as well as about the value and the consequences of further diagnostic steps. Particularly in view of the often still limited therapeutic options, other strategies such as watchful waiting or systematic clinical-neuropsychological follow-up examinations may represent preferable alternatives.

IV.6. Controversies with regard to disease models

There are many questions unresolved regarding the development of neurodegenerative disorders and the answers to these questions may in the future affect the way diagnostic questions are asked or how diagnostic algorithms will be drafted. The dominant hypothesis in Alzheimer's disease up to now is the amyloid hypothesis, whereby amyloid deposition is considered as an early causal event of the disease.⁷² This hypothesis has led to the amyloid/tau/(neurodegeneration) (A/T/(N)) model (see supplementary materials),² which is well-accepted but also stimulated much debate and criticisms.⁷³⁻⁷⁵ Multimodal imaging may allow testing and possible revision of these models, and it has already stimulated consideration of alternative models, including the dual pathway hypothesis, amyloid-independent mechanisms, and the vascular hypothesis.⁷⁶⁻⁸⁰ However, while drafting the diagnostic algorithm, we aimed at providing a model with diagnostic value largely on the basis of commonly agreed facts and independently from still controversial concepts and assumptions on disease causality.

V. Conclusion and future directions

The panellists at EANM Focus Meeting 2 agreed on recommendations regarding the use of PET imaging within the scope of available biomarkers for early and differential diagnosis of neurodegenerative diseases. After clinical/neuropsychological evaluation and structural imaging when needed, the decision on necessity and choice of the next biomarker depends on the specific clinical profile and the individual diagnostic question. Amyloid-PET allows to detect amyloidosis *in vivo* in a standardized fashion and has high negative predictive value toward Alzheimer's disease. Compared with amyloid CSF biomarkers, amyloid-PET is used to determine the location and extent of pathology, and detect brain areas of earliest amyloid accumulation⁸¹ and changes over time.^{35,39} FDG-PET allows to detect neurodegeneration with greater sensitivity than structural MRI. Compared with CSF neurodegeneration biomarkers, topographical information on neurodegeneration obtained with FDG-PET (patterns of hypometabolism) is closely associated to type and severity of cognitive deficits, making this biomarker particularly useful for differential diagnosis, staging of disease extent and predicting short-term progression.^{8,29} Based on our current knowledge of the respective advantages and disadvantages of each biomarker together with logical and pragmatic considerations, the authors converged towards a diagnostic algorithm for the optimal combination of biomarkers depending on the clinical condition. The implementation of this algorithm in clinical practice will have to face challenges related with practicality, cost-effectiveness, ethical considerations, validation, controversies surrounding the underlying pathophysiological model and integration of future biomarker developments. There are currently numerous technologies, other tracers and biomarkers under development (see supplementary materials), which may open new diagnostic avenues and have an impact on the proposed algorithm. Importantly, advanced approaches/instrumentation such as integrated PET/MR imaging in combination with dual-phase PET acquisition may allow to acquire multimodal imaging in a one-stop manner, while remaining cost-effective and logistically feasible, thus omitting the need to decide on sequences of tests.⁸² Other most interesting future options include tau-PET which has recently obtained FDA-approval for one tracer in the US, synaptic density imaging, inflammation imaging, and blood biomarkers, as well as improvement of PET quantification methods or scanner equipment.

Contributors

GC, JA, HB, VG, IL, SMO, and EvdG are part of the EANM Neuroimaging committee and the EANM Focus 2 Meeting Scientific Committee. JA, HB, VG, IL, SMO, and EvdG contributed equally to this work. FA, FB, DJB, MC, BD, AMF, GBF, OH, KH, BH, CJ, AL, SL, SMi, FN, AN, RO, WO, DP, GR, PS, VV, HZ, and AD were all members of the EANM Focus 2 expert panel, contributed to the content of the study, and reviewed the paper and PS also provided the case study.

Declaration of interests

HB, MC, GC, AMF, VG, AL, IL, FN, AN, RO, WO, DP, and EvdG have nothing to declare.

GC has received research support from the European Union's Horizon 2020 research and innovation program (grant agreement N° 667696), Inserm, Fondation d'entreprise MMA des Entrepreneurs du Futur, Fondation Alzheimer, Programme Hospitalier de Recherche Clinique, Région Normandie, Association France Alzheimer et maladies apparentées and Fondation Vaincre Alzheimer (all to Inserm), and personal fees from Fondation d'entreprise MMA des Entrepreneurs du Futur. No stock options, patents, or royalties.

GBF has received research funds and personal fees from GE Healthcare, Avid Lilly, and Life Molecular Imaging; FA reports personal fees from Elsevier INC, personal fees from Biogen Idec, personal fees from Novartis, outside the submitted work; JA reports grants from General Electric, grants from Piramal, grants from Lilly-Avid, personal fees from Biogen, personal fees and non-financial support from Araclon, personal fees and non-financial support from Advanced Accelerator Applications, personal fees from Bayer, outside the submitted work; FB reports consultancies for Bayer-Schering Pharma, Biogen-Idec, TEVA, Merck-Serono, Novartis, Roche, Jansen Research, Genzyme-Sanofi, IXICO Ltd, GeNeuro, and Apitope, grants for AMYPAD (IMI), EuroPOND (H2020), UK MS Society, Dutch MS Society, PICTURE (IMDI-NWO), NIHR UCLH Biomedical Research Centre (BRC), ECTRIMS-MAGNIMS, speakers' bureau for Biogen-IDEC and IXICO; DJB reports grants and personal fees from GE Healthcare, outside the submitted work; AD reports personal fees and non-financial support from GE Healthcare, personal fees and non-financial support from Life Molecular Imaging (Piramal), personal fees and non-financial support from Lilly / Avid, during the conduct of the study, grants, personal fees

and non-financial support from Siemens Healthcare, outside the submitted work, and has a PSMA patent pending; BD reports personal fees from Biogen-Boehringer Ingelheim, grants from Merck Foundation for IM2A, outside the submitted work; KH reports grants from GlaxoSmithKline, outside the submitted work; BH reports other from GE Healthcare, other from Siemens, other from GSK, outside the submitted work; CJ consults for Lily and serves on an independent data monitoring board for Roche but he receives no personal compensation from any commercial entity. He receives research support from NIH and the Alexander Family Alzheimer's Disease Research Professorship of the Mayo Foundation, other from Lily, other from Roche, outside the submitted work; OH has acquired research support (for the institution) from Roche, GE Healthcare, Biogen, AVID Radiopharmaceuticals and Euroimmun. In the past 2 years, he has received consultancy/speaker fees (paid to the institution) from Biogen and Roche; SL reports personal fees from Cortexyme, Inc, personal fees from NeuroVision, outside the submitted work; SMi reports consultancy for Hamamatsu Photonics; SMO reports speaker's honoraria from GE Healthcare; GR reports grants from NIH, grants from Alzheimer's Association, grants from American College of Radiology, grants from Tau Consortium, grants from Michael J. Fox Foundation, grants from Association for Frontotemporal Degeneration, grants from Avid Radiopharmaceuticals, grants from Eli Lilly, grants from GE Healthcare, grants from Life Molecular Imaging, personal fees from Genentech, personal fees from Merck, personal fees from Eisai, from Lundbeck, outside the submitted work; PS reports other from Medavante, other from ProBiodrug AG, other from EIP Pharma, other from Novartis AG, other from Toyama, outside the submitted work; VV reports grants from Life Molecular Imaging, grants from Avid Radiopharmaceuticals, grants from GE Healthcare, outside the submitted work; HZ reports that he has served at scientific advisory boards of Roche Diagnostics, Samumed, Wave and CogRx and has given open lectures sponsored by Alzecure.

Acknowledgements

The authors acknowledge John Bean PhD (Bean Medical Writing, Halle, Belgium and funded by EANM) for providing medical writing services which included taking the minutes of the EANM Focus 2 meeting, amending

text of the article to include EANM Focus Meeting 2 content, editing drafts to improve the accuracy of language, flow, organization, structure, and overall readability, and checking for grammatical and spelling errors. The authors also acknowledge Susanne Koebe, Andreas Felser, Janine Effey, Petra Neubauer, Hanna Krippel, and Henrik Silber (EANM) for project management. This research was funded by the European Association of Nuclear Medicine and supported by unrestricted grants from Siemens Healthineers, Biogen, Cerveau Technologies, Life Molecular Imaging, and Lilly. These sponsors had no direct or indirect influence on the programme and content of the EANM Focus 2 meeting and the writing or content of this article. FB and BH are supported by the NIHR University College London Hospitals Biomedical Research Centre. The AMYPAD project has received funding from the Innovative Medicines Initiative 2 Joint Undertaking under grant agreement No 115952. The IDEAS study was funded by the Alzheimer's Association, the American College of Radiology (ACR), Avid Radiopharmaceuticals, Inc. (a wholly owned subsidiary of Eli Lilly and Company), General Electric Healthcare and Life Molecular Imaging (formerly Piramal Imaging). The U.S. Centers for Medicare and Medicaid Services provided coverage for amyloid-PET scans in DEAS under coverage with evidence development.

References

- 1 Beach TG, Monsell SE, Phillips LE, Kukull W. Accuracy of the Clinical Diagnosis of Alzheimer Disease at National Institute on Aging Alzheimer Disease Centers, 2005–2010: *Journal of Neuropathology & Experimental Neurology* 2012; **71**: 266–73.
- 2 Jack CR, Bennett DA, Blennow K, *et al.* NIA-AA Research Framework: Toward a biological definition of Alzheimer’s disease. *Alzheimer’s & Dementia* 2018; **14**: 535–62.
- 3 McKhann GM, Knopman DS, Chertkow H, *et al.* The diagnosis of dementia due to Alzheimer’s disease: recommendations from the National Institute on Aging-Alzheimer’s Association workgroups on diagnostic guidelines for Alzheimer’s disease. *Alzheimers Dement* 2011; **7**: 263–9.
- 4 Dubois B, Feldman HH, Jacova C, *et al.* Advancing research diagnostic criteria for Alzheimer’s disease: the IWG-2 criteria. *The Lancet Neurology* 2014; **13**: 614–29.
- 5 Albert MS, DeKosky ST, Dickson D, *et al.* The diagnosis of mild cognitive impairment due to Alzheimer’s disease: Recommendations from the National Institute on Aging-Alzheimer’s Association workgroups on diagnostic guidelines for Alzheimer’s disease. *Alzheimer’s & Dementia* 2011; **7**: 270–9.
- 6 Teipel S, Drzezga A, Grothe MJ, *et al.* Multimodal imaging in Alzheimer’s disease: validity and usefulness for early detection. *The Lancet Neurology* 2015; **14**: 1037–53.
- 7 Zhang S, Han D, Tan X, Feng J, Guo Y, Ding Y. Diagnostic accuracy of 18F-FDG and 11C-PIB-PET for prediction of short-term conversion to Alzheimer’s disease in subjects with mild cognitive impairment. *International Journal of Clinical Practice* 2012; **66**: 185–98.
- 8 Laforce R, Soucy J-P, Sellami L, *et al.* Molecular imaging in dementia: Past, present, and future. *Alzheimers Dement* 2018; **14**: 1522–52.
- 9 Frisoni GB, Boccardi M, Barkhof F, *et al.* Strategic roadmap for an early diagnosis of Alzheimer’s disease based on biomarkers. *The Lancet Neurology* 2017; **16**: 661–76.
- 10 Rascovsky K, Hodges JR, Knopman D, *et al.* Sensitivity of revised diagnostic criteria for the behavioural variant of frontotemporal dementia. *Brain* 2011; **134**: 2456–77.
- 11 Gorno-Tempini ML, Hillis AE, Weintraub S, *et al.* Classification of primary progressive aphasia and its variants. *Neurology* 2011; **76**: 1006–14.
- 12 McKeith IG, Boeve BF, Dickson DW, *et al.* Diagnosis and management of dementia with Lewy bodies. *Neurology* 2017; **89**: 88–100.
- 13 Höglinger GU, Respondek G, Stamelou M, *et al.* Clinical diagnosis of progressive supranuclear palsy: The movement disorder society criteria. *Movement Disorders* 2017; **32**: 853–64.
- 14 Prestia A, Caroli A, Wade SK, *et al.* Prediction of AD dementia by biomarkers following the NIA-AA and IWG diagnostic criteria in MCI patients from three European memory clinics. *Alzheimers Dement* 2015; **11**: 1191–201.
- 15 McKhann GM, Knopman DS, Chertkow H, *et al.* The diagnosis of dementia due to Alzheimer’s disease: Recommendations from the National Institute on Aging-Alzheimer’s Association workgroups on diagnostic guidelines for Alzheimer’s disease. *Alzheimer’s & Dementia* 2011; **7**: 263–9.

- 16 Molinuevo JL, Ayton S, Batrla R, *et al.* Current state of Alzheimer's fluid biomarkers. *Acta Neuropathologica* 2018; **136**: 821–53.
- 17 Blennow K, Zetterberg H. Biomarkers for Alzheimer's disease: current status and prospects for the future. *J Intern Med* 2018; **284**: 643–63.
- 18 Leuzy A, Carter SF, Chiotis K, Almkvist O, Wall A, Nordberg A. Concordance and Diagnostic Accuracy of [11C]PIB PET and Cerebrospinal Fluid Biomarkers in a Sample of Patients with Mild Cognitive Impairment and Alzheimer's Disease. *Journal of Alzheimer's Disease* 2015; **45**: 1077–88.
- 19 Zetterberg H, Bendlin BB. Biomarkers for Alzheimer's disease—preparing for a new era of disease-modifying therapies. *Molecular Psychiatry* 2020; : 1–13.
- 20 Yuan Y, Gu Z-X, Wei W-S. Fluorodeoxyglucose–Positron-Emission Tomography, Single-Photon Emission Tomography, and Structural MR Imaging for Prediction of Rapid Conversion to Alzheimer Disease in Patients with Mild Cognitive Impairment: A Meta-Analysis. *American Journal of Neuroradiology* 2009; **30**: 404–10.
- 21 Caminiti SP, Ballarini T, Sala A, *et al.* FDG-PET and CSF biomarker accuracy in prediction of conversion to different dementias in a large multicentre MCI cohort. *NeuroImage Clinical* 2018; **18**: 167–77.
- 22 Shaffer JL, Petrella JR, Sheldon FC, *et al.* Predicting cognitive decline in subjects at risk for Alzheimer disease by using combined cerebrospinal fluid, MR imaging, and PET biomarkers. *Radiology* 2013; **266**: 583–91.
- 23 Blazhenets G, Ma Y, Sørensen A, *et al.* Predictive Value of 18F-Florbetapir and 18F-FDG PET for Conversion from Mild Cognitive Impairment to Alzheimer Dementia. *J Nucl Med* 2020; **61**: 597–603.
- 24 Arbizu J, Festari C, Altomare D, *et al.* Clinical utility of FDG-PET for the clinical diagnosis in MCI. *Eur J Nucl Med Mol Imaging* 2018; **45**: 1497–508.
- 25 Jagust W, Reed B, Mungas D, Ellis W, Decarli C. What does fluorodeoxyglucose PET imaging add to a clinical diagnosis of dementia? *Neurology* 2007; **69**: 871–7.
- 26 Nobili F, Arbizu J, Bouwman F, *et al.* European Association of Nuclear Medicine and European Academy of Neurology recommendations for the use of brain ¹⁸F-fluorodeoxyglucose positron emission tomography in neurodegenerative cognitive impairment and dementia: Delphi consensus. *European Journal of Neurology* 2018; **25**: 1201–17.
- 27 Smailagic N, Lafortune L, Kelly S, Hyde C, Brayne C. 18F-FDG PET for Prediction of Conversion to Alzheimer's Disease Dementia in People with Mild Cognitive Impairment: An Updated Systematic Review of Test Accuracy. *J Alzheimers Dis* 2018; **64**: 1175–94.
- 28 Iaccarino L, Sala A, Perani D, Alzheimer's Disease Neuroimaging Initiative. Predicting long-term clinical stability in amyloid-positive subjects by FDG-PET. *Ann Clin Transl Neurol* 2019; **6**: 1113–20.
- 29 Caroli A, Prestia A, Galluzzi S, *et al.* Mild cognitive impairment with suspected nonamyloid pathology (SNAP): Prediction of progression. *Neurology* 2015; **84**: 508–15.
- 30 Silverman DHS. Brain 18F-FDG PET in the diagnosis of neurodegenerative dementias: comparison with perfusion SPECT and with clinical evaluations lacking nuclear imaging. *J Nucl Med* 2004; **45**: 594–607.

- 31 Bergeron D, Gorno-Tempini ML, Rabinovici GD, *et al.* Prevalence of amyloid- β pathology in distinct variants of primary progressive aphasia. *Ann Neurol* 2018; **84**: 729–40.
- 32 Höglinger GU, Schöpe J, Stamelou M, *et al.* Longitudinal magnetic resonance imaging in progressive supranuclear palsy: A new combined score for clinical trials. *Movement disorders : official journal of the Movement Disorder Society* 2017; **32**: 842–852.
- 33 Clark CM, Pontecorvo MJ, Beach TG, *et al.* Cerebral PET with florbetapir compared with neuropathology at autopsy for detection of neuritic amyloid- β plaques: a prospective cohort study. *The Lancet Neurology* 2012; **11**: 669–78.
- 34 Dickerson BC, McGinnis SM, Xia C, *et al.* Approach to atypical Alzheimer’s disease and case studies of the major subtypes. *CNS Spectrums* 2017; **22**: 439–49.
- 35 Villemagne VL, Doré V, Bourgeat P, *et al.* A β -amyloid and Tau Imaging in Dementia. *Seminars in Nuclear Medicine* 2017; **47**: 75–88.
- 36 Klunk WE, Koeppe RA, Price JC, *et al.* The Centiloid Project: standardizing quantitative amyloid plaque estimation by PET. *Alzheimers Dement* 2015; **11**: 1-15.e1-4.
- 37 Mallik A, Drzezga A, Minoshima S. Clinical Amyloid Imaging. *Seminars in Nuclear Medicine* 2017; **47**: 31–43.
- 38 Jansen WJ, Ossenkoppele R, Knol DL, *et al.* Prevalence of cerebral amyloid pathology in persons without dementia: a meta-analysis. *JAMA* 2015; **313**: 1924–38.
- 39 Villain N, Chételat G, Grassiot B, *et al.* Regional dynamics of amyloid- β deposition in healthy elderly, mild cognitive impairment and Alzheimer’s disease: a voxelwise PiB–PET longitudinal study. *Brain* 2012; **135**: 2126–39.
- 40 Barthel H, Sabri O. Clinical Use and Utility of Amyloid Imaging. *Journal of Nuclear Medicine* 2017; **58**: 1711–7.
- 41 Fantoni ER, Chalkidou A, O’ Brien JT, Farrar G, Hammers A. A Systematic Review and Aggregated Analysis on the Impact of Amyloid PET Brain Imaging on the Diagnosis, Diagnostic Confidence, and Management of Patients being Evaluated for Alzheimer’s Disease. *Journal of Alzheimer’s Disease* 2018; **63**: 783–96.
- 42 de Wilde A, van der Flier WM, Pelkmans W, *et al.* Association of Amyloid Positron Emission Tomography With Changes in Diagnosis and Patient Treatment in an Unselected Memory Clinic Cohort. *JAMA Neurology* 2018; **75**: 1062.
- 43 Johnson KA, Minoshima S, Bohnen NI, *et al.* Appropriate use criteria for amyloid PET: A report of the Amyloid Imaging Task Force, the Society of Nuclear Medicine and Molecular Imaging, and the Alzheimer’s Association. *Alzheimer’s & Dementia* 2013; **9**: E1–16.
- 44 Rabinovici GD, Gatsonis C, Apgar C, *et al.* Association of Amyloid Positron Emission Tomography With Subsequent Change in Clinical Management Among Medicare Beneficiaries With Mild Cognitive Impairment or Dementia. *JAMA* 2019; **321**: 1286.
- 45 Altomare D, Ferrari C, Festari C, *et al.* Quantitative appraisal of the Amyloid Imaging Taskforce appropriate use criteria for amyloid-PET. *Alzheimer’s & Dementia* 2018; **14**: 1088–98.

- 46 Apostolova LG, Haider JM, Goukasian N, *et al.* Critical review of the Appropriate Use Criteria for amyloid imaging: Effect on diagnosis and patient care. *Alzheimer's & Dementia: Diagnosis, Assessment & Disease Monitoring* 2016; **5**: 15–22.
- 47 Salloway S, Sperling R, Fox NC, *et al.* Two Phase 3 Trials of Bapineuzumab in Mild-to-Moderate Alzheimer's Disease. *New England Journal of Medicine* 2014; **370**: 322–33.
- 48 Slot RER, Sikkes SAM, Berkhof J, *et al.* Subjective cognitive decline and rates of incident Alzheimer's disease and non-Alzheimer's disease dementia. *Alzheimer's & Dementia* 2018; published online Dec 13. DOI:10.1016/j.jalz.2018.10.003.
- 49 Frisoni GB, Barkhof F, Altomare D, *et al.* AMYPAD Diagnostic and Patient Management Study: Rationale and design. *Alzheimer's & Dementia* 2018; published online Oct 16. DOI:10.1016/j.jalz.2018.09.003.
- 50 Bang J, Spina S, Miller BL. Frontotemporal dementia. *The Lancet* 2015; **386**: 1672–82.
- 51 Rabinovici GD, Rosen HJ, Alkalay A, *et al.* Amyloid vs FDG-PET in the differential diagnosis of AD and FTL. *Neurology* 2011; **77**: 2034–42.
- 52 Santos-Santos MA, Rabinovici GD, Iaccarino L, *et al.* Rates of Amyloid Imaging Positivity in Patients With Primary Progressive Aphasia. *JAMA Neurology* 2018; **75**: 342.
- 53 Foster NL, Heidebrink JL, Clark CM, *et al.* FDG-PET improves accuracy in distinguishing frontotemporal dementia and Alzheimer's disease. *Brain* 2007; **130**: 2616–35.
- 54 Bouwman F, Orini S, Gandolfo F, *et al.* Diagnostic utility of FDG-PET in the differential diagnosis between different forms of primary progressive aphasia. *European Journal of Nuclear Medicine and Molecular Imaging* 2018; **45**: 1526–33.
- 55 Dubois B, Feldman HH, Jacova C, *et al.* Advancing research diagnostic criteria for Alzheimer's disease: the IWG-2 criteria. *The Lancet Neurology* 2014; **13**: 614–29.
- 56 Day GS, Lim TS, Hassenstab J, *et al.* Differentiating cognitive impairment due to corticobasal degeneration and Alzheimer disease. *Neurology* 2017; **88**: 1273–81.
- 57 Ossenkoppele R, Jansen WJ, Rabinovici GD, *et al.* Prevalence of Amyloid PET Positivity in Dementia Syndromes. *JAMA* 2015; **313**: 1939.
- 58 McKeith I, Fairbairn A, Perry R, Thompson P, Perry E. Neuroleptic sensitivity in patients with senile dementia of Lewy body type. *BMJ* 1992; **305**: 673–8.
- 59 Hellwig S, Amtage F, Kreft A, *et al.* [18F]FDG-PET is superior to [123I]IBZM-SPECT for the differential diagnosis of parkinsonism. *Neurology* 2012; **79**: 1314–22.
- 60 Walker Z, Gandolfo F, Orini S, *et al.* Clinical utility of FDG PET in Parkinson's disease and atypical parkinsonism associated with dementia. *European Journal of Nuclear Medicine and Molecular Imaging* 2018; **45**: 1534–45.
- 61 Tiraboschi P, Corso A, Guerra UP, *et al.* ¹²³I-2β-carbomethoxy-3β-(4-iodophenyl)-N-(3-fluoropropyl) nortropane single photon emission computed tomography and ¹²³I-metaiodobenzylguanidine myocardial scintigraphy in differentiating dementia with lewy bodies from oth. *Annals of Neurology* 2016; **80**: 368–78.

- 62 Frisoni GB, Prestia A, Rasser PE, Bonetti M, Thompson PM. In vivo mapping of incremental cortical atrophy from incipient to overt Alzheimer's disease. *Journal of Neurology* 2009; **256**: 916–24.
- 63 Koikkalainen J, Rhodius-Meester H, Tolonen A, *et al.* Differential diagnosis of neurodegenerative diseases using structural MRI data. *NeuroImage: Clinical* 2016; **11**: 435–49.
- 64 Gordon BA, Blazey TM, Su Y, *et al.* Spatial patterns of neuroimaging biomarker change in individuals from families with autosomal dominant Alzheimer's disease: a longitudinal study. *The Lancet Neurology* 2018; **17**: 241–50.
- 65 Albert MS, DeCarli C, DeKosky ST, *et al.* The Use of MRI and PET for Clinical Diagnosis of Dementia and Investigation of Cognitive Impairment. Report of the neuroimaging work group of the Alzheimer's Association. 2005.
- 66 Shea Y-F, Barker W, Greig-Gusto MT, Loewenstein DA, Duara R, DeKosky ST. Impact of Amyloid PET Imaging in the Memory Clinic: A Systematic Review and Meta-Analysis. *J Alzheimers Dis* 2018; **64**: 323–35.
- 67 Carswell CJ, Win Z, Muckle K, *et al.* Clinical utility of amyloid PET imaging with (18)F-florbetapir: a retrospective study of 100 patients. *J Neurol Neurosurg Psychiatry* 2018; **89**: 294–9.
- 68 Easty A, Varangu L, Knott J, Shi S, Waddington K. Energy Consumption Profiles of Common Types of Medical Imaging Equipment in Clinical Settings. In: Lhotska L., Sukupova L., Lacković I., Ibbott G. Springer, Singapore, 2019.
- 69 Jacques L, Jensen T, Rollins J, *et al.* Decision Memo for Beta Amyloid Positron Emission Tomography in Dementia and Neurodegenerative Disease (CAG-00431N). 2013. <https://www.cms.gov/medicare-coverage-database/details/nca-decision-memo.aspx?NCAId=265> (accessed Feb 8, 2019).
- 70 Mustafa R, Brosch JR, Rabinovici GD, *et al.* Patient and Caregiver Assessment of the Benefits From the Clinical Use of Amyloid PET Imaging. *Alzheimer Disease & Associated Disorders* 2018; **32**: 35–42.
- 71 Rabinovici GD, Karlawish J, Knopman D, Snyder HM, Sperling R, Carrillo MC. Testing and disclosures related to amyloid imaging and Alzheimer's disease: Common questions and fact sheet summary. *Alzheimer's & Dementia* 2016; **12**: 510–5.
- 72 Hardy JA, Higgins GA. Alzheimer's disease: the amyloid cascade hypothesis. *Science* 1992; **256**: 184–5.
- 73 Glymour MM, Brickman AM, Kivimaki M, *et al.* Will biomarker-based diagnosis of Alzheimer's disease maximize scientific progress? Evaluating proposed diagnostic criteria. *European Journal of Epidemiology* 2018; **33**: 607–12.
- 74 Garrett MD. A Critique of the 2018 National Institute on Aging's. Research Framework: Toward a biological definition of Alzheimer's disease. *Curr Neurobiol* 2018; **9**: 49–58.
- 75 Morris GP, Clark IA, Vissel B. Questions concerning the role of amyloid- β in the definition, aetiology and diagnosis of Alzheimer's disease. *Acta Neuropathologica* 2018; **136**: 663–89.
- 76 Chételat G. A β -independent processes—rethinking preclinical AD. *Nature Reviews Neurology* 2013; **9**: 123–4.
- 77 Pimplikar SW, Nixon RA, Robakis NK, Shen J, Tsai L-H. Amyloid-Independent Mechanisms in Alzheimer's Disease Pathogenesis. *Journal of Neuroscience* 2010; **30**: 14946–54.

- 78 Small SA, Duff K. Linking A β and Tau in Late-Onset Alzheimer's Disease: A Dual Pathway Hypothesis. *Neuron* 2008; **60**: 534–42.
- 79 Herrup K. The case for rejecting the amyloid cascade hypothesis. *Nat Neurosci* 2015; **18**: 794–9.
- 80 de la Torre J. The Vascular Hypothesis of Alzheimer's Disease: A Key to Preclinical Prediction of Dementia Using Neuroimaging. *J Alzheimers Dis* 2018; **63**: 35–52.
- 81 Grothe MJ, Barthel H, Sepulcre J, *et al.* In vivo staging of regional amyloid deposition. *Neurology* 2017; **89**: 2031–8.
- 82 Florek L, Tiepolt S, Schroeter ML, *et al.* Dual Time-Point [18F]Florbetaben PET Delivers Dual Biomarker Information in Mild Cognitive Impairment and Alzheimer's Disease. *J Alzheimers Dis* 2018; **66**: 1105–16.
- 83 Zimmer ER, Parent MJ, Souza DG, *et al.* [18F]FDG PET signal is driven by astroglial glutamate transport. *Nat Neurosci* 2017; **20**: 393–5.
- 84 Magistretti PJ, Pellerin L, Rothman DL, Shulman RG. Energy on demand. *Science* 1999; **283**: 496–7.
- 85 Ikonomic MD, Klunk WE, Abrahamson EE, *et al.* Post-mortem correlates of in vivo PiB-PET amyloid imaging in a typical case of Alzheimer's disease. *Brain* 2008; **131**: 1630–45.
- 86 Zetterberg H, Tullhög K, Hansson O, Minthon L, Londos E, Blennow K. Low incidence of post-lumbar puncture headache in 1,089 consecutive memory clinic patients. *Eur Neurol* 2010; **63**: 326–30.
- 87 Duits FH, Martinez-Lage P, Paquet C, *et al.* Performance and complications of lumbar puncture in memory clinics: Results of the multicenter lumbar puncture feasibility study. *Alzheimer's & Dementia* 2016; **12**: 154–163.
- 88 Mattsson N, Andreasson U, Persson S, *et al.* CSF biomarker variability in the Alzheimer's Association quality control program. *Alzheimer's & dementia : the journal of the Alzheimer's Association* 2013; **9**: 251–61.
- 89 Zetterberg H, Pedersen M, Lind K, *et al.* Intra-individual stability of CSF biomarkers for Alzheimer's disease over two years. *Journal of Alzheimer's disease : JAD* 2007; **12**: 255–60.
- 90 Jack CR, Knopman DS, Jagust WJ, *et al.* Tracking pathophysiological processes in Alzheimer's disease: an updated hypothetical model of dynamic biomarkers. *The Lancet Neurology* 2013; **12**: 207–16.
- 91 Blennow K, Zetterberg H, Minthon L, *et al.* Longitudinal stability of CSF biomarkers in Alzheimer's disease. *Neuroscience Letters* 2007; **419**: 18–22.
- 92 Sabri O, Sabbagh MN, Seibyl J, *et al.* Florbetaben PET imaging to detect amyloid beta plaques in Alzheimer's disease: Phase 3 study. *Alzheimer's & Dementia* 2015; **11**: 964–74.
- 93 Salloway S, Gamez JE, Singh U, *et al.* Performance of [18F]flutemetamol amyloid imaging against the neuritic plaque component of CERAD and the current (2012) NIA-AA recommendations for the neuropathologic diagnosis of Alzheimer's disease. *Alzheimer's & dementia (Amsterdam, Netherlands)* 2017; **9**: 25–34.
- 94 Shaw LM, Vanderstichele H, Knapik-Czajka M, *et al.* Cerebrospinal fluid biomarker signature in Alzheimer's disease neuroimaging initiative subjects. *Annals of Neurology* 2009; **65**: 403–13.

- 95 Tapiola T, Alafuzoff I, Herukka S-K, *et al.* Cerebrospinal fluid {beta}-amyloid 42 and tau proteins as biomarkers of Alzheimer-type pathologic changes in the brain. *Arch Neurol* 2009; **66**: 382–9.
- 96 Khalil M, Teunissen CE, Otto M, *et al.* Neurofilaments as biomarkers in neurological disorders. *Nat Rev Neurol* 2018; **14**: 577–89.
- 97 May PC, Dean RA, Lowe SL, *et al.* Robust central reduction of amyloid- β in humans with an orally available, non-peptidic β -secretase inhibitor. *The Journal of neuroscience : the official journal of the Society for Neuroscience* 2011; **31**: 16507–16.
- 98 Duits FH, Prins ND, Lemstra AW, *et al.* Diagnostic impact of CSF biomarkers for Alzheimer's disease in a tertiary memory clinic. *Alzheimer's & Dementia* 2015; **11**: 523–532.
- 99 Nath S, Badhiwala JH, Alhazzani W, *et al.* Atraumatic versus traumatic lumbar puncture needles: A systematic review and meta-analysis protocol. *BMJ Open* 2017; **7**: 1–6.
- 100 Alexopoulos P, Werle L, Roesler J, *et al.* Conflicting cerebrospinal fluid biomarkers and progression to dementia due to Alzheimer's disease. *Alzheimer's Research & Therapy* 2016; **8**: 51.
- 101 Rosén C, Farahmand B, Skillbäck T, *et al.* Benchmarking biomarker-based criteria for Alzheimer's disease: Data from the Swedish Dementia Registry, SveDem. *Alzheimer's & Dementia* 2015; **11**: 1470–9.
- 102 Leuzy A, Savitcheva I, Chiotis K, *et al.* Clinical impact of [18F]flutemetamol PET among memory clinic patients with an unclear diagnosis. *European Journal of Nuclear Medicine and Molecular Imaging* 2019; published online March 26. DOI:10.1007/s00259-019-04297-5.
- 103 Ceccaldi M, Jonveaux T, Verger A, *et al.* Added value of 18 F-florbetaben amyloid PET in the diagnostic workup of most complex patients with dementia in France: A naturalistic study. *Alzheimer's & Dementia* 2018; **14**: 293–305.
- 104 Ramusino MC, Garibotto V, Bacchin R, *et al.* Incremental value of amyloid-PET versus CSF in the diagnosis of Alzheimer's disease. *Eur J Nucl Med Mol Imaging* 2019; published online Aug. DOI:10.1007/s00259-019-04466-6.

Panels, Tables, and Figures

Panel 1. Search strategy and selection criteria

References for this Review were identified by searches of PubMed between November 1, 2018 and October 1, 2019 and from references to relevant articles. The search terms (alone or in combination) “Alzheimer’s disease”, “dementia”, “neurodegenerative diseases”, “MCI”, “imaging”, “biomarkers”, “PET”, “FDG”, “amyloid imaging”, “amyloid PET”, “PIB”, “flutemetamol”, “florbetapir”, “florbetaben”, “amyloid markers”, “magnetic resonance imaging (MRI)”, “CSF biomarkers”, “clinical validity”, “clinical utility”, “clinical acceptance”, “management change”, “diagnostic change” were used. Additional studies cited from the previously identified papers and known to the authors were also included. There were no language restrictions. The final reference list was generated on the basis of relevance to the topics covered in this Review.

Panel 2. Glossary

Dementia

Dementia is a syndrome characterized by a progressive alteration of cognitive functions beyond that expected for age and education and severe enough to affect daily functioning. According to the Diagnostic and Statistical Manual of Mental Disorders (DSM-5), dementia is categorised as a major neurocognitive disorder (major-NCD) and defined by a decline from a previous level of performance, and compared to appropriate norms, sufficient to interfere with independence, in at least one of the following cognitive functions: attention, planning, inhibition, learning, memory, language, visual perception, spatial skills, social skills or other cognitive functions. Cognitive impairment might be accompanied by deterioration in emotional control, social behaviour, or motivation.

Dementia is not a single disease; it is caused by a variety of brain diseases or injury, including by neurodegenerative diseases. The most frequent cause of dementia is Alzheimer’s disease, which may represent 60-70% of cases according to the World Health Organization (WHO), with other major forms including vascular dementia, dementia with Lewy bodies and frontotemporal dementia. Dementia could also be caused by non-neurodegenerative diseases such as stroke, cancer or chronic alcoholism.

Neurodegenerative diseases

Neurodegenerative disease is a generic term for all diseases characterized by a progressive loss of structure or function of neurons including neurodegenerative diseases leading to dementia, Parkinson's disease, motor neurone disease (or amyotrophic lateral sclerosis), cerebellar degenerations, Huntington's disease, fatal familial insomnia and prion diseases. Neurodegeneration causes cognitive deterioration which might progress to dementia. This paper focuses on neurodegenerative diseases leading to dementia. However, this is not the case for all neurodegenerative diseases. In Parkinson's disease for instance, motor symptoms might remain isolated or be accompanied by cognitive symptoms leading to dementia. The causes for neurodegenerative diseases are not fully understood but most likely include genetic and environmental factors. Neurodegenerative diseases are characterized by presence of neuropathologies - which reflect the alteration of specific proteins, and are most often used to define the disease and as the gold-standard for diagnosis. There is an overlap between diseases in the proteins involved. The tau protein for instance is involved in both Alzheimer's disease and some forms of fronto-temporal lobar diseases.

Mild Cognitive Impairment (MCI)

MCI, called as mild neurocognitive disorder (mild-NCD) in the DSM-5, refers to a stage of cognitive impairment that is beyond that expected for age and education but, in opposition to dementia, not severe enough to affect daily functioning. Criteria for MCI include self or informant-reported memory/cognitive complaint. Several subtypes have been defined based on the predominant cognitive domain that is affected. It has been demonstrated that MCI is associated with an increased risk of developing dementia, with the amnesic subtype showing high conversion to Alzheimer's type dementia.

Biomarkers

Biomarkers refer to biological measurements that could be obtained *in vivo* and allow to quantify biological and pathological conditions / processes or therapeutic effects. In the field of neurodegenerative diseases, several biomarkers are available from CSF or blood sampling, or from neuroimaging. In this paper we focus on neuroimaging and especially on PET biomarkers. The most widely used and validated PET biomarkers for Alzheimer's disease include Amyloid-PET and FDG-PET, while Tau-PET biomarkers are entering the field.

Diagnostic algorithm

A diagnostic algorithm is supposed to support the clinician in the decision on which diagnostic test to employ in which situation, depending on the clinical presentation of the patient, the probability of the underlying disease and the expected consequences of the diagnostic procedure. While several biomarkers are available for neurodegenerative diseases, uncertainty has arisen regarding appropriate combination and/or order of application of these biomarkers as there is no consensus or theoretical framework concerning how they should be combined. In this paper we aimed to propose a diagnostic algorithm suggesting the optimal timepoint for available PET-biomarkers, taking into account the other available established biomarkers, for early and differential diagnosis of neurodegenerative diseases that can lead to dementia. An interdisciplinary group of experts converge on a diagnostic algorithm indicating the recommended order of tests depending on the clinical presentation.

Panel 3. Case vignette

Mr. B is a 75-year-old man, who is presented to a neurologist by his wife because of progressive complaints of memory loss and occasional word finding difficulties. Despite his age, he still works as a tax-consultant and helps friends and family members with their finances. His "clients" notice that he has become slow in finishing the tax filings and recently some of them were returned because they were incomplete and full of mistakes. He was never very good with the computer, but lately his wife had to help him making wire transfers and writing emails. He has 2 children and 5 grandchildren, of which he sometimes mixes up the names. His wife reports that his gait has also become slower; he used to walk 3 meters ahead of her always during the weekly outings, but now he lags behind her.

His MMSE score is 27/30 and the MOCA is 20/30, of which the latter is lower than expected, and indicative of executive dysfunction more than memory dysfunction. Because of a history of mild hypertension since he was 40 years and mild diabetes since 7 years, both well controlled, the neurologist orders an MRI, that shows bilateral hippocampal atrophy grade 2 on the Scheltens scale and grade 3 White Matter Hyperintensities on the Fazekas scale, with 5 lacunar infarcts in the deep white matter and striatum, indicative of severe small vessel disease. The neurologist doubts whether all the cognitive complaints and findings can be attributed to the vascular damage and

wants to rule out Alzheimer's as co-pathology, also in view of the worse prognosis of the combination of both pathologies. She orders an amyloid PET scan which comes back negative, ruling out AD co-pathology. She makes a diagnosis of pure vascular cognitive impairment and intensifies his vascular care and offers life style advice. Mr B and his wife are relieved that AD is ruled out and subscribe to a fitness program at their local gym and put themselves on a Mediterranean diet.

Table 1. PET biomarkers for dementia.

	What it measures	In dementia	Used as
FDG-PET	Reflects regional glucose consumption directly linked to the local intensity of brain glutamatergic synaptic and astrocyte activity ^{83,84}	Allows to assess extent and location of hypometabolism as a reflect of neuronal dysfunction	Biomarker of brain neurodegeneration
Amyloid-PET	Reflects fibrillar β -amyloid deposits (plaques), one of the main neuropathological landmarks of AD ⁸⁵	Allows to assess the presence, extent and location of amyloid deposition in the brain	Biomarker of brain amyloid deposition

Table 2: Comparison of amyloid-PET and amyloid CSF assessments.

	PET imaging	CSF sampling
Costs	Relatively high	Relatively low
Contraindications	None	Treatment with anti-coagulants, spinal defects
Side effects	The common side effects (>1/100 and < 1/10) reported with fluorinated tracers are: injection site irritation and pain, flushing, increased blood pressure, and headache.	The common side effect of CSF sampling is post-lumbar puncture headache that occurs in 1 to 10% of the investigations in memory clinic settings; ^{86,87} more serious side effects of lumbar puncture, such as infection or brain herniation, might occur in the clinical setting, albeit extremely rarely.
Variability of the measure across centres and methods	Low ³⁷	Used to be considerable, ⁸⁸ but recently commercialised fully automated assays might solve the problem. ¹⁶
Individual variability of values in healthy subjects	Low ³⁷	Quite high but could be corrected for by measuring changes over time and/or employing the ratio-based approaches. ⁸⁹
Sensitivity to detect change over time / in the disease course	Yes, but low: possibly fast accumulation during the negative to positive transition, ⁹⁰ followed by protracted increase before reaching a plateau	No: Stable (studies show that CSF A β 42 changes 10-20 years prior to dementia and remains stable during the clinical phase of the disease). ^{89,91}
Sensitivity for amyloid pathology	91-98% ^{33,92,93}	80-96% ^{94,95}
Specificity for amyloid pathology	87-100% ^{33,92,93}	77-82% ^{94,95}
Information about N status	Possible with “early phase imaging” ⁸²	Available with total tau (but currently being questioned), might be with neurofilament levels but still need validation/confirmation/standardisation. ⁹⁶
Information about T status	None	Potentially available with phospho-tau levels
Information on extent of amyloid-pathology	Available; distribution of amyloid pathology might indicate the amyloidosis stage. ⁸¹	Not available
Information on location of amyloid-pathology	Available	Not available
Potential to measure anti-amyloid therapy effects	Conceivable	Conceivable with APP and A β peptides other than A β 42 (BACE inhibitors would influence A β 38 and -40 levels, as well as sAPP β in the CSF). ⁹⁷

Despite sometimes reflecting similar pathological processes, CSF and imaging biomarkers may possess complementary strengths and disadvantages. Certainly, the level of experience, establishment and standardisation as well as availability at a given centre will have to be considered with regard to the choice of the corresponding biomarker. Compared with amyloid-PET, CSF amyloid assessment is less expensive, and a conservative approach could be to use CSF sampling whenever possible. Then, amyloid-PET would only be necessary in a proportion of patients i) who refused the lumbar puncture (up to 10%);⁹⁸ ii) in whom CSF sampling is contraindicated (about 5%);⁹⁹ or iii) for whom CSF results are inconclusive due e.g. to technical problems or values close to threshold

(about 20%).^{100,101} This statement is confirmed by the experience in a context in which both amyloid-PET and CSF procedures are accessible and reimbursed, such as in Sweden.¹⁰² However, other than imaging, CSF analysis may not answer a number of questions such as location and extent of pathology. Recent studies also show that amyloid-PET has incremental diagnostic value when performed after CSF evaluation.^{103,104} It may be discussed that performing amyloid-PET in the first line may spare patients multiple visits and unnecessary invasive interventions and that this may contribute to a more direct, more comprehensive and standardised workup, particularly in diagnostic reference centres such as memory clinics. Furthermore, disease follow-up and treatment specific therapy monitoring may only be possible by means of suitable neuroimaging biomarkers, as e.g. CSF markers would not provide conclusive information on change in extent of pathology or neurodegeneration over time. Finally, the topographic/regional information provided by PET offer valuable information about the earliest pathological stages of amyloid accumulation.⁸¹

Figure 1. Examples of images obtained with structural MRI or PET using different radiotracers listed in order of the level of current clinical establishment versus primarily research-oriented application (from left to right).

Top row shows healthy controls, while bottom row shows individuals with a clinical syndrome of late-onset Alzheimer’s dementia. First column illustrates structural MRI-based z-score deviations of grey-matter volume in patients compared to controls displayed in blue on the right hemisphere of a template image. Second column shows [18F]FDG-PET glucose metabolism displayed as a 3D-surface projection of the right hemisphere with normal metabolism shown in yellow/red and reduced metabolism in green/blue. Third column shows amyloid-PET with [11C]PiB, displayed as a 3D-surface projection of the right hemisphere, with high amyloid burden indicated in yellow/red and no/low amyloid deposition in green/blue. Fourth column shows tau-PET with [18F]AV-1451, displayed as a 3D-surface projection of the right hemisphere, with high tau-tracer retention shown in yellow/red and no/low tau-tracer retention in green/blue (columns 1-4: images courtesy of University of Cologne, Germany). Fifth column shows TSPO-PET with [11C]PK11195, displayed as axial slices (caudal aspect, frontal to the top) with yellow/red showing elevated TSPO expression reflecting neuroinflammation (images courtesy of Prof. David Brooks, Aarhus University, Denmark). Sixth column shows SV2A-PET of synaptic density with [11C]UCB-J displayed as axial slices (caudal aspect, frontal to the top) with yellow/red showing normal synaptic density and green reflecting reduced synaptic density (images courtesy of Prof. Ming-Kai Chen, Yale School of Medicine, USA).

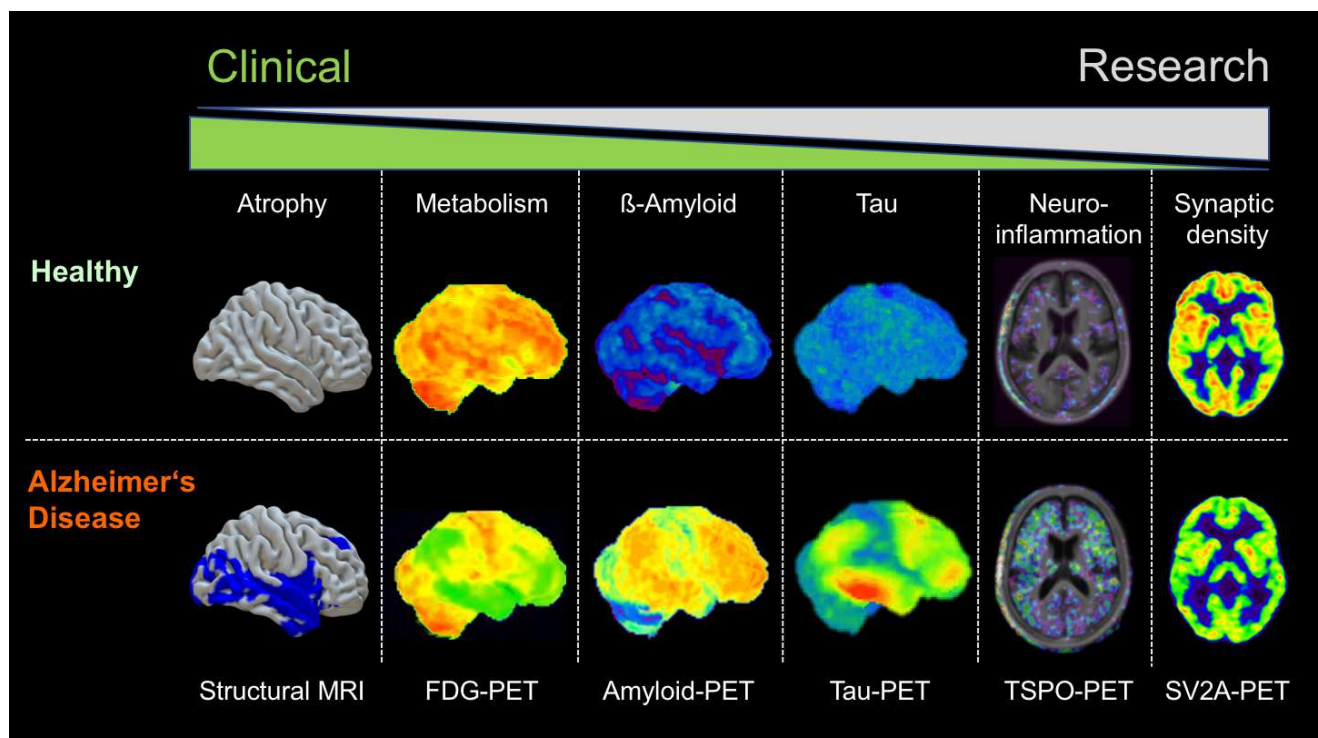
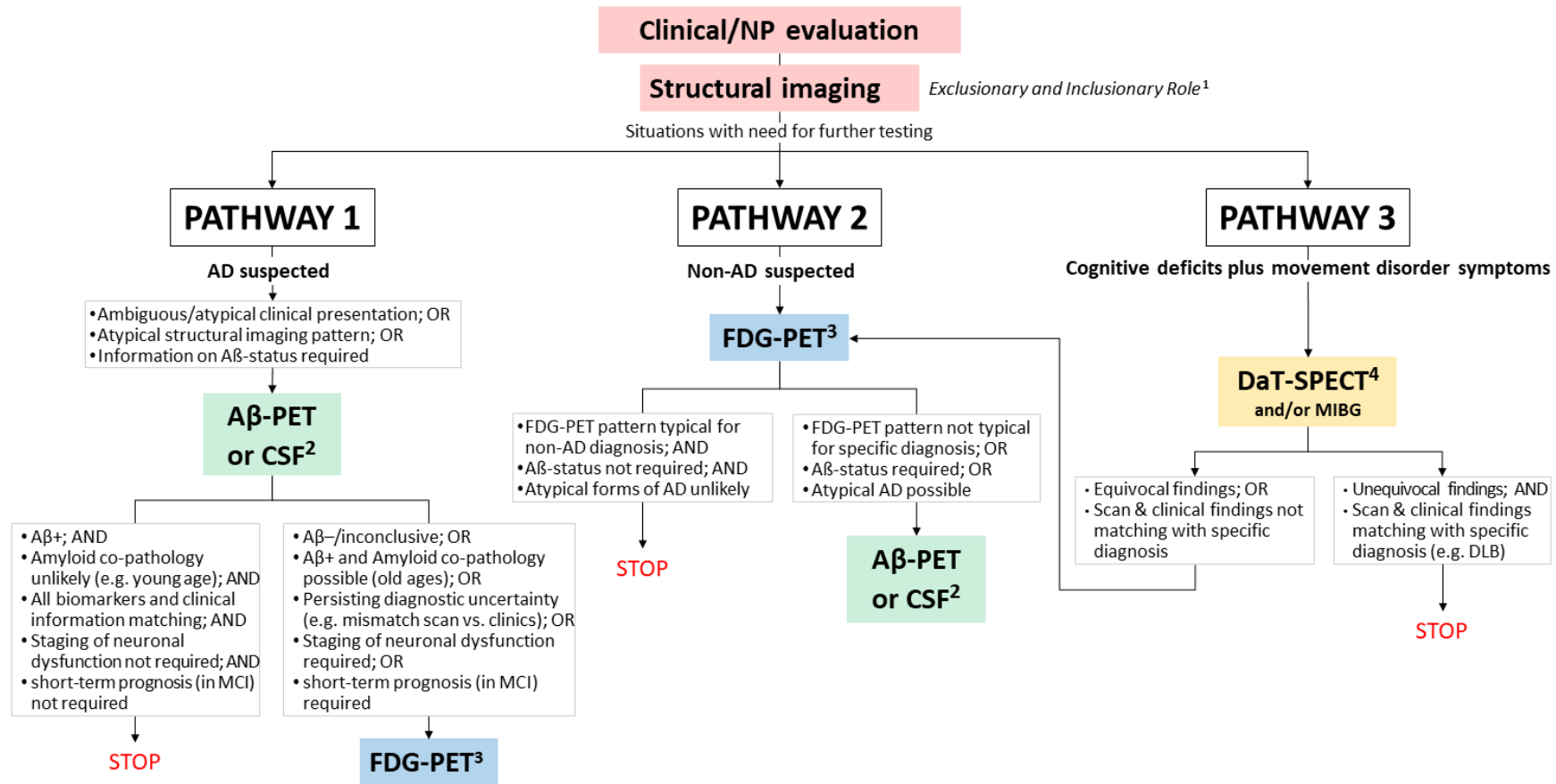


Figure 2. Proposal for a diagnostic algorithm for early and differential diagnoses of dementia.

The diagnostic work-up should start with a clinical/neuropsychological evaluation, followed by structural imaging when needed to establish reliable etiological diagnosis. Further workup could be halted, if clinical and structural imaging information both converge towards a specific diagnosis, e.g., in patients with memory predominant profile with typical hippocampal atrophy, possibly with positive family history and/or $\epsilon 4$ -positive *APOE* genotype when available, and/or if consequences of the diagnosis are limited (e.g. other comorbidities dominating patient prognosis). However, if tailored therapy concepts are the aim and/or decisions depend on a conclusive diagnosis and prognosis, additional biomarker assessment is required (referred to in the figure as: “situations with need for further testing”; see also supplementary materials for further details). In **pathway 1**, preferred if the main suspicion is AD, analysis of amyloid pathology would be the subsequent next step. Depending on the result, FDG-PET may be additionally required to obtain further prognostic/diagnostic information, e.g. on the extent of neurodegeneration or on a specific pattern of hypometabolism or with regard to short-term prognosis in MCI. **Pathway 2** is recommended if AD is not the single most probable/suspected diagnosis or for older (>75-80 years) individuals. If the result of the FDG-PET scan is conclusive, no further test might be requested (examples 1); in contrast, if the pattern of FDG-PET hypometabolism is not conclusive, or if the reliable clarification of neuropathology is clinically relevant, a further amyloid test might be necessary (examples 2). Finally, in **Pathway 3**, we would recommend a DaT-SPECT (or mIBG imaging) as the primary test for all situations in which a movement disorder/parkinsonian syndrome is clinically in question; in some cases (abnormal DaT-SPECT), no further test is required (example 3), but if further specification is needed (i.e. if the DaT-SPECT is normal, or, if it is abnormal, to differentiate between all neurodegenerative PS), then an additional FDG-PET is recommended, followed by amyloid-PET if AD remains a possibility. More details and examples are given in Supplementary materials. This algorithm is a theoretical proposal and further validation of the order of tests is needed (see text for details).



¹ Exclusion of neoplastic, vascular, and inflammatory changes supporting non-neurodegenerative aetiologies and evaluation of topography of atrophy might inform on the neurodegenerative disease (but FDG-PET might be more sensitive and accurate).

² Whatever is established/available and preferred; always Aβ-PET if CSF is contraindicated or inconclusive. See Table 1 for further details.

³ Age and *APOE* status (when available) may influence the use of FDG-PET even before amyloid-PET especially in individuals with available but inconclusive CSF results. Analyses of FDG-PET images should also take into account comorbidities, i.e. uncontrollable diabetes, brain trauma, chronic ischemia, as well as some medications (e.g. psychotropic drugs or corticosteroids) that might affect the images, since these can alter cerebral metabolism.

⁴ FDG-PET can be performed before DaT-SPECT or mIBG, particularly if the cortical involvement of neurodegeneration is in the diagnostic focus.

Panel 4. Take-home messages

- PET neuroimaging biomarkers have an important role in the diagnosis workup of neurodegenerative diseases leading to dementia.
- Amyloid PET is most useful to prove or rule out AD and provide specific information on the underlying pathology.
- FDG-PET has great value for differential diagnosis of neurodegenerative diseases, prediction of short-term outcome, and staging of neurodegenerative processes.
- Depending on the clinical presentation, specific combinations of biomarkers are of significant added value for early and differential diagnosis.