



HAL
open science

Significance of Hemodynamics Biomarkers, Tissue Biomechanics and Numerical Simulations in the Pathogenesis of Ascending Thoracic Aortic Aneurysms

Salvatore Campisi, Raja Jayendiran, Francesca Condemi, Magalie Viallon, Pierre Croisille, Stéphane Avril

► **To cite this version:**

Salvatore Campisi, Raja Jayendiran, Francesca Condemi, Magalie Viallon, Pierre Croisille, et al.. Significance of Hemodynamics Biomarkers, Tissue Biomechanics and Numerical Simulations in the Pathogenesis of Ascending Thoracic Aortic Aneurysms. *Current Pharmaceutical Design*, In press, 10.2174/1381612826999201214231648 . hal-03139798

HAL Id: hal-03139798

<https://hal.science/hal-03139798v1>

Submitted on 12 Feb 2021

HAL is a multi-disciplinary open access archive for the deposit and dissemination of scientific research documents, whether they are published or not. The documents may come from teaching and research institutions in France or abroad, or from public or private research centers.

L'archive ouverte pluridisciplinaire **HAL**, est destinée au dépôt et à la diffusion de documents scientifiques de niveau recherche, publiés ou non, émanant des établissements d'enseignement et de recherche français ou étrangers, des laboratoires publics ou privés.

Title Page

Journal: CURRENT PHARMACEUTICAL DESIGN

Article type: Minireview article

Title

Significance of Hemodynamics Biomarkers, Tissue Biomechanics and Numerical Simulations in the Pathogenesis of Ascending Thoracic Aortic Aneurysms

Running Title

Hemodynamics and biomechanics in the pathogenesis of aortic diseases.

Authors

Salvatore Campisi¹

¹ *Department of Cardiovascular Surgery; University Hospital of Saint Etienne, France.*

Raja Jayendiran ²

² *Mines Saint-Etienne, Univ Lyon, Univ Jean Monnet, INSERM, U 1059 Sainbiose, Centre CIS, F - 42023 Saint-Etienne France.*

Francesca Condemi²

² *Mines Saint-Etienne, Univ Lyon, Univ Jean Monnet, INSERM, U 1059 Sainbiose, Centre CIS, F - 42023 Saint-Etienne France.*

Magalie Viallon³

³ *Department of Radiology, University Hospital of Saint Etienne.*

Pierre Croisille³

³ *Department of Radiology, University Hospital of Saint Etienne.*

Avril Stephane²

² *Mines Saint-Etienne, Univ Lyon, Univ Jean Monnet, INSERM, U 1059 Sainbiose, Centre CIS, F - 42023 Saint-Etienne France.*

Corresponding Author:

Stéphane Avril

Mines Saint-Etienne, Univ Lyon, Univ Jean Monnet, INSERM, U 1059 Sainbiose, Centre CIS, F - 42023 Saint-Etienne France.

Phone: 00 33 04 77 42 01 88

Email address: avril@emse.fr

Significance of Hemodynamics Biomarkers, Tissue Biomechanics and Numerical Simulations for the Pathogenesis of Ascending Thoracic Aortic Aneurysms

Abstract

Guidelines for the treatment of aortic wall diseases are based on measurements of maximum aortic diameter. However aortic rupture or dissections do occur for small aortic diameters. Growing scientific evidence underlines the importance of biomechanics and hemodynamics in aortic disease development and progression. Wall shear stress (WSS) is an important hemodynamics marker which depends on aortic wall morphology and on the aortic valve function. WSS could be helpful to interpret aortic wall remodeling and define personalized risk criteria. The complementarity of Computational Fluid Dynamics and 4D Magnetic Resonance Imaging as tools for WSS assessment is a promising reality. The potentiality of these innovative technologies will provide maps or atlases of hemodynamics biomarkers to predict aortic tissue dysfunction. Ongoing efforts should focus on the correlation between these non-invasive imaging biomarkers and clinico-pathologic situations for the implementation of personalized medicine in current clinical practice.

Keywords

Magnetic Resonance Imaging, Computational Fluid Dynamics, Ascending thoracic aorta aneurysms, vascular remodeling, wall shear stress, aortic dissection.

1. Introduction

Ascending thoracic aorta aneurysms (ATAAs) can lead to catastrophic complications as aortic dissection and rupture. An aneurysm is defined as a localized dilatation of the aorta that is more than 50% of predicted (ratio of observed-to-expected diameter ≥ 1.5). Aneurysm should be distinguished from ectasia, which represents a diffuse dilation of the aorta less than 50% of normal aortic diameter. Aneurysms generally occur progressively, over a span of years. Surgical management of ATAAs relies on the risk-to-benefit trade-off considering the risk of rupture and the risk related to the surgical procedure. For many years, the main decision-making criteria for surgical intervention have been the maximum aortic diameter, growth rate and risk factors for aortic dissection

(family history of acute aortic syndrome, uncontrolled hypertension, presence of connective tissue disorders)^[1]. Data from several studies and registries for aortic dissection showed that the aorta can dissect at diameter values inferior to these recommendations^[2]. Thus, the current criteria do not fully satisfy the need to predict life-threatening aortic events and other specific patient-related factors could be taken into account by clinicians for better interventional planning^[3].

The challenge for cardiac surgeons and cardiologists in the future will be deciphering which patient with a dilated aorta is likely to dissect or rupture imminently. In clinical practice it is not rare to find two patients with the same ascending thoracic aorta maximum diameter but with two very different risk of rupture: which aorta is at risk of impending rupture?

For the past 20 years, Computational Fluid Dynamics (CFD) and 4D Flow Magnetic Resonance Imaging (MRI) have been increasingly commonplace to assess hemodynamics parameters as wall shear stress (WSS), relative residence time (RRT), oscillatory index (OSI), flow helicity and other criteria that have to be related to para-physiological or pathological conditions of the aortic wall^[4-7]. Nowadays, CFD and 4D MRI with their different strengths and weaknesses are complementary tools to investigate hemodynamics and biomechanics in aortic diseases^[8-9].

There is growing evidence that hemodynamics determine growth and remodeling in the aortic wall. However, it remains obscure how altered hemodynamics descriptors could indicate a potential future risk for a mildly pathological aorta.

In this review we survey the factors that can influence the development and progression of aortic disease and focus on future promising directions for the clinical translation of recent research in this field.

2. Vascular biology of aortic diseases: genetic, pharmacological and hemodynamic aspects.

From a morphological point of view, aneurysms are defined as localized portions where the aortic wall lost its geometrical parallelism and potentially its ability to withstand the wall tension generated by high intraluminal pressure. Dissections are acute events that could occur, with or without a subjacent aneurysm, when the intramural integrity of the aortic wall has been lost, leading to an intimal tear and blood leaks or flows within the external part of the media^[10-11]. When the

ascending thoracic aorta (ATA) is involved, the dissection is defined as “type A”, conversely, when the initial lesion is localized just below the ostium of the left subclavian artery, the dissection is called “type B”^[12-13].

As the aorta undergoes a continuous pressurization, the structure of its wall structure is optimized to sustain tensile stresses. It is organized in three layers, respectively from inside to outside, the intima, the media and the adventitia^[14]. The mechanical function of the media is mediated by the interaction between smooth muscle cells (SMCs) and the extracellular matrix (ECM)^[15]. SMCs produce a tone in response to sympathetic stimuli. They can also synthesize fibers, matrix metalloproteases (MMPs) or glycoproteoglycans (GAGs) to remodel the ECM. In the ECM, collagen fibers provide the resistance to rupture, whereas elastin provides elastic properties required to sustain aortic cyclic distensions^[16]. Dysfunctional interactions between these different factors can significantly hamper the capacity of responding to mechanical stimuli^[17].

Since the discovery in 1991 that aortic dilatation in Marfan’s syndrome is caused by mutations in the FBN1 gene, the importance of genetics in ATAA predisposition has been underlined^[18]. About 140 mutations have been associated with syndromic and non-syndromic ATAAs^[19]. The main groups of genes involved in ECM or SMCs dysfunction are: genes encoding proteins in microfibrils (FBN1, MFAP5, LOX); genes encoding structural components essential to SMCs contractility (ACTA2, MYH11, MYLK, PRKG1); genes encoding proteins in the canonical TGF- β signaling pathway (TGF- β 2, TGF- β 3, TGF β R1, TGF β R2)^[20-21].

Normally, the ECM undergoes continuous modifications to adapt to different stimuli with the objective of maintaining a constant biochemomechanical balance. Therefore, dysfunctional homeostasis results in a compromised ability of intramural cells to sense their mechanical environment and to regulate the ECM to respond appropriately to environmental stimuli in a continuous dynamic process^[22-23].

Despite different etiologies, aneurysms and dissections present common histopathological features, including disruption and loss of elastic fibers, changes in cell amount or phenotype, and infiltration of inflammatory cells in the aortic wall^[10-11]. The transmural pressure gradient between the intramural arterial blood pressure and the adventitial interstitial pressure is responsible for an important phenomenon called “outward convection”^[15-17]. This phenomenon creates a unidirectional outward conductance across the aortic wall with a

convective transport of soluble plasma micro and macromolecules and could be affected by hemodynamic factors and permeability of the aortic wall. Accordingly, any change in pressure and shear can subsequently induce degenerative processes after percolation with blood-borne particles, namely loss of elastic fiber integrity, decrease of SMC tone and increase in GAGs concentration^[22].

The outward convection phenomenon links hemodynamics ECM regulation and altered SMC mechano-sensing, leading to ATAA expansion^[20].

The role of the TGF- β signaling pathway was characterized with mouse models of the Marfan's syndrome where abnormal stimulation of the TGF- β pathway could be obtained via the angiotensin II type I receptors^[23-24]. A series of experimental studies have demonstrated that the ECM production is reduced in response to administration of angiotensin-converting enzyme inhibitor, an angiotensin II type I receptor antagonist, or a TGF- β neutralizing antibody^[25-26]. These evidences led to a large clinical trial comparing losartan therapy, an inhibitor of angiotensin II type I receptors, and β -blockers in patients with Marfan syndrome^[27]. Beyond the results, not always concordant, this showed the major interaction between mechanics and biochemical in aneurysm progression.

Inflammation is another frequent condition in ATAAs. Cyclic loading of SMCs, after angiotensin II administration, can promote recruitment of monocytes/macrophages that can contribute to matrix turnover and adventitial fibrosis via interleukin secretion^[28].

Mechanosensing and mechanoregulation are closely dependent also from integrins, a transmembrane complex that mediate the interaction between SMCs, adventitial fibroblasts/myofibroblasts cells and ECM through activation of signal transduction pathways^[29]. Integrins are essential for tensional homeostasis and proper mechanosensing of ECM^[30].

ECM production and degradation after SMCs response to mechanical stimuli is mediated by MMP^[31-32-33]. The activity of MMPs is normally under control of specific endogenous tissue inhibitors (TIMP): an MMP/TIMP imbalance has been evidenced in patient with aortic aneurysms^[34-35]. An overexpression of MMPs, especially MMP2 and MMP9, can be related to inflammatory conditions, via the interleukins pathways^[36-37-38]. Several inflammatory biomarkers have been proposed to assess the risk of aortic rupture or dissection^[39-40-41-42]. Oxidative

stress and antioxidant agents have been investigated in animal models of aortic dissection^[43-44].

In this complex scenario we can consider the pivotal role of SMCs as the common thread of the aortic wall vascular biology. The capability to switch from contractile to proliferative, synthetic and inflammatory phenotype (SMCs plasticity) and regulate the balance between ECM production and degradation is involved in all the aspects of aortic wall pathology. Likewise, increasing in aortic wall stiffness accompanying ageing and hypertensive disease is related to changes in SMCs phenotype. Thus, hemodynamics can influence the status of aortic wall and consequently, its adaptive mechanical response. Intraluminal pressure and tensile stresses are able to modify, via the outward convection phenomenon, the status of the aortic wall leading to aortic wall remodeling (see *Fig. 1*).

In summary, although genetic models have evidenced dysfunctional mechanosensing, due to flawed SMCs or ECM, as a sufficient condition for ATAA development, the pathogenesis of idiopathic ATAAs is still a topic of intense research. A major question is how mechanobiological dysfunctions interact with hemodynamics, the latter being an important marker of ATAA propensity.

3. Aortic hemodynamics and in-vivo evaluation.

Two major approaches can be used to assess flow and velocity profiles in the aorta: CFD and 4D MRI^[45].

CFD is a branch of fluid mechanics that solves equilibrium equations satisfied by fluids flowing in a given domain and subjected to certain boundary conditions. CFD has been applied to abdominal aneurysms^[46-47], to the design of vascular devices^[48], to surgical planning^[49] and to predict surgical outcomes^[50-51]. The technology relies on meshing the volume occupied by the fluid. The necessary requirement is therefore an accurate three-dimensional geometric reconstruction of the aorta. Detailed anatomical imaging can be obtained by cardiovascular magnetic resonance (CMR)^[52] or multislice computed tomography (CT)^[53]. Both techniques can be carried out with electrocardiogram-gating in order to reduce motion artefacts. CMR provide anatomical data through two main methodologies: MR angiography and high-resolution cardiac and respiratory steady state in free precession (SSFP)^[52]. The first technique

requires the use of an intravenous contrast injection which is usually less nephrotoxic than that used in CT angiography.

Therefore, both MR techniques and standard ECG-gated CT-scan can provide basic anatomic images that are needed for segmentation process. During this procedure, the vessel boundaries are segmented either automatically selection or by manual interaction^[54]. The result is a detailed geometric 3D model of the aorta and its branches that can be further elaborated by mesh algorithms to create a framework of data points at which hemodynamic parameters, such as velocity and pressure, can be calculated.

For carrying out accurate CFD simulations of blood flow a key aspect is the specification of boundary conditions at the inlet of the aorta (i.e. the aortic root) and at the outlet of each branch in the aortic arch and descending thoracic aorta^[55]. So far, many studies have used idealized velocity profiles derived from mathematical models of flow as boundary conditions for CFD simulations^[56-57] but these ideal mathematical models are actually different of physiological situations where the aortic valve morphology and function might alter the flow patterns in the ATA.

Through phase-contrast techniques (PC MRI), CMR allows patient specific blood flow and velocity measurements at a given plane along the aorta so that the velocity profiles calculated at the level of the aortic valve or above can be used as boundary conditions for CFD simulations^[45]. Therefore, coupling MRI and CFD is the best approach to study flow characteristics and biomechanical forces and reproduce as closely as possible the physiological conditions in the aorta^[50]. 4D MRI is the acquisition of 3D phase-contrast MRI in a time resolved ECG-gated manner with three-directional velocity encoding and enables the quantification of flow and volume at any location along all dimensions. Hemodynamics measurements related to flow and velocities can be calculated by MRI and CFD. Therefore both techniques represent new tools for in vivo assessment of aortic hemodynamics with different strengths and weaknesses. The 4D MRI spatial resolution is lower than CFD and the acquisition requires long scan times for the patient^[45-46-47]. Conversely, CFD can be refined temporally and spatially and is able to describe spatial variations not only of velocity but also of pressure indices. CFD including fluid structure interactions (FSI) can provide information on how a deformable structure like the aortic wall responds to flow changes^[58]. FSI can be steady or oscillatory. Accordingly it is possible to describe the behavior of the aorta in response to hemodynamics load throughout the cardiac cycle^[59].

Recently, the role of hemodynamics has emerged as determinant in influencing the remodeling of the vascular system. Changes in endothelial or SMC homeostasis and ECM remodeling, after hemodynamics stimuli, have clinical effects in terms of development and maintenance of pathophysiological processes underlying vascular diseases.

WSS is one of the most cited hemodynamics factors involved in vasculopathy^[60]. Shear stress is the component of stress coplanar with a cross section. It arises from the force vector component parallel to the cross section of the vessel whereas the normal stress is the result of application of the force vector component perpendicular to the cross section. So the WSS is defined as the tangential force per unit area exerted by a moving fluid against the wall of a vessel. Any real fluid moving along a solid boundary will produce a shear stress at that boundary; the speed of the fluid at the boundary is zero (no-slip condition) while at some distance from the boundary the velocity is different. WSS is therefore given by the viscosity and the wall shear strain rate. In Newtonian models the viscosity is constant and the shear stress is proportional to the strain rate in the fluid, unlike non-Newtonian fluids^[61]. A number of markers derived from shear stresses have been under investigation to assess their influence on biochemical processes responsible for vascular diseases such as atherosclerosis and aneurysms. Time averaged wall shear stress (TAWSS), oscillatory shear index (OSI), transverse wall shear stress (transWSS), spatial WSS gradient (WSSG) and temporal WSS gradient are examples of shear stress parameters that have been investigated^[45]. TAWSS is calculated by integrating each nodal WSS magnitude over the cardiac cycle; OSI is a dimensionless metric which characterizes whether the WSS vector is aligned with the TAWSS vector throughout the cardiac cycle. The transverse wall shear stress (transWSS) quantifies deviations in the direction of WSS vector throughout the cardiac cycle. The spatial WSS gradient (WSSG) is calculated from the WSS gradient tensor components parallel and perpendicular to the time-averaged WSS vector. The temporal WSS gradient (TWSSG) is simply quantified as the rate of change in WSS magnitude over the cardiac cycle^[62]. Another essential hemodynamics parameter is the relative residence time (RRT) defined as a measure of how much time the material flowing through a volume spends in that volume^[63]. This parameter is applicable to a wide variety of disciplines including fluids in a chemical reservoir, water in a catchment, bacteria in a culture reactor and drugs in the human body. It can be specific for each particle or molecule of a fluid. For more complex systems, a better descriptor is the residence time distribution

(RTD) which depends on time constants such as turn-over time or flushing time, mean age time and mean transit time. Novel understanding in vessel wall remodeling may consider the interaction between the blood and the vessel wall and how RRT and circulating blood particles can interact and infiltrate in the aortic wall in presence of deranged wall barrier action^[64-65]. Our group recently investigated the correlation between RRT distribution and tissue remodeling in aneurysms. Elevated RRT distribution was found to be a useful parameter for quantifying hemodynamics alterations, usually associated with low local velocities and low WSS^[66].

4. Translational research.

4.1 Hemodynamics and vascular remodeling

The aortic wall is a complex organ consisting of endothelial, smooth-muscle and fibroblast cells interacting reciprocally in a sophisticated, active and integrated manner^[67-68-69-70]. Through regulation processes, it is able to adapt to different stimuli and remodel its structure and function through the production and local secretion of many signaling mediators^[71-72].

The ECM can be remodeled depending on WSS variations and the latter can trigger aortic disease. The relationship between WSS and vascular pathologies was first evidenced in atherosclerotic plaques^[73-74-75]. Subsequently, Malet et al.^[76] described how different WSS values can determine various gene expressions influencing atherogenic or atheroprotective phenotypes of endothelial cells in the aortic wall. Although these pioneering studies related low rather than high values of WSS to atherosclerosis, further studies underlined the role of high WSS in media degeneration. The contribution by Della Corte et al.^[77-78] helped to decipher signaling pathways leading to aneurysm formation through degradation of type I and III collagen fibers and SMCs apoptosis, and related these mechanisms to high WSS. A recent study by Guzzardi et al.^[79] demonstrated how increased concentrations of TGF β 1 and MMP-1, MMP-2 and MMP-3 are prone to occur in regions of high WSS. According to their observations medial elastic fibers degeneration was higher in areas of elevated WSS, the latter being amplified for bicuspid aortic valve (BAV).

4.2 Hemodynamics and aortic valve morphology and function

As mentioned above, WSS is a stimulus for vascular remodeling. It is well established that the morphology of the ATA, the aortic valve phenotype and its function can affect hemodynamics and WSS distribution, and incidentally provoke aortic dilatation. The impact of each of these factors has been investigated by several authors.

Concerning aortic valve phenotype many studies focused on BAV-mediated aortopathy^[80-81] and two main theories exist, genetics and hemodynamics. The first one ascribes to genetic mechanisms the weakness and propensity to dilatation of BAV patients. The basis of this theory relies on the fact that BAV is a heritable trait, with approximately 9% of prevalence among first-degree relatives and is not only a disorder of valvular development but also represents a complex coexistent genetic disease of the aorta and cardiac development^[82-83]. Aortic dilatation in BAV patients is reported in up to 50-60% of affected individuals and may occur independently of the underlying valvular morphology and function. Moreover, significant heterogeneity has been described as the phenotype expression of associated aortopathy can vary from asymmetric ATA dilatation to different degrees of aortic arch or aortic root enlargement^[84-85-86].

On the other hand though, no common or univocal genetics pattern has been reported explaining BAV aortopathy; furthermore, the evidence of altered flow patterns in ATA of BAV patients shown by CFD and 4D MRI studies^[87-88-89-90], even in normally functioning BAV, suggests that hemodynamics factors, as turbulent or eccentric flow from a narrowed orifice, can play an important role on vascular remodeling and aortic dilatation in BAV patients. Mahadevia et al.^[91] demonstrated how the presence and pattern of cusp fusion are related to different phenotypes of BAV aortopathy, evoking the crucial role of hemodynamics factors such as WSS distribution and systolic flow eccentricity.

A recent study has investigated the role of hemodynamics in the development of BAV-related aortopathy^[92-93]. In their study^[93] the authors have enrolled five young patients with BAV and absolutely normal aortic diameters and valve function and ten age-matched healthy volunteers; the patients were followed for three years with 4D MRI. The authors found evidences of WSS alterations in absence of clinically-relevant aortic remodeling. The results suggest two mutually exclusive interpretations: the first one is no cause-effect relationship between altered fluid dynamic stimuli and onset of aortopathy, the second one is that vascular remodeling is linked to altered fluid dynamics in a slow process which can take several years to reach clinical relevance. The latter statement is

in agreement with previous studies. The authors concluded that WSS alterations precede by far the onset of BAV-related aortopathy and the short-term effect is probably detectable only at the cell or molecular level.

Several papers have investigated the interplay between ATA geometry, aortic valve morphology and function and aortic hemodynamics^[94-95]. In case of ATAA with normally functioning BAV, it is largely debated if the effect of aortic geometry is more important than aortic valve opening-and-closing mechanism in determining hemodynamic alterations. We recently reported the case of a patient with normally functioning BAV (R-L type I) who underwent surgical repair for ATAA without aortic valve replacement, demonstrating that the restoration of parallel aortic geometry lead to improved flow patterns^[96]. In their study Youssefi et al.^[97] compared five groups of patients, divided into volunteers, aortic regurgitation-tricuspid aortic valve (AR-TAV), aortic stenosis-tricuspid aortic valve (AS-TAV), aortic stenosis BAV with right-left cusp fusion (AS R-L BAV) and aortic stenosis-right-non coronary cusp fusion (AS R-NC BAV). The results showed that BAV displays eccentric flow with high helicity and the presence of AS, particularly in R-NC BAV, led to higher WSS and lower OSI in the greater curvature of the ATA.

Addressing the role of valve function we found that the degree of aortic insufficiency affects the degradation of biomechanical properties in the aortic wall, independently of typical jet flow impingement^[98]. BAV seems to be associated with deranged flow patterns^[8] but other factors have to be taken into account, each contributing with a different weight^[90,99] and probably resulting in altered ECM homeostasis as well. Moreover, the role of aortic wall stiffness should not be neglected, as shown in our previous study^[100].

In conclusion, aortic valve function and morphology, ATA geometry and stiffness are all important determinants of ATA wall frailty for diagnosis and prognostics of clinical risks and outcomes^[101].

4.3 Hemodynamics and aging

The aortic structure is different in proximal and distal portions in order to ensure both cushion buffering and resistive conduit functions^[102]. Actually, the proximal aorta receives and dampens the pulsatile pressure of the blood expelled from the left ventricle and transmits the blood volume to peripheral arteries, while the distal aorta ensures a continuous peripheral perfusion, behaving as a normal

duct conveying fluids. High compliance and distensibility allow the proximal aorta to store about 60% of the heart stroke volume during systole and push it forward, via its elastic recoil, to coronary and distal circulation during diastole^[103]. The ATA has a higher elastin-to-collagen ratio when compared to the abdominal aorta.

Aging is related to higher cardiovascular risk^[104] due to progressive alterations in the structure and in the function of the cardiovascular system. Owing to the wearing effect of distension cycles leading to fatigue, the proximal aorta degenerates with aging. It has been estimated that, over an average lifetime, the ATA is subject to cyclic pulsatile stresses at each left ventricle ejection. As a result of this, elastin undergoes fatigue, and the aorta thickens and lengthens, leading to a stiffer para-physiological condition (arteriosclerosis). The histological modification of the aorta with aging implies progressive fragmentation of elastin fibers, rearrangement of remnant fibers and fibrosis^[105], leading to altered mechanical properties of the aortic wall^[106].

With aging the aorta is less efficient in fulfilling its mechanical function. Moreover, the stiffened aorta is exposed to stronger backward pulse waves, as the pressure wave propagation is faster and stronger^[107-108] (loss of distensibility) and thus, the reflection of this pulse pressure wave is faster and occurs earlier in the cardiac cycle with increase of left ventricle afterload^[109]. Because of that, left ventricle hypertrophy, lower diastolic blood pressure, with consequent reduced coronary perfusion, and myocardial ischemia are typically pathological age-related conditions of the cardiovascular system^[110] and correlates to higher cardiovascular risk^[111]. Other consequences may be progressive dysfunctions of brain and kidney^[112].

Therefore, in summary, aging results in several changes occurring at tissue, cellular and molecular levels, such as diminished SMCs functionality, loss of elastic fiber integrity, remodeled collagen, increased concentrations of GAGs. All these effects are common to ATAAs, suggesting that ATAA development could be assumed to express a localized and accelerated aortic aging. New technologies, as 4D MRI, allow in vivo assessment of hemodynamics changes and contribute to evaluate the biomechanical behavior of the aorta with aging. Aging implies a “reverse remodeling” of the aorta, which thickens, lengthens and unfolds becoming less effective in assuming its biomechanical role^[113]. This can account for the increase in aortic diameter with age and geometrical changes as elongation and enlargement that correlates with increased cardiovascular risk.

4D MRI studies have evidenced decreased distensibility, larger aortic pulse wave velocity and increased backward flow in the ATA. Therefore, deranged flows and subsequent dilatation and elongation, resulting in progressive aortic unfolding, determine a vicious circle that lead to local blood vortices, contributing to activate and maintain biochemomechanical pathways of aortic wall remodeling, just like in connective tissue disorders^[114-115].

5. Future directions

Considering the impact of valve function, aortic valve phenotype and aneurysm geometry on deranged hemodynamics a follow-up study combining 4D-MRI and CFD should be conducted on patients with ATAA, which do not meet the diameter criterion for surgical treatment. The heterogeneous population study consisting of patients with different valve morphologies and functions and different degrees of ATA would allow defining how each factor interacts in establishing deranged hemodynamics conditions. It is still debated, for example, if functionally normal BAV in presence of regular ATA is responsible for flow helicity and vortex effects. Our recent study has demonstrated that even in the presence of mildly pathologic BAV the restoration of a normal parallel ATA geometry improves significantly the hemodynamics. This is a translational topic as, actually, there are no clear recommendations both on the management of mild aortic dilatation in case of aortic valve replacement for diseased BAV and on the management of a “functionally healthy” BAV in case of ATAA replacement. These two situations represent, in absence of strong guidelines, a real dilemma for surgeons.

Another point needing elucidation is how to interpret the variety of WSS values associated with aortic dilatations. Two opposite trends have emerged, one promoting lower WSS (Gnasso et al. about atherosclerotic plaque formation in carotid arteries; Malet et al. about quiescent endothelial phenotype gene expression), another promoting higher WSS, to induce aortic remodeling and aortopathy. In the future the WSS gradient distribution should receive more investigations than simply the WSS absolute value. Moreover, we recently underlined the correlation of RRT-distribution with aneurysm size and aortic wall remodeling.

About valve morphology, it seems that beyond BAV and TAV, the valve function, in terms of closing, opening and effective surface area, should receive more interest. In a simplistic model where the flow patterns in the ATA are determined

by geometric characteristics, the angle between the left ventricle chamber axis and the ATA axis should be taken into account. An excessive angle can give rise to a hemodynamics situation similar to mild aortic stenosis on a BAV or TAV, with jet flow impingement, helicity and vorticity. In any case the WSS gradients could be a relevant descriptor of deranged flow patterns in the ATA.

In the future, risk estimation should take into account patient-specific biomechanical factors. PWA and PWV techniques are good candidates for patient-specific non-invasive assessment of aortic stiffness and potentially cardiovascular risk^[116-117]. However, aortic stiffness can evolve due to various pathological conditions and completing PWA/PWV with 4D flow MRI represents a possible direction to interpret PWA/PWV results and determine the links between aortic stiffening and hemodynamics alterations.

6. Conclusions

In conclusion, hemodynamics markers obtained using 4D flow MRI or patient-specific CFD analyses have a significant potential for predicting ATA dysfunction, as summarized in Fig. 1. Ongoing efforts should focus on the correlation between these non-invasive biomarkers and clinico-pathologic situations according to the principles of personalized medicine. The potentially catastrophic consequences of aortic aneurysms represent a too heavy burden for patients and for the society in general. Reliable predictive models of ATAA evolution could finally allow clinicians to implement efficient pharmacological therapies in order to prevent disease onset or slow down progression.

Consent for Publication

Declared none.

Conflict of interest statement

The authors have no potential conflict of interest.

Funding

The authors are grateful to the European Research Council (**ERC grant Biolochanics, grant number 647067**).

Acknowledgements

The authors are grateful to the European Research Council (**ERC grant Biolochanics, grant number 647067**).

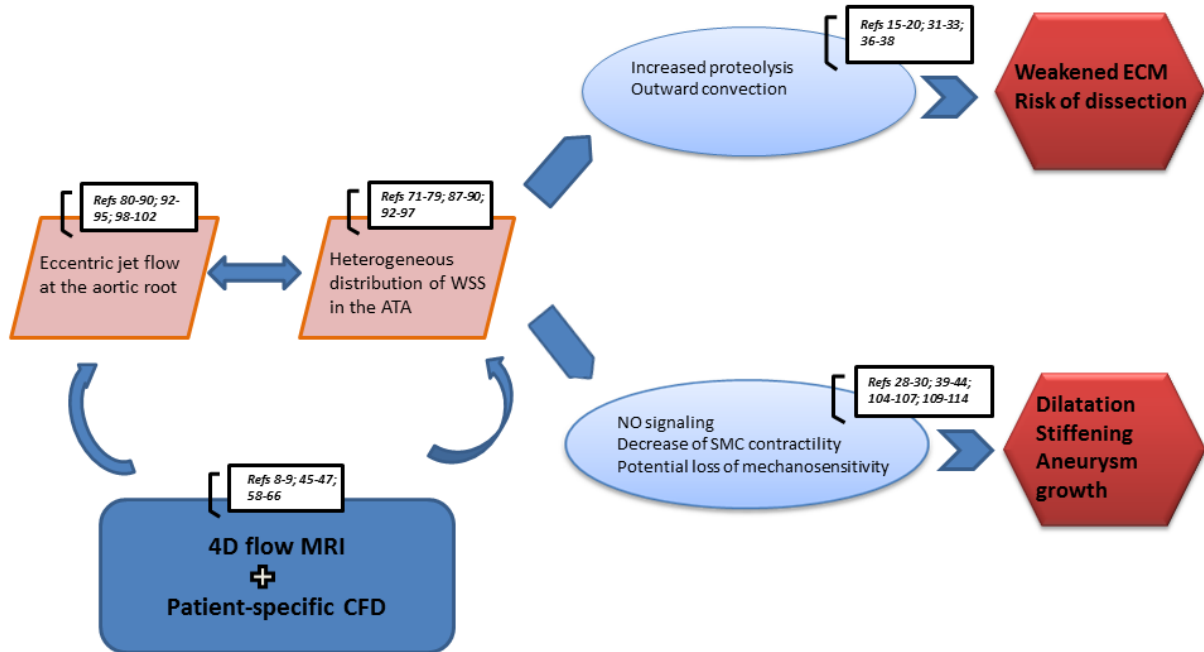


Figure 1. Conclusive concept illustration showing how hemodynamics markers obtained using 4D flow MRI or patient-specific CFD analyses can indicate ATA remodeling and potential dissection risk.

References

- [1] Erbel R, Aboyans V, Boileau C et al. **2014 ESC Guidelines on the diagnosis and treatment of aortic diseases: Document covering acute and chronic aortic diseases of the thoracic and abdominal aorta of the adult. The Task Force for the Diagnosis and Treatment of Aortic Diseases of the European Society of Cardiology (ESC).** *Eur Heart J.* (2014)
- [2] Evangelista A, Isselbacher EM, Bossone E et al. **Insights From the International Registry of Acute Aortic Dissection: A 20-Year Experience of Collaborative Clinical Research.** *Circulation.* 2018 Apr 24;137(17):1846-1860.
- [3] Elefteriades JA, Farkas EA. **Thoracic aortic aneurysm clinically pertinent controversies and uncertainties.** *J Am Coll Cardiol.* 2010 Mar 2;55(9):841-57.
- [4] Schnell S, Markl M, Entezari P, et al. **k-t GRAPPA accelerated four-dimensional flow MRI in the aorta: effect on scan time, image quality, and quantification of flow and wall shear stress.** *Magn Reson Med.* 2014;72(2):522–33.
- [5] Petersson S, Dyverfeldt P, Ebbers T. **Assessment of the accuracy of MRI wall shear stress estimation using numerical simulations.** *J Magn Reson Imaging.* 2012;36(1):128–38.
- [6] Boussel L, Rayz V, Martin A et al. **Phase-contrast magnetic resonance imaging measurements in intracranial aneurysms in vivo of flow patterns, velocity fields, and wall shear stress: comparison with computational fluid dynamics.** *Magn Reson Med.* 2009;61(2):409–17.
- [7] Sengupta PP, Pedrizzetti G, Kilner PJ et al. **Emerging trends in CV flow visualization.** *JACC Cardiovasc Imaging.* 2012;5(3):305–16.
- [8] Hope MD, Hope TA, Meadows AK, et al. **Bicuspid aortic valve: four-dimensional MR evaluation of ascending aortic systolic flow patterns.** *Radiology* 2010;255:53–61.2.
- [9] Hope MD, Hope TA, Crook SES et al. **4D Flow CMR in assessment of valve-related ascending aortic disease.** *J Am Coll Cardiol Img*2011;4:781–7.
- [10] Erbel R, Alfonso F, Boileau C et al. **Diagnosis and management of aortic dissection.** *Eur Heart J.* 2001 Sep;22(18):1642-81.
- [11] Gollledge J, Eagle KA. **Acute aortic dissection.** *Lancet.* 2008 Jul 5;372(9632):55-66.
- [12] DeBakey ME, Henly WS, Cooley DA et al. **SURGICAL MANAGEMENT OF DISSECTING ANEURYSMS OF THE AORTA.** *J Thorac Cardiovasc Surg.* 1965 Jan;49:130-49.
- [13] Scholl FG, Coady MA, Davies R et al. **Interval or permanent nonoperative management of acute type A aortic dissection.** *Arch Surg.* 1999 Apr;134(4):402-5.
- [14] Grewal N, Gittenberger-de Groot AC. **Pathogenesis of aortic wall complications in Marfan syndrome.** *Cardiovasc Pathol.* 2018 Mar - Apr;33:62-69.
- [15] Michel J-B. **Biology of Vascular Wall Dilation and Rupture.** Oxford, UK: Oxford University Press; 2017.
- [16] Lacolley P, Regnault V, Nicoletti A et al. **The vascular smooth muscle cell in arterial pathology: a cell that can take on multiple roles.** *Cardiovasc Res* 2012;95: 194–204. 3. Michel JB,

- [17] Michel JB, Jondeau G, Milewicz DM. **From genetics to response to injury: vascular smooth muscle cells in aneurysms and dissections of the ascending aorta.** *Cardiovasc Res.* 2018 Mar 15;114(4):578-589.
- [18] Lynn Y. Sakai, Douglas R. Keene, Marjolijn Renard et al. **FBN1: The Disease-Causing Gene for Marfan Syndrome and Other Genetic Disorders.** *Gene.* 2016 Oct 10; 591(1): 279–291.
- [19] Brownstein AJ, Ziganshin BA, Kuivaniemi H et al. **Genes associated with thoracic aortic aneurysm and dissection: an update and clinical implications.** *Aorta Stamford* 2017, 5(1):11–20.
- [20] Humphrey JD, Schwartz MA, Tellides G et al. **Role of mechanotransduction in vascular biology: focus on thoracic aortic aneurysms and dissections.** *Circ Res.* 2015 Apr 10;114(8):1448-61.
- [21] Wagenseil JE. **Bio-chemo-mechanics of thoracic aortic aneurysms.** *Curr Opin Biomed Eng.* 2018 Mar;5:50-57.
- [22] Davies HA, Caamaño-Gutiérrez E, Chim YH et al. **Idiopathic degenerative thoracic aneurysms are associated with increased aortic medial amyloid.** *Amyloid.* 2019 Sep;26(3):148-155.
- [23] Ruiz-Ortega M, Rodríguez-Vita J, Sanchez-Lopez E et al. **TGF-beta signaling in vascular fibrosis.** *Cardiovasc Res.* 2007;74:196– 206.
- [24] Trachet B, Piersigilli A, Fraga-Silva RA et al. **Ascending aortic aneurysm in angiotensin II infused mice: formation, progression, and the role of focal dissections.** *Arterioscler Thromb Vasc Biol* 2016, 36(4): 673–681.
- [25] Rateri DL, Davis FM, Balakrishnan A et al. **Angiotensin II induces region-specific medial disruption during evolution of ascending aortic aneurysms.** *Am J Pathol* 2014, 184(9):2586–2595.
- [26] Raúl Rodrigues Díez, Raquel Rodrigues-Díez, Carolina Lavoz et al. **Statins Inhibit Angiotensin II/Smad Pathway and Related Vascular Fibrosis, by a TGF- β -Independent Process.** *PLoS One.* 2010; 5(11): e14145.
- [27] Milleron O, Arnoult F, Ropers J et al. **Marfan Sartan: a randomized, double-blind, placebocontrolled trial.** *Eur Heart J* 2015, 36(32):2160–2166
- [28] Bersi MR, Khosravi R, Wujciak AJ et al. **Differential cell-matrix mechanoadaptations and inflammation drive regional propensities to aortic fibrosis, aneurysm or dissection in hypertension.** *J R Soc Interface* 2017, 14(136). 54.
- [29] Bachmann M, Kukkurainen S, Hytönen VP et al. **Cell Adhesion by Integrins.** *Physiol Rev.* 2019 Oct 1;99(4):1655-1699.
- [30] Conway JRW, Jacquemet G. **Cell matrix adhesion in cell migration.** *Essays Biochem.* 2019 Aug 23.
- [31] Maguire EM, Pearce SWA, Xiao R et al. **Matrix Metalloproteinase in Abdominal Aortic Aneurysm and Aortic Dissection.** *Pharmaceuticals (Basel).* 2019 Aug 6;12(3).
- [32] Nissinen L, Kähäri VM. **Matrix metalloproteinases in inflammation.** *Biochim Biophys Acta.* (2014)
- [33] An Z, Liu Y, Song ZG et al. **Mechanisms of aortic dissection smooth muscle cell phenotype switch.** *J Thorac Cardiovasc Surg.* 2017 Nov;154(5):1511-1521.
- [34] Ikonomidis JS, Nadeau EK, Akerman AW et al. **Regulation of membrane type-1 matrix metalloproteinase activity and intracellular localization in clinical thoracic aortic aneurysms.** *J Thorac Cardiovasc Surg.* 2017 Mar;153(3):537-546.

- [35] Liu C, Zhang C, Jia L et al. **Interleukin-3 stimulates matrix metalloproteinase 12 production from macrophages promoting thoracic aortic aneurysm/dissection.** *Clin Sci (Lond)*. 2018 Mar 26;132(6):655-668.
- [36] Pearce WH, Shively VP. **Abdominal aortic aneurysm as a complex multifactorial disease: interactions of polymorphisms of inflammatory genes, features of autoimmunity, and current status of MMPs.** *Ann N Y Acad Sci*. 2006 Nov;1085:117-32.
- [37] Benjamin MM, Khalil RA. **Matrix metalloproteinase inhibitors as investigative tools in the pathogenesis and management of vascular disease.** *Exp Suppl*. 2012;103:209-79.
- [38] Suzuki T, Distanto A, Eagle K. **Biomarker-assisted diagnosis of acute aortic dissection: how far we have come and what to expect.** *Curr Opin Cardiol*. 2010 Nov;25(6):541-5.
- [39] Botta DM Jr. **Biomarkers for diagnosis in thoracic aortic disease: PRO.** *Cardiol Clin*. 2010 May;28(2):207-11.
- [40] Suzuki T, Distanto A, Zizza A et al. **Diagnosis of acute aortic dissection by D-dimer: the International Registry of Acute Aortic Dissection Substudy on Biomarkers (IRAD-Bio) experience.** *Circulation*. 2009;119:2702-7.
- [41] Trescher K, Thometich B, Demyanets S et al. **Type A dissection and chronic dilatation: tenascin-C as a key factor in destabilization of the aortic wall.** *Interact Cardiovasc Thorac Surg*. 2013 Aug;17(2):365-70.
- [42] McCormick ML, Gavrila D, Weintraub NL. **Role of oxidative stress in the pathogenesis of abdominal aortic aneurysms.** *Arterioscler Thromb Vasc Biol*. 2007 Mar;27(3):461-9.
- [43] van Andel MM, Groenink M, Zwinderman AH et al. **The Potential Beneficial Effects of Resveratrol on Cardiovascular Complications in Marfan Syndrome Patients—Insights from Rodent-Based Animal Studies.** *Int J Mol Sci*. 2019 Mar 5;20(5).
- [44] Huynh DTN, Heo KS. **Arch Pharm Res. 2019 Aug 16. Therapeutic targets for endothelial dysfunction in vascular diseases.** *Arch Pharm Res*. 2019 Aug 16.
- [45] Youssefi P, Sharma R, Figueroa CA et al. **Functional assessment of thoracic aortic aneurysms - the future of risk prediction?** *Br Med Bull*. 2017 Jan 1;121(1):61-71.
- [46] Lo RC, Lu B, Fokkema MT et al. **Relative importance of aneurysm diameter and body size for predicting abdominal aortic aneurysm rupture in men and women.** *J Vasc Surg*. 2014 May;59(5):1209-16.
- [47] Fillinger MF, Raghavan ML, Marra SP et al. **In vivo analysis of mechanical wall stress and abdominal aortic aneurysm rupture risk.** *J Vasc Surg*. 2002 Sep;36(3):589-97.
- [48] Pol JA, Truijers M, van der Vliet JA et al. **Impact of dynamic computed tomographic angiography on endograft sizing for endovascular aneurysm repair.** *J Endovasc Ther*. 2009 Oct;16(5):546-51.
- [49] Suckow BD, Goodney PP, Columbo JA et al. **National trends in open surgical, endovascular, and branched-fenestrated endovascular aortic aneurysm repair in Medicare patients.** *J Vasc Surg*. 2018 Jun;67(6):1690-1697.
- [50] Les AS, Shadden SC, Figueroa CA et al. **Quantification of hemodynamics in abdominal aortic aneurysms during rest and exercise using magnetic resonance imaging and computational fluid dynamics.** *Ann Biomed Eng*. 2010 Apr;38(4):1288-313.

- [51] Suh GY, Les AS, Tenforde AS et al. **Quantification of particle residence time in abdominal aortic aneurysms using magnetic resonance imaging and computational fluid dynamics.** *Ann Biomed Eng.* 2011 Feb;39(2):864-83.
- [52] Lee JW, Hur JH, Yang DH et al. **Guidelines for Cardiovascular Magnetic Resonance Imaging from the Korean Society of cardiovascular Imaging-Part 2: Interpretation of Cine, Flow, and Angiography Data.** *Korean J Radiol.* 2019 Nov;20(11):1477-1490.
- [53] Zhao DL, Liu XD, Zhao CL et al. **Multislice spiral CT angiography for evaluation of acute aortic syndrome.** *Echocardiography.* 2017 Oct;34(10):1495-1499.
- [54] Renner J, Nadali Najafabadi H, Modin D et al. **Subject-specific aortic wall shear stress estimations using semi-automatic segmentation.** *Clin Physiol Funct Imaging.* 2012 Nov;32(6):481-91.
- [55] Madhavan S, Kemmerling EMC. **The effect of inlet and outlet boundary conditions in image-based CFD modeling of aortic flow.** *Biomed Eng Online.* 2018 May 30;17(1):66.
- [56] Pirola S, Cheng Z, Jarral OA et al. **On the choice of outlet boundary conditions for patient-specific analysis of aortic flow using computational fluid dynamics.** *J Biomech.* 2017 Jul 26;60:15-21.
- [57] Xu P, Liu X, Zhang H et al. **Assessment of boundary conditions for CFD simulation in human carotid artery.** *Biomech Model Mechanobiol.* 2018 Dec;17(6):1581-1597.
- [58] Jayendiran R, Nour BM, Ruimi A. **Dacron graft as replacement to dissected aorta: A three-dimensional fluid-structure-interaction analysis.** *J Mech Behav Biomed Mater.* 2018 Feb;78:329-341.
- [59] Lassila T, Manzoni A, Quarteroni A et al. **A reduced computational and geometrical framework for inverse problems in hemodynamics.** *Int J Numer Method Biomed Eng.* 2013 Jul;29(7):741-76.
- [60] Rodríguez-Palomares JF, Dux-Santoy L, Guala A et al. **Aortic flow patterns and wall shear stress maps by 4D-flow cardiovascular magnetic resonance in the assessment of aortic dilatation in bicuspid aortic valve disease.** *J Cardiovasc Magn Reson.* 2018 Apr 26;20(1):28.
- [61] Michael A. Day **The no-slip condition of fluid dynamics.** November 1990, Volume 33, Issue 3, pp 285–296.
- [62] Kleinstreuer C, Hyun S, Buchanan JR Jr et al. **Hemodynamic Parameters and Early Intimal Thickening in Branching Blood Vessels.** *Crit Rev Biomed Eng.* 2017;45(1-6):319-382.
- [63] Riccardello GJ Jr, Shastri DN, Changa AR et al. **Influence of Relative Residence Time on Side-Wall Aneurysm Inception.** *Neurosurgery.* 2018 Sep 1;83(3):574-581.
- [64] Arzani A, Gambaruto AM, Chen G et al. **Wall shear stress exposure time: a Lagrangian measure of near-wall stagnation and concentration in cardiovascular flows.** *Biomech Model Mechanobiol.* 2017 Jun;16(3):787-803.
- [65] Sugiyama S, Niizuma K, Nakayama T et al. **Relative residence time prolongation in intracranial aneurysms: a possible association with atherosclerosis.** *Neurosurgery.* 2013 Nov;73(5):767-76
- [66] Raja Jayendiran, Francesca Condemi, Salvatore Campisi et al. **Computational prediction of hemodynamical and biomechanical alterations induced by aneurysm dilatation in patient-specific ascending thoracic aortas.** Unedr submission.
- [67] Humphrey JD, Taylor CA. **Intracranial and abdominal aortic aneurysms: similarities, differences, and need for a new class of computational models.** *Annu Rev Biomed Eng* 2008;10:221–46.

- [68] Chien S, Li S, Shyy YJ. **Effects of mechanical forces on signal transduction and gene expression in endothelial cells.** *Hypertension* 1998;31:162–9.
- [69] Davies PF. **Flow-mediated endothelial mechanotransduction.** *Physiol Rev* 1995;75:519–60.
- [70] Gibbons GH, Dzau VJ. **The emerging concept of vascular remodeling.** *N Engl J Med* 1994;330:1431–8.
- [71] Langille BL. **Arterial remodeling: relation to hemodynamics.** *Can J Physiol Pharmacol* 1996;74:834–41.
- [72] Humphrey JD. **Mechanisms of arterial remodeling in hypertension: coupled roles of wall shear and intramural stress.** *Hypertension* 2008;52:195–200.
- [73] Cebal JR, Vazquez M, Sforza DM, et al. **Analysis of hemodynamics and wall mechanics at sites of cerebral aneurysm rupture.** *J Neurointerv Surg* 2015;7:530–6.
- [74] Gnasso A, Irace C, Carallo C, et al. **In vivo association between low wall shear stress and plaque in subjects with asymmetrical carotid atherosclerosis.** *Stroke* 1997;28:993–8.
- [75] Gnasso A, Carallo C, Irace C, et al. **Association between intima-media thickness and wall shear stress in common carotid arteries in healthy male subjects.** *Circulation* 1996;94:3257–62.
- [76] Malek AM, Alper SL, Izumo S. **Hemodynamic shear stress and its role in atherosclerosis.** *JAMA* 1999;282:2035–42.
- [77] Della Corte A, De Santo LS, Montagnani S, et al. **Spatial patterns of matrix protein expression in dilated ascending aorta with aortic regurgitation: congenital bicuspid valve versus Marfan's syndrome.** *J Heart Valve Dis* 2006;15:20–7.
- [78] Della Corte A, Quarto C, Bancone C, et al. **Spatiotemporal patterns of smooth muscle cell changes in ascending aortic dilatation with bicuspid and tricuspid aortic valve stenosis: focus on cell-matrix signaling.** *J Thorac Cardiovasc Surg* 2008;135:8–18. 18.e1–2.
- [79] Guzzardi DG, Barker AJ, van Ooij P, et al. **Valve-related hemodynamics mediate human bicuspid aortopathy: insights from wall shear stress mapping.** *J Am Coll Cardiol* 2015;66:892–900.
- [80] Michelena, H. I., Della Corte A, Prakash et al. **Bicuspid aortic valve aortopathy in adults: incidence, etiology, and clinical significance.** *Int. J. Cardiol.* 2015 ; 201, 400–407.
- [81] Michelena, H. I., Khanna, A. D., Mahoney, D. et al. **Incidence of aortic complications in patients with bicuspid aortic valves.** *JAMA* 2011;306, 1104–1112.
- [82] Ratnasari Padang, Paul G. Bannon, Richmond Jeremy et al. **The genetic and molecular basis of bicuspid aortic valve associated thoracic aortopathy: a link to phenotype heterogeneity.** *Ann Cardiothorac Surg.* 2013 Jan; 2(1): 83–91.
- [83] Siu SC, Silversides CK. **Bicuspid aortic valve disease.** *J Am Coll Cardiol* 2010;55:2789–800
- [84] Cripe L, Andelfinger G, Martin LJ, et al. **Bicuspid aortic valve is heritable.** *J Am Coll Cardiol* 2004;44:138–43
- [85] Vallely MP, Semsarian C, Bannon PG. **Management of the ascending aorta in patients with bicuspid aortic valve disease.** *Heart Lung Circ* 2008;17:357–63
- [86] Ward C. **Clinical significance of the bicuspid aortic valve.** *Heart* 2000;83:81–5

- [87] Barker AJ, Markl M, Burk J, et al. **Bicuspid aortic valve is associated with altered wall shear stress in the ascending aorta.** *Circ Cardiovasc Imaging* 2012;5:457–66.
- [88] Girdauskas E., Borger M. A., Secknus M. A. et al. **Is aortopathy in bicuspid aortic valve disease a congenital defect or a result of abnormal hemodynamics? A critical reappraisal of a one-sided argument.** *Eur. J. Cardiothorac. Surg.* 2011;39, 809–814.
- [89] Girdauskas, E., Borger, M. A. **Surgical threshold for bicuspid aortic valve associated aortopathy: does the phenotype matter?** *JACC Cardiovasc Imaging* 2014;7:318.
- [90] Bissell MM, Hess AT, Biasioli L, et al. **Aortic dilation in bicuspid aortic valve disease: flow pattern is a major contributor and differs with valve fusion type.** *Circ Cardiovasc Imaging* 2013;6:499–507.
- [91] Mahadevia R, Barker AJ, Schnell S, et al. **Bicuspid aortic cusp fusion morphology alters aortic three-dimensional outflow patterns, wall shear stress, and expression of aortopathy.** *Circulation* 2014;129:673–82.
- [92] Piatti F, Pirola S, Bissell M et al. **Towards the improved quantification of in vivo abnormal wall shear stresses in BAV-affected patients from 4D-flow imaging: Benchmarking and application to real data.** *J Biomech.* 2017 Jan 4;50:93-101.
- [93] Piatti F, Sturla F, Bissell MM et al. **4D Flow Analysis of BAV-Related Fluid-Dynamic Alterations: Evidences of Wall Shear Stress Alterations in Absence of Clinically-Relevant Aortic Anatomical Remodeling.** *Front Physiol.* 2017 Jun 26;8:441.
- [94] Fatehi Hassanabad A, Barker AJ, Guzzardi D et al. **Evolution of Precision Medicine and Surgical Strategies for Bicuspid Aortic Valve-Associated Aortopathy.** *Front Physiol.* 2017 Jul 10;8:475.
- [95] Gülan U, Calen C, Duru F et al. **Blood flow patterns and pressure loss in the ascending aorta: A comparative study on physiological and aneurysmal conditions.** *J Biomech.* 2018 Jul 25;76:152-159.
- [96] Condemi F, Campisi S, Viallon M et al. **Ascending thoracic aorta aneurysm repair induces positive hemodynamic outcomes in a patient with unchanged bicuspid aortic valve.** *Biomech.* 2018 Nov 16;81:145-148.
- [97] P. Youssefi, A. Gomez, T. He et al. **Patient-specific computational fluid dynamics-assessment of aortic hemodynamics in a spectrum of aortic valve pathologies.** *J. Thorac. Cardiovasc. Surg.*, 153 (2017), pp. 8-20.e23
- [98] Condemi F, Campisi S, Viallon M et al. **Fluid- and Biomechanical Analysis of Ascending Thoracic Aorta Aneurysm with Concomitant Aortic Insufficiency.** *Ann Biomed Eng.* 2017 Dec;45(12):2921-2932.
- [99] Lorenz R, Bock J, Barker AJ et al. **4D flow magnetic resonance imaging in bicuspid aortic valve disease demonstrates altered distribution of aortic blood flow helicity.** *Magn Reson Med.* 2014 Apr;71(4):1542-53.
- [100] Campobasso R, Condemi F, Viallon M et al. **Evaluation of Peak Wall Stress in an Ascending Thoracic Aortic Aneurysm Using FSI Simulations: Effects of Aortic Stiffness and Peripheral Resistance.** *Cardiovasc Eng Technol.* 2018 Dec;9(4):707-722
- [101] Borger MA, Fedak PWM, Stephens EH et al. **The American Association for Thoracic Surgery consensus guidelines on bicuspid aortic valve-related aortopathy.** *J Thorac Cardiovasc Surg.* 2018 Aug;156(2):e41-e74.

- [102] O'Rourke M, Farnsworth A, O'Rourke J. **Aortic dimensions and stiffness in normal adults.** *JACC Cardiovascular imaging.* 2008; 1:749–51.
- [103] O'Rourke MF, Hashimoto J. **Mechanical factors in arterial aging: a clinical perspective.** *Journal of the American College of Cardiology.* 2007; 50:1–13.
- [104] Mitchell GF, Hwang SJ, Vasan RS et al. **Arterial stiffness and cardiovascular events: the Framingham Heart Study.** *Circulation.* 2010; 121:505–11.
- [105] Ohyama Y, Redheuil A, Kachenoura N et al. **Imaging Insights on the Aorta in Aging.** *Circ Cardiovasc Imaging.* 2018 Apr;11(4):e005617.
- [106] Yanagisawa H, Wagenseil J. **Elastic fibers and biomechanics of the aorta: Insights from mouse studies.** *Matrix Biol.* 2019 Mar 15.
- [107] McEniery CM, Yasmin, Hall IR et al. **Normal vascular aging: differential effects on wave reflection and aortic pulse wave velocity: the Anglo-Cardiff Collaborative Trial (ACCT).** *Journal of the American College of Cardiology.* 2005; 46:1753–60
- [108] Kenyhercz WE, Raterman B, Illapani VS et al. **Quantification of aortic stiffness using magnetic resonance elastography: Measurement reproducibility, pulse wave velocity comparison, changes over cardiac cycle, and relationship with age.** *Magn Reson Med.* 2016 May;75(5):1920-6.
- [109] London GM, Guerin AP. **Influence of arterial pulse and reflected waves on blood pressure and cardiac function.** *Am Heart J.* 1999; 138:220–4.
- [110] Kass DA. **Ventricular arterial stiffening: integrating the pathophysiology.** *Hypertension.* 2005;46:185–93.
- [111] Safar ME, Levy BI, Struijker-Boudier H. **Current perspectives on arterial stiffness and pulse pressure in hypertension and cardiovascular diseases.** *Circulation.* 2003; 105:2864–9.
- [112] Boutouyrie P, Tropeano AI, Asmar R et al. **Aortic Stiffness Is an Independent Predictor of Primary Coronary Events in Hypertensive Patients: A Longitudinal Study.** *Hypertension.* 2002; 39:10–15.
- [113] Redheuil A, Yu WC, Mousseaux E, Harouni AA et al. **Age-related changes in aortic arch geometry: relationship with proximal aortic function and left ventricular mass and remodeling.** *Journal of the American College of Cardiology.* 2011; 58:1262–70.
- [114] López-Guimet J, Peña-Pérez L, Bradley RS et al. **MicroCT imaging reveals differential 3D micro-scale remodelling of the murine aorta in ageing and Marfan syndrome.** *Theranostics.* 2018 Nov 15;8(21):6038-6052.
- [115] Bonnans C, Chou J, Werb Z. **Remodelling the extracellular matrix in development and disease.** *Nature Reviews. Molecular Cell Biology.* Dec 2014; 15 (12): 786–801.
- [116] A. N Gurovich, R. W Braith. **Pulse wave analysis and pulse wave velocity techniques: are they ready for the clinic?** *Hypertension Research (2011) 34, 166–169.*
- [117] S. Sherifova, G. A. Holzapfel. **Biomechanics of aortic wall failure with a focus on dissection and aneurysm: A review.** *Acta Biomater.* 2019 November; 99: 1–17.

Established facts

- **ATAAs can lead to catastrophic complications as aortic dissection.**
- **The aorta can dissect at diameter values inferior to 55 mm.**
- **There is growing evidence about the importance of hemodynamics in determining growth and remodeling in the aortic wall.**

Lines of research

- **How patient-specific factors like aging, aortic valve morphology and function, ascending aorta geometry can influence hemodynamics, vascular biology and, consequently, aortic wall remodeling.**
- **How altered hemodynamics descriptors could indicate a potential future risk for a mildly pathological aorta.**

Future directions

- **Coupling 4D MRI and CFD is a promising approach to study flow characteristics and biomechanical forces reproducing as closely as possible the patient-specific conditions in the aorta.**
- **Developing of patient specific risk model of aortic wall rupture.**