



HAL
open science

Cemented vs Uncemented Femoral Components: A Randomized, Controlled Trial at 10 Years Minimum Follow-Up

Cécile Batailler, Yves Malemo, Guillaume Demey, Raymond Kenney,
Sebastien Lustig, Elvire Servien

► **To cite this version:**

Cécile Batailler, Yves Malemo, Guillaume Demey, Raymond Kenney, Sebastien Lustig, et al.. Cemented vs Uncemented Femoral Components: A Randomized, Controlled Trial at 10 Years Minimum Follow-Up. *The Journal of Arthroplasty*, 2020, 35 (8), pp 2090-2096. 10.1016/j.arth.2020.03.043 . hal-03138588

HAL Id: hal-03138588

<https://hal.science/hal-03138588v1>

Submitted on 22 Aug 2022

HAL is a multi-disciplinary open access archive for the deposit and dissemination of scientific research documents, whether they are published or not. The documents may come from teaching and research institutions in France or abroad, or from public or private research centers.

L'archive ouverte pluridisciplinaire **HAL**, est destinée au dépôt et à la diffusion de documents scientifiques de niveau recherche, publiés ou non, émanant des établissements d'enseignement et de recherche français ou étrangers, des laboratoires publics ou privés.



Distributed under a Creative Commons Attribution - NonCommercial 4.0 International License

1 **Cemented versus uncemented femoral components: A randomized control**
2 **trial at 10 years minimum follow-up.**

3 Cécile BATAILLER, MD¹, Yves MALEMO, MD¹, Guillaume DEMEY, MD^{1,2}, Raymond
4 KENNEY, MD^{1,3}, Sébastien LUSTIG, MD, PhD^{1,4}, Elvire SERVIEN, MD, PhD^{1,5}

5
6 **Institution(s) at which the work was performed.**

7 Orthopedic Surgery Department, Croix-Rousse Hospital,
8 103 grande rue de la Croix-Rousse,
9 69004 LYON, France

10
11 **Affiliations.**

12 ¹ Orthopedic Surgery Department, Croix-Rousse Hospital, 103 grande rue de la Croix-Rousse,
13 69004 LYON, France

14
15 ² Lyon-Ortho-Clinic, Clinique de la Sauvegarde, 8 Avenue Ben Gourion, 69009, Lyon,
16 France.

17
18 ³ Department of Orthopaedics; University of Rochester Medical Center, 4901 Lac De Ville
19 Blvd Building D, ROCHESTER, NY 14618, USA

20
21 ⁴ Univ Lyon, Université Claude Bernard Lyon 1, IFSTTAR, LBMC UMR_T9406, 69622,
22 Villeurbanne, France

23
24 ⁵ EA 7424 – Interuniversity Laboratory of Human Movement Science, Université Lyon 1,
25 Lyon, France

26
27
28 **Authors**

29 1. Cécile BATAILLER
30 MD. Orthopaedic Department.
31 Lyon North University Hospital,
32 Hôpital de la Croix Rouse, Hospices Civils de Lyon
33 103 Grande Rue de la Croix Rouse, 69004 Lyon, France

34 mail: cecile-batailler@hotmail.fr

35

36 2. Yves MALEMO

37 MD. Orthopaedic Department.

38 Lyon North University Hospital,

39 Hôpital de la Croix Rouse, Hospices Civils de Lyon

40 103 Grande Rue de la Croix Rouse, 69004 Lyon, France

41 mail: nostrakin@hotmail.fr

42

43 3. Guillaume DEMEY

44 MD. Orthopaedic Department.

45 Lyon-Ortho-Clinic, Clinique de la Sauvegarde

46 8 Avenue Ben Gourion, 69009, Lyon, France

47 mail: demeyguillaume@gmail.com

48

49 4. Raymond KENNEY

50 MD. Orthopaedic Department.

51 Department of Orthopaedics; University of Rochester Medical Center,

52 4901 Lac De Ville Blvd Building D, ROCHESTER, NY 14618, USA

53 mail: raymond_kenney@urmc.rochester.edu

54

55 5. Sebastien LUSTIG

56 MD, PhD, Prof. Orthopaedic Department.

57 Lyon North University Hospital,

58 Hôpital de la Croix Rouse, Hospices Civils de Lyon

59 103 Grande Rue de la Croix Rouse, 69004 Lyon, France

60 mail: sebastien.lustig@gmail.com

61

62 6. Elvire SERVIEN

63 MD, PhD, Prof. Orthopaedic Department.

64 Lyon North University Hospital,

65 Hôpital de la Croix Rouse, Hospices Civils de Lyon

66 103 Grande Rue de la Croix Rouse, 69004 Lyon, France

67 mail: elvire.servien@chu-lyon.fr

68

69 **Corresponding Author.**

70 Cécile BATAILLER

71 cecile-batailler@hotmail.fr

72

73

74 **Conflict of interest**

75 CB, YM, RK and GD declare that they have no conflict of interest.

76 ES: consultant for Corin.

77 SL: consultant for Smith & Nephew, institutional research support to Corin and Amplitude.

78

79 **Funding**

80 This research did not receive any specific grant from funding agencies in the public,

81 commercial, or not-for-profit sectors.

82

83 **Ethical approval**

84 All procedures performed in studies involving human participants were in accordance with
85 the ethical standards of the institutional and/or national research committee and with the 1964
86 Helsinki declaration and its later amendments or comparable ethical standards.

87 The study was registered at ClinicalTrials.gov (Identifier: NCT00132587) and was approved
88 by our hospital's Institutional Review Board as a Randomized Controlled Trial (study ID
89 Number: 2003.095.2A). All patients signed a consent form that included a description of the
90 protocol and the potential complications of both procedures.

91

92 **Authors' contributions**

93 CB: study design, statistical analysis, literature review and manuscript writing.

94 YM: data collection, literature review and manuscript writing.

95 GD: study design, literature review and manuscript editing.

96 RK, SL: study design and manuscript editing.

97 ES: study design, supervision, literature review and manuscript editing.

98 All authors read and approved the final manuscript.

1 **Cemented versus uncemented femoral components: A randomized control trial at**
2 **10 years minimum follow-up**

3
4

5 **Abstract**

6 Background.

7 The type of TKA fixation (cemented or uncemented) is still subject to debate. The aim of this study was
8 to assess the survival rate, clinical outcomes and radiological results of TKA according to the fixation
9 type.

10 Methods.

11 130 patients were randomly assigned to either the Cement Group (cemented femoral and tibial
12 implants) or the Hybrid Group (cemented tibial implant, uncemented femoral implant). The inclusion
13 criteria were patients between 50 and 90 years old who underwent primary TKA for osteoarthritis
14 between 2004 and 2005 without a history of prior open knee surgery. Revisions and complications were
15 reported, as well as, clinical scores and radiological signs of loosening.

16 Results.

17 118 patients had complete data at 10 years of minimum follow-up (59 in each group). The mean age
18 was 72 years-old. The mean follow-up was 13 years. The survival rate was 98% at 13 years in both
19 groups (one aseptic loosening at 2 years in the Cement Group, one septic loosening in the Hybrid
20 Group). The complication rate in the Cement Group was 8.5% (n=5) versus 12.1% (n=7) in the Hybrid
21 Group (p=0.8). The clinical results were not significantly different. In the Cement Group, 25% of
22 patients (n=15) had radiolucent lines at 10 years. In the Hybrid Group, 33% of patients had bone
23 transparencies, not evolving or symptomatic.

24 Conclusion.

25 At a minimum follow-up of 10 years, there were no significant difference between cemented TKA and
26 hybrid TKA for the survivorship, the complications rate, the clinical scores or the radiologic signs of
27 loosening.

28

29 **Level of Evidence:** I

30

31 **Keywords:** Total knee replacement; Cemented femoral implant; Uncemented femoral implant; survival
32 rate; loosening.

33 **Abbreviations**

34 BMI: Body Mass Index

35 HKA: Hip Knee Ankle

36 KSS: Knee Society Score

37 OA: Osteoarthritis

38 PE: Poly-Ethylene

39 TKA: Total Knee Arthroplasty

40 **Introduction**

41 Knee osteoarthritis is a common problem with well-described negative effects on patient's quality
42 of life[1]. Total knee arthroplasty (TKA) remains one of the most successful medical procedures to
43 restore a patient's knee function and alleviate pain when nonoperative methods have been exhausted.
44 Despite advances in TKA technique and implants, a significant number of revision TKA procedures are
45 performed annually. Over time, the fixation of TKA has been assessed and improved, in an effort to
46 decrease failures due to implant loosening.

47 The question of whether cement is required for implant fixation remains open to debate[2]. Some
48 of the earliest TKA models were cemented implants, with numerous subsequent studies demonstrating
49 excellent long-term survivorship[1, 3-5]. However, several studies described some disadvantages of
50 cemented implants. Failure of the cement-bone interface[6] with lack of remodeling capacity of bone
51 cement as well as third-body wear raise concerns over the long-term durability of cemented fixation.
52 Mjöberg et al.[7, 8] then Stürup et al.[9] reported that the cement can be toxic and lead to bone damages
53 due to the local heat. Gandhi et al. demonstrated that cement degrades in long-term follow-up[10]. These
54 findings led to the development of uncemented TKA implant design. Historically, cementless implants
55 have experienced early loosening and complications especially at the tibial and patellar interfaces[11-
56 13]. However, with more modern implant designs and fixation as well as a better understanding of
57 surgical technique, outcomes have improved. Good long-term results have also been reported with
58 uncemented implants in recent years[14-16].

59 The major concern with uncemented TKA procedures has been the reliability of the tibial
60 component fixation. Several comparative studies have demonstrated improved results with cemented
61 tibial components[11, 17, 18]. Potential long-term benefits of implants with bone integration continue
62 to drive interest in uncemented implants, particularly on the femoral side where the geometry may be
63 more suitable for this type of fixation[19]. Hybrid TKA utilizing cemented tibial components combined

64 with uncemented fixation of the femoral component presents a solution to this problem[2]. The
65 theoretical benefits of uncemented femoral component are preservation of bone stock, absence of
66 cement debris, extended survival due to bone integration, particularly in young patients. However,
67 there are other references against the use of hybrid fixation, due to the increased revision rate[20].

68 The aim of this study was to compare the survival rate of either an uncemented femoral component
69 or an all cemented TKA, using a single implant design, at a minimum of 10-year follow-up. We
70 hypothesized that there were no significant differences for the femoral implant survival, for the rate of
71 radiographic signs of femoral implant loosening or for clinical outcomes.

72

73 **Materials and Methods**

74 *Patients*

75 A prospective, randomized, single center study included 130 consecutive primary TKA between
76 2004 and 2005. Inclusion criteria were: age between 50 and 90 years old and an indication of a primary
77 TKA for osteoarthritis. Exclusion criteria included rheumatoid arthritis, preoperative knee flexion less
78 than 90 degrees, associated femoral or tibial osteotomy, history of prior ipsilateral knee surgery other
79 than arthroscopy. Randomization was performed via random number generation. The study was
80 registered at ClinicalTrials.gov (Identifier: NCT00132587) and was approved by our hospital's
81 Institutional Review Board as a Randomized Controlled Trial (study ID Number: 2003.095.2A). All
82 patients signed a consent form that included a description of the protocol and the potential
83 complications of both procedures. The patients were blinded on the used surgical technique.

84 One hundred thirty patients were randomized into the cemented (n=65) or hybrid (n=65) groups.
85 One patient randomized to the hybrid group underwent cementing of the femoral component due to
86 failure of the press fit fixation, during the trials of primary TKA (Fig.1).

87

88 *Surgery*

89 The surgical technique for both groups has been described in detail in previous studies[21, 22]. All
90 operations were performed by senior surgeons. The surgical approach was a medial or lateral
91 parapatellar approach depending on the pre-operative limb deformity. The TKA was performed with the
92 same technique for all patients, including the trial implants positioning. At this point, the sealed
93 envelope was opened in the operating room and fixation proceeded according to the randomization
94 protocol. The tibial and patellar components were cemented in all cases and the femoral component was
95 either cemented (cement group) or placed without cement (hybrid group).

96 The same prosthesis (HLS Noetos, Tornier, St-Ismier, France) was used in all cases. This implant
97 is a posterior stabilized TKA, the design of which has been previously described[23]. There were two
98 types of femoral component differentiated by the method of fixation: cemented femoral component or
99 hydroxyapatite-coated femoral component (uncemented). The femoral component is a chrome cobalt
100 component. The uncemented femoral component has a coating of hydroxyapatite with a thickness of
101 75µm and a hydroxyapatite purity superior to 95%. The bioactive titanium-hydroxyapatite coating is
102 applied using a vacuum plasma spray technique.

103
104 *Data management*

105 Pre-operatively, all patients were evaluated clinically (range of motion ; International Knee Society
106 (IKS) scores[24]) and radiographically. Radiographic evaluation included anteroposterior, lateral,
107 patellar and long leg films. Limb alignment of the knee was defined using the hip-knee-ankle angle.

108 Clinical and radiographic assessments were repeated at two years and at least ten years post-
109 operatively. The major complications included all complications needing revisions or all life-
110 threatening complications (particularly deep infections, vascular complications, fractures, loosening,
111 patellar complications...). The radiographic assessment also included an assessment of radiolucent lines
112 and bone transparency about the femoral component on the lateral radiograph. Radiolucent lines (RLL)

113 were evaluated in terms of location, width (in millimeters), and progression as recommended by the
114 Knee Society[25]. RLL were observed at the interface between bone and cement for cemented
115 component or between bone and prosthesis in case of uncemented component. Zone 1 was defined as
116 the anterior area, zone 2 as the anterior chamfer, zone 3 as the posterior chamfer, zone 4 as the posterior
117 area, and zones 5–7 as central (Fig. 2). The same observer made all measurements manually on plain
118 radiographs. The bone radiotransparencies corresponded with a low radiopacity at the interface between
119 bone and prosthesis, with a width greater than 2mm.

120

121 *Statistical analysis*

122 For the power analysis, we considered that a difference of 15-points in the post-operative IKS
123 score was significant, according to previous analyses in our department and some studies[26, 27]. A
124 power analysis demonstrated that a 15 points difference in post-operative IKS score would be detected
125 with 80% power ($\alpha = 0.05$) with 64 patients in each group. A post-hoc power analysis has been
126 performed (12 lost to follow-up). This post-hoc power analysis found a power superior to 80%.

127 All analyses were performed utilizing the intention to treat principle. Comparisons between the
128 cemented and hybrid groups were carried out with Student's t-tests and Fisher's exact tests for
129 continuous and categorical data respectively. Continuous variables were averaged and reported with
130 standard deviation. A p value <0.05 was considered statistically significant in each analysis. SPSS 13.0
131 software (SPSS Inc., Chicago, IL) was used for all statistical calculations.

132

133 *Funding source*

134 This research did not receive any specific grant from funding agencies in the public, commercial, or
135 not-for-profit sectors.

136

137 **Results**

138 One hundred eighteen patients (90%) were clinically and radiologically assessed at a minimum
139 follow up of 10 years (59 patients (90%) from the cemented group; 59 patients (89%) from the hybrid
140 group). Twelve patients died from the cemented group and 9 from the hybrid group, with complete data
141 at the last follow-up. Twelve patients could not be reviewed during this period for personal reasons
142 (unable to come in hospital due to health problem or a long-distance move) (7 for Cement Group, 5 for
143 Hybrid Group) (Fig. 1). The mean follow-up of the 118 patients was 13.1 ± 1.2 years [10;14.4]. The
144 patients lost to follow-up had no complication or revision at the last follow-up. Their mean follow-up
145 was 7.9 ± 1.6 years [2.7;9.4]. There were no significant differences concerning clinical and radiographic
146 data preoperatively between both groups (Table 1).

147

148 *Survival rate*

149 In the hybrid group, one patient required revision for septic loosening prior to two years post-
150 operative. No revision TKAs were performed for mechanical failure or aseptic loosening. The survival
151 rate at 14.2 years of follow-up was 98.3%. In the cement group, one patient underwent revision for
152 aseptic loosening prior to two years post-operative. The survival rate at 13.9 years of follow-up was
153 98.2%. There was no significant difference of the survival rate between both groups. There was no
154 predictive factor of surgical revision.

155

156 *Complications*

157 The rate of major complications in the hybrid group was 8.5%. These complications included:
158 one revision for patellar instability, one acute deep infection treated by debridement, antibiotics and
159 implant retention (DAIR), one vascular bypass following a popliteal thrombosis at 3 weeks post-
160 operatively, and 2 traumatic-fractures at 13.0 years follow-up.

161 In the cemented group, the rate of major complications was 3.4%. These complications included:
162 one patient underwent arthroscopy for a loose body (cement fragment) removal and clunk syndrome, and
163 one patient required exchange to a large polyethylene insert due to symptomatic varus valgus laxity.
164 There was no significant difference of the complications rate between both groups. The complications
165 were not secondary to the femoral fixation.

166

167 *Clinical outcomes*

168 IKS scores significantly improved in both groups following TKA ($p < 0.05$), without significant
169 difference of post-operative scores between both groups at the last follow up (Table 2).

170

171 *Radiographic results*

172 There were no significant difference concerning radiographic measurements.

173 There was a significant difference of bone transparencies of the femoral epiphysis between both
174 groups ($n=6$ for Cement Group (10 %); $n=17$ for Hybrid Group (29 %); $p < 0.05$) (Table 3). In all cases,
175 the bone transparencies were observed in zone 2, under the anterior chamfer cut (Fig. 3), and appeared
176 during the first year.

177 Transparency was noted in 35 of the 59 patients in the hybrid group at two years post-operative. At ten
178 years post-operative, the transparency had resolved in 18 patients (51.4%) and remained stable in 17
179 patients (48.6%). No new bony transparency developed between 2- and 10-years post-operative.

180

181 Radiolucent lines were more frequent in the Cement Group at the last follow-up ($p < 0.05$) (Table
182 3). Radiolucent lines were noted for 25% of patients ($n=15/59$) in the Cement Group at two years post-
183 operative. At ten years post-operative, these lines had progressed in 3 patients (20%) (Fig. 4) and
184 remained stable in 12 patients (80%). All radiolucent lines measured less than 2 mm in width.

185 Radiolucent lines were noted in only one patient in the Hybrid Group. This patient was revised for
186 septic loosening prior to 2-year follow-up.

187 No risk factors for radiolucent lines or bone transparencies have been found except the type of
188 implant. There was no correlation between IKS scores and the presence of radiolucent lines or bone
189 transparencies.

190

191 **Discussion**

192 The most important finding of this prospective randomized study was a similarly high survival rate
193 between cemented and uncemented femoral implants at a minimum of 10 years follow-up. To our
194 knowledge, this study is one of the randomized controlled trials with the longest follow-up period
195 comparing hybrid TKA with a cemented TKA.

196 The recent studies comparing cemented and uncemented femoral components reported similar
197 results to this study. The difference of survival rate is not statistically significant between both types of
198 implants, even for mobile-bearing TKA system. Iofisidis et al. found that the fixation technique had no
199 influence on the prosthesis's survivorship, and on clinical and radiographic outcomes at a mean follow-
200 up of 9.5 years[28]. Their revision rate was 4.9% in the uncemented group. The survivorship rate of
201 hybrid TKA varied between 94.3% and 98.2% at 5 years of follow-up[29, 30], and between 83% and
202 96.3% at 15 years of follow-up[30, 31]. The rate of aseptic loosening of hybrid TKA remained at less
203 than 1% at 10 years of follow-up in recent studies, similar to cemented TKA[29-31].

204 Few studies describe the survival rate of cemented and hybrid TKA at a long follow-up[32, 33]. On 77
205 hybrid TKA at 12 years of follow-up, Perry et al. found that press-fit fixation of the femoral component
206 was a reliable and durable alternative to cemented fixation[34]. McLaughlin and Lee showed that
207 primary hybrid TKA can achieve excellent fixation at 16 years of follow-up[35].

208

209 Several older studies reported a higher rate of aseptic loosening for uncemented femoral
210 components[36, 37]. Campbell et al. reported that 13.8% of the hybrid TKA's required revision[38].
211 The common characteristic between these older studies is their publication date prior to 2002. The type
212 of surface coating of the uncemented implant may be of importance. The biological fixation of the
213 femoral component with bone ingrowth should be more efficient with newer coating technologies[17].
214 Henricson et al. reported no statistically significant differences in implants migration (radiostereometric
215 analysis) or clinical results between cemented TKA and uncemented TKA with porous fiber titanium
216 mesh coating at 10 years follow-up[39]. Other uncemented designs with clinical results equal to
217 cemented design have been equipped with various types of porous coatings[16, 40-43] or
218 hydroxyapatite (HA) coating[21, 44, 45]. Smooth or grit blasted surface seems to result in inferior
219 uncemented fixation[36]. Pijls et al. compared component migration in HA-coated versus non-HA-
220 coated TKA[46]. They concluded that HA reduced migration of uncemented TKA.

221
222 Another important finding of this study was the significant radiographic differences (bone
223 transparencies and radiolucent lines) between both groups at ten years follow-up. However, these
224 radiographic findings did not influence clinical outcomes or survivorship. Park and Kim found
225 significant radiolucent lines in only 5% of the cemented and uncemented TKA at 14 years follow-
226 up[33]. By contrast, Illgen et al. reported radiolucent lines in the uncemented femoral components in
227 about 13% at 10 years[42]. We observed that bone transparency was more frequently noted in the
228 hybrid group at ten years follow-up, in all cases in zone 2 under the anterior chamfer cut.

229 The most interesting finding was that the half of the bone transparencies observed at 2 years
230 spontaneously resolved at 10 years. We can suppose that some of these bone transparencies were
231 secondary to the bone preparation during the surgery and disappear over time as the bone remodels
232 postoperatively. Liu et al.[47] and Peters et al.[48] reported that distal femoral bone density decreased
233 between the 6th month and the 12th month postoperatively after performing TKA. Akizuki et al.

234 described a spontaneous disappearance of the clear zones at 12 months postoperatively after
235 uncemented TKA[49]. Asymptomatic bone transparencies at 2 years of uncemented hybrid TKA are not
236 worrying situations of early loosening and need only a regular monitoring.

237
238 According to our study, there was no difference for the clinical outcomes at 10 years follow-up
239 between both groups. Gao et al. found no significant differences in clinical outcomes[50]. Pelt et al.
240 reported that hybrid fixation leads to similar intermediate-term outcomes as fully cemented
241 components[51]. Several recent studies described similar results for cemented and uncemented
242 TKA[18, 28-30, 32, 33, 52].

243
244 In the currently published literature and in our study, there was no demographic risk factor of
245 aseptic loosening identified after TKA with uncemented femoral component, particularly the
246 obesity[29, 53]. Some studies can be distorted by the lack of randomization. Indeed, the surgeons can
247 choose during the surgery between the use of cemented or uncemented components, according to the
248 bone quality. In this study, the two groups were comparable because the patients were randomized and
249 only one patient had bone quality deemed too poor for an uncemented TKA.

250
251 This study had some limitations. Firstly, the assessment of the femoral loosening was performed on
252 radiographs, without CT scan. But these exams are invasive and not justified for the usual follow-up
253 after TKA. Secondly, we didn't assess the polyethylene wear, which can be a cause of aseptic
254 loosening. We don't perform a radiostereometric analysis in current practice. But the two groups of
255 patients had the same design of implant and the same polyethylene. A previous study has described a
256 very low rate of polyethylene wear for these same implants [54]. Additionally, the patients have two
257 types of surgical approaches (medial and lateral approaches). Nevertheless, due to the randomization,
258 the two groups were comparable for this parameter. Then, there were several patients lost to follow-up.

259 However, in the first power analysis, we had considered 10% of patients potentially lost to follow-up.
260 And the post-hoc power analysis showed a sufficient power. Finally, the observer was not blinded but
261 was independent. The difference between cemented and uncemented is systematically known with the
262 radiographs. Despite these limitations, this study presented some strengths. It is a randomized design
263 using a sufficient number of knees investigated at a long follow-up period. The implants were identical
264 except for the femoral fixation. Two experienced surgeons performed all TKAs using the same surgical
265 technique.

266

267 **Conclusion**

268 No significant difference was reported for the survival rate and the rate of femoral loosening between
269 cemented TKA and hybrid TKA at a minimum follow-up of 10 years. The clinical outcomes were also
270 similar between both groups. Hybrid fixation appears to be a safe alternative to cemented fixation in
271 TKA.

272

273 **Figures**

274 Figure 1.

275 Flowchart of this prospective series of TKA.

276

277 Figure 2.

278 International Knee Society zone assignment of the femoral component, on a profile view radiography.

279

280 Figure 3.

281 Last follow-up lateral radiographs showing bone transparencies after implantation of an uncemented
282 femoral component.

283

284 Figure 4.

285 Last follow-up lateral radiographs showing radiolucent lines on cemented femoral component zone 1-2-
286 3-4

INITIAL COHORT	Cement Group n=65 knees	Hybrid Group n=65 knees	p-value
Age (years) (mean ±SD) [Min; Max]	72 ±8.5 [54 ; 85]	72.5 ±7.3 [52 ; 85]	n.s.
BMI (kg/m2) (mean ±SD) [Min; Max]	29 ±5.2 [20.5 ; 40.5]	28.4 ±3.9 [20.5 ; 39.7]	n.s.
Side (Right)	33 (50.8%)	36 (55.4%)	n.s.
Gender (Female)	53 (81.5%)	45 (69.2%)	n.s.
ANALYZED COHORT	Cement group n=59 knees	Hybrid group n=59 knees	p-value
Age (years) (mean ±SD) [Min; Max]	72.2 ±8.3 [54 ; 85]	72.3 ±7.9 [52 ; 85]	n.s.
BMI (kg/m2) (mean ±SD) [Min; Max]	29 ±4.6 [20.5 ; 40.5]	28 ±3.8 [20.5 ; 39.7]	n.s.
Side (Right)	25 (42.4%)	25 (42.4%)	n.s.
Gender (Female)	46 (80%)	40 (67.8%)	n.s.
Etiology (Nb)			n.s.
Osteoarthritis	56 (94.9%)	58 (98.3%)	
Chondrocalcinosis	3 (5.1%)	1 (1.7%)	
Osteoarthritis stage			
1	1 (1.7%)	1 (1.7%)	
2	11 (17%)	11 (17%)	n.s.
3	40 (67.8%)	33 (55.9%)	
4	7 (11.9%)	14 (23.7%)	

292 Table 2.

293 Clinical outcomes preoperatively and postoperatively in both groups (cemented and hybrid TKA).

	Cement Group	Hybrid Group	p-value
	n = 59 knees	n = 59 knees	
Preoperative knee score	48.9 ±15.9	49.3 ±17.8	n.s.
(mean ±SD) [Min; Max]	[14 ; 90]	[23 ; 97]	
Postoperative knee score	89.7 ±8.5	90.7 ±9.2	n.s.
(mean ±SD) [Min; Max]	[60 ; 100]	[50 ; 100]	
Preoperative function score	53.4 ±19.2	56.9 ±19.7	n.s.
(mean ±SD) [Min; Max]	[5 ; 90]	[20 ; 100]	
Postoperative function score	79.9 ±14.5	80.7 ±15.8	n.s.
(mean ±SD) [Min; Max]	[45 ; 100]	[45 ; 100]	
Preoperative IKS global score	102 ±30.2	105.6 ±31.5	n.s.
(mean ±SD) [Min; Max]	[25 ; 180]	[44 ; 175]	
Postoperative IKS global score	169.6 ±18.2	171.3 ±17.5	n.s.
(mean ±SD) [Min; Max]	[124 ; 200]	[100 ; 200]	
Preoperative flexion (°)	120.4 ±14.4	119.4 ±13.9	n.s.
(mean ±SD) [Min; Max]	[85 ; 140]	[80 ; 140]	
Postoperative flexion (°)	117.7 ±12.1	120.4 ±11.6	n.s.
(mean ±SD) [Min; Max]	[90 ; 140]	[85 ; 140]	

294 *IKS: International Knee Society; SD : Standard Deviation ; Min : Minimum ; Max : Maximum ; n.s. : non-significant.*

295

296

297

298

299

300

301

302

303 Table 3.

304 Radiological results in both groups (cemented and hybrid TKA)

RLL radiolucent lines	Cement Group	Hybrid Group	p-value
	n = 59 knees	n = 59 knees	
Preoperative HKA (°)	176.2 ±6.7	176.7 ±7.5	ns
(mean ±SD) [Min; Max]	[164 ; 196]	[164 ; 192]	
Postoperative HKA (°)	179.4 ±4	180 ±3.3	ns
(mean ±SD) [Min; Max]	[177 ; 184]	[177 ; 183]	
Incidence of RLL	15	1	<0.05
RLL zone 1	9	1	<0.05
RLL zone 2	5	0	<0.05
RLL zone 3	2	1	ns
RLL zone 4	11	1	<0.05
RLL progressive	3	1	<0.05
Bone transparencies	6	17	<0.05

305 *HKA: Hip Knee Ankle angle ; RLL : Radiolucent Line; SD : Standard Deviation ; Min : Minimum ; Max : Maximum ; n.s. : non-*
306 *significant.*

307 **References**

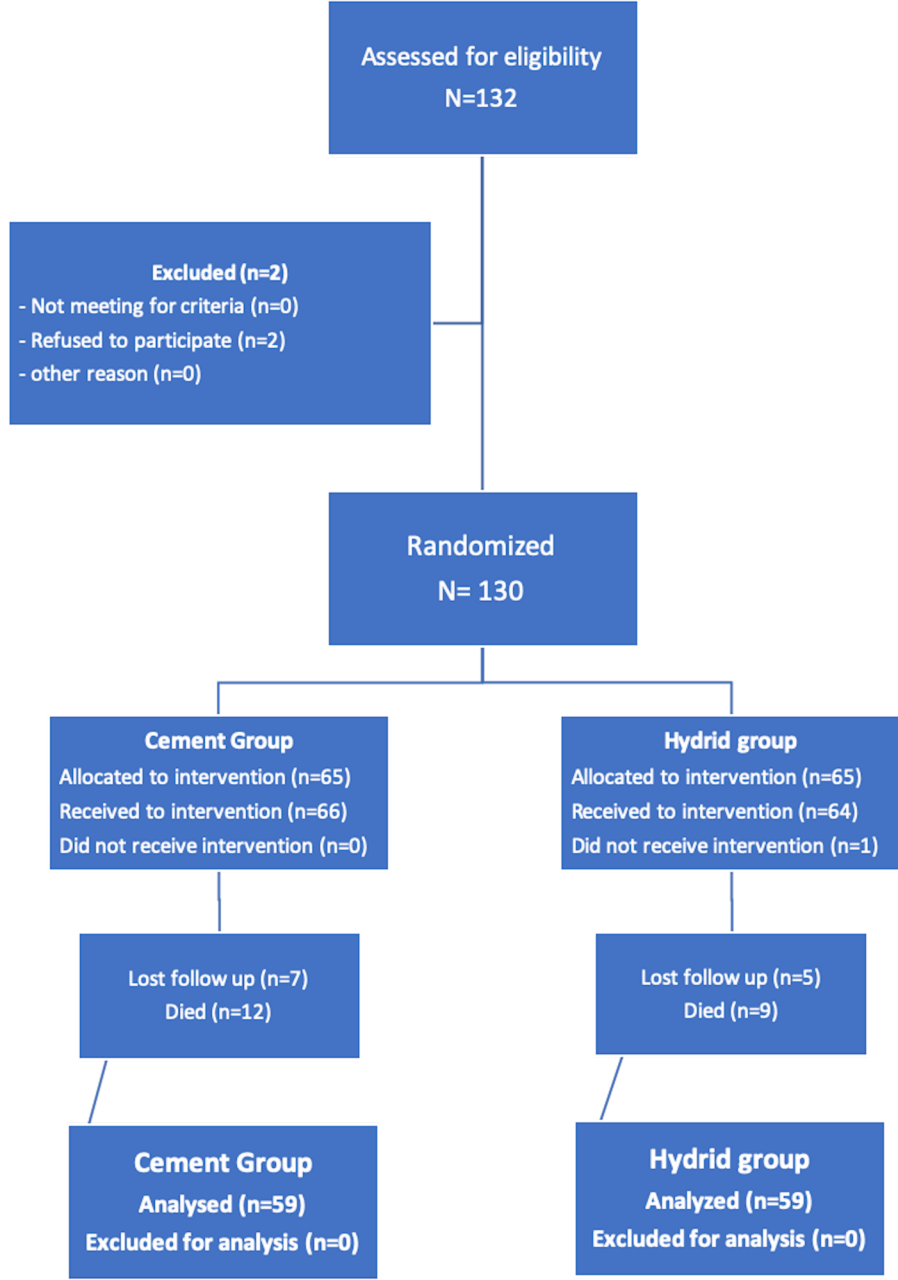
308

- 309 1. van der Waal JM, Terwee CB, van der Windt DA, Bouter LM, Dekker J. The impact of non-
310 traumatic hip and knee disorders on health-related quality of life as measured with the SF-36 or SF-12. A
311 systematic review. *Qual Life Res.* 2005;14(4):1141-1155.
- 312 2. Nugent M, Wyatt MC, Frampton CM, Hooper GJ. Despite Improved Survivorship of Uncemented
313 Fixation in Total Knee Arthroplasty for Osteoarthritis, Cemented Fixation Remains the Gold Standard: An
314 Analysis of a National Joint Registry. *J Arthroplasty.* 2019. Doi:10.1016/j.arth.2019.03.047.
- 315 3. Dixon MC, Brown RR, Parsch D, Scott RD. Modular fixed-bearing total knee arthroplasty with
316 retention of the posterior cruciate ligament. A study of patients followed for a minimum of fifteen years. *J*
317 *Bone Joint Surg Am.* 2005;87(3):598-603. Doi:10.2106/JBJS.C.00591.
- 318 4. Font-Rodriguez DE, Scuderi GR, Insall JN. Survivorship of cemented total knee arthroplasty. *Clin*
319 *Orthop Relat Res.* 1997(345):79-86.
- 320 5. Metsovitis SR, Ploumis AL, Chantzidis PT et al. Rotaglide total knee arthroplasty: a long-term
321 follow-up study. *J Bone Joint Surg Am.* 2011;93(9):878-884. Doi:10.2106/JBJS.I.01702.
- 322 6. Lewis G. Properties of acrylic bone cement: state of the art review. *J Biomed Mater Res.*
323 1997;38(2):155-182. Doi:10.1002/(sici)1097-4636(199722)38:2<155::aid-jbm10>3.0.co;2-c.
- 324 7. Mjoberg B, Selvik G, Hansson LI, Rosenqvist R, Onnerfalt R. Mechanical loosening of total hip
325 prostheses. A radiographic and roentgen stereophotogrammetric study. *J Bone Joint Surg Br.*
326 1986;68(5):770-774.
- 327 8. Mjoberg B. Loosening of the cemented hip prosthesis. The importance of heat injury. *Acta Orthop*
328 *Scand Suppl.* 1986;2211-40.
- 329 9. Sturup J, Nimb L, Kramhoft M, Jensen JS. Effects of polymerization heat and monomers from
330 acrylic cement on canine bone. *Acta Orthop Scand.* 1994;65(1):20-23. Doi:10.3109/17453679408993711.
- 331 10. Gandhi R, Tsvetkov D, Davey JR, Mahomed NN. Survival and clinical function of cemented and
332 uncemented prostheses in total knee replacement: a meta-analysis. *J Bone Joint Surg Br.* 2009;91(7):889-
333 895. Doi:10.1302/0301-620X.91B7.21702.
- 334 11. Duffy GP, Berry DJ, Rand JA. Cement versus cementless fixation in total knee arthroplasty. *Clin*
335 *Orthop Relat Res.* 1998(356):66-72.
- 336 12. Berger RA, Lyon JH, Jacobs JJ et al. Problems with cementless total knee arthroplasty at 11 years
337 followup. *Clin Orthop Relat Res.* 2001(392):196-207. Doi:10.1097/00003086-200111000-00024.
- 338 13. Collins DN, Heim SA, Nelson CL, Smith P, 3rd. Porous-coated anatomic total knee arthroplasty. A
339 prospective analysis comparing cemented and cementless fixation. *Clin Orthop Relat Res.* 1991(267):128-
340 136.
- 341 14. Gill GS, Joshi AB. Long-term results of Kinematic Condylar knee replacement. An analysis of 404

- 342 knees. *J Bone Joint Surg Br.* 2001;83(3):355-358.
- 343 15. Hofmann AA, Evanich JD, Ferguson RP, Camargo MP. Ten- to 14-year clinical followup of the
344 cementless Natural Knee system. *Clin Orthop Relat Res.* 2001(388):85-94.
- 345 16. Ritter MA, Meneghini RM. Twenty-year survivorship of cementless anatomic graduated
346 component total knee arthroplasty. *J Arthroplasty.* 2010;25(4):507-513. Doi:10.1016/j.arth.2009.04.018.
- 347 17. Carlsson A, Bjorkman A, Besjakov J, Onsten I. Cemented tibial component fixation performs better
348 than cementless fixation: a randomized radiostereometric study comparing porous-coated, hydroxyapatite-
349 coated and cemented tibial components over 5 years. *Acta Orthop.* 2005;76(3):362-369.
- 350 18. van Hamersveld KT, Marang-van de Mheen PJ, Tsonaka R, Valstar ER, Toksvig-Larsen S.
351 Fixation and clinical outcome of uncemented peri-apatite-coated versus cemented total knee arthroplasty :
352 five-year follow-up of a randomised controlled trial using radiostereometric analysis (RSA). *Bone Joint J.*
353 2017;99-B(11):1467-1476. Doi:10.1302/0301-620X.99B11.BJJ-2016-1347.R3.
- 354 19. Matassi F, Carulli C, Civinini R, Innocenti M. Cemented versus cementless fixation in total knee
355 arthroplasty. *Joints.* 2013;1(3):121-125.
- 356 20. Duffy GP, Murray BE, Trousdale RR. Hybrid total knee arthroplasty analysis of component
357 failures at an average of 15 years. *J Arthroplasty.* 2007;22(8):1112-1115. Doi:10.1016/j.arth.2007.04.007.
- 358 21. Demey G, Servien E, Lustig S, Ait Si Selmi T, Neyret P. Cemented versus uncemented femoral
359 components in total knee arthroplasty. *Knee Surg Sports Traumatol Arthrosc.* 2011;19(7):1053-1059.
360 Doi:10.1007/s00167-010-1347-2.
- 361 22. Demey G, Servien E, Pinaroli A, Lustig S, Ait Si Selmi T, Neyret P. The influence of femoral
362 cementing on perioperative blood loss in total knee arthroplasty: a prospective randomized study. *J Bone*
363 *Joint Surg Am.* 2010;92(3):536-541. Doi:10.2106/JBJS.H.01159.
- 364 23. Tayot O, Ait Si Selmi T, Neyret P. Results at 11.5 years of a series of 376 posterior stabilized
365 HLS1 total knee replacements. Survivorship analysis, and risk factors for failure. *Knee.* 2001;8(3):195-
366 205.
- 367 24. Insall JN, Dorr LD, Scott RD, Scott WN. Rationale of the Knee Society clinical rating system. *Clin*
368 *Orthop Relat Res.* 1989(248):13-14.
- 369 25. Ewald FC. The Knee Society total knee arthroplasty roentgenographic evaluation and scoring
370 system. *Clin Orthop Relat Res.* 1989(248):9-12.
- 371 26. Lee WC, Kwan YH, Chong HC, Yeo SJ. The minimal clinically important difference for Knee
372 Society Clinical Rating System after total knee arthroplasty for primary osteoarthritis. *Knee Surg Sports*
373 *Traumatol Arthrosc.* 2017;25(11):3354-3359. Doi:10.1007/s00167-016-4208-9.
- 374 27. Lingard EA, Katz JN, Wright RJ, Wright EA, Sledge CB, Kinemax Outcomes G. Validity and
375 responsiveness of the Knee Society Clinical Rating System in comparison with the SF-36 and WOMAC. *J*
376 *Bone Joint Surg Am.* 2001;83(12):1856-1864. Doi:10.2106/00004623-200112000-00014.
- 377 28. Iosifidis M, Iliopoulos E, Neofytou D et al. The Rotaglide mobile-bearing total knee arthroplasty:

- 378 no difference between cemented and hybrid implantation. *Knee Surg Sports Traumatol Arthrosc.*
379 2014;22(8):1843-1848. Doi:10.1007/s00167-013-2829-9.
- 380 29. Boyle KK, Nodzo SR, Ferraro JT, Augenblick DJ, Pavlesen S, Phillips MJ. Uncemented vs
381 Cemented Cruciate Retaining Total Knee Arthroplasty in Patients With Body Mass Index Greater Than 30.
382 *J Arthroplasty.* 2018;33(4):1082-1088. Doi:10.1016/j.arth.2017.11.043.
- 383 30. van der List JP, Sheng DL, Kleeblad LJ, Chawla H, Pearle AD. Outcomes of cementless
384 unicompartmental and total knee arthroplasty: A systematic review. *Knee.* 2017;24(3):497-507.
385 Doi:10.1016/j.knee.2016.10.010.
- 386 31. Petursson G, Fenstad AM, Havelin LI et al. Better survival of hybrid total knee arthroplasty
387 compared to cemented arthroplasty. *Acta Orthop.* 2015;86(6):714-720.
388 Doi:10.3109/17453674.2015.1073539.
- 389 32. Baker PN, Khaw FM, Kirk LM, Esler CN, Gregg PJ. A randomised controlled trial of cemented
390 versus cementless press-fit condylar total knee replacement: 15-year survival analysis. *J Bone Joint Surg*
391 *Br.* 2007;89(12):1608-1614. Doi:10.1302/0301-620X.89B12.19363.
- 392 33. Park JW, Kim YH. Simultaneous cemented and cementless total knee replacement in the same
393 patients: a prospective comparison of long-term outcomes using an identical design of NexGen prosthesis.
394 *J Bone Joint Surg Br.* 2011;93(11):1479-1486. Doi:10.1302/0301-620X.93B11.27507.
- 395 34. Perry CR, Perry KI. Femoral Component Survival in Hybrid Total Knee Arthroplasty. *Orthopedics.*
396 2016;39(3):181-186. Doi:10.3928/01477447-20160427-05.
- 397 35. McLaughlin JR, Lee KR. Hybrid total knee arthroplasty: 10- to 16-year follow-up. *Orthopedics.*
398 2014;37(11):e975-977. Doi:10.3928/01477447-20141023-53.
- 399 36. Chockalingam S, Scott G. The outcome of cemented vs. cementless fixation of a femoral
400 component in total knee replacement (TKR) with the identification of radiological signs for the prediction
401 of failure. *Knee.* 2000;7(4):233-238.
- 402 37. Hartford JM, Hunt T, Kaufer H. Low contact stress mobile bearing total knee arthroplasty: results
403 at 5 to 13 years. *J Arthroplasty.* 2001;16(8):977-983. Doi:10.1054/arth.2001.27670.
- 404 38. Campbell MD, Duffy GP, Trousdale RT. Femoral component failure in hybrid total knee
405 arthroplasty. *Clin Orthop Relat Res.* 1998(356):58-65.
- 406 39. Henricson A, Wojtowicz R, Nilsson KG, Crnalic S. Uncemented or cemented femoral components
407 work equally well in total knee arthroplasty. *Knee Surg Sports Traumatol Arthrosc.* 2019;27(4):1251-1258.
408 Doi:10.1007/s00167-018-5227-5.
- 409 40. Khaw FM, Kirk LM, Morris RW, Gregg PJ. A randomised, controlled trial of cemented versus
410 cementless press-fit condylar total knee replacement. Ten-year survival analysis. *J Bone Joint Surg Br.*
411 2002;84(5):658-666.
- 412 41. Bouras T, Bitas V, Fennema P, Korovessis P. Good long-term results following cementless TKA
413 with a titanium plasma coating. *Knee Surg Sports Traumatol Arthrosc.* 2017;25(9):2801-2808.
414 Doi:10.1007/s00167-015-3769-3.

- 415 42. Illgen R, Tueting J, Enright T, Schreiber K, McBeath A, Heiner J. Hybrid total knee arthroplasty:
416 a retrospective analysis of clinical and radiographic outcomes at average 10 years follow-up. *J*
417 *Arthroplasty*. 2004;19(7 Suppl 2):95-100.
- 418 43. Kim YH, Park JW, Lim HM, Park ES. Cementless and cemented total knee arthroplasty in patients
419 younger than fifty five years. Which is better? *Int Orthop*. 2014;38(2):297-303. Doi:10.1007/s00264-013-
420 2243-4.
- 421 44. Epinette JA. Long lasting outcome of hydroxyapatite-coated implants in primary knee arthroplasty:
422 a continuous series of two hundred and seventy total knee arthroplasties at fifteen to twenty two years of
423 clinical follow-up. *Int Orthop*. 2014;38(2):305-311. Doi:10.1007/s00264-013-2246-1.
- 424 45. Uvehammer J, Karrholm J, Carlsson L. Cemented versus hydroxyapatite fixation of the femoral
425 component of the Freeman-Samuelson total knee replacement: a radiostereometric analysis. *J Bone Joint*
426 *Surg Br*. 2007;89(1):39-44. Doi:10.1302/0301-620X.89B1.17974.
- 427 46. Pijls BG, Nieuwenhuijse MJ, Schoones JW, Middeldorp S, Valstar ER, Nelissen RG. RSA
428 prediction of high failure rate for the uncoated Interax TKA confirmed by meta-analysis. *Acta Orthop*.
429 2012;83(2):142-147. Doi:10.3109/17453674.2012.672092.
- 430 47. Liu TK, Yang RS, Chieng PU, Shee BW. Periprosthetic bone mineral density of the distal femur
431 after total knee arthroplasty. *Int Orthop*. 1995;19(6):346-351.
- 432 48. Petersen MM, Nielsen PT, Lauritzen JB, Lund B. Changes in bone mineral density of the proximal
433 tibia after uncemented total knee arthroplasty. A 3-year follow-up of 25 knees. *Acta Orthop Scand*.
434 1995;66(6):513-516.
- 435 49. Akizuki S, Takizawa T, Horiuchi H. Fixation of a hydroxyapatite-tricalcium phosphate-coated
436 cementless knee prosthesis. Clinical and radiographic evaluation seven years after surgery. *J Bone Joint*
437 *Surg Br*. 2003;85(8):1123-1127.
- 438 50. Gao F, Henricson A, Nilsson KG. Cemented versus uncemented fixation of the femoral component
439 of the NexGen CR total knee replacement in patients younger than 60 years: a prospective randomised
440 controlled RSA study. *Knee*. 2009;16(3):200-206. Doi:10.1016/j.knee.2008.11.009.
- 441 51. Pelt CE, Gililand JM, Doble J, Stronach BM, Peters CL. Hybrid total knee arthroplasty revisited:
442 midterm followup of hybrid versus cemented fixation in total knee arthroplasty. *Biomed Res Int*.
443 2013;2013854871. Doi:10.1155/2013/854871.
- 444 52. Bercovy M, Beldame J, Lefebvre B, Duron A. A prospective clinical and radiological study
445 comparing hydroxyapatite-coated with cemented tibial components in total knee replacement. *J Bone Joint*
446 *Surg Br*. 2012;94(4):497-503. Doi:10.1302/0301-620X.94B4.27496.
- 447 53. Ang JE, Bin Abd Razak HR, Howe TS, Tay BK, Yeo SJ. Obesity Does Not Affect Outcomes in
448 Hybrid Versus Cemented Total Knee Arthroplasty in Asians. *J Arthroplasty*. 2017;32(12):3643-3646.
449 Doi:10.1016/j.arth.2017.06.043.
- 450 54. Gaillard R, Lustig S, Peltier A, Villa V, Servien E, Neyret P. Total knee implant posterior stabilised
451 by a third condyle: Design evolution and post-operative complications. *Orthop Traumatol Surg Res*.
452 2016;102(8):1061-1068. Doi:10.1016/j.otsr.2016.08.015.



1

2

5-7

3

4

