



HAL
open science

Partial Patellar Lateral Facetectomy: Arthroscopic Technique

Axel Schmidt, John Swan, Sébastien Lustig, Elvire Servien

► **To cite this version:**

Axel Schmidt, John Swan, Sébastien Lustig, Elvire Servien. Partial Patellar Lateral Facetectomy: Arthroscopic Technique. *Arthroscopy Techniques*, 2020, 9 (7), 6p. <10.1016/j.eats.2020.03.026>. <hal-03136330>

HAL Id: hal-03136330

<https://hal.science/hal-03136330v1>

Submitted on 26 May 2021

HAL is a multi-disciplinary open access archive for the deposit and dissemination of scientific research documents, whether they are published or not. The documents may come from teaching and research institutions in France or abroad, or from public or private research centers.

L'archive ouverte pluridisciplinaire **HAL**, est destinée au dépôt et à la diffusion de documents scientifiques de niveau recherche, publiés ou non, émanant des établissements d'enseignement et de recherche français ou étrangers, des laboratoires publics ou privés.



HAL Authorization

Partial Patellar Lateral Facetectomy: Arthroscopic Technique



Axel Schmidt, M.D., John Swan, M.B.B.S., Sébastien Lustig, M.D., Ph.D., and Elvire Servien, M.D., Ph.D.

Abstract: Lateral patellofemoral osteoarthritis is a relatively common condition in young, active patients. Partial lateral patellar facetectomy is a relatively minimally invasive option to restore knee function and return to sport when conservative treatments are insufficient. We describe the arthroscopic technique of partial lateral patellar facetectomy, which has been historically performed as an open procedure. We describe preoperative planning, arthroscopic portals, landmarks, intra-articular evaluation of bone resection, and surgical difficulties. The goal of the preoperative planning was a target bone resection of 10 to 15 mm including osteophytes and the lateral facet of the patella. Arthroscopic anterolateral and anterior superolateral portals were used to achieve the desired resection. An arthroscopic technique allows a direct view of the osteoarthritic bone for removal and permits intraoperative dynamic evaluation, which allows the surgeon to finetune the bone resection and obtain optimal patellar tracking. Avoiding arthrotomy could reduce morbidity and allows a rapid postoperative rehabilitation.

Patellofemoral osteoarthritis (OA) without coexisting femorotibial pathology is a relatively frequent condition impacting younger and active patients with a prevalence in the general population of 5% to 8%.¹ Anterior knee pain and crepitus are often described as the primary symptoms, frequently exacerbated by ascending or descending stairs and rising from or lowering to a sitting position.² Radiographic investigations quantify the severity of the OA according to the Iwano classification³ and predisposing factors are analyzed, such as trochlear dysplasia, patellar dysplasia, traumatic lesion, abnormal patellar height, or coronal plane malalignment.⁴ In 90% of cases, OA develops in the lateral facet of the patellofemoral joint³ and mainly impacts middle aged adults between 40 and 65 years old.

Initially, conservative treatment is trialed with nonsteroidal anti-inflammatory medication, bracing, physical therapy,⁵ hyaluronic acid injection, and intra-articular corticosteroid injection.⁶ When medical management is ineffective, or in cases of severe OA, surgical options are proposed. Surgical interventions can include more aggressive options for older patients including patellofemoral arthroplasty^{7,8} and total knee arthroplasty with associated patellar resurfacing.⁷ Less-aggressive procedures are preferred for younger patients, such as arthroscopic debridement, lateral retinacular release and partial lateral patellar facetectomy.⁹ Partial lateral patellar facetectomy is classically described in the literature as an open surgery and has good results¹⁰⁻¹³ without impacting a potential secondary patellar resurfacing at the time of arthroplasty.

From the FIFA Medical Center of Excellence, Orthopaedics Surgery and Sports Medicine Department, Croix-Rousse Hospital, Hospices Civils de Lyon (A.S., J.S., S.L., E.S.); Univ Lyon, Claude Bernard Lyon 1 University, IFSTTAR, LBMC UMR_T9406 (S.L.); and LIBM – EA 7424, Interuniversity Laboratory of Biology of Mobility, Claude Bernard Lyon 1 University (E.S.), Lyon, France.

The authors report the following potential conflicts of interest or sources of funding: S.L. reports consultancy for Smith & Nephew, Groupe Lepine, Stryker, Medacta, and DePuy; institutional from Amplitude and Corin; and editorial board of Knee Surgery, Sports Traumatology, Arthroscopy, Orthopaedics & Traumatology: Surgery & Research, and Maitrise Orthopédique, outside the submitted work. Full ICMJE author disclosure forms are available for this article online, as [supplementary material](#).

Received January 22, 2020; accepted March 29, 2020.

Address correspondence to Axel Schmidt, M.D., FIFA Medical Center of Excellence, Orthopaedics Surgery and Sports Medicine Department, Croix-Rousse Hospital, Hospices Civils de Lyon, 103 grande rue de la Croix Rousse, 69004 Lyon, France. E-mail: axel.schmidt0310@gmail.com

© 2020 by the Arthroscopy Association of North America. Published by Elsevier. This is an open access article under the CC BY-NC-ND license (<http://creativecommons.org/licenses/by-nc-nd/4.0/>).

2212-6287/20113

<https://doi.org/10.1016/j.eats.2020.03.026>

Indications for partial lateral patellar facetectomy include symptomatic isolated lateral patellofemoral OA in active and young patients not suitable for prosthetic surgery, with bone deformation of the patella and an overhanging lateral facet/osteophyte leading to an impingement with the trochlea,¹⁴ in isolated or associated with other procedures.¹⁰ Through this, we describe an arthroscopic technique of partial lateral patellar facetectomy: arthroscopic portals, surgical equipment, preoperative planning, bone resection, and technical difficulties.

Surgical Technique (With Video Illustration)

Patient Positioning

The patient is positioned supine with the knee in extension to provide maximal excursion of patellofemoral joint (Fig 1, Video 1). A high thigh tourniquet is inflated.

Arthroscopic Portals and Diagnostic Evaluation

Through a standard anterolateral portal, a diagnostic knee arthroscopy is performed using a 30° arthroscope with intra-articular exploration. Impingement between the trochlea and the lateral patellar facet is observed during a dynamic examination throughout knee range of motion and the severity of the OA is quantified. To avoid any patellofemoral joint alterations during dynamic evaluation, the arthroscopic exploration is commenced without any liquid in the knee. Patellar tracking with the knee distended by the irrigation fluid may not accurately represent in vivo patellofemoral kinematics. Next, an anterior superolateral portal (ASLP) is established using transillumination of the skin with the arthroscope light and a percutaneous needle for localization (Fig 2, Video 1).

Defining the Bone Resection and Performing the Osteotomy

The first step consists of synovial debridement using an arthroscopic shaver (Fig 3, Video 1) via the ASLP to expose the patella and define the lateral border. Next, the osteotomy area was delineated with a radiofrequency probe according to preoperative planning and intraoperative observation of dynamic patellar tracking. The goal of the preoperative planning was a target bone resection of 10 to 15 mm including osteophytes and the lateral facet of the patella (Fig 4) to restore normal patellar anatomy and reduce intraosseous pressure due to patellofemoral impingement.

The best landmarks for the osteotomy are the pathological cartilage and the measurement from the lateral border of the patella. Dynamic landmarks are evaluated initially during knee exploration and can be useful: during flexion–extension range of motion, patellar

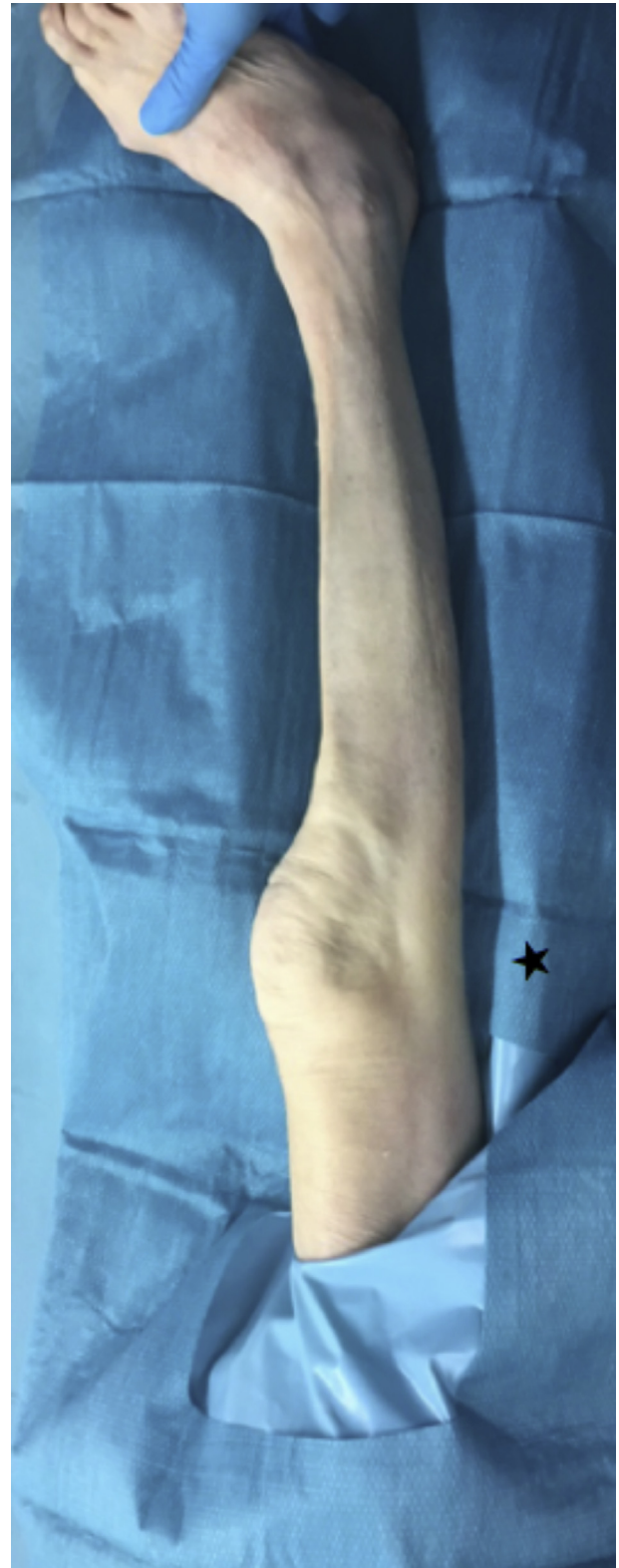


Fig 1. Leg position of a right knee in extension close to the edge of the table (star).

course, and engagement in the trochlea are observed and then the impinging portion of the lateral patellar facet can be resected.

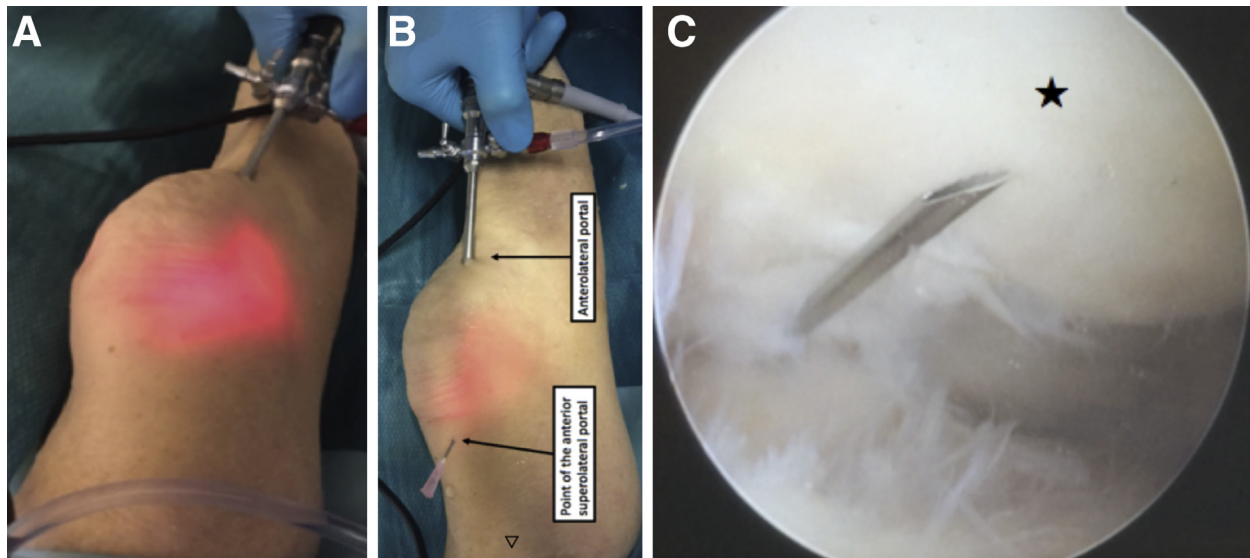


Fig 2. ASLP location with transillumination on a right knee (A and B). The superior part of the body is in the left side of the picture (\triangleleft). Intra-articular view via the anterolateral portal (C). The needle simulates the future localization of the arthroscopic ASLP portal and the position of the instruments towards the patella (star). The lateral side of the knee is to the left side of the picture. (ASLP, anterior superolateral portal.)

The bone resection is performed using a 4-mm or 5.5-mm arthroscopic motorized burr (Acromioblaster Burr; Smith & Nephew, Andover, MA) placed through the ASLP while the arthroscope is placed in the anterolateral portal allowing direct visual control of the bone resection (Fig 5, Video 1). The bone resection is started from the superior portion of the patella, working distally, and from the cartilage working anteriorly towards the cortex. The size of the burr is adapted to the size of the patella. A 5.5-mm burr is commonly used, but for small patella a smaller burr (4 mm) is preferred.

Switching between arthroscopic portals with the arthroscope and instruments is required to have good access to the superior and inferior portions of the lateral

patellar facet in order to assure equal bone resection (Figs 6 and 7). The pearls and pitfalls of this technique are summarized in Table 1.

Evaluation of the Bone Resection and Completion of the Procedure

Dynamic evaluation of the patellar tracking during knee flexion allowing visualization of residual impingement and control the patellar tracking (Fig 8). At the conclusion of the procedure, a lavage of the joint, especially in the condylar ramps, is necessary to remove all bone debris secondary to the resection (Table 1). A thorough hemostasis is performed with a radio-frequency device and the skin portals are sutured

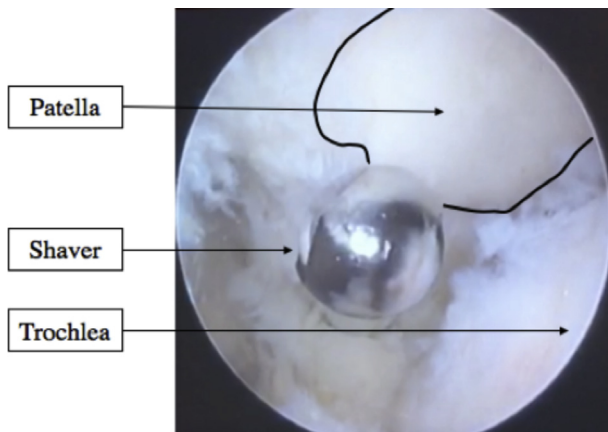


Fig 3. Exposure of the lateral edge of the patella by synovial debridement using a shaver. The shaver is positioned in the anterior superolateral portal and the scope in the anterolateral portal for a right knee. The lateral side of the knee is the left side of the picture.

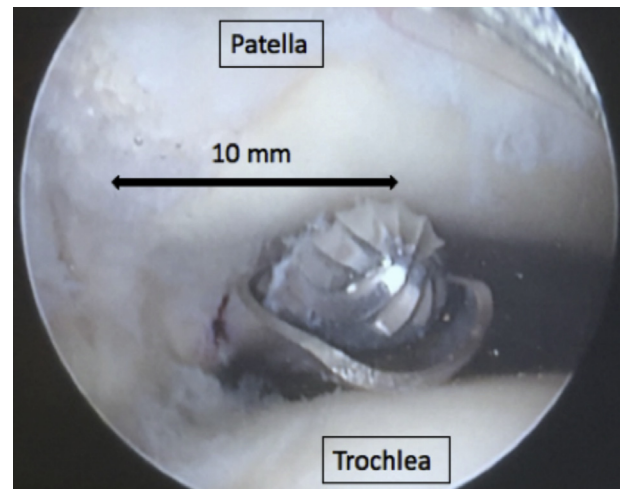


Fig 4. Sizing of the bone resection of the patella with the burr in the anterior superolateral portal. The scope is in the anterolateral portal (right knee).




Fig 5. Shown are 4-mm and 5.5-mm arthroscopic motorized burrs (Acromioblaster Burr; Smith & Nephew).

closed. A compression bandage is used to limit hematomarthrosis.

Postoperative Rehabilitation

This procedure can be performed as a day-surgical case. No postoperative drainage is required. Full weight-bearing and walking with 2 crutches are immediately allowed. Physiotherapy commences in the first postoperative days and should be gentle, slow, and gradual to avoid any pain. It consists of isometric quadriceps contractions, patellar motion, and maintaining full range of motion without limits to prevent joint stiffness. A splint is recommended for 2 to 3 days to allow complete recovery of quadriceps muscle control. It is not recommended to avoid walking up or down inclines and kneeling during the initial 2 months. We encourage spinning on a bicycle without resistance from the second postoperative month and return to normal sporting activity from the fourth postoperative month.

Discussion

The potential advantages of the arthroscopic partial lateral patellar facetectomy compared with the open procedure are less morbidity, less pain, less blood loss, and earlier knee mobilization; however, this needs to be shown in clinical studies.^{14,15} Furthermore, arthroscopic intraoperative dynamic evaluation permits the surgeon to fine tune the quantity of lateral facet bone resection, increasing the accuracy of the osteotomy. Other advantages include the ability for complete diagnostic arthroscopy and the opportunity to treat associated intra-articular knee pathology during the same surgery.

Few surgical difficulties were identified. For patients with a high body mass index, instruments placed through the ASLP were constrained by the larger soft-tissue envelope and made resection of the anterior patella challenging. In addition, resection of the anterior patellar cortex could be difficult as a result of patellar morphology and physical limitations of the burr. In some cases, there could be a persistent thin wafer of cortical bone, like an “eggshell.” To limit iatrogenic risk, the surgeon should proceed with caution when using the burr to prevent chondral lesions on the trochlea and patella and to preserve the lateral patellar retinaculum. The advantages and disadvantages of this procedures are summarized in [Table 2](#).

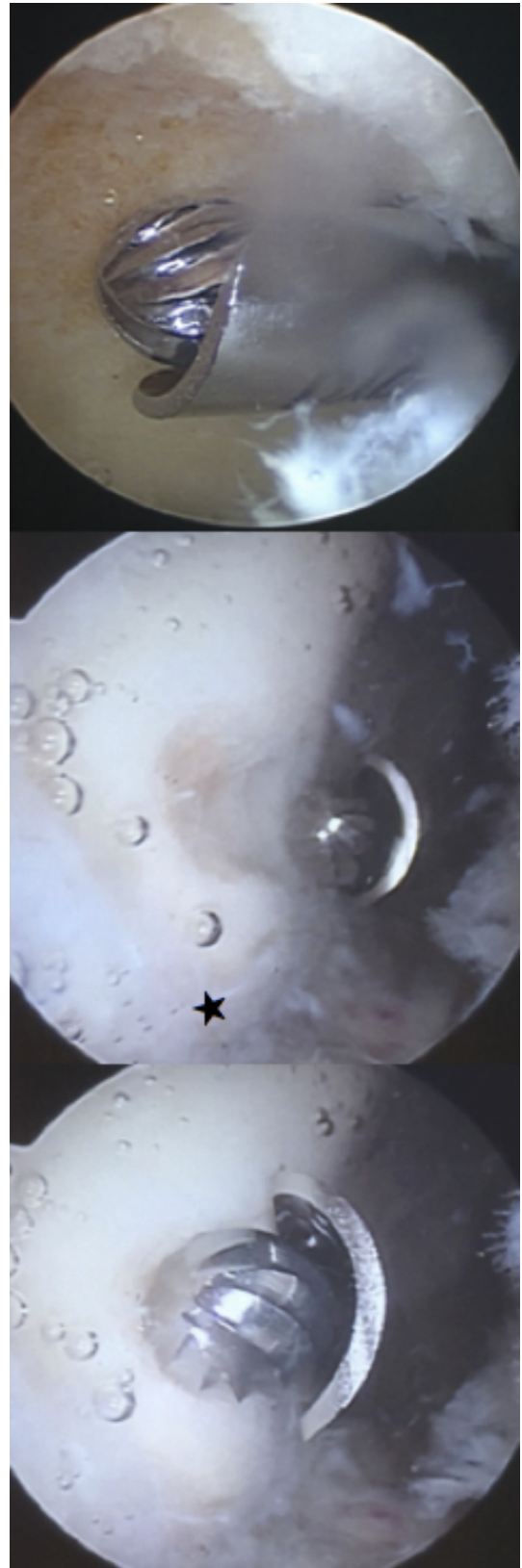


Fig 6. Commencing the bone resection with the burr at the medial limit of the osteotomy and working towards the lateral border (star). The burr is placed through the anterior superolateral portal and the scope in the anterolateral portal (right knee). The lateral side of the knee is the left side of the picture.

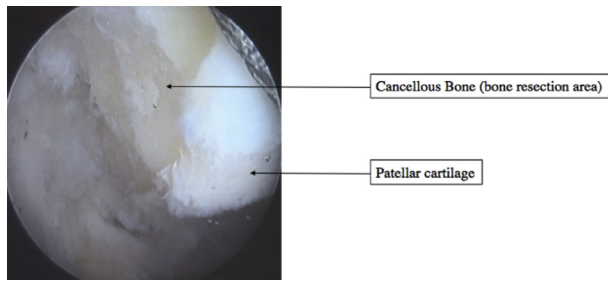


Fig 7. Arthroscopic view of the bone resection from the anterolateral portal. View from the inferior aspect of the patella (right knee).

Ferrari et al.¹⁶ recommend an arthroscopic lateral patellar facetectomy for the treatment of isolated patellofemoral OA in patients with an overhanging lateral facet of the patella and anterior knee pain. They insist on dynamic assessment to ensure that normal bony contact has been restored. Unlike our technique, they use anteromedial and anterolateral arthroscopic portals only, similar to the technique used by Wu et al.¹⁴ When using our technique, an additional anteromedial portal could be useful for patients with a high body mass index to avoid impingement between the arthroscopic burr handle and the patient's thigh.

This technique resembles arthroscopic resection for painful bipartite patella after failed conservative medical treatment.^{17,18}

Additional indications for arthroscopic lateral patellar facetectomy could be treatment of residual or recurrent osteophytes¹⁹ or patellofemoral impingement in patients post-total knee arthroplasty (TKA) with patellar resurfacing, presenting with excessive lateral patellar tilt.²⁰ Furthermore, arthroscopic lateral patellar facetectomy could be used in the setting of painful lateral patellofemoral OA after TKA without prosthetic patella resurfacing to treat impingement between the lateral facet and the femoral implant.²¹ As evidenced by these 3 studies,^{19,21,22} lateral patellar facetectomy in patients post-TKA has been shown to improve patellar tilt and lateral patellar displacement for both resurfaced and nonresurfaced patellae. Performing the procedure arthroscopically would be less invasive with a




Fig 8. Dynamic evaluation at the end of the procedure to control the bone resection and the patellar tracking during knee flexion. View from the inferior aspect of the patella (right knee).

Table 1. Pearls and Pitfalls of Arthroscopic Partial Lateral Patellar Facetectomy

Pearls	Pitfalls
Less morbidity:	For patients with a high BMI:
<ul style="list-style-type: none"> The vastus lateralis and lateral patellar retinaculum insertions are preserved due to resection being performed from the articular side. Early postoperative rehabilitation with full range of motion and quadriceps function recovery. 	<ul style="list-style-type: none"> Instruments placed through the ASLP were constrained by the larger soft-tissue envelope Resection of the anterior patellar cortex is challenging, and in some cases, there can be a persistent thin wafer of cortical bone.
Arthroscopic intraoperative dynamic evaluation:	Under-resection of the lateral facet leading to persistent patella-trochlear impingement and residual anterior knee pain.
<ul style="list-style-type: none"> Confirm patella-trochlear impingement due to the overhanging lateral patellar facet. Finetune the quantity of lateral facet bone resection Increasing the accuracy of the osteotomy. Ensure that normal patellofemoral articulation has been restored 	Insufficient lavage of the joint at the end of the procedure could leave bone debris secondary to the resection

ASLP, anterior superolateral portal; BMI, body mass index.

potentially lower infection risk compared with the traditional open approach, but in vivo studies will be necessary to validate the long-term clinical outcomes and to further refine the indications.

Table 2. Advantages and Disadvantages of Arthroscopic Partial Lateral Patellar Facetectomy

Advantages	Disadvantages
Less invasive with preservation of peripatellar tissues, leading to a potentially faster recovery	Iatrogenic risk when using the burr: <ul style="list-style-type: none"> Chondral lesions on the trochlea and patella. Patella maltracking due to over-resection of the patella or unintentional release of the lateral patellar retinaculum.
Arthroscopic intraoperative dynamic evaluation allows adaptation of the bone resection	The arthroscopic technique is technically more challenging than the open surgical technique
Complete intra-articular diagnostic:	
<ul style="list-style-type: none"> Treat associated intra-articular knee pathology (meniscal tears, chondral flaps, loose bodies) during the same surgery. 	

Conclusions

The advantages of this arthroscopic technique include its minimally invasive nature, the opportunity to perform a diagnostic evaluation, and to treat any concurrent intra-articular pathology. In addition, arthroscopically performing the lateral patellar facetectomy improves the accuracy of the bone resection, as the intra-articular view allows for dynamic examination of the patellofemoral joint.

References

- Davies AP, Vince AS, Shepstone L, Donell ST, Glasgow MM. The radiologic prevalence of patellofemoral osteoarthritis. *Clin Orthop* 2002;(402):206-212.
- Schiphof D, van Middelkoop M, de Klerk BM, et al. Crepitus is a first indication of patellofemoral osteoarthritis (and not of tibiofemoral osteoarthritis). *Osteoarthritis Cartilage* 2014;22:631-638.
- Iwano T, Kurosawa H, Tokuyama H, Hoshikawa Y. Roentgenographic and clinical findings of patellofemoral osteoarthrosis. With special reference to its relationship to femorotibial osteoarthrosis and etiologic factors. *Clin Orthop* 1990;(252):190-197.
- Arendt EA, Dejour D. Patella instability: building bridges across the ocean a historic review. *Knee Surg Sports Traumatol Arthrosc* 2013;21:279-293.
- Crossley K, Bennell K, Green S, Cowan S, McConnell J. Physical therapy for patellofemoral pain: A randomized, double-blinded, placebo-controlled trial. *Am J Sports Med* 2002;30:857-865.
- Arroll B, Goodyear-Smith F. Corticosteroid injections for osteoarthritis of the knee: Meta-analysis. *BMJ* 2004;328:869.
- van Jonbergen H-PW, Poolman RW, van Kampen A. Isolated patellofemoral osteoarthritis. *Acta Orthop* 2010;81:199-205.
- Rodriguez-Merchan EC. Surgical treatment of isolated patellofemoral osteoarthritis. *HSS J* 2014;10:79-82.
- Bonnin M, Amendola NA, Bellemans J, MacDonald SJ, Menetrey J. *The Knee joint: surgical techniques and strategies*. Paris: Springer-Verlag Paris, 2013.
- Paulos LE, O'Connor DL, Karistinos A. Partial lateral patellar facetectomy for treatment of arthritis due to lateral patellar compression syndrome. *Arthroscopy* 2008;24:547-553.
- Becker R, Röpke M, Krull A, Musahl V, Nebelung W. Surgical treatment of isolated patellofemoral osteoarthritis. *Clin Orthop* 2008;466:443-449.
- Yercan HS, Ait Si Selmi T, Neyret P. The treatment of patellofemoral osteoarthritis with partial lateral facetectomy. *Clin Orthop* 2005;436:14-19.
- Wetzels T, Bellemans J. Patellofemoral osteoarthritis treated by partial lateral facetectomy: Results at long-term follow up. *Knee* 2012;19:411-415.
- Wu T, Tang S, Wang F. Treatment for lateral patellar impingement syndrome with arthroscopic lateral patellectomy: A bidirectional cohort study. *J Orthop Surg* 2017;12:173.
- Zhao G, Liu Y, Yuan B, et al. Arthroscopic patellectomy and circumpatellar denervation for the treatment of patellofemoral osteoarthritis. *Chin Med J (Engl)* 2015;128:79-84.
- Ferrari MB, Sanchez G, Chahla J, Moatshe G, LaPrade RF. Arthroscopic patellar lateral facetectomy. *Arthrosc Tech* 2017;6:e357-e362.
- Azarbod P, Agar G, Patel V. Arthroscopic excision of a painful bipartite patella fragment. *Arthroscopy* 2005;21:1006.e1-1006.e3.
- James E, LaPrade C, Chahla J, Cinque M, Kennedy N, LaPrade R. Arthroscopic excision of bipartite patella with preservation of lateral retinaculum in an adolescent ice hockey player. *Am J Orthop* 2017;46:135-138.
- Moghtadaei M, Sajadi MRM, Farahini H, Yeganeh A. Osteophytes removal in patella versus lateral facetectomy of the patella in patella-retaining total knee arthroplasty. *Interv Med Appl Sci* 2017;9:15-19.
- Cercek R, Jacofsky D, Kieffer K, Larsen B, Jacofsky M. Lateral patellofemoral impingement: A cause of treatable pain after TKA. *J Knee Surg* 2011;24:181-184.
- Pagenstert G, Seelhoff J, Henninger HB, Wirtz DC, Valderrabano V, Barg A. Lateral patellar facetectomy and medial reefing in patients with lateral facet syndrome after patellar-retaining total knee arthroplasty. *J Arthroplasty* 2014;29:2156-2162.
- Kim C-W, Lee C-R, Seo S-S, Gwak H-C, Kim J-H, Park J-H. Clinical and radiologic outcomes of partial lateral patellar facetectomy in total knee arthroplasty. *J Knee Surg* 2017;30:185-192.