



**HAL**  
open science

## Early outcomes of native and graft-related abdominal aortic infection managed with orthotopic xenopericardial grafts

William Alonso, Baris Ozdemir, Lucien Chassin-Trubert, Vicent Ziza, Pierre Alric, Ludovic Canaud

### ► To cite this version:

William Alonso, Baris Ozdemir, Lucien Chassin-Trubert, Vicent Ziza, Pierre Alric, et al.. Early outcomes of native and graft-related abdominal aortic infection managed with orthotopic xenopericardial grafts. *Journal of Vascular Surgery*, 2021, 73 (1), pp.222-231. 10.1016/j.jvs.2020.04.513 . hal-03130046

**HAL Id: hal-03130046**

**<https://hal.science/hal-03130046>**

Submitted on 15 Nov 2022

**HAL** is a multi-disciplinary open access archive for the deposit and dissemination of scientific research documents, whether they are published or not. The documents may come from teaching and research institutions in France or abroad, or from public or private research centers.

L'archive ouverte pluridisciplinaire **HAL**, est destinée au dépôt et à la diffusion de documents scientifiques de niveau recherche, publiés ou non, émanant des établissements d'enseignement et de recherche français ou étrangers, des laboratoires publics ou privés.

# Early outcomes of native and graft-related abdominal aortic infection managed with orthotopic xenopericardial grafts

William Alonso, MD, Baris Ozdemir, FRCS, PhD, Lucien Chassin-Trubert, MD, Vicent Ziza, MD, Pierre Alric, MD, PhD, and Ludovic Canaud, MD, PhD, *Montpellier, France*

## ABSTRACT

**Objective:** Reconstruction of infected aortic cases has shifted from extra-anatomic to in situ. This study reports the surgical strategy and early outcomes of abdominal aortic reconstruction in both native and graft-related aortic infection with in situ xenopericardial grafts.

**Methods:** Included in the analysis are 21 consecutive patients (mean age, 69 years; 20 male) who underwent abdominal xenopericardial in situ reconstruction of native aortic infection (4) and endovascular (4) or open (13) graft aortic infection between July 2017 and September 2019. All repairs were performed on an urgent basis, but none were ruptured. All patients were followed up with clinical and biologic evaluation, ultrasound at 3 months, and computed tomography scan at 6 months and 1 year.

**Results:** Technical success was 100%; 8 patients were treated with xenopericardial tubes and 13 with bifurcated grafts. Thirty-day mortality was 4.7% (one death due to pneumonia with respiratory hypoxic failure in critical care.). Six patients (28%) developed acute kidney injury, four (19%) requiring temporary dialysis; five fully recovered and one died. Four patients (19%) required a return to the operating room. After a median follow-up of 14 months (range, 1-26 months), overall mortality was 19% (n = 4). Two patients presented with recurrent sepsis after reconstruction, leading to death due to multiorgan failure. Other patients (17/21) have discontinued antibiotics with no evidence of recurrence of infection clinically, radiologically, or on blood tests. Computed tomography scans at 1 year demonstrated no stenosis or graft dilation and one asymptomatic left graft branch thrombosis. Primary patency is 95%.

**Conclusions:** In situ xenopericardial aortic reconstruction is a safe and effective management strategy for both native and graft-related abdominal aortic infection with good short-term results. The graft demonstrates appropriate resistance to infection such that reliable eradication of infection in this vascular bed is possible. Longer follow-up is required in future studies to determine the durability of the reconstruction and need for reinterventions.

**Keywords:** Native aortic infection; Graft aortic infection; Xenopericardial graft; Aorta

Native or graft-related infection of the aorta remains one of the most difficult challenges for vascular surgical teams. The choice of reconstruction after complete removal of infected foreign material and tissue as part of an extensive debridement remains controversial. Whereas extra-anatomic grafts were considered state of the art some decades ago, in situ reconstruction, with its superior patency, is clearly favored today.<sup>1</sup> In situ replacement with a standard graft, rifampicin-bonded or silver-coated Dacron graft, autologous femoral vein, and cryopreserved homograft, each combined with

aggressive systemic antibiotic therapy, has been widely used. Although revascularization with extra-anatomic bypass grafting has a similar long-term survival rate, because of the higher postoperative complication rate, it should be considered only in patients who are unsuited for in situ grafts.<sup>2</sup>

Biologic substitutes are superior to prosthetic grafts because of their resistance to reinfection.<sup>3</sup> Although the cryopreserved arterial homograft is good material for the treatment of infected aortas, supply is often inadequate, and it can be difficult to obtain in sufficient time for an urgent operation.<sup>4</sup> Autologous femoral vein has good characteristics, but the time-consuming process of harvest adds to the duration and morbidity of a procedure in already fragile patients. In the emergent setting, even assessment of the patency and suitability of the deep veins can be challenging.<sup>5</sup> Because of its finite availability, orthotopic reconstruction with femoral vein is often not possible in patients requiring more extensive reconstructions.

Bovine or equine pericardium is well established in cardiac surgery for coverage of surgical pericardial and congenital atrial septal defects and as a component of

---

From the Department of Thoracic and Vascular Surgery, Hôpital A de Villeneuve.

Author conflict of interest: none.

Correspondence: William Alonso, MD, Service de Chirurgie Vasculaire et Thoracique, Hôpital A de Villeneuve, 191 av Doyen Gaston Giraud, 34090 Montpellier, France (e-mail: [william-alonso@hotmail.com](mailto:william-alonso@hotmail.com)).

biologic heart valves. In studies with long follow-up, bovine pericardium has been shown to perform well in infected ascending aorta replacement and in endocarditis, with 80% freedom from reinfection reported at 5 and 10 years.<sup>6</sup>

As a readily available off-the-shelf solution that can be tailored to form a straight or bifurcated conduit, xenopericardium is attractive graft material. Reports to date regarding its resistance to reinfection are promising.<sup>7-10</sup>

The aim of this study was to detail our technical approach and outcomes in the treatment of native and graft-related abdominal aortic infection managed with orthotopic xenopericardial grafts.

## METHODS

**Patients.** Between July 2017 and September 2019, patients with native and graft-related abdominal aortic infection who underwent abdominal aortic replacement with xenopericardial grafts were included in the study. Ruptured infected aortas were excluded. A retrospective analysis was performed using a prospectively maintained database.

Written informed consent was obtained from all patients before the procedure. The Institutional Review Board and ethics commission approved this study.

**Diagnosis of infection.** The Management of Aortic Graft Infection Collaboration (MAGIC) criteria were used to diagnose graft infections.<sup>11</sup> There is no consensus on the diagnosis or indeed the nomenclature of native infected aortic aneurysms.<sup>12</sup> Native aortic infections were therefore diagnosed by a constellation of clinical findings, blood testing, and imaging. Although, strictly speaking, the MAGIC criteria were agreed on to diagnose aortic graft infection, for completeness we have also reported the MAGIC criteria present in the four patients with mycotic infections. All patients in the study had intraoperative signs of infection, such as suppuration, secretion, or intestinal fistula.

For all patients, serial leukocyte count, C-reactive protein serum level, and serum calcitonin level were sampled. Computed tomography (CT) was used in all patients, and this was supplemented by fluorodeoxyglucose positron emission tomography in eight.

**Surgical procedure.** From the clinical assessment, any available notes, and imaging, the type and extent of required reconstruction were planned. In particular, based on the patient's anatomy, preoperative decisions were made regarding whether the reconstruction would be with a tube or bifurcated graft, graft lengths, diameters of the proximal and distal anastomoses, and required clamp sites.

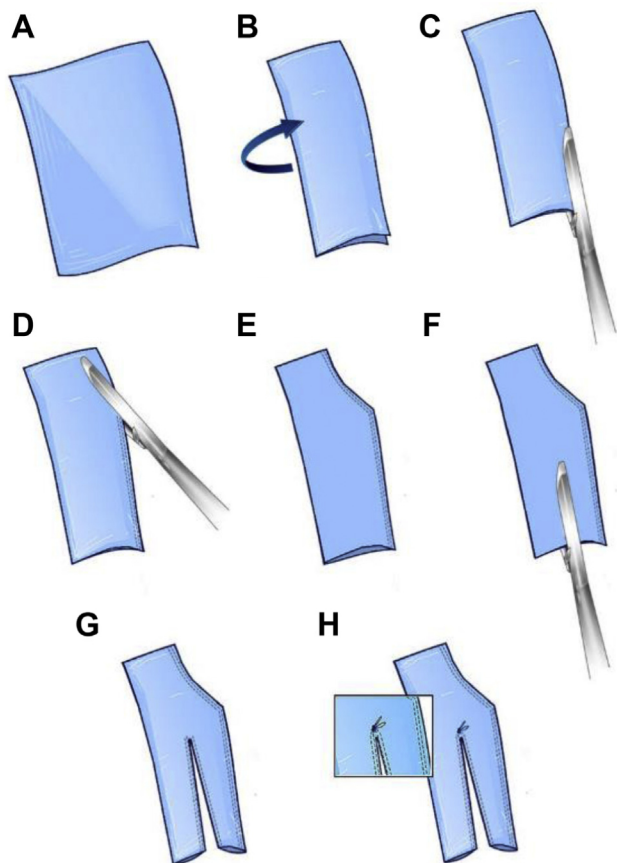
Construction of the xenopericardial graft (10 × 16 cm XenoSure Biological Patch; LeMaitre Vascular, Burlington, Mass) was performed on a back table, commencing

- **Type of Research:** Single-center, retrospective cohort study
- **Key Findings:** In situ xenopericardial aortic reconstruction for abdominal aortic infection in 21 patients resulted in 4.7% 30-day mortality, 19% overall mortality, and 95% primary patency with a median follow-up of 14 months.
- **Take Home Message:** Combined with debridement and an appropriately long course of antibiotics, in situ xenopericardial aortic reconstruction is a safe and effective management strategy for both native and graft-related abdominal aortic infection with good short-term results.

before the start of anesthesia. The procedure for graft construction is illustrated in Fig 1. Each patch was constructed on the basis of the required anatomy from measurements made from the preoperative CT image. Stapling of the patch to form tubes was performed with a 60-mm vascular Endo GIA Tri-Staple (Medtronic, Minneapolis, Minn). The proximal and distal staple rows could be angled to decrease the diameter of the graft at these points. Bifurcated grafts were constructed by adding an additional staple line to the distal tube to form limbs (Fig 1). If needed, additional tubular segments were sutured to the main graft as required (4-0 polypropylene; Fig 2). Sealing was tested with heparinized saline solution. The construction of the graft was completed between 10 and 30 minutes, depending on complexity.

All procedures were transperitoneal using a midline laparotomy. A standardized systematic surgical approach was used for all patients. Technical success was defined as complete graft removal and successful vessel reconstruction, with no perioperative death.

**Clamp placement.** For native aortic infection, the location of proximal and distal clamp sites was dependent on the extent of the aneurysm, but the strategy was to have a low threshold for suprarenal clamping. For infected open grafts, both supraceliac and suprarenal clamp sites were prepared. In general, only the suprarenal clamp was used for proximal control. The distal clamp site was determined by the level of any previous repair. In patients with infected endografts with suprarenal fixation, both supraceliac and suprarenal clamp sites were prepared. The initial clamp was applied to the supraceliac location, the endograft was disconnected, and the clamp site was moved to the suprarenal location. If a patient presented with only infrarenal fixation, only a suprarenal clamp site was prepared and used. Distal control was initially by clamping the limbs of the endograft after opening the aortic sac. After removal of



**Fig 1.** Construction of the xenopericardial graft. **A**, Bovine pericardial patch (10 × 16 cm). **B**, The patch is folded in two. **C**, The open margin is stapled shut with a vascular stapler. **D**, The diameter of the proximal anastomosis is adjusted by angling the stapler. **E**, Final xenopericardial tube graft. **F** and **G**, If a bifurcated graft is required, this can be constructed by dividing the distal three-quarters of the tube graft to form limbs. **H**, The neo-aortic bifurcation is reinforced with a 4-0 polypropylene suture. After testing for leaks, any additional reinforcing sutures are placed as required.

the proximal parts of the graft, occlusion balloons were used through the graft limbs. The graft limbs were disconnected and then cut off the occlusion balloon shafts.

The extensive debridement of all foreign material (complete graft removal) and macroscopically infected tissues was performed in stages, immediately after clamping, after the proximal and distal anastomoses. Samples of fluid, aortic tissues, or graft were collected for microscopy, culture, and sensitivities. Copious lavage with saline solution mixed with povidone-iodine flushes with syringe was performed at the end of debridement. Patient 7 with aortoenteric fistula had a duodenal resection and a duodenojejunal anastomosis. Patient 17 with aortosigmoid fistula had a Hartmann procedure.

As a final step, an omental wrap was used to protect the reconstruction by mobilizing a segment off the transverse colon and delivering it through a window created in the transverse mesocolon into the infracolic compartment.

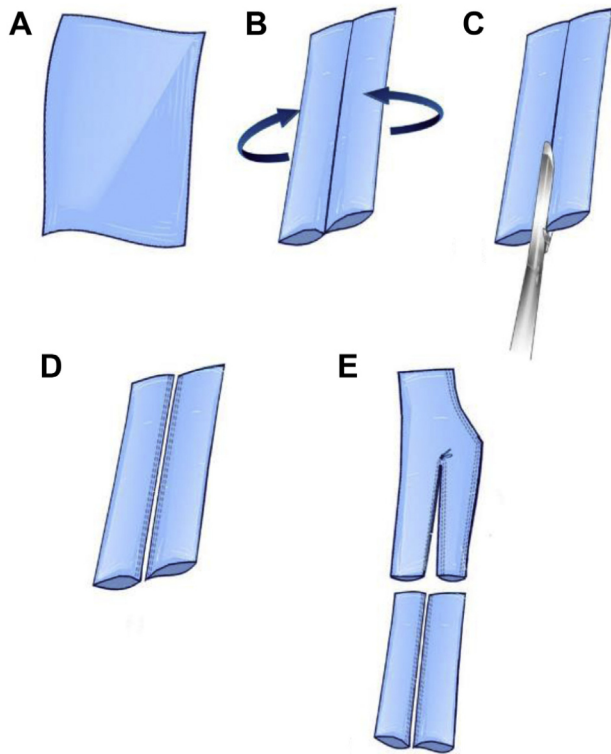
**Antibiotic therapy.** In consultation with our local microbiology department, we followed the guidelines of the French Infectious Diseases Society (Société de Pathologie Infectieuse de Langue Française) for graft and native vascular infections. We switched from broad-spectrum empirical to narrow-spectrum antimicrobials when the causative microorganisms were identified. In culture-negative cases, we continued empirical antibiotic treatment. In all cases of favorable clinical, hematologic (white cell count), and biochemical evolution (C-reactive protein level), antibiotics were stopped at 6 weeks. Otherwise, antibiotic therapy was continued until normalization of both clinical and blood inflammatory markers.

**Follow-up and statistical analysis.** Data were collected prospectively and analyzed retrospectively. Follow-up surveillance was performed routinely by clinical and biologic evaluation, with Doppler ultrasound evaluation at 3 months and serial CT scans at 6 months and 1 year. Outcomes were staged by the Clavien-Dindo classification.<sup>13</sup> Descriptive statistics are provided as means and standard deviations for quantitative variables and numbers or percentages for qualitative variables unless otherwise stated. Overall survival was calculated using the method of Kaplan and Meier. All calculations were performed with SSPS 21.0 software (IBM Corp, Armonk, NY).

## RESULTS

**Patients.** Between July 2017 and September 2019, there were 21 consecutive patients (mean age, 69 ± 8 years; 20 men) with native and graft-related abdominal aortic infection who were treated in our institution. None were ruptured. Four patients had a past history of endovascular abdominal aortic surgery, and 13 patients had a past history of open abdominal aortic surgery with synthetic graft. Four patients had native abdominal aortic infections. Two patients had an aortodigestive fistula (patients 7 and 17). The initial source of infection was clearly a groin wound in three patients (patients 14, 19, and 20). Descriptive characteristics and comorbidities of the population cohort are summarized in [Tables I and II](#).

**Technical success.** Technical success rate was 100%. The mean duration of surgery was 157 minutes (70-310 minutes). Eight patients were treated with tube and 13 with bifurcated grafts ([Figs 3 and 4](#)). All aortic reconstructions were strictly below the renal arteries.



**Fig 2.** Construction of xenopericardial graft for distal iliac or femoral anastomosis. **A**, Bovine pericardial patch (10 × 16 cm). **B**, The patch is folded medially from both sides as shown. **C** and **D**, The midline is stapled with a vascular stapler to form two limbs. **E**, A 5-0 Prolene suture is used to extend the limbs of the bifurcated graft illustrated in Fig 1.

**Perioperative results.** Thirty-day mortality was 4.7% (n = 1); patient 19 died in critical care of pneumonia with respiratory hypoxic failure. Six patients (28%) had a postoperative acute kidney injury, of whom four (19%) needed dialysis (Clavien-Dindo grade IVa); five fully recovered and one died.

The median hospital stay was 20 days (range, 8-70 days), and the median time in critical hospital care was 4 days (range, 1-15 days). Operative results and complications are listed for individual patients in Table III.

**Antibiotic therapy.** The median duration of antibiotic therapy was 6 weeks (range, 2-24 weeks). One patient with Q fever was treated with hydroxychloroquine and doxycycline for 6 months. Cultures were negative in only three patients, all of whom had been established on antibiotic therapy before referral to our unit. Microbiologic findings are listed in Table II. All patients have discontinued antibiotics, and freedom from reinfection rate is 100% at latest follow-up in all surviving patients. Antibiotic therapy for individual patients is listed in Table III.

**Table I.** Patients' demographics and comorbidities

Total patients	N = 21
Age, years, mean	68.9
Male	20 (95)
Comorbidities	
Smoking history	14 (67)
Diabetes	5 (24)
Hypertension	18 (85)
Dyslipidemia	9 (42)
Ischemic heart disease	4 (19)
Cerebrovascular disease	2 (9)
Chronic obstructive pulmonary disease	2 (17)
Renal impairment (eGFR <60 mL/min)	1 (5)
American Society of Anesthesiologists class	
1	0
2	3 (14)
3	12 (58)
4	6 (28)
eGFR, Estimated glomerular filtration rate. Values are reported as number (%).	

**Follow-up.** The median follow up period was 14 months (range, 1-26 months). Overall mortality was 19% (n = 4). The Kaplan-Meier curve of survival is shown in Fig 5.

Four patients (19%) had Clavien-Dindo grade IIIb complications; all developed out of the hospital, beyond 30 days, and required readmission to the hospital. These reinterventions under general anesthesia included patch rupture repaired directly, false aneurysm distal anastomosis repaired directly, treatment of abdominal wound dehiscence, and periprosthetic fluid evacuation. Late complications and follow-up are detailed in Table III.

Patient 8 presented with signs of recurrent sepsis 3 months after reconstruction, with fever and high serial leukocyte count and C-reactive protein serum level. CT scan identified periprosthetic fluid and gas. We reintroduced triple antibiotic therapy and waited for general medical improvement. Two weeks after the onset of symptoms, hemorrhagic shock developed as a result of a ruptured false aneurysm in the main graft segment at the staple line, culminating in emergency surgery. The false aneurysm was repaired directly, and bacteriologic samples were sent for analysis. Based on the results of these specimens, antibiotics were switched to narrow spectrum for 4 weeks. One month subsequently, all clinical symptoms and signs of infection were absent. Blood markers had normalized. The xenopericardial graft was relined with a bifurcated endograft for reinforcement. At 9 months, the patient presented again with signs of reinfection, with endocarditis, leading to death.

**Table II.** Preoperative details of individual cases

Case No.	Age, years	Sex	Initial indication	Previous aortic surgery	MAGIC criteria
1	84	Male	Aortic aneurysm	Aortobi-iliac endograft	3 major, 2 minor
2	71	Male	Native aortic infection	N/A	2 major, 4 minor
3	66	Male	Native aortic infection	N/A	3 major, 4 minor
4	74	Male	Aortic aneurysm	Aortobifemoral bypass	1 major, 4 minor
5	71	Female	Iliac aneurysms	Aortobifemoral bypass	3 major, 4 minor
6	75	Male	Occlusive disease	Aortobifemoral bypass	5 major, 3 minor
7	64	Male	Occlusive disease	Aortobifemoral bypass	3 major, 3 minor
8	65	Male	Aortic aneurysm	Aortobi-iliac endograft	5 major, 4 minor
9	72	Male	Aortic aneurysm	Aortobi-iliac bypass	3 major, 4 minor
10	65	Male	Aortic aneurysm	Aortobi-iliac bypass	5 major, 3 minor
11	64	Male	Occlusive disease	Aortobifemoral bypass	4 major, 4 minor
12	60	Male	Aortoiliac aneurysms	Aortobifemoral bypass	5 major, 4 minor
13	63	Male	Native aortic infection	N/A	5 major, 4 minor
14	83	Male	Occlusive disease	Femorofemoral bypass	5 major, 2 minor
15	71	Male	Aortic aneurysm	Aortoaortic bypass	5 major, 2 minor
16	63	Male	Aortic aneurysm	Aortobi-iliac endograft	3 major, 3 minor
17	70	Male	Aortic aneurysm	Aortobi-iliac endograft	3 major, 3 minor
18	67	Male	Native aortic infection	N/A	2 major, 4 minor
19	73	Male	Aortic aneurysm	Aortobifemoral bypass	5 major, 4 minor
20	58	Male	Aortic aneurysm	Aortobifemoral bypass	5 major, 3 minor
21	57	Male	Occlusive disease	Aortobifemoral bypass	5 major, 2 minor

MAGIC, Management of Aortic Graft Infection Collaboration; N/A, not applicable; PET/CT, positron emission tomography/computed tomography.

At 2 months, a symptomatic false aneurysm of a distal iliac anastomosis (pain and anemia) developed in patient 12, without any clinical signs of infection and negative microbiology results. Endovascular exclusion with a Viabahn (W. L. Gore & Associates, Flagstaff, Ariz) endograft combined with surgical evacuation of the hematoma was performed. At 5 months, the Viabahn endograft was manifesting signs of reinfection. The endograft was explanted and reconstructed with a femorofemoral arterial allograft. The patient died in critical care of multiorgan failure.

Patient 9 died 5 months after the aortic replacement, consequent to a retroperitoneal sarcoma, with no curative possibility.

The primary patency rate is 95% (20/21). Patient 6 has an asymptomatic left graft limb thrombosis. Follow-up imaging (ultrasound at 3 months, CT scans at 6 months and 1 year) has revealed no stenosis or dilation of the xenopericardial grafts during the follow-up period (Table III).

## DISCUSSION

This series of patients contributes to the limited number of publications that include the early outcomes of patients undergoing abdominal aortic reconstruction with xenopericardial grafts for graft or native infection.<sup>14</sup> A systematic approach is detailed with excellent perioperative and short-term results. There was one perioperative death, excellent graft durability, and only two deaths due to reinfections in the follow-up to date. Of the four previous articles studying xenopericardial graft use in infected aortic diseases (including ascending, arch, and thoracoabdominal aortic surgery), the 30-day mortality in the abdominal subgroups was 16% (5/31).<sup>7-10</sup>

The established management of infected aortic grafts has been explantation and extensive debridement followed by extra-anatomic bypass. There has been a clear shift toward in situ reconstruction principally to reduce the rate of limb thrombosis,<sup>3,4</sup> although the reinfection

**Table II.** Continued.

PET/CT	Time to infection, months	Antibiotics before surgery	Microorganisms from cultures
Not performed	27	Ceftriaxone + gentamicin, 3 days	<i>Streptococcus haemolyticus</i> C
Not performed	N/A	Amoxicillin + metronidazole, 2 days	<i>Salmonella</i> spp
+	N/A	–	<i>Coxiella burnetii</i>
Not performed	25	Daptomycin + rifampicin, 3 days	<i>Klebsiella pneumoniae</i>
+	34	–	Negative cultures
Not performed	3	Tazocin + vancomycin + gentamicin, 3 days	<i>Escherichia coli</i>
+	36	Vancomycin + rifampicin, 3 days	Negative cultures
+	17	Tazocin + vancomycin + amikacin, 3 days	<i>Klebsiella pneumoniae</i>
+	9	Tazocin + daptomycin, 1 week	Negative cultures
+	5	–	<i>Propionibacterium acnes</i>
Not performed	8	–	<i>Staphylococcus aureus</i> , <i>Pseudomonas aeruginosa</i>
Not performed	3	Imipenem + amikacin + daptomycin, 3 days	<i>Escherichia coli</i>
Not performed	N/A	–	<i>Streptococcus equi</i> , <i>Staphylococcus aureus</i> , <i>Candida parapsilosis</i>
Not performed	37	–	<i>Staphylococcus warneri</i> , <i>Proteus hauseri</i>
Not performed	<1	Tazocin + gentamicin, 5 days	<i>Staphylococcus aureus</i> (methicillin sensitive)
Not performed	12	Tazocin + amikacin, 4 days	<i>Staphylococcus aureus</i> (methicillin sensitive)
Not performed	48	Tazocin + amikacin, 7 days	<i>Staphylococcus caprae</i> , <i>Escherichia coli</i> , <i>Citrobacter freundii</i>
+	N/A	Amoxicillin + clarithromycin, 10 days	<i>Campylobacter fetus</i>
+	52	Tazocin + linezolid, 1 month	<i>Staphylococcus aureus</i> (methicillin sensitive)
Not performed	2	Tazocin + gentamicin, 3 days	<i>Staphylococcus aureus</i> (methicillin resistant)
Not performed	120	Tazocin + vancomycin + gentamicin, 6 days	<i>Staphylococcus aureus</i> (methicillin sensitive)

rate and long-term mortality are superior with the in situ techniques.<sup>2</sup> Indeed, the extra-anatomic approach is still recommended by some experienced groups for patients with aortoenteric fistula, virulent gram-negative organisms, or *Candida* because of poor outcomes with in situ reconstruction in this group of patients in previous series.<sup>15,16</sup> We note that xenopericardial reconstruction performed well in a number of patients with these adverse features in our series. However, the two patients (patients 8 and 12) with deterioration or partial failure of the graft (hemorrhage and false aneurysm formation) both had gram-negative infections. Only one of these patients had overt signs of reinfection. Gram-negative infections have correlated with higher rates of reinfection, graft failure, or death in other series of both deep vein and prosthetic but not xenopericardial patch aortic reconstruction.<sup>16,17</sup>

The most suitable graft material for reconstructing infected aorta remains a matter of controversy. Previous management algorithms for aortic infections had to

tailor the reconstructive material and strategy to accommodate the weaknesses of each approach. For example, deep vein and cadaveric artery were not suitable for unstable patients. Both deep vein and prosthetic reconstruction had unsatisfactory outcomes for virulent organisms or those with aortoenteric fistula. Prosthetic reconstruction was in effect limited to low-virulence rifampicin-sensitive organisms. This meant that many patients were confined to extra-anatomic reconstruction, which in addition to the risks associated with extra-anatomic bypass carried a risk of aortic stump blowout.<sup>18</sup>

An alternative strategy in patients with infected grafts with rupture or herald bleeding is endografting as a bridge to definitive explantation and repair at a second sitting. Whereas this is a useful strategy in unstable patients, we do not think that it is indicated in stable patients, particularly as the construction of the xenopericardial patch can be rapidly and synchronously performed. A multicenter European series<sup>19</sup> and a Swedish population-based study<sup>20</sup> suggested that

**Table III.** Intraoperative and postoperative details of individual cases

Case No.	Graft reconstruction	Clamp level	Length of surgery, minutes	Acute kidney injury	Intensive care unit, days
1	Aortic tube	Supraceliac	138	No	4
2	Aortic tube	Infrarenal	70	No	2
3	Aortic tube	Supramesenteric	133	Yes (no dialysis)	2
4	Bifemoral graft	Supraceliac	190	No	3
5	Bifemoral graft	Infrarenal	62	No	1
6	Bifemoral graft	Suprarenal	120	No	2
7	Bifemoral graft	Infrarenal	170	No	2
8	Aortic tube	Suprarenal	123	No	4
9	Bi-iliac graft	Suprarenal	246	No	5
10	Bi-iliac graft	Supraceliac	310	No	3
11	Bifemoral graft	Infrarenal	140	No	1
12	Bifemoral graft	Suprarenal	165	Yes (dialysis)	11
13	Aortic tube	Infrarenal	150	No	2
14	Bifemoral graft	Suprarenal	180	No	1
15	Aortic tube	Suprarenal	70	Yes (no dialysis)	3
16	Aortic tube	Supraceliac	180	Yes (dialysis)	6
17	Bifemoral graft	Suprarenal	190	Yes (dialysis)	10
18	Aortic tube	Infrarenal	110	No	3
19	Bifemoral graft	Infrarenal	240	Yes (dialysis)	15
20	Bifemoral graft	Suprarenal	160	No	1
21	Bifemoral graft	Infrarenal	240	No	4

endovascular aneurysm repair can be used for native aortic infection. In the multicenter study of native aortic infections treated with endovascular aneurysm repair, Sörelius et al<sup>19</sup> reported a total of 33 of 123 (33%) patients with infection-related complications, of whom 23 (19%) died. Twelve patients died within 3 months, 19 within 1 year. Moreover, endografting needs long-duration antibiotics (mean duration of 30 weeks vs 6 weeks in this study), with nine deaths after discontinuation of antibiotic treatment. We would use this approach only in extremely frail patient as the xenopericardial approach offers an off-the-shelf, flexible, quick, low-morbidity strategy that allows in situ reconstruction for most patients.

The principal remaining questions surround the long-term durability of this material for reconstruction in this vascular territory. Previous reports in other vascular territories support excellent resistance to reinfection with a wide variety of organisms and in immunocompromised transplant patients.<sup>21,22</sup> The use of xenopericardial patches in carotid and femoral endarterectomy is now established, with excellent long-term outcomes.<sup>23,24</sup> There have been concerns in the cardiac literature with the long-term durability of specific commercial xenopericardial conduits because of unexpected late failures.<sup>25,26</sup> These devices were preformed valves and conduits, with

a high level of manufacturing complexity, raising doubt about the manufacturing process. Experience with custom-made pericardial tubes combined has been more favorable.<sup>14,27-29</sup> Furthermore, in cases of pericardial patch degradation, such as false aneurysm or stenosis, as we are able to achieve eradication of infection, endovascular therapies represent a relatively safe rescue option.

**Limitations.** The cohort of patients described in this study is small as both native and graft-related aortic infections have a low incidence. In addition, the study also focused exclusively on the treatment of these diseases in the abdominal compartment. This was with the intention of reporting a reproducible management strategy. As follow-up is relatively short, these encouraging results will need to be confirmed in studies reporting long-term outcomes.

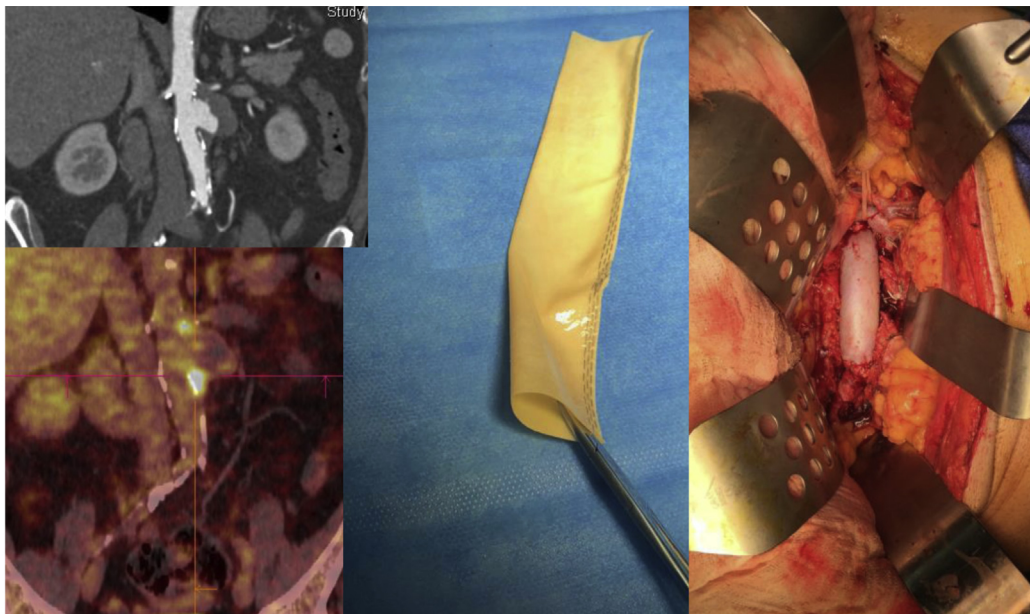
## CONCLUSIONS

Xenopericardial aortic reconstruction combined with a finite long course of antibiotics is a safe and effective management strategy for both native and graft-related abdominal aortic infection. The availability and flexibility of the approach facilitate the in situ reconstruction of patients who would have otherwise been denied it. Longer

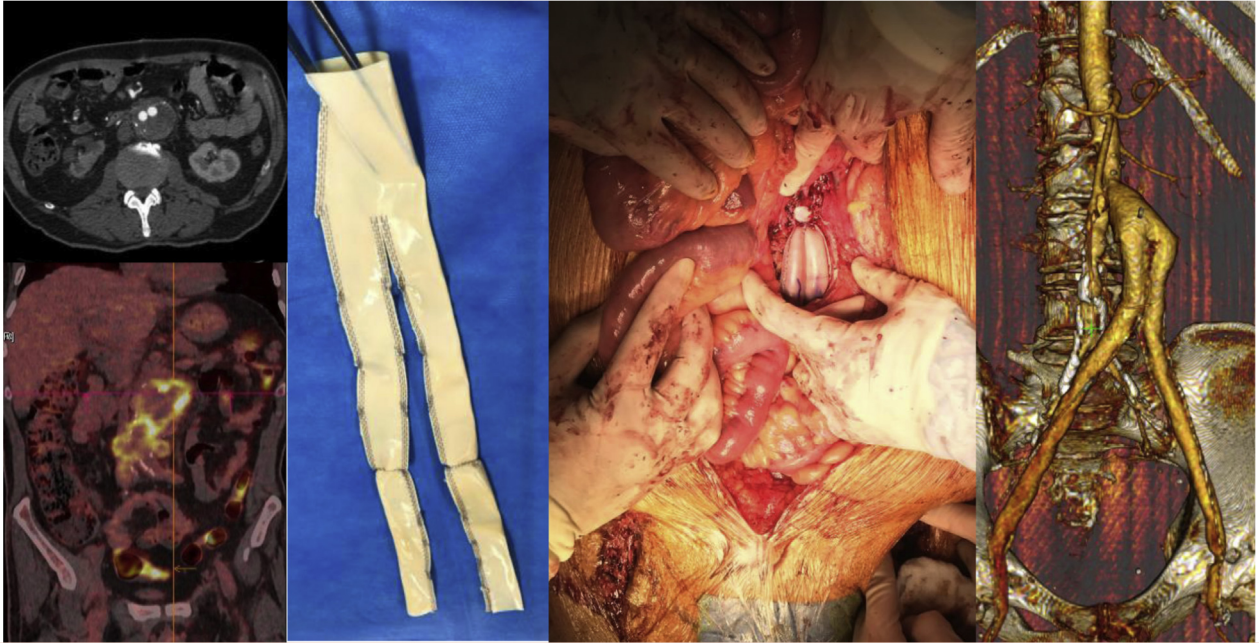


**Table III.** Continued.

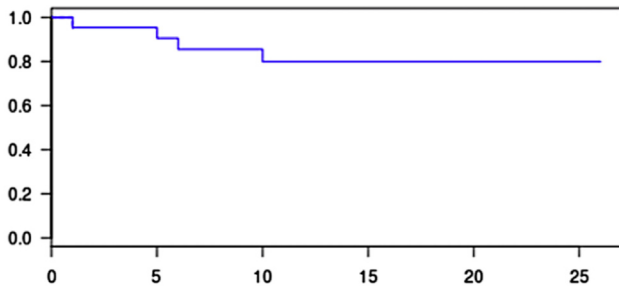
Length of stay, days	Duration of antibiotics	Follow-up, months	Complications	Time at occurrence of complication, months	Status
8	6 weeks	26	0	0	Alive
17	6 weeks	24	Abdominal wound dehiscence	2	Alive
14	6 months	23	0	0	Alive
19	3 weeks	21	0	0	Alive
16	3 weeks	21	0	0	Alive
20	2 weeks	21	Asymptomatic graft limb thrombosis	6	Alive
16	6 weeks	21	0	0	Alive
13	6 weeks	10	Patch rupture repaired directly	3	Dead
41	6 weeks	5	Periprosthetic fluid evacuation	2	Dead
14	6 weeks	17	0	0	Alive
10	4 weeks	17	0	0	Alive
70	6 weeks	6	False aneurysm repaired directly	5	Dead
18	2 weeks	14	0	0	Alive
13	6 weeks	13	0	0	Alive
16	6 weeks	13	0	0	Alive
22	6 weeks	11	0	0	Alive
30	6 weeks	9	0	0	Alive
8	4 weeks	9	0	0	Alive
15	6 weeks	1	Respiratory hypoxic failure	<1	Dead
14	6 weeks	5	0	0	Alive
20	6 weeks	10	0	0	Alive



**Fig 3.** Case 2, native aorta infection with *Salmonella* spp. Computed tomography (CT) angiogram demonstrates a saccular aneurysm, with an abnormality on positron emission tomography/CT. Xenopericardial aortic tube on back table and in situ.



**Fig 4.** Case 11. Aortobifemoral bypass infection with *Staphylococcus aureus* and *Pseudomonas aeruginosa*. Bifurcated xenopericardial graft on back table, in situ, and on follow-up imaging.



Months	1	5	6	10
Number at risk	21	20	19	15
Standard Error	0,046	0,064	0,076	0,09
Survival %	95	90	85	80

**Fig 5.** Kaplan-Meier analysis of survival in patients treated with in situ xenopericardial grafts secondary to native and graft-related abdominal aortic infection.

follow-up is required in future studies to determine the durability of the reconstruction and need for reinterventions.

### AUTHOR CONTRIBUTIONS

Conception and design: WA, BO, LCT, LC  
 Analysis and interpretation: WA  
 Data collection: WA, LCT, VZ, PA, LC  
 Writing the article: WA, BO, LCT, VZ, LC  
 Critical revision of the article: WA, BO, PA, LC  
 Final approval of the article: WA, BO, LCT, VZ, PA, LC  
 Statistical analysis: WA, BO  
 Obtained funding: Not applicable  
 Overall responsibility: WA

### REFERENCES

1. Bandyk DF, Novotney ML, Back MR, Johnson BL, Schmacht DC. Expanded application of in situ replacement for prosthetic graft infection. *J Vasc Surg* 2001;34:411-20.
2. Lee CH, Hsieh HC, Ko PJ, Li HJ, Kao TC, Yu SY. In situ versus extra-anatomic reconstruction for primary infected infrarenal abdominal aortic aneurysms. *J Vasc Surg* 2011;54:64-70.
3. O'Connor S, Andrew P, Batt M, Becquemin JP. A systematic review and meta-analysis of treatment for aortic graft infection. *J Vasc Surg* 2006;44:38-45.
4. Touma J, Cochenec F, Parisot J, Fialaire Legendre A, Becquemin JP, Desgranges P. In situ reconstruction in native and prosthetic aortic infections using cryopreserved arterial allografts. *Eur J Vasc Endovasc Surg* 2014;48:292-9.
5. Neufang A, Savvidis S. Operative technique and morbidity of superficial femoral vein harvest. *Gefasschirurgie* 2016;21(Suppl 2):45-54.
6. Leontyev S, Borger MA, Modi P, Lehmann S, Seeburger J, Doent T, et al. Surgical management of aortic root abscess: a 13-year experience in 172 patients with 100% follow-up. *J Thorac Cardiovasc Surg* 2012;143:332-7.
7. Weiss S, Tobler EL, von Tengg-Kobligh H, Makaloski V, Becker D, Carrel TP, et al. Self made xeno-pericardial aortic tubes to treat native and aortic graft infections. *Eur J Vasc Endovasc Surg* 2017;54:646-52.
8. Lutz B, Reeps C, Biro G, Knappich C, Zimmermann A, Eckstein HH. Bovine pericardium as new technical option for in situ reconstruction of aortic graft infection. *Ann Vasc Surg* 2017;41:118-26.
9. Kubota H, Endo H, Noma M, Ishii H, Tsuchiya H, Yoshimoto A, et al. Xenopericardial roll graft replacement for infectious pseudoaneurysms and graft infections of the aorta. *J Cardiothorac Surg* 2015;10:133.
10. Czerny M, von Allmen R, Opfermann P, Sodeck G, Dick F, Stellmes A, et al. Self-made pericardial tube graft: a new surgical concept for treatment of graft infections after thoracic and abdominal aortic procedures. *Ann Thorac Surg* 2011;92:1657-62.

11. Lyons OT, Baguneid M, Barwick TD, Bell RE, Foster N, Homer-Vanniasinkam S, et al. Diagnosis of aortic graft infection: a case definition by the Management of Aortic Graft Infection Collaboration (MAGIC). *Eur J Vasc Endovasc Surg* 2016;52:758-63.
12. Sörelius K, di Summa PG. On the diagnosis of mycotic aortic aneurysms. *Clin Med Insights Cardiol* 2018;12:117954681875967.
13. Clavien PA, Barkun J, de Oliveira ML, Vauthey JN, Dindo D, Schulick RD, et al. The Clavien-Dindo classification of surgical complications. *Ann Surg* 2009;250:187-96.
14. Hostalrich A, Ozdemir BA, Sfeir J, Solovei L, Alric P, Canaud L, et al. Systematic review of native and graft-related aortic infection outcome managed with orthotopic xenopericardial grafts. *J Vasc Surg* 2019;69:614-8.
15. Back MR. Graft infection. In: Sidway AN, Perler BA, editors. *Rutherford's vascular surgery and endovascular therapy*. 9th ed. Philadelphia: Elsevier; 2019. Chapter 47.
16. Ali AT, Modrall JG, Hocking J, Valentine RJ, Spencer H, Eidt JF, et al. Long-term results of the treatment of aortic graft infection by in situ replacement with femoral popliteal vein grafts. *J Vasc Surg* 2009;50:30-9.
17. Oderich GS, Bower TC, Cherry KJ, Panneton JM, Sullivan TM, Noel AA, et al. Evolution from axillofemoral to in situ prosthetic reconstruction for the treatment of aortic graft infections at a single center. *J Vasc Surg* 2006;43:1166-74.
18. Bacourt F, Koskas F. Axillobifemoral bypass and aortic exclusion for vascular septic lesions: a multicenter retrospective study of 98 cases. *French University Association for Research in Surgery. Ann Vasc Surg* 1992;6:119-26.
19. Sörelius K, Mani K, Björck M, Sediwy P, Wahlgren CM, Taylor P, et al. Endovascular treatment of mycotic aortic aneurysms: a European multicenter study. *Circulation* 2014;130:2136-42.
20. Sorelius K, Wanhainen A, Furebring M, Bjork M, Gillgren P, Mani K. Nationwide study of the treatment of mycotic abdominal aortic aneurysms comparing open and endovascular repair. *Circulation* 2016;134:1822-32.
21. McMillan WD, Leville CD, Hile CN. Bovine pericardial patch repair in infected fields. *J Vasc Surg* 2012;55:1712-5.
22. Garcia Aroz S, Spaggiari M, Jeon H, Oberholzer J, Benedetti E, Tzvetanov I. The use of bovine pericardial patch for vascular reconstruction in infected fields for transplant recipients. *J Vasc Surg Cases Innov Tech* 2017;3:47-9.
23. Kim JH, Cho YP, Kwon TW, Kim H, Kim GE. Ten-year comparative analysis of bovine pericardium and autogenous vein for patch angioplasty in patients undergoing carotid endarterectomy. *Ann Vasc Surg* 2012;26:353-8.
24. Oldenburg WA, Almery T, Selim M, Farres H, Hakaim AG. Durability of carotid endarterectomy with bovine pericardial patch. *Ann Vasc Surg* 2018;50:218-24.
25. Carrel TP, Schoenhoff FS, Schmidli J, Stalder M, Eckstein FS, Englberger L. Deleterious outcome of No-React-treated stentless valved conduits after aortic root replacement: why were warnings ignored? *J Thorac Cardiovasc Surg* 2008;136:52-7.
26. Reineke DC, Kaya A, Heinisch PP, Oezdemir B, Winkler B, Huber C, et al. Long-term follow-up after implantation of the Shelhigh No-React complete biological aortic valved conduit. *Eur J Cardiothorac Surg* 2016;50:98-104.
27. Carrel T, Englberger L, Schmidli J. How to treat aortic graft infection? With a special emphasis on xeno-pericardial aortic tube grafts. *Gen Thorac Cardiovasc Surg* 2019;67:44-52.
28. Kreibich M, Siepe M, Morlock J, Beyersdorf F, Kondov S, Scheumann J, et al. Surgical treatment of native and prosthetic aortic infection with xenopericardial tube grafts. *Ann Thorac Surg* 2018;106:498-504.
29. Amasi-Sperling V, Damaris H, Meyer A, Lang W, Rother U. Treatment of aortic and peripheral prosthetic graft infections with bovine pericardium. *J Vasc Surg* 2020;71:592-8.