



HAL
open science

Lipo-Bodylift Reconstruction Following Massive Weight Loss: Our Experience with 100 Consecutive Cases

Nicolas Bertheuil, Damien Bergeat, Yanis Berkane, Raphael Carloni, Silvia Gandolfi, Jérôme Duisit

► **To cite this version:**

Nicolas Bertheuil, Damien Bergeat, Yanis Berkane, Raphael Carloni, Silvia Gandolfi, et al.. Lipo-Bodylift Reconstruction Following Massive Weight Loss: Our Experience with 100 Consecutive Cases. *Aesthetic Plastic Surgery*, 2021, 45 (5), pp.2220-2228. 10.1007/s00266-020-02118-x . hal-03128713

HAL Id: hal-03128713

<https://hal.science/hal-03128713>

Submitted on 10 Sep 2021

HAL is a multi-disciplinary open access archive for the deposit and dissemination of scientific research documents, whether they are published or not. The documents may come from teaching and research institutions in France or abroad, or from public or private research centers.

L'archive ouverte pluridisciplinaire **HAL**, est destinée au dépôt et à la diffusion de documents scientifiques de niveau recherche, publiés ou non, émanant des établissements d'enseignement et de recherche français ou étrangers, des laboratoires publics ou privés.

Lipo-Bodylift reconstruction following massive weight loss:

Our experience with 100 consecutive cases

Nicolas Bertheuil, MD, PhD^{1,2,3}, Damien Bergeat, MD^{4,5}, Yanis Berkane, MD¹, Raphael Carloni, MD⁶, Silvia Gandolfi, MD⁷, Jérôme Duisit, MD, PhD⁸.

1 - Department of Plastic, Reconstructive and Aesthetic Surgery, Hospital Sud, University of Rennes 1, Rennes, France.

2 - INSERM U1236, University of Rennes 1, Rennes, France.

3 - SITI Laboratory, Rennes University Hospital, Rennes, France.

4 - Department of HPB and Digestive Surgery, CHU Rennes, Pontchaillou Hospital, Rennes, France

5 - Institut NuMeCan (Nutrition Metabolism and Cancer), INSERM 1241, F-35000 Rennes, France

6 - Department of Plastic, Reconstructive and Aesthetic Surgery, Hopital Privé de l'estuaire, Le Havre, France.

7 - Department of Plastic, Reconstructive and Aesthetic Surgery, CHU Rouen, Rouen, France.

8 - Department of Plastic, Reconstructive and Aesthetic Surgery, Cliniques Universitaires Saint-Luc, Brussels, Belgium.

Corresponding author:

Dr Nicolas Bertheuil

Department of Plastic, Reconstructive and Aesthetic Surgery, Hospital Sud, Rennes, France.

16 Boulevard de Bulgarie, 35200, Rennes

Phone: 00 33 2 99 26 71 68

Fax: 00 33 2 99 26 67 18

E-mail: nbertheuil@gmail.com

Financial disclosure and conflicts of interest

The authors received no funding support for the research of this article and declared no potential conflicts of interest with the respect to the research, authorship and/or publication.

Authorship of the manuscript

Nicolas Bertheuil: conception and design of the study/technique, surgeon who operated the 25 patients, interpretation of the data and drafting of the manuscript.

Damien Bergeat: Perform statistical analyses, critically revising the article

Silvia Gandolfi: revising the article

Yanis Berkane: revising the article

Raphael Carloni: revising the article.

Jérôme Duisit: revising the article, final approval of the version to be published.

Lipo-Bodylift reconstruction following massive weight loss:

Our experience with 100 consecutive cases

Abstract

Background

We report our experience using the Lipo-Bodylift technique for circumferential lower trunk reconstruction following massive weight loss.

Methods

The procedure combines extensive circular liposuction with circular skin resection immediately under the dermis. We classify lower trunk deformities using three parameters: (1) excess skin (in the horizontal direction, or both horizontally and vertically); (2) the body mass index (BMI); and, (3) skin quality (hyperlaxity or a normal tone). All patients can be divided into four groups, of whom groups I and II are the best candidates for the Lipo-Bodylift procedure. We also describe our perioperative management and patient outcomes, with a focus on postoperative complications.

Results

Between January 2015 and January 2020, 100 patients underwent Lipo-Bodylift treatment. The median patient age was 41 years. The median preoperative BMI was 26.3 kg/m². The median drainage duration and hospital stay were both 3 days. Of all patients, 30% experienced at least one complication, 2% of which were major. Of the minor complications, 27 patients evidenced wound dehiscence. Only (positive) smoking status was significantly associated with postoperative complications (p<0.001).

Conclusion

We developed the Lipo-Bodylift technique after analyzing changes in the skin and subcutaneous fat after massive weight loss. The technique completes the arsenal of body contouring techniques, appears to be less invasive than the undermining that is usually performed during circumferential reconstruction of the lower trunk, and is associated with a lower rate of major complications.

Evidence Based Medicine Level II: A prospective cohort study.

Introduction

Massive weight loss caused by hygienic-dietetic rebalancing or bariatric surgery is associated with two types of major cutaneous sequelae. First, excess skin may be present in all dimensions; reconstruction affords only a partial response at the cost of significant scarring. Second, the skin may exhibit loss of elasticity and (potentially) extensive skin laxity attributable to metabolic and/or nutritional disorders¹. The latter compromise(s) the outcomes of plastic surgery, which are often difficult to predict and potentially disappointing. No current treatment is available. The goal of plastic surgical management after massive weight loss is reconstruction of a skin envelope that considers the patient's body mass index (BMI); an acceptably reconstructed bodily image improves the quality-of-life. Truncal skin redundancy can be corrected via abdominoplasty; however, excess skin and fat on the flanks, hips, buttocks, and gluteal ptosis cannot thus be corrected. The circular deformation caused by massive weight loss can be fully corrected only via a circular technique termed a lower circumferential body lift. Such major surgery is associated with significant complications², explaining the growing interest in less-invasive techniques that reduce postoperative morbidity and the hospital stay. Here, we describe a procedure that assists patients suffering from weight loss sequelae: the "Lipo-Bodylift". This combines extensive circular liposuction with circular skin resection

immediately below the dermis, as previously described³⁻⁷. We detail our experience with 100 patients.

Patients and Methods

One hundred patients requiring abdominal body-contouring reconstruction following massive weight loss underwent the Lipo-Bodylift procedure performed by the senior author (NB) in the Department of Plastic and Reconstructive Surgery of Rennes University Hospital between January 2015 and January 2020. Patient data were prospectively recorded in a secure database; we noted age, sex, weight, height, pre-bariatric surgery BMI, pre-bodylift BMI, the type and number of bariatric procedure(s), and any medical history. Before performing Lipo-Bodylift, all patients exhibited stable weight for least 6 months after massive weight loss. Smoking cessation 1 month before surgery was strongly advised but not mandatory. We collected the following peroperative data: The anterior and posterior liposuction volumes; the weight of resected skin; the operative duration (min); the American Society of Anesthesiologists (ASA) score; postoperative complications (major and minor); and the duration of hospital stay. Major complications were events occurring within 30 days after surgery that required either surgical revision, hospital re-admission, or a visit to an emergency room. Minor complications were those that could be treated in an outpatient clinic; among these, delayed wound-healing was defined as any scar that required dressing for longer than 15 days postoperatively, without wound dehiscence, which was considered present when an initially closed wound required resumption of dressing care, even if the wound was less than 0.5 cm² in area. The study was approved by the Institutional Review Board of Rennes University Hospital and adhered to all relevant tenets of the Declaration of Helsinki (1964) and the French bioethics laws that came into force on 7 July, 2011.

Patient selection

Patients with certain weight loss sequelae (deformities of the lower trunk) can be classified by reference to three parameters: (1) excess skin (in either the horizontal direction or in both the horizontal and vertical directions); (2) the BMI; and, (3) skin quality (skin hyperlaxity or skin of normal tone). Such patients can be divided into four groups depending on the extent of the lower trunk deformities. Patients of **Type I** exhibit only excessive, very deflated skin of poor tone (thus high-level skin laxity). The BMI is normal, thus $<25 \text{ kg/m}^2$ (**Figures 1 and 2**). **Type II** patients exhibit both significant skin laxity (as do Type I patients) and moderate lipodystrophy. The BMI ranges from that characteristic of overweight to that of type 1 obesity ($<35 \text{ kg/m}^2$) (**Figures 3 and 4**). **Type III** patients exhibit moderate-to-poor skin laxity and moderate-to-major fat excess; the BMI generally ranges up to 35 kg/m^2 . **Type IV** patients include those with a transverse skin excess requiring a “fleur-de-lys” body lift, irrespective of skin laxity status and the BMI. We considered that the optimal Lipo-Bodylift candidates were those of **Types I and II**; **Type III** patients required lower body lifts with traditional undermining⁸; and **Type IV** patients “inverted T” body lifts⁹.

Patients with any history of prior abdominal surgery (other than bariatric surgery) were treated very cautiously during the Lipo-Bodylift procedure, because of the extensive liposuction required. Preoperative imaging was performed to exclude hernias of the linea alba and flank,¹⁰ and any parietal anomaly. Patients with rectus diastasis were not favored for surgery even if rectus plication was feasible¹¹. A follow-up by a nutritionist was requested in the preoperative period; all biological deficiencies were systematically recorded and remedied (if necessary).

Operative procedure

Patients were preoperatively marked-up in both the standing and supine positions, as previously described^{4,6,7}. All were placed under general anesthesia. Antibioprophylaxis featured administration of 4 g Cefazolin prior to surgery. A urinary catheter was out in place. Adipose tissue was infiltrated with an adrenaline solution in saline (1:1,000 [w/v]; mean 1-1.2 L/patient)

to reduce bleeding during surgery and to facilitate liposuction. We initiated the procedure in the posterior region, with the patient prone. Liposuction was performed (using 4 mm-diameter cannulae) between the superior and inferior marks from the dermis to the muscular fascia. Commencing with the 25th patient, we used a power-assisted liposuction device (PAL; Microaire, Charlottesville, VA, USA). The trochanteric areas were suctioned under the superficialis fascia to facilitate lifting of the lateral thigh. Thereafter, the required skin excisions were checked by pinching, and skin resections were performed immediately below the dermis to preserve all connective tissue¹² (**Figure 5 and Supplemental Digital Content Video 1**). We next performed flapless gluteal autoaugmentation, as previously described¹³; we lifted the buttock from the outside inwards. This suturing tip moderately increases the buttock projection, or at least ensures that it is not entirely flat, which is normally the case after a body lift. Posterior wound closure was performed without drain placement using absorbable stitches (Polysorb 2; Covidien, Dublin, Ireland) placed between the two superficial fascial layers and the use of additional absorbable stitches (Monocryl 3/0; Ethicon, Somerville, NJ, USA) to secure the subdermal plane. A running suture (Monocryl 4/0) was employed for wound closure.

Thereafter, the patient was placed in the supine position and the anterior procedure commenced. We performed highly modified lipoabdominoplasty; only areas under the skin resection were subjected to liposuction, as in the previous step. Very limited (traditional) undermining was performed in the area below the region running from above the umbilicus to the xiphoid. Monsplasty (using three non-absorbable stitches; [Premicron 1; B. Braun, Melsungen, Germany]) was performed from the region between the Camper adipose layer to the muscular fascia. This smoothly elevated the mons pubis and corrected any ptosis.¹⁴ Next, high-tension suturing was performed at the top of the umbilicus to facilitate wound closure (by reducing the tension on the scar) and to remodel the subumbilical abdomen.¹⁵ Tension-free closure was achieved using absorbable Polysorb 2/0 and 3/0, and Monocryl 4/0, stitches. All patients wore

compression garments (Lipo-Panty S005; Medical Z, San Antonio, TX, USA) for 2 months postoperatively.

Postoperative care

Deep venous thrombosis (DVT) prophylaxis required mandatory wearing of compression stockings and low-molecular weight heparin injections for 15 postoperative days (PODs). The dressings were changed every two days. Walking was authorized on POD 1 and the urinary catheter removed the next day. Physiotherapy (scar massage, LPG therapy, and lymphatic drainage) was initiated no earlier than 6 weeks after surgery.

Statistical analysis

Statistical analyses were performed using R statistical software (<http://www.r-project.org/>). Continuous data are expressed as medians with interquartile ranges (IQRs) and were compared with the aid of the Mann-Whitney U-test. Categorical data are expressed as percentages and were compared employing the Chi-squared test or the two-sided Fisher's exact test when the Chi-squared test was inappropriate. Exploratory univariate analyses were performed to define risk factors for postoperative complications. We calculated the Spearman correlation between operative time and patient sequence (from the earliest to the latest). The threshold for statistical significance was set at $P < 0.05$.

Results

During the study period, 100 post-massive weight loss patients underwent the Lipo-Bodylift procedure. The patient and procedural characteristics are summarized in Tables 1 and 2. The median patient age was 41 years. The median pre-body lift BMI was 26.3 kg/m² and the average weight loss prior to body lift 50 kg, with a mean delta-BMI loss of 18.5 kg/m². Of all patients, 94% had histories of bariatric surgery (either gastric bypass [75%] or sleeve gastrectomy [26%]). The pre-operative ASA scores were 1 in 36% and 2 in 64% of all patients. The median operative time was 153.5 min; the median liposuction volume 2,800 mL; and the mean mass of

resected skin 904.5 g. Notably, the operative time fell with increasing experience; a learning curve was in play (**Figure 6**). The median hospital stay was 3 days and the median drainage duration 3 days. Of all patients, 30% experienced at least one complication; 2% developed hematomas and/or phlebitis (major complications). Minor complications predominated (28%), including a 27% incidence of wound dehiscence treated via healing with secondary intention, a 3% incidence of wound infections, and a 4% occurrence of fat necrosis. The wound dehiscence was isolated in six patients but not so in others; the mean defect area was 3.7 ± 2.6 cm². We encountered no seroma. We performed seven revision surgeries for esthetic purposes (secondary liposuction because of initial undercorrection). Complications were significantly associated with smoking status (Table 4) ($p < 0.001$).

Discussion

We report one of the most extensive series of circumferential body contouring of the lower trunk; we performed extensive liposuction and skin resection immediately under the dermis. Our technique was inspired by that of Saldanha,¹¹ but differs in some respects. We incorporated several new adaptations to deal with the major skin laxities of Type I and II patients with massive weight loss. After such loss, the skin and the subcutaneous adipose layer are particularly affected. Obesity induces chronic inflammation of both adipose tissue and skin, triggering skin reshaping via differential expression of certain proteins involved in maintenance of biomechanical properties and extracellular matrix organization.¹⁶⁻¹⁸ Skin inflammation is always present after massive weight loss, but is more significant after bariatric surgery than after dieting.¹⁹ The mechanical properties of the subcutaneous fat also change. The subcutaneous adipose tissue is divided into two layers (superficial and deep) by the superficialis (Scarpa) fascia that parallels the skin, and into multiple compartments separated by connective septa that run from the dermis to the muscular fascia.²⁰ Lockwood, in 1991, described this entire conjunctival structure, and termed it the “superficial fascial system” (SFS).²¹ The system

divides adipose tissue into multiple compartments that support the skin surfaces overlying musculoskeletal structures. The SFS is more dense in some locations than others, creating deep-seated skin adhesions. The SFS is of great importance in terms of the sequelae of obesity in patients experiencing massive weight loss. In obese patients, the SFS becomes progressively looser (“relaxes”) as the adipose content increases. On palpation, the skin and subcutaneous fat appear tense (thus not very mobile). During massive weight loss, the SFS that became highly relaxed during obesity does not retract and the septae perpendicular to the skin do not restore the “traditional” tension. This creates extreme laxity on palpation, and marked skin mobilization (which is often greater than suggested clinically). These SFS changes explain the typical deformations encountered after massive weight loss; an analysis of the SFS greatly assists selection of an appropriate technique. We developed our “Lipo-Bodylift” technique after careful consideration of SFS hyperlaxity and the related skin changes⁴. The key principles are: (1) the different structures affected by massive weight loss are treated differently; excess fat is removed via liposuction and excess skin by resection immediately below the dermis, allowing preservation of the entire connective framework and thus better conservation of tissue structure and (probably) tissue physiology; (2) no undermining is performed outside the areas of skin resection; (3) abdominal flap descent is possible given the hyperlaxity induced by changes to the skin and the SFS; and, (4) only limited subumbilical undermining is required to transpose the umbilicus.

The Lipo-Bodylift differs greatly from the lipoabdominoplasty of Saldanha.¹¹ The latter surgery is performed on patients of normal weight who lack skin and SFS abnormalities; liposuction is performed above and below the umbilicus. The skin below the umbilicus and the superficial adipose layer (above the Scarpa fascia) are then removed with preservation of the superficialis fascia and the deep fat (to avoid lymphatic damage). Liposuction is performed under the abdominal flap to increase flap mobility, and the flap is then pulled down.

We incorporated extensive circumferential liposuction into our Lipo-Bodylift procedure to reduce the complication rate, particularly seroma (we encountered no seroma). We then extended the principle (mostly to arm lifts) and achieved results as good as those afforded by medial thighplasty²²⁻²⁴ and brachioplasty²⁵⁻²⁷. We consider that the absence of seroma is probably attributable to the preservation of connective tissue in the resected areas. Indeed, it has been previously reported that the tissue remaining after liposuction exhibits a morphologically preserved microvascular network, suggestive of functional preservation.¹² Our present data support this suggestion.

The Lipo-Bodylift is as reproducible and safe as traditional abdominal flap undermining, with a lower complication rate than that described in a recent meta-analysis (36.55% [IQR: 26.63-45.65%]).²⁸ Notably, our major complication rate was only 2% in a relatively large series, possibly attributable to connective tissue preservation in the subumbilical area, the very limited subumbilical undermining, and that the fact that abdominal flap mobilization exploited the mechanical properties of tissue (we did not engage in wide undermining). This avoids complications attributable to large dead spaces and abdominal flap problems that appear following undermining and the sacrifice of some vascularization.

The principal postoperative complication of the present study was wound dehiscence. Notably, our prospective database showed that the dehiscence rate was less than that of the only prior prospective study (that of Kitzinger) (60%).²⁹ Indeed, our rate was higher than those of the retrospective studies of Rohrich³⁰, Koller³¹, Vico³², and Nemerofsky³³ (1, 16, 23, and 32.5% respectively). This shows that prospective studies/databases reflect clinical reality more accurately than do retrospective studies/databases. Also, no consensus definition of wound dehiscence yet exists; we used a broad definition. This may have enhanced the apparent complication rate.

Smoking status was the only factor that increased the rate of postoperative complications. Peri-operative tobacco use was previously shown to be a risk factor for postoperative complications after circumferential lowering of the trunk contours,³³⁻³⁵ and also in a recent meta-analysis of plastic surgery outcomes.³⁶ The suggested association between tobacco use and complications is not obvious in all reported series, probably because of a lack of true self-reporting and because increasing numbers of surgeons refuse to operate on smokers.

Our technique has certain limitations. A learning curve is in play. The technique usefully treats Type I and II deformities, but not those of Type III, given the absence of tissue flaccidity (poor skin tone) in the latter patients, who may thus require liposuction of the umbilical abdominal flap (as described by Saldanha)¹¹ prior to flap lowering. We did not perform rectus plication, although this could be performed by removing the “tissue connectives” between the inner edges of the rectus abdominis muscles. Indeed, after massive weight loss, all patients exhibit a certain parietal “hypotonia/laxity” that includes the muscles, without necessarily evidencing a real diastasis of the abdominal rectus. Intraoperatively, we commonly observe a 2-cm gap between the rectus abdominis muscles; this does not require correction. Indeed, correction would be painful and increase the risk of postoperative bleeding. However, the lack of rectus plication may be associated with incomplete correction of parietal laxity.

Conclusion

The Lipo-Bodylift seems to be less invasive than the traditional undermining that usually accompanies circumferential reconstruction of the lower trunk. The rate of major complications is low. We developed the Lipo-Bodylift technique after analyzing the changes in skin and subcutaneous fat induced by massive weight loss. The technique deals particularly well with the sequelae developing in Type I and II patients after massive weight loss.

References

1. Manzoni AP, Weber MB. Skin changes after bariatric surgery. *An Bras Dermatol*;90:157-66.
2. Carloni R, Naudet F, Chaput B, et al. Are There Factors Predictive of Postoperative Complications in Circumferential Contouring of the Lower Trunk? A Meta-Analysis. *Aesthetic surgery journal / the American Society for Aesthetic Plastic surgery* 2016;36:1143-54.
3. Bertheuil N, Chaput B, De Runz A, Girard P, Carloni R, Watier E. Reply: The Lipo-Body Lift: A New Circumferential Body-Contouring Technique Useful after Bariatric Surgery. *Plastic and reconstructive surgery* 2017;140:352e-3e.
4. Bertheuil N, Chaput B, De Runz A, Girard P, Carloni R, Watier E. The Lipo-Body Lift: A New Circumferential Body-Contouring Technique Useful after Bariatric Surgery. *Plastic and reconstructive surgery* 2017;139:38e-49e.
5. Bertheuil N, Chaput B, Girard P, Carloni R, Watier E, De Runz A. The Lipo-Bodylift: An ideal technique for type I and II massive weight loss patients (reply to Dast et al.). *Plastic and reconstructive surgery* 2017.
6. Bertheuil N, Carloni R, Herlin C, Chaput B, Watier E. Lower Body Lift after Massive Weight Loss: Autoaugmentation versus No Augmentation. *Plastic and reconstructive surgery* 2016;137:476e-7e.
7. Bertheuil N, Chaput B, Bergeat D, Morvan C, Mocquard C, Watier E. The Lipo-Body Lift: Operative Technique. *Plast Reconstr Surg Glob Open* 2019;7:e2156.
8. Meal C, Mocquard C, Bergeat D, et al. Impact of Lipo-Body Lift Compared to Classical Lower Body Lift on Postoperative Outcome and Patient's Satisfaction: A Retrospective Study. *Aesthetic plastic surgery* 2020;44:464-72.
9. Mendes FH, Donnabella A, Fagotti Moreira AR. Fleur-de-lis Abdominoplasty and Neo-umbilicus. *Clinics in plastic surgery* 2019;46:49-60.

10. Delliere V, Bertheuil N, Harnois Y, et al. Multiple bowel perforation and necrotising fasciitis secondary to abdominal liposuction in a patient with bilateral lumbar hernia. *Indian J Plast Surg*;47:436-40.
11. Saldanha OR, Pinto EB, Matos WN, Jr., Lucon RL, Magalhaes F, Bello EM. Lipoabdominoplasty without undermining. *Aesthetic surgery journal / the American Society for Aesthetic Plastic surgery* 2001;21:518-26.
12. Bertheuil N, Chaput B, Berger-Muller S, et al. Liposuction Preserves the Morphological Integrity of the Microvascular Network: Flow Cytometry and Confocal Microscopy Evidence in a Controlled Study. *Aesthetic surgery journal / the American Society for Aesthetic Plastic surgery*.
13. Bertheuil N, Carloni R, Herlin C, Chaput B, Watier E. Lower Body Lift after Massive Weight Loss: Autoaugmentation versus No Augmentation. *Plastic and reconstructive surgery*;137:476e-7e.
14. Patoue A, De Runz A, Carloni R, Aillet S, Watier E, Bertheuil N. Safe monsoplasty technique. *J Plast Surg Hand Surg* 2017:1-6.
15. Le Louarn C, Pascal JF. High superior tension abdominoplasty. *Aesthetic plastic surgery* 2000;24:375-81.
16. Shipman AR, Millington GW. Obesity and the skin. *The British journal of dermatology* 2011;165:743-50.
17. Light D, Arvanitis GM, Abramson D, Glasberg SB. Effect of weight loss after bariatric surgery on skin and the extracellular matrix. *Plastic and reconstructive surgery* 2010;125:343-51.
18. Halawi A, Abiad F, Abbas O. Bariatric surgery and its effects on the skin and skin diseases. *Obesity surgery* 2013;23:408-13.

19. Gallo JRB, Maschio-Signorini LB, Cabral CRB, et al. Skin Protein Profile after Major Weight Loss and Its Role in Body Contouring Surgery. *Plast Reconstr Surg Glob Open* 2019;7:e2339.
20. Markman B, Barton FE, Jr. Anatomy of the subcutaneous tissue of the trunk and lower extremity. *Plastic and reconstructive surgery* 1987;80:248-54.
21. Lockwood TE. Superficial fascial system (SFS) of the trunk and extremities: a new concept. *Plastic and reconstructive surgery* 1991;87:1009-18.
22. Le Louarn C, Pascal JF. The concentric medial thigh lift. *Aesthetic plastic surgery* 2004;28:20-3.
23. Bertheuil N, Thienot S, Chaput B, Varin A, Watier E. Quality-of-Life assessment after medial thighplasty in patients following massive weight loss. *Plastic and reconstructive surgery*;135:67e-73e.
24. Bertheuil N, Chaput B, Girard P, Carloni R, Watier E, De Runz A. Reply: The Lipo-Body Lift: A New Circumferential Body-Contouring Technique Useful after Bariatric Surgery. *Plastic and reconstructive surgery* 2017;140:233e-4e.
25. Pascal JF, Le Louarn C. Brachioplasty. *Aesthetic plastic surgery* 2005;29:423-9; discussion 30.
26. Hunstad JP, Kortesis BG, Knotts CD. Avulsion Thighplasty: Technique Overview and 6-Year Experience. *Plastic and reconstructive surgery*;137:84-7.
27. Knotts CD, Kortesis BG, Hunstad JP. Avulsion brachioplasty: technique overview and 5-year experience. *Plastic and reconstructive surgery*;133:283-8.
28. Carloni R, Chaput B, Auquit-Auckbur I, Watier E, Bertheuil N. A higher excision pattern does not only reduce gluteal cleft elongation but also reduces overall complications in circumferential contouring of the lower trunk. Results of a meta-analysis. *Plastic and reconstructive surgery*.

29. Kitzinger HB, Cakl T, Wenger R, Hacker S, Aszmann OC, Karle B. Prospective study on complications following a lower body lift after massive weight loss. *Journal of plastic, reconstructive & aesthetic surgery : JPRAS*;66:231-8.
30. Rohrich RJ, Gosman AA, Conrad MH, Coleman J. Simplifying circumferential body contouring: the central body lift evolution. *Plastic and reconstructive surgery* 2006;118:525-35; discussion 36-8.
31. Koller M, Hintringer T. Circumferential superficial fascia lift of the lower trunk: surgical technique and retrospective review of 50 cases. *Journal of plastic, reconstructive & aesthetic surgery : JPRAS*;65:433-7.
32. Vico PG, De Vooght A, Nokerman B. Circumferential body contouring in bariatric and non-bariatric patient. *Journal of plastic, reconstructive & aesthetic surgery : JPRAS*;63:814-9.
33. Nemerofsky RB, Oliak DA, Capella JF. Body lift: an account of 200 consecutive cases in the massive weight loss patient. *Plastic and reconstructive surgery* 2006;117:414-30.
34. de Runz A, Brix M, Gisquet H, et al. Satisfaction and complications after lower body lift with autologous gluteal augmentation by island fat flap: 55 case series over 3 years. *Journal of plastic, reconstructive & aesthetic surgery : JPRAS*;68:410-8.
35. van Huizum MA, Roche NA, Hofer SO. Circular belt lipectomy: a retrospective follow-up study on perioperative complications and cosmetic outcome. *Annals of plastic surgery* 2005;54:459-64; discussion 65-6.
36. Pluvy I, Panouilleres M, Garrido I, et al. Smoking and plastic surgery, part II. Clinical implications: a systematic review with meta-analysis. *Annales de chirurgie plastique et esthetique*;60:e15-49.

Legends to Figures

Figure 1: A Lipo-Bodylift patient of Type I.

Top: Preoperative view. Bottom: After the Lipo-Body lift. The BMI of a 37-year-old female fell from 39.7 to 25.9 kg/m² after BYPASS.

Figure 2: Lipo-Bodylift patient of Type I.

Top: Preoperative view. Bottom: After the Lipo-Bodylift. The BMI of a 44-year-old female fell from 45.7 to 24.6 kg/m² after BYPASS.

Figure 3: Lipo-Bodylift patient of Type II.

Top: Preoperative view. Bottom: After the Lipo-Bodylift. The BMI of a 57-year-old female fell from 45.8 to 29.3 kg/m² after SLEEVE gastrectomy.

Figure 4: Lipo-Bodylift patient of Type II.

Top: Preoperative view. Bottom: After the Lipo-Bodylift. The BMI of a 41-year-old female fell from 40.9 to 29.4 kg/m² after BYPASS.

Figure 5: Dissection level of skin resection.

Figure 6: The learning curve.

The operative time fell as the number of procedures performed increased.

Supplemental Digital Content Video 1: Skin resection.

The video shows the skin resection performed immediately below the dermis; this conserved all connective tissue.

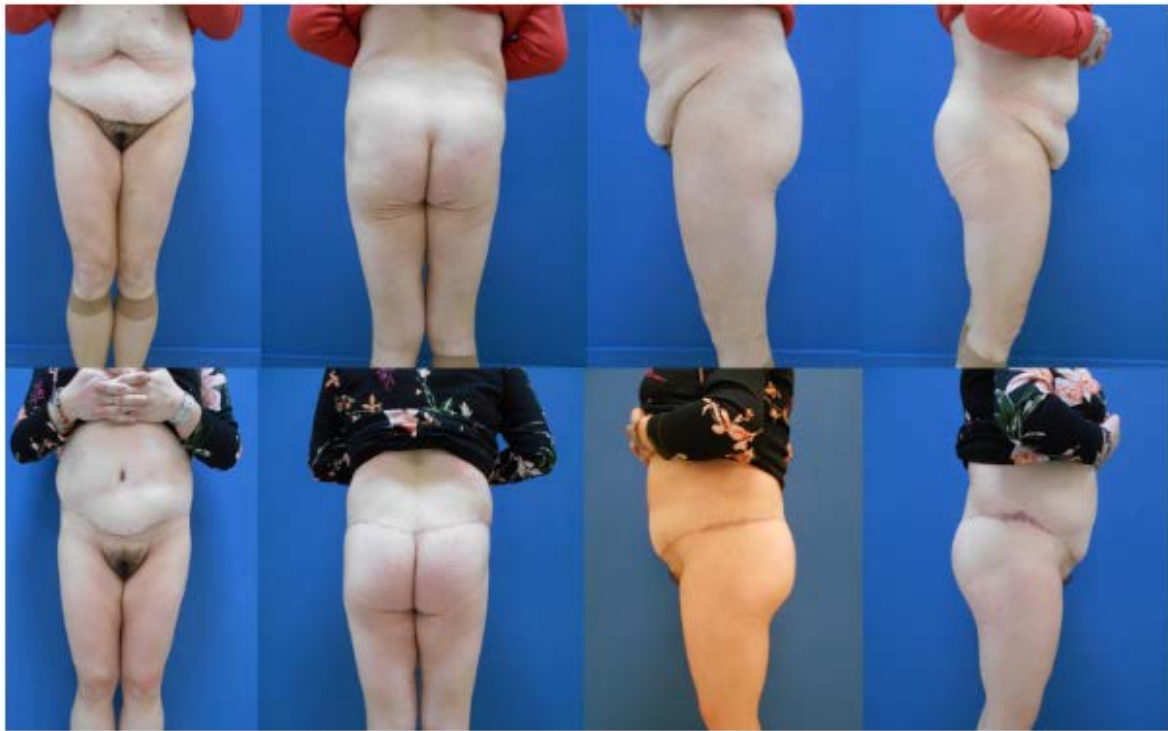

Fig. 1A Type I Lipo-Bodylift patient. Top: Preoperative view. Bottom: After the Lipo-Bodylift. The BMI of a 37-year-old female fell from 39.7 to 25.9 kg/m² after BYPASS

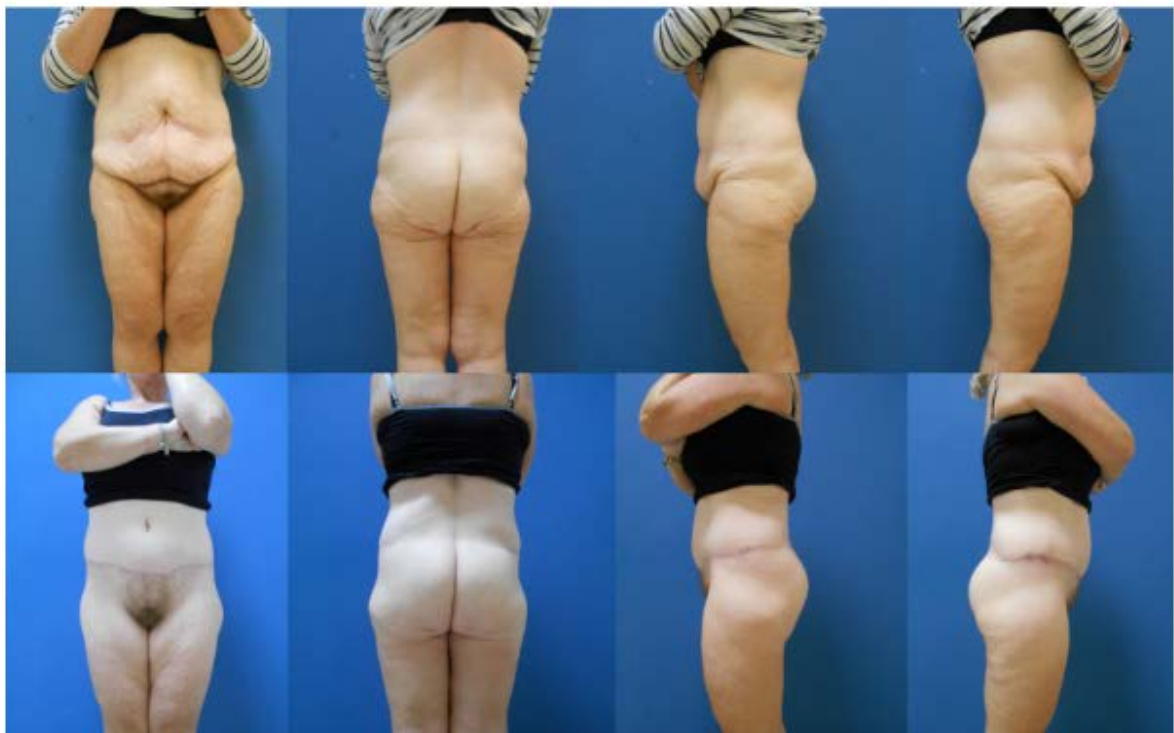

Fig. 2A Type I Lipo-Bodylift patient. Top: Preoperative view. Bottom: After the Lipo-Bodylift. The BMI of a 44-year-old female fell from 45.7 to 24.6 kg/m² after BYPASS

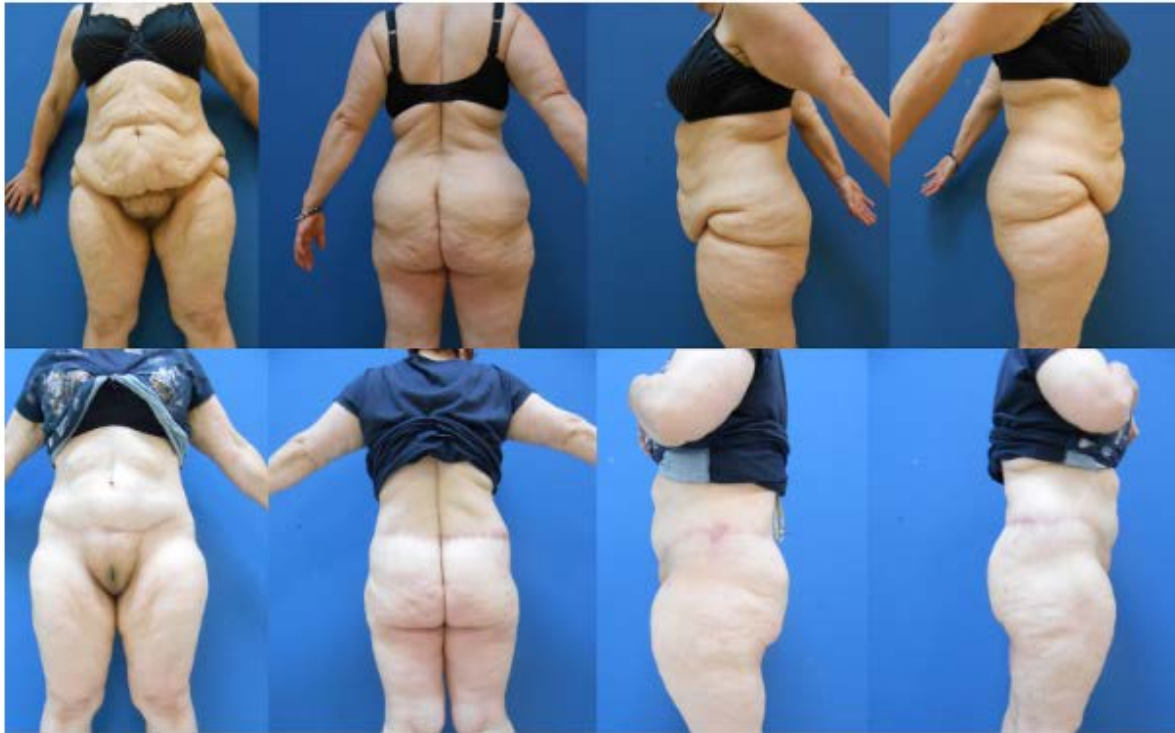

Fig. 3A Type II Lipo-Bodyliftpatient. Top: Preoperative view.Bottom: After the Lipo-Bodylift. The BMI of a 57-year-old female fell from 45.8 to 29.3kg/m²after SLEEVEgastrectomy

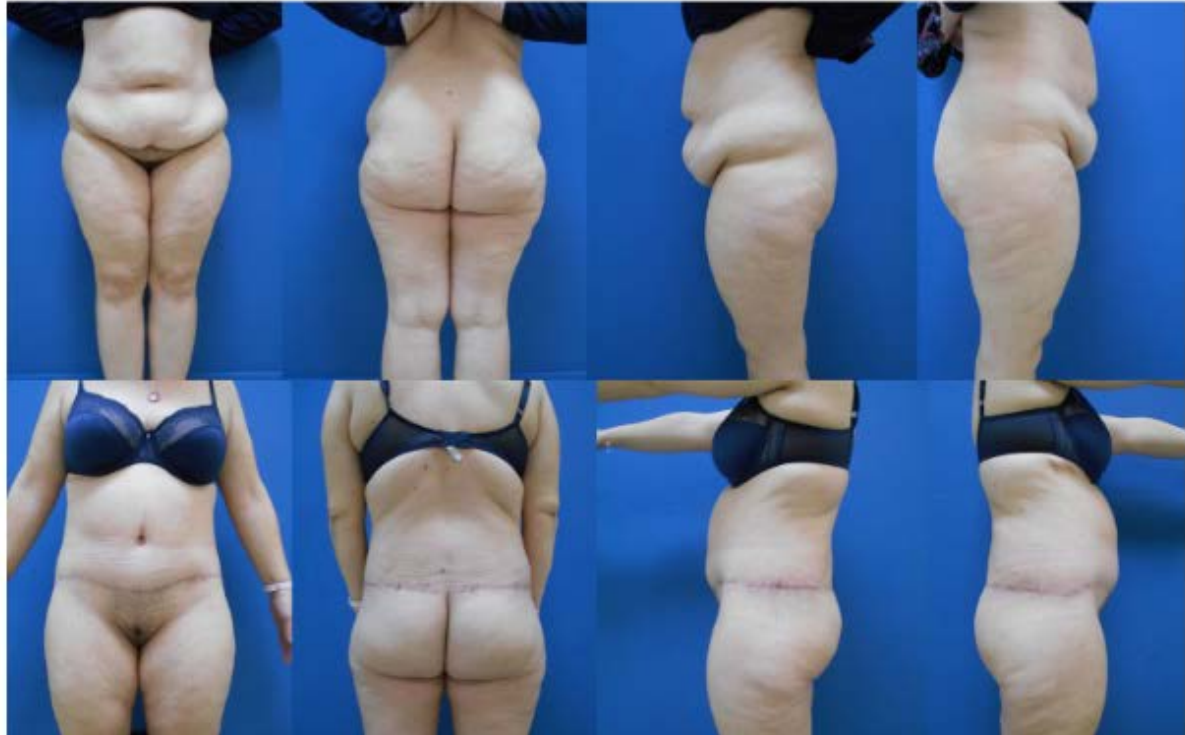

Fig. 4A Type II Lipo-Bodyliftpatient. Top: Preoperative view.Bottom: After the Lipo-Bodylift. The BMI of a 41-year-old female fell from 40.9 to 29.4kg/m²after BYPASS

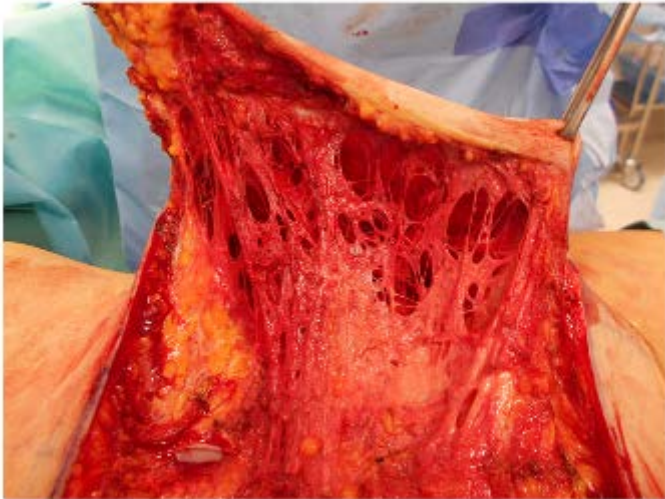


Fig. 5 Dissection level of skin resection

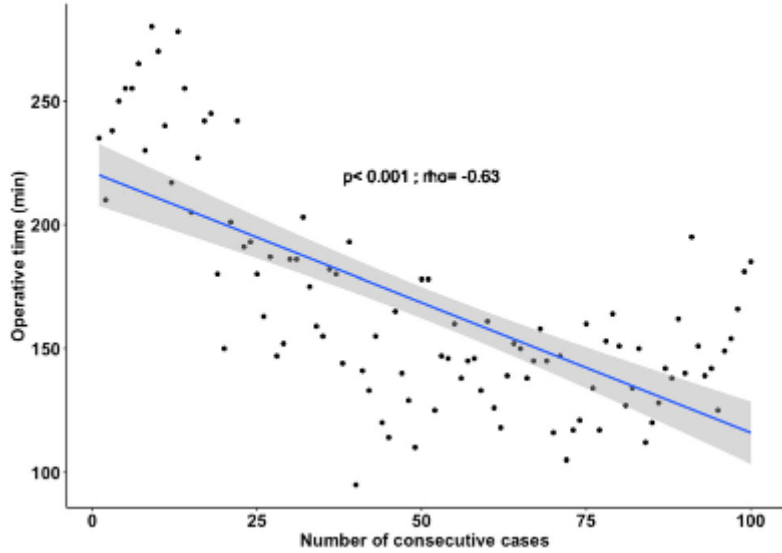


Fig. 6 The learning curve. The operative time fell as the number of procedures performed increased

Table 1 - Patient and operative characteristics.

Variable	
Patients	100
Age (years)	41.0 [31-47]
Gender F:M	3.8
Pre massive weight loss BMI (Kg/m ²)	45.0 [41.08-48.33]
Pre body lift BMI (Kg/m ²)	26.3 [24.31-28.12]
Weight loss (Kg)	50.0 [41-60]
Delta BMI (Kg/m ²)	18.5 [15.58-21.74]
History of bariatric surgery	94
One procedure	87 (92.6)
Two procedures	5 (5.3)
≥Three procedures	2 (2.1)
Gastric bypass	70 (74.5)
Sleeve gastrectomy	24 (25.5)
ASA score	
1	36 (36)
2	64 (64)
Overall operative time (minutes)	153.5 [138.8-188]
Posterior operative time (min)	70.0 [57.00-82.25]
Posterior liposuction volume (mL)	1500.0 [1088-1900]
Posterior weight resection (Gram)	308.0 [274.8-373.2]
Anterior operative time (min)	88.0 [76.75-110.00]
Anterior liposuction volume (mL)	1300.0 [900-1700]
Anterior weight resection (Gram)	589/5 [499.0-686.5]
Drain duration	3.0 [3-4]
Length of stay (days)	3.0 [3-4]

Categorical variables are presented with number and (%), continuous variable are expressed with median and [interquartile range]

Table 2 - Medical history

Comorbidities	n (%)
Tabacco use	25 (25)
Hight blood pressure	6 (6)
Hypothyroidism	8 (8)
Asthma	10 (10)
Diabetes	2 (2)
Sleep apnea	3 (3)
Psychiatric	4 (4)
Depression	2 (2)
Bipolar disorder	2 (2)

Categorical variables are presented with number and (%)

Table 3 - Complications after lipobodylift

Complications	n (%)
Overall complications	30 (30)
Major complications	2 (2)
Minor Complications	28 (28)
Thromboembolism	1 (1)
Hematoma	2 (2)
Wound dehiscence	27 (27)
Wound infection	3 (3)
Skin necrosis	0 (0)
Fat necrosis	4 (4)
Seroma	0 (0)
Revision for aesthetic purpose	7 (7)

Categorical variables are presented with numbers and (%)

Table 4 – Risk factors analysis for postoperative complications

	Overall complication		<i>P</i> value
	Yes n=30	No n=70	
Age	38.5[32.5-44.75]	41[31.0-47.0]	0.81
ASA score			0.30
	1	8 (26.67)	28 (40.00)
	2	22 (73.33)	42 (60.00)
Pre plastic surgery BMI	26.80[25.75-28.10]	25.85[24.22-28.09]	0.25
Delta BMI	18.51[13.82-22.55]	18.54[16.72-21.66]	0.68
Hypertension		3 (10.00)	3 (4.29)
Diabetes		1 (3.33)	1 (1.43)
Smoking		18 (60.00)	13 (18.57)
Liposuction volume (mL)	3325[1925-3812]	2625[2100-3475]	0.25
		101.00[85.59-	
Liposuction volume/BMI	124.27[78.46-138.47]	122.43]	0.20
Weight of skin resection (gram)	914.0[775.5-1074.5]	904.5[819.2-999.2]	0.95
Operative time (min)	164.0[142.5-235.2]	150.0[138.2-180.8]	0.08
Consecutive cases			0.56
First 10 patients		4 (13.33)	6 (8.57)
From 11 to 50 patients		13 (43.33)	27 (38.57)
After 50 patients		13 (43.33)	37 (52.86)

Categorical variables are presented with numbers and (%) ; Continuous variables are expressed with median and [interquartile range]

The English in this document has been checked by at least two professional editors, both native speakers of English. For a certificate, please see:

<http://www.textcheck.com/certificate/gSMJDz>