



HAL
open science

Single bilateral ovarian venous return in uterine transplant: Validation in an orthotopic auto-transplant model in the Yucatan minipig

Ludivine Dion, Maela Le Lous, Krystel Nyangoh Timoh, Jean Levêque, Alexis Arnaud, Charles Henri-Malbert, Fabrice Foucher, Karim Boudjema, Claude Bendavid, Cécile Vigneau, et al.

► To cite this version:

Ludivine Dion, Maela Le Lous, Krystel Nyangoh Timoh, Jean Levêque, Alexis Arnaud, et al.. Single bilateral ovarian venous return in uterine transplant: Validation in an orthotopic auto-transplant model in the Yucatan minipig. *Journal of Gynecology Obstetrics and Human Reproduction*, 2021, 50 (7), pp.102059. 10.1016/j.jogoh.2021.102059 . hal-03128700

HAL Id: hal-03128700

<https://hal.science/hal-03128700>

Submitted on 3 Feb 2023

HAL is a multi-disciplinary open access archive for the deposit and dissemination of scientific research documents, whether they are published or not. The documents may come from teaching and research institutions in France or abroad, or from public or private research centers.

L'archive ouverte pluridisciplinaire **HAL**, est destinée au dépôt et à la diffusion de documents scientifiques de niveau recherche, publiés ou non, émanant des établissements d'enseignement et de recherche français ou étrangers, des laboratoires publics ou privés.



Distributed under a Creative Commons Attribution - NonCommercial 4.0 International License

Single bilateral ovarian venous return in uterine transplant :
Validation in an orthotopic auto-transplant model in the Yucatan minipig

Short Title : Ovarian venous return in uterine transplant in the Yucatan minipig

Ludivine Dion^{1,2*}, Maela Le Lous¹, Krystel Nyangoh Timoh¹, Jean Levêque^{1,2}, Alexis Arnaud^{3,4}, Charles Henri-Malbert⁵, Fabrice Foucher¹, Karim Boudjema⁶, Claude Bendavid⁷, Cécile Vigneau⁸, Patrick Legembre², David Val-Laillet⁴, Vincent Lavoué^{1,2}.

¹ Rennes University Hospital, Department of Gynecology, Hôpital Sud, France.

² INSERM, U1242, COS, Rennes, France.

³ Rennes University Hospital, Département of paediatrics, Hôpital sud, France

⁴ INRA, INSERM, Univ Rennes, Nutrition Metabolisms and Cancer (NuMeCan), Rennes, St Gilles, France.

⁵ INRA, US 1395 Ani-Scans, Saint-Gilles, France.

⁶ Rennes University Hospital, Département of Hepatobile Surgery and Liver Transplantation, Pontchaillou, France.

⁷ Rennes University Hospital, Département of biochemistry, Pontchaillou, France.

⁸ Rennes University Hospital, Département of nephrology, Pontchaillou, France.

* Corresponding Author: Dr Ludivine Dion, MD, ludivine.dion@chu-rennes.fr, Department of Gynecology, Rennes University Hospital, 16 Bd de Bulgarie, 35000 Rennes, France.

The authors declare no conflicts of interest.

Abstract

Background : Uterine transplant (UT) represents an opportunity to treat absolute uterine infertility. However, the use of uterine veins for venous return, in addition to ovarian veins, significantly increases the risk of ureteral wounds in the living donor and UT time for the recipient. Our aim was to demonstrate that dual ovarian venous return is sufficient for graft viability and survival.

Methods : Uterine orthotopic auto-transplant was performed under general anaesthesia in six Yucatan minipig sows. The uterus graft was implanted with termino-lateral anastomoses between the ovarian and external iliac veins, and between the uterine and external iliac arteries, respectively.

Results : The macroscopic physical aspect of the graft was adequate in 83% of the sows (5/6) 30 min after reperfusion with a surgical time of 439 ± 54 min (mean anastomosis time: 153 ± 49 min). Two sows died the day after surgery. In the four remaining sows, two uteri were necrotic and two were adequately vascularized on Day 7.

Conclusions : the learning curve was relatively fast, the sole use of bilateral ovarian venous return is possible and might reduce post-surgery morbidity in human living donors as well as UT time for the recipient.

Keywords : uterine transplant, Yucatan minipig, auto-transplant, absolute uterine infertility.

Declarations :

This study was carried out in strict accordance with the recommendations of the European Community (Directive 2010/63/EU ; Agreement No A35-622). The protocol was approved by the Regional Committee on the Ethics of Animal Experiments of Brittany (Protocol Number : 01894), and validated by the Ministry of National Education, Higher Education and Research (approval number : 2017083120283994-V2-APAFiS #11100). All surgery was performed under general anesthesia, and all efforts were made to minimize suffering.

Funding :

Biomedicine Agency (call for tender 2017) and the University-Hospital of Rennes (CHU Rennes, Research Department).

List of abbreviation :

ATP : Adenosine Tri-Phosphates
AUI : Absolute Uterin Infertility
CPK : Creatine PhosphoKinase
EIA/V: External Iliac Artery / Vein
HES : Hematoxylin Eosin Saffron
IIA/V: Internal Iliac Artery / Vein
IM : Intramuscular
INRA : Institut National de la Recherche Agronomique
IV : Intravenous
MRKH : Mayer Rokistansky Küster Hauser
OV: Ovarian Vein
SC : Subcutaneous
UT : Uterus Transplantation
UA/V: Uterine Artery / Vein
UOV: Utero-Ovarian Vein
UR: Ureter

Introduction

Uterine transplant (UT) offers women with absolute uterine infertility (AUI) the opportunity to bear and give birth to a child. It received worldwide attention after a successful procedure by a Swedish team headed by Pr. Brännström resulted in the birth of a healthy child in 2014[(1)]. To date, more than 76 UTs have been performed worldwide allowing the birth of 19 children and several pregnancies that are currently ongoing[2], UTx Cleveland congress 2019.

The uterine graft can be harvested either from a living or brain-dead donor without impact on UT feasibility or the child's health[1,3,4]. In the Swedish princeps study[5], venous return of the uterine graft was primarily achieved by the utero-ovarian veins, sometimes supplemented by the ovarian veins. In a Brazilian case involving a brain-dead donor[6], venous return was quadruple with the use of two uterine and two ovarian veins. However, the variable anatomical pathway of uterine veins and their thin walls makes dissection tricky and puts the living donor at risk of ureteral wounds. This risk is real: some authors[7-9] have reported the need to implant a double J catheter, while Brännström et al. [5] described a uretero-vaginal fistula requiring reimplantation by pyelostomy. In 2018, Chmel et al. [8] also described a ureteral wound during uterine removal surgery.

In addition to the risk of ureteral wound for the donor, performing four anastomoses (two uterine veins and two ovarian and/or utero-ovarian veins) significantly increases the duration of the implantation procedure for the recipient (11 h for the Swedish series[5], 10 h 30 min for the Brazilian team[6]). The average duration of a termino-lateral vascular suturing was 36 min in the Swedish series. Thus, if venous return could be obtained without the uterine veins, not only would the risk for ureteral wound and the duration of uterine removal be minimized for the donor, but the surgical time of the UT would also be reduced for the recipient. However, before advocating the use of single venous return *via* the ovarian veins, it is necessary first to ascertain that the uterine graft is viable in an animal model, and that women undergoing such a procedure can bear a child.

The aim of this preclinical study was thus to validate the viability of a uterine graft after transplantation using bilateral ovarian venous return only in a minipig model of uterine orthotopic auto-transplantation. Graft viability was evaluated on the basis of visual macroscopic criteria, as well as biological and histological analyses performed 30 min and 7 days after UT (Day 7).

Materials & methods

This study was carried out in strict accordance with the recommendations of the European Community (Directive 2010/63/EU ; Agreement No A35-622). The protocol was approved by the Regional Committee on the Ethics of Animal Experiments of Brittany (Protocol Number : 01894), and validated by the Ministry of National Education, Higher Education and Research (approval number : 2017083120283994-V2-APAFiS #11100). All surgery was performed under general anesthesia, and all efforts were made to minimize suffering.

Animals

The experimental animals were nine multiparous Yucatan minipig sows. They came from breeding of INRA (Saint Gilles). The sows were sheltered in cages (2.3m by 2m), with some ropes and a rubber duck-board for environmental enrichment. Water was in open access and food was distributed once a day (ration adapted to the weight of the animal). Food was withdrawn 24 h before surgery and reintroduced the day after transplantation.

The sow's anatomy was first studied in four subjects that were not included in the study (Fig 1A). Three sows were used in a sham group for which manipulation of the uterus was performed only without any dissection. Six other sows were used for the UT procedure *per se* between April 2017 and October 2018 (mean age: 6.0 ± 2.6 years; mean body weight: 65 ± 11 kg; number of gestations: 9 ± 5). The venous return of the uterus is ensured by two uterine and two ovarian veins (Fig 1B). The uterine arteries originate from the internal iliac artery and cross the ureter at the cervico-vaginal junction. The uterus is drained by a venous arch composed of the uterine vein which runs along the uterus and flows into the internal iliac vein. The ovarian veins flow into both the lumbar-ovarian pedicles and the uterine veins by the utero-ovarian veins. The ovaries are vascularized by the ovarian arteries and drained by the ovarian veins.




Fig 1. Anatomical specimen of a control Yucatan minipig sow's uterus

After hysterectomy (A) and schematic representation of the native uterus (B, left) and post-transplant vascular anastomoses (B, right). EIA: external iliac artery; EIV: external iliac vein; IIA: internal iliac artery; IIV: internal iliac vein; OV: ovarian vein; UOV: utero-ovarian vein; UA: uterine artery; UR: ureter; UV: uterine vein.

Anaesthesia and analgesia

In the course of the experimental protocol, two anaesthesia and analgesia strategies were used consecutively and in different animals. This was a consequence of the extended duration of the surgical procedure and the inability to maintain central perfusion within adequate boundaries in the pig with the exclusive use of isoflurane as a primary anaesthetic agent[10].

Initial anaesthesia strategy. Five sows underwent this anaesthesia protocol. All were fasted 12h before surgery. Pre-anaesthesia was induced by the intramuscular injection of Zoletil 100 mg (15 to 20 mg/kg, Rhone VIRBAC). The suppression of the pharyngotracheal reflex was obtained by inhalation of isoflurane through a facial mask (3-5% v/v, Baxter, France).—Analgesia was achieved during surgery with fentanyl (18 µg/kg/min IV) and continued upon awakening with morphine hydrochloride (10 mg in toto, SC, Aguettant). Additional doses of morphine were given according to the PLATTER (Plan, Treat, Evaluate, Return) approach with the help of a pain assessment questionnaire designed in our facility for pain management after porcine abdominal surgery[11]. This questionnaire is derived from the 4Avet composite pain measurement tool[12]. Preventive antibacterial therapy (Amoxicillin 150 mg IM) was applied at the end of surgery and maintained for 3 days or more according to changes in body temperature.

Secondary anaesthesia strategy. In the first five animals, we observed a poor overall recovery rate together with depression of cardiovascular parameters including a mean arterial pressure lower than 7 mmHg associated with intractable tachycardia after several hours of anaesthesia (>4 hours). Such a clinical picture has been already described in pigs during long surgical procedures performed with isoflurane as the primary anaesthetic agent irrespective of its delivery scheme[13]. Therefore, we decided to switch to target control anaesthesia (TCA) using propofol as the primary anaesthetic agent as this solution preserves spO₂ and improves the ventilation-perfusion ratio. Furthermore, it protects haemodynamic stability while maintaining a stable depth of anaesthesia[14]. TCA was achieved using home-made software based on the Gepts weight adjusted model[15] modified for the pig. The desired concentration of propofol in the target tissue was set to 5.5 µg/ml of brain.

Surgery

Median laparotomy was performed with the sows lying in a dorsal decubitus reverse Trendelenburg position. The bladder was drained and the whole digestive tract was pushed towards the thorax to make the uterus accessible. The ureters were isolated and preserved and an extended hysterectomy was performed. The round ligaments were sectioned to allow access to the uterine arteries that were dissected from their point of origin to the cervical portion. The uterine veins were sectioned at their origin. The ovarian veins were dissected along the uterus for about 6 centimetres and the lumbar-ovarian pedicles were sectioned. The external iliac vessels were exposed in preparation for the vascular anastomoses during uterus re-implantation. A colpotomy with electrocautery was performed. The last step was to clamp and cut the uterine arteries and then the ovarian veins. All the surgical steps were timed, and intra-operative complications recorded.

Back-table graft preparation

Once explanted, the uterus was immediately perfused with a Ringer's lactate solution containing Choay heparin® 25 000 IU/L (Sanofi, Gentilly, France) and xylocaine 20 mg/L (Aguettant, Lyon, France) for 60 minutes (17mL/min) at 4°C. The uterus was then put on an ice-chilled tray. The uterine arteries and ovarian veins were prepared for transplantation under a binocular microscope (x3.5).

Uterine transplantation: orthotopic re-implantation of the uterus

The sow was injected with 12,500 IU intravenous heparin. Warm ischemia time began as soon as the back-table graft perfusion was stopped. Termino-lateral vascular anastomoses were performed between the external iliac vein and the ovarian vein bilaterally. The external iliac vein was clamped before venotomy and the suture was performed using three continuous stitches of prolene 7-0 (polypropylene, Ethicon, Ph. Eur.) after triangulation of the ovarian vein to perform a termino-lateral anastomosis. The ovarian vein was clamped upstream to the suture to prevent warming of the graft when unclamping the external iliac vein. The ipsilateral uterine artery was then anastomosed on the external iliac artery. The external iliac artery was clamped before arteriotomy with ablation of an arterial patch. The uterine artery was spatulated and sutured by two simple continuous sutures of 7-0 prolene (polypropylene,

Ethicon, Ph., Eur.) to achieve a termino-lateral anastomosis. The arterial clamps were then removed, and additional sutures were made if there was leakage. During vascular anastomosis, heparin flushes were performed *in situ* (i.e., by an intravascular Cathlon® catheter through the anastomosis). The contralateral vascular anastomoses were performed in the same manner. The ovarian veins and then the uterine arteries of the graft were unclamped simultaneously on both sides after suturing the vein and contralateral artery. The UT procedure was finalized by the re-anastomosis of the uterus using two simple continuous sutures of vicryl 1-0 (polyglactin 910; Ethicon; Ph. Eur.) on the vagina. The abdominal wall was closed in two places by vicryl 1-0 sutures (polyglactin 910, Ethicon, Ph. Eur.) (Figure 1B). The macroscopic physical aspect of the graft was evaluated 30 minutes after reperfusion applying three criteria: graft recoloration when declamping the uterine arteries (compared with initial blanching on the back-table); bleeding from the cut on the uterine horn; and visualisation of the pulsatility of the uterine arteries (a 3-grade score was used to indicate the absence/presence of the sign, i.e. -, +, ++). All three criteria were necessary to qualify the UT as a success.

Postoperative monitoring and animal care

A jugular venous catheter was inserted at least 15 days before surgery (1.02 mmx2.16 mm) under general anaesthesia to assure post-operative care. After surgery, the sows were housed in individual cages. A postoperative pain management protocol was followed as indicated in the anaesthesia and analgesia section for 3 days. Depending on the health status of the animal, IV infusion of Ringer's lactate (1000 mL daily), glucose 30% (100 mL daily) and intralipid (100 mL daily) were performed together with phloroglucinol (40 to 120 mg daily depending on the animal's overall condition) for additional pain management in the absence of morphine. Rectal temperature, and water and feed consumption were recorded every day for further analyses. A postoperative anticoagulation protocol (enoxaparine sodium: Lovenox 0.4 IU/day subcutaneous) was applied the day after surgery and then daily for 8 days.

Terminal surgery

In both groups, the uterus was explanted between Days 7 and 10 under general anaesthesia and according to the previously described protocol. The macroscopic aspect of the graft was evaluated applying the same three criteria that were used 30 min after reperfusion the day of surgery. At the end of the procedure, the animals were euthanized by IV injection of T61 (MSD, Intervet Beaucouzé, France).

Biological analyses

In the experimental group, blood samples were collected from the left external iliac vein before removal of the uterus and 30 min after transplantation. In the control group, blood samples were collected before manipulation and 30 min after, as well as 7 days later. For both groups, a tube containing 4 mL of blood was centrifuged (3500 rpm for 10 min) and the plasma was frozen before creatine phosphokinase (CPK) analysis. A second tube containing 1 mL of blood and 1 mL of perchloric acid was frozen for lactate and glucose analyses.

Histological analyses

A biopsy of the left horn was performed before the hysterectomy, 30 min after reperfusion, and between Days 7 and 10. In the control group, biopsies were performed before, 30 min after manipulation and on Day 7. The samples were fixed in 4% buffered formalin at pH7. After 24 h of fixation, the samples were cut in 4- μ m paraffin sections. Haematoxylin-eosin staining was then performed. Leukocytes in the stromal tissue, the aspect of the epithelial stroma, detachment of the glandular cells, retraction of the nucleus were categorized in three classes: normal, inflammatory or necrotic.

Study endpoints and statistical analyses

The primary study endpoint was the macroscopic visual inspection of the uterus 30 min after reperfusion. Secondary study endpoints were the macroscopic visual inspection of the uterus on Day 7, as well as the histological and biological data. The durations of the different surgical steps (anaesthesia, surgery, cold and warm ischemia) were expressed as mean \pm standard deviation. Biological data are represented as box-plots. Statistical analyses were performed with R software (R Core Team 2018; R: A language and environment for statistical computing, R Foundation for Statistical Computing, Vienna, Austria; URL <https://www.R-project.org>). To compare the operating times, the coefficient of determination was calculated and a Pearson test performed. Non-continuous data were compared using the non-parametric Mann-Whitney test for the independent data and Wilcoxon test for dependent data. A p-value below 0.05 was considered significant, and a p-value comprised between 0.1 and 0.05 was considered as a trend.

Results

Surgery

The durations of the different surgical steps are reported in Table 1. We observed shorter operating times for all stages of the UT surgery with each repeated procedure, which indicates a surgical learning curve. No intra-operative surgical complications were reported. The anaesthesia and analgesia protocols were modified as from the fifth procedure as described above. In Sow 5, the opioid dose was increased which led to a massive drug release after awakening and provoked a respiratory arrest. As a consequence, anaesthesia maintenance was modified for Sow 6 and performed with propofol instead of isoflurane, which stabilized anaesthesia and awakening.

Sow	Surgery time	Anaesthesia time	Hysterectomy time	Cold ischemia time	Warm ischemia time
1	510	570	230	74	160
2	435	495	155	55	175
3	450	510	150	75	225
4	480	540	183	82	165
5	400	455	170	60	105
6	360	405	135	65	90
Mean ± SD	439 ± 54	496 ± 59	170 ± 34	69 ± 11	153 ± 49
Coefficient of determination	0.67	0.68	0.40	0.02	0.45
p	0.05	0.04	0.18	0.82	0.14

Table 1. Duration of the different surgical steps during the uterine auto-transplant procedure in the Yucatan minipig model.

All durations are expressed in minutes as mean ± standard deviation.

Primary study endpoint

The surgical success rate was 83%: the three criteria used for the macroscopic visual assessment of uterus, *i.e.* recoloration after initial blanching, bleeding from the cut, and uterine artery pulsatility (Fig 2) was reported in five of the six UT procedures.

Sow	Initial blanching	Recolouring	Bleeding from the cut	Arterial pulsability	Transplant outcome
1	+	-	-	-	Failure
2	+	+	+	++	Success
3	+	+	+	+	Success
4	+	+	+	+	Success
5	+	+	+	++	Success
6	+	+	+	+	Success

Fig 2. Primary study endpoints recorded 30 minutes after uterine auto-transplant in the Yucatan minipig model.

The + symbol indicates a positive outcome, ++ a very positive outcome, and - the absence of the judgment criterion.

Secondary study endpoints

No significant differences were observed between the lactate, CPK, and glycemia concentrations in the external iliac vein 30 min after reperfusion between the control group and the UT group or between before and 30 min after the UT procedure. (Fig 3). Day 7 blood sampling from the left external iliac vein was not technically feasible (pelvic inflammation) in the experimental group.

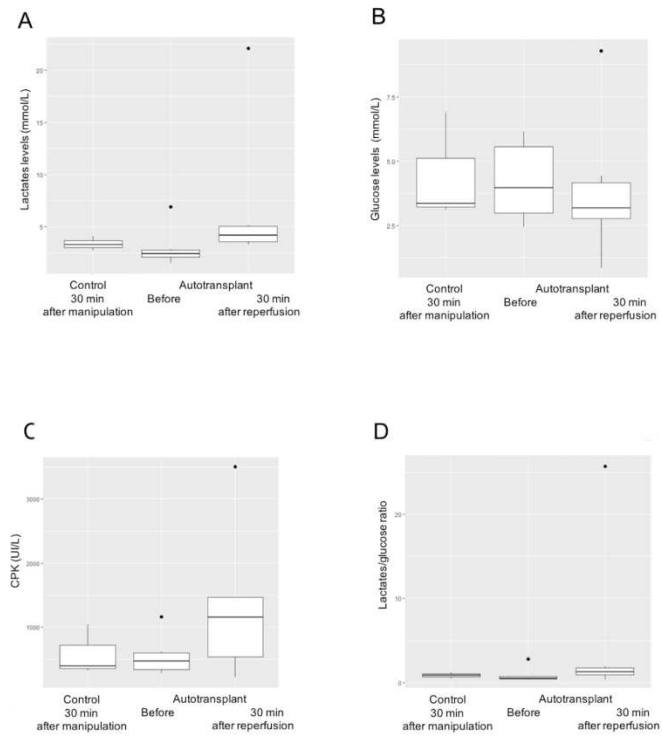


Fig 3. Biochemical parameters

From the external iliac vein 30 min after manipulation in the control group, before and 30 minutes after uterine auto-transplant in the Yucatan minipig model, including the lactates levels (A), glucose levels (B), the CPK (Creatine Phospho-Kinase) levels (C), and the lactate/glucose ratio (D).

No differences were found in terms of morphological change or inflammation when data were compared before and 30 min after UT (Fig 4). Day 7 data analysis was not performed because of the death of two sows on Day 1. For Sow 1, no blood cells were detected in the vessels on the histological sections performed 30 min after UT, which confirmed the macroscopic criteria of absence of revascularisation of the uterus after re-implantation and vascular anastomoses.

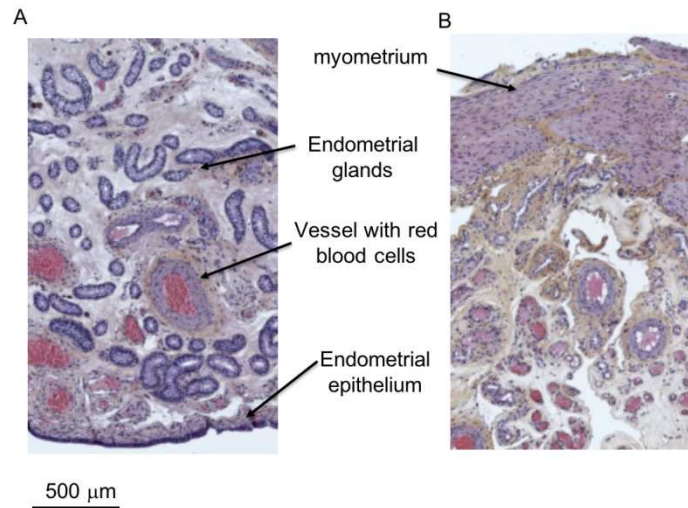


Fig 4. Hematoxylin-eosin staining of histological slices

From the left uterine horn biopsy performed before (A) and 30 minutes after (B) uterine auto-transplant in the Yucatan minipig model. Sow 2 was taken as a representative example of the situation

Post-operative outcomes

Sow 1 only resumed normal eating behaviour on Day 6. The animal was not painful and there was no sign of abscess at the scar level. Sow 2 died the day after surgery. Haemoperitoneum was found on autopsy but the vascular anastomoses were still intact. Sows 3 and 4 showed a satisfactory postoperative follow-up, resuming eating and normal transit on Days 2 and 4, respectively. Sow 3 stopped eating on Day 5. Sow 5 died during the night that followed the UT due to a respiratory arrest that was probably caused by morphine intoxication. On autopsy, the abdomen showed no evidence of haemoperitoneum and the vascular anastomoses were still intact. Complete necrosis of the uterus was observed in Sow 3 during uterine explantation on Day 7. It was not possible to access the vascular anastomoses because of pelvic inflammation. Sows 4 and 6 had a viable uterus on Day 7, with normal colouration, some bleeding observed from the cut, and pulsatile uterine arteries.

Discussion

This preclinical study performed in a Yucatan minipig model of orthotopic UT with simple ovarian venous return, without uterine venous return, showed a surgical success rate of 83% in immediate reperfusion of uterus. This demonstrates that simple ovarian venous return ensures sufficient venous drainage of the uterine graft and the viability of the graft in a new animal model. Nevertheless, the long term of viability of uterus with simple ovarian venous return have to be validated in this animal model.

While the choice of uterine arteries for perfusion of a uterine graft is consensual, the strategy used to ensure venous return differs from one human UT study to another, with the use of utero-ovarian veins[5], uterine veins[8], ovarian veins[16], or a combination of the above[6,8]. Some procedures require up to four endo-lateral venous anastomoses for the recipient. Increasing the number of vascular sutures for UT increases warm ischemia time, hence increasing the oxidative stress in the graft. During the period of warm ischemia, oxygen deprivation leads to a decrease in ATP production and to an increase in the production of free radicals[17], which can induce cytoskeletal disorders. The transmembrane ion exchange is made possible by ATP-driven proton pumps. Any disruption of ATP production will thus cause an accumulation of both sodium and calcium ions in the intracellular compartment. The accumulation of calcium ions is responsible for apoptotic cell death[18]. To preserve the uterine veins, the parameters of the uterus have to be dissected which can cause devascularization of the ureter and create fistula. This complication has been observed in four living donors after uterine explantation[5,7-9]. Thus the reduction of operative morbidity during uterus explantation in a living donor represents a major challenge for the development of UT and requires modification of the original operative technique described by the Swedish team[5]. One such modification could be to discard uterine venous return in favour of single bilateral ovarian venous return. Such a strategy presents the double benefit of decreasing the risk for ureteral wound and reducing the surgical time: the mean uterine explantation time in the donor was 697 ± 65 min in the Swedish princeps trial[5], compared with 180 min in the Indian trial published in 2019 for which the dissection of the uterine veins were abandoned in favour of the ovarian veins only[9]. This highly significant reduction in surgical duration represents a major breakthrough and simplifies the uterine explantation technique in a living donor. The aim of our study was to validate the proof of concept of this single bilateral ovarian venous return in a UT animal model before advocating this technical simplification in human medicine. Our idea has been validated by the successful completion of the UT performed by the Indian team and the birth of a healthy child in October 2018 (unpublished results). To our knowledge, our team is the first to publish a preclinical animal model to validate the proof of concept of this operative strategy.

Before starting a UT programme in women, a pertinent animal model has to be developed to better understand the difficulties of the surgical technique and all the factors surrounding the transplant procedure. Surgical training in a large animal model is highly recommended and is ethical: it increases the success rate (*i.e.*, viable graft) at the start of a UT program in women from 56% before animal training to 82% after animal training[19]. This could help prevent negative surgical outcomes such as those reported by the US team of Baylor et al. [20] who had to explant the uterus in the first three UTs they performed, or the Cleveland team who

also had to explant the uterus early after surgery[21]. In the light of these examples, prior animal experience could be highly profitable for any team who wish to start a human UT programme. In addition, our study shows that there is a learning curve for UT, with a decrease in vascular suture times (warm ischemia) as the trial progresses, from 160 min for the first sow to 90 min for the sixth. Surgical experience gained with an animal model would thus also benefit patients by shortening the whole procedure, reducing the time of warm ischemia and thus the oxidative stress of the graft. In the literature available on the pig model, the average time to perform anastomoses was similar to that in our study: 119 min for Wranning et al. [22] and 144 min for Zhang et al. [23]. In human medicine, warm ischemia time is slightly shorter, with an average of 83 min for Brännström et al. [5], 89 min for the Chinese team of Wei et al. [16], 62 min for the American team of Dallas[20], and 90 min for the Brazilian team[6].

There are several advantages and limitations of our Yucatan minipig model, and of the UT pig model in general. The first limitation is anatomical: contrary to the woman's uterus, the pig has a bicornuate uterus with two well-developed uterine horns. However, the pig has the advantage of presenting a vascular system that is very close to that of women, with a vascular tree presenting the same distribution, which makes the pig model relevant for surgical training. In addition, the Yucatan sow is much closer to humans in terms of size and body weight (65 kg in our study), compared to the rabbit[24] or rodent[25] models, for example. The ideal preclinical model for surgery remains the macaque[26-28] but there are severe ethical restrictions in the use of non-human primates for experimentation, and they are much more expensive to breed and house compared to minipigs. Another limitation of the macaque model is its limited fertility, with monthly ovulation as well as a single and long pregnancy, contrary to the pig model benefitting from a short gestation time (3 months, 3 weeks and 3 days) and large litter size (from 4-6 in the Yucatan minipig to 12-15 in the conventional pig). The pig model could also be used to assess the embryo implantation in the uterus as well as its development during gestation. Finally, another limitation of the pig auto-transplant model is the long surgical time, which makes it sometimes difficult to stabilize the anaesthesia. Such difficulties increase the risk of animal suffering as well as the need for higher doses of analgesics. In our study this might explain the death of Sow 2 immediately after surgery due to haemoperitoneum: low blood flow probably masked vascular anastomosis leakage, which was detected after anaesthesia. After adapting our anaesthesia protocol with Sow 5, we observed fatal post-surgical respiratory distress which was probably related to opioid overdosing. The propofol anaesthesia protocol used for Sow 6 proved to be suitable for the long surgical procedure in the Yucatan minipig model. In the literature, UT anaesthesia protocols in sows are similar to that used initially in our study but other methodological discrepancies make comparisons difficult. For example, contrary to our study, two previous studies did not assess graft survival and the animals were euthanized right after surgery[22,29]. In another study of UT in sows[23], the anaesthesia was maintained with isoflurane and the graft survival was evaluated several days after surgery, but an allo-transplant procedure was preferred with shorter surgery time for the recipient animal (359 min in average), which makes comparison with our own data difficult. Despite a longer surgical time in our auto-transplant model, which might have been associated with poorer peripheral

vascularisation and a weakening of the uterine graft, we obtained a success rate of 83% on UT re-implantation, which further pleads in favour of a simple bilateral ovarian venous return. Weaknesses of the study is the post-operative follow-up. But few study showed experimental design with long term uterus viability but rather no post-operative follow-up[22,29]. Furthermore, auto transplantation is a long surgical procedure for the same animal that negatively impact post-operative follow-up. Indeed, there is no intensive care unit for animal that check bleedings, blood pressure or temperature. Lastly, pig display coagulative state that lead to add preventive anticoagulation treatment to decrease thrombose rate, specially graft thrombose.

Conclusion

We found that the learning curve was relatively fast, this information is important for the development of a transplant program. Bilateral ovarian venous return alone would appear feasible for uterine graft viability in 2 sows, but long term of uterus perfusion have still to be validated by others pre-clinical studies. This variability in success may be due to anatomical variability in vessel size, that's why this venous return can be used, but after a careful pre-operative and per-operative evaluation. This opens the way to a technical simplification of the uterine explantation from a living donor, decreases the risk of ureteral wound, and reduces the duration of the surgery for both the donor and recipient. Furthermore, as the number of vascular anastomoses is reduced, warm ischemia time is also reduced, thus maximzing the chances of graft viability. Poor results can be explained by the anaesthesia difficulties, the early experience of the team and the low number of animals. In the light of what is known, animal experiments and the surgeons' experience with a large animal model is a mandatory prerequisite—from an ethical, medical and economic point of view—for any surgical team with the ambition to start a UT program in women. Similarly, the clinical development of UT would benefit from translational research programs in the same animal model used for surgical training.

Acknowledgements

The authors would like to thank the UEPR (Unité Expérimentale Porcs de Rennes), INRA St Gilles, France, and especially Mr. Serge Dubois and his team for participating in this study. The authors would like to thank the CSCGA (Centre de Simulation en Chirurgie sur le Gros Animal) for the administrative and legal management of the project. The authors would like to thank the Biomedicine Agency (call for tender 2017) and the University-Hospital of Rennes (CHU Rennes, Research Department) for financial support.

References

1. Brännström M, Johannesson L, Bokström H, Kvarnström N, Mölne J, Dahm-Kähler P, et al. Livebirth after uterus transplantation. *The Lancet*. 20 févr 2015;385(9968):607-16.
2. Brännström M, Dahm Kähler P, Greite R, Mölne J, Díaz-García C, Tullius SG. Uterus Transplantation: A Rapidly Expanding Field. *Transplantation*. avr 2018;102(4):569-77.
3. Testa G, McKenna GJ, Gunby RT, Anthony T, Koon EC, Warren AM, et al. First live birth after uterus transplantation in the United States. *Am J Transplant Off J Am Soc Transplant Am Soc Transpl Surg*. 25 mars 2018;
4. Wise J. Baby is born after uterus transplantation from dead donor. *BMJ*. 4 déc 2018;363:k5135.
5. Brännström M, Johannesson L, Dahm-Kähler P, Enskog A, Mölne J, Kvarnström N, et al. First clinical uterus transplantation trial: a six-month report. *Fertil Steril*. mai 2014;101(5):1228-36.
6. Ejzenberg D, Andraus W, Baratelli Carelli Mendes LR, Ducatti L, Song A, Tanigawa R, et al. Livebirth after uterus transplantation from a deceased donor in a recipient with uterine infertility. *The Lancet*. 22 déc 2018;392(10165):2697-704.
7. Fageeh W, Raffa H, Jabbad H, Marzouki A. Transplantation of the human uterus. *Int J Gynaecol Obstet Off Organ Int Fed Gynaecol Obstet*. mars 2002;76(3):245-51.
8. Chmel R, Novackova M, Janousek L, Matecha J, Pastor Z, Maluskova J, et al. Revaluation and lessons learned from the first nine cases of a Czech uterus transplantation trial: four deceased donor and five living donor uterus transplantations. *Am J Transplant Off J Am Soc Transplant Am Soc Transpl Surg*. 27 août 2018;
9. Puntambekar S, Puntambekar S, Telang M, Kulkarni P, Date S, Panse M, et al. A Novel Anastomotic Technique for Uterine Transplant Using Utero-ovarian Veins for Venous Drainage and Internal Iliac Arteries for Perfusion in Two Laparoscopically Harvested Uteri. *J Minim Invasive Gynecol*. 29 déc 2018;
10. Bollen P, Hansen A, Alstrup A. *The laboratory swine*. 2nd ed. Broken Sound Parkway; 2010. (CRC press).
11. Epstein M, Rodan I, Griffenhagen G, Kadrlik J, Petty M, Robertson S, et al. 2015 AAHA/AAFP Pain Management Guidelines for Dogs and Cats. *J Am Anim Hosp Assoc*. avr 2015;51(2):67-84.
12. Mahler SP, Reece JLM. Electrical nerve stimulation to facilitate placement of an indwelling catheter for repeated brachial plexus block in a traumatized dog. *Vet Anaesth Analg*. sept 2007;34(5):365-70.
13. Calzetta L, Rossi P, Bove P, Alfonsi P, Bonizzi L, Roncada P, et al. A Novel and Effective Balanced Intravenous-Inhalant Anaesthetic Protocol in Swine by Using Unrestricted Drugs. *Exp Anim*. 2014;63(4):423-33.

14. Lerman J, Jöhr M. Inhalational anesthesia vs total intravenous anesthesia (TIVA) for pediatric anesthesia. *Pediatr Anesth*. 1 mai 2009;19(5):521-34.
15. Bressan N, Moreira AP, Amorim P, Nunes CS. Target controlled infusion algorithms for anesthesia: Theory vs practical implementation. In: 2009 Annual International Conference of the IEEE Engineering in Medicine and Biology Society. 2009. p. 6234-7.
16. Wei L, Xue T, Tao K-S, Zhang G, Zhao G-Y, Yu S-Q, et al. Modified human uterus transplantation using ovarian veins for venous drainage: the first report of surgically successful robotic-assisted uterus procurement and follow-up for 12 months. *Fertil Steril*. août 2017;108(2):346-356.e1.
17. Barrou B, Chatauret N, Hauet T, Thuret R, Kleinclauss F, Timsit M-O, et al. Ischémie–reperfusion. *Liquides de conservation et machines de perfusion en transplantation rénale*. *Prog En Urol*. 1 nov 2016;26(15):964-76.
18. Peng T-I, Jou M-J. Oxidative stress caused by mitochondrial calcium overload. *Ann N Y Acad Sci*. 2010;1201(1):183-8.
19. Kisu I, Kato Y, Obara H, Matsubara K, Matoba Y, Banno K, et al. Emerging problems in uterus transplantation. *BJOG Int J Obstet Gynaecol*. 4 juin 2018;
20. Testa G, Koon EC, Johannesson L, McKenna GJ, Anthony T, Klintmalm GB, et al. Living Donor Uterus Transplantation: A Single Center's Observations and Lessons Learned From Early Setbacks to Technical Success. *Am J Transplant Off J Am Soc Transplant Am Soc Transpl Surg*. nov 2017;17(11):2901-10.
21. Flyckt R, Davis A, Farrell R, Zimberg S, Tzakis A, Falcone T. Uterine Transplantation: Surgical Innovation in the Treatment of Uterine Factor Infertility. *J Obstet Gynaecol Can JOGC J Obstet Gynecol Can JOGC*. 15 août 2017;
22. Wranning CA, El-Akouri RR, Lundmark C, Dahm-Kähler P, Mölne J, Enskog A, et al. Auto-transplantation of the uterus in the domestic pig (*Sus scrofa*): Surgical technique and early reperfusion events. *J Obstet Gynaecol Res*. août 2006;32(4):358-67.
23. Zhang X, Liu J, Wu Q, Liu Z, Yan Z. Uterus Allo-Transplantation in a Swine Model: Long-Term Graft Survival and Reproductive Function. *Med Sci Monit Int Med J Exp Clin Res*. 22 nov 2018;24:8422-9.
24. Saso S, Petts G, David AL, Thum M-Y, Chatterjee J, Vicente JS, et al. Achieving an early pregnancy following allogeneic uterine transplantation in a rabbit model. *Eur J Obstet Gynecol Reprod Biol*. févr 2015;185:164-9.
25. Wranning CA, Akhi SN, Diaz-Garcia C, Brännström M. Pregnancy after syngeneic uterus transplantation and spontaneous mating in the rat. *Hum Reprod Oxf Engl*. mars 2011;26(3):553-8.
26. Kisu I, Banno K, Mihara M, Suganuma N, Aoki D. Current status of uterus transplantation in primates and issues for clinical application. *Fertil Steril*. juill 2013;100(1):280-94.

27. Kisu I, Banno K, Mihara M, Hara H, Umene K, Adachi M, et al. A surgical technique using the ovarian vein in non-human primate models of potential living-donor surgery of uterus transplantation. *Acta Obstet Gynecol Scand.* sept 2015;94(9):942-8.
28. Kisu I, Umene K, Adachi M, Emoto K, Nogami Y, Banno K, et al. Allowable warm ischemic time and morphological and biochemical changes in uterine ischemia/reperfusion injury in cynomolgus macaque: a basic study for uterus transplantation. *Hum Reprod Oxf Engl.* 01 2017;32(10):2026-35.
29. Avison DL, DeFaria W, Tryphonopoulos P, Tekin A, Attia GR, Takahashi H, et al. Heterotopic uterus transplantation in a swine model. *Transplantation.* 27 août 2009;88(4):465-9.