



HAL
open science

Endovascular stenting for chronic femoro-iliac venous obstructive disease: Clinical efficacy and short-term outcomes

Kévin Guillen, Nicolas Falvo, Motoki Nakai, Olivier Chevallier, Serge Aho-Glélé, Christophe Galland, Emmanuel Demaistre, Lorenzo Pescatori, Maxime Samson, Sylvain Audia, et al.

► To cite this version:

Kévin Guillen, Nicolas Falvo, Motoki Nakai, Olivier Chevallier, Serge Aho-Glélé, et al.. Endovascular stenting for chronic femoro-iliac venous obstructive disease: Clinical efficacy and short-term outcomes. *Diagnostic and Interventional Imaging*, 2020, 101 (1), pp.15-23. 10.1016/j.diii.2019.03.014 . hal-03125112

HAL Id: hal-03125112

<https://hal.science/hal-03125112>

Submitted on 21 Jul 2022

HAL is a multi-disciplinary open access archive for the deposit and dissemination of scientific research documents, whether they are published or not. The documents may come from teaching and research institutions in France or abroad, or from public or private research centers.

L'archive ouverte pluridisciplinaire **HAL**, est destinée au dépôt et à la diffusion de documents scientifiques de niveau recherche, publiés ou non, émanant des établissements d'enseignement et de recherche français ou étrangers, des laboratoires publics ou privés.



Distributed under a Creative Commons Attribution - NonCommercial 4.0 International License

Endovascular stenting for chronic femoro-iliac venous obstructive disease: clinical efficacy and short-term outcomes

Kévin Guillen ¹, Nicolas Falvo ², Motoki Nakaï ¹, Olivier Chevallier ¹, Serge Aho-Glélé ³, Christophe Galland ¹, Emmanuel Demaistre ⁴, Lorenzo Pescatori ¹, Maxime Samson ⁵, Sylvain Audia ⁵, Bernard Bonnotte ⁵, Marco Midulla ¹, Romaric Loffroy ¹

1. Department of Vascular and Interventional Radiology, Image-Guided Therapy Center, Hôpital Universitaire François-Mitterrand, 21079 Dijon, France

2. Department of Angiology and Vascular Medicine, Hôpital Universitaire François-Mitterrand, 21079 Dijon, France

3. Department of Epidemiology, Statistics and Clinical Research, Hôpital Universitaire François-Mitterrand, 21079 Dijon, France

4. Department of Biological Haemostasis and Thrombosis Treatment, Hôpital Universitaire François-Mitterrand, 21079 Dijon, France

5. Department of Internal Medicine and Clinical Immunology, Hôpital Universitaire François-Mitterrand, 21079 Dijon, France

Corresponding author : Prof. Romaric Loffroy, MD, PhD

Department of Vascular and Interventional Radiology, Image-Guided Therapy Center, François-Mitterrand University Hospital, 14 Rue Paul Gaffarel, BP 77908, 21079 Dijon Cedex, France

E-mail: romaric.loffroy@chu-dijon.fr

Abstract

Purpose: To report the clinical efficacy and mid-term outcomes of endovascular treatment in patients with chronic, symptomatic, post-thrombotic femoro-iliac venous obstruction.

Materials and methods: Forty-two patients with post-thrombotic syndrome (PTS) presenting with femoro-iliac venous obstructive lesions treated in our institution by endovascular approach between March 2012 and October 2017 were retrospectively included. There were 27 women and 15 men with a mean age of 47.3 ± 17 (SD) years (range: 22-86 years). Procedure included first venous recanalization, then pre-dilatation and self-expandable metallic stenting of the narrowed or occluded iliac and/or femoral veins. Severity of PTS and quality of life were assessed at baseline and 3 months after the intervention respectively, using Villalta score and Chronic Venous Insufficiency Questionnaire (CIVIQ-20) scale. Imaging follow-up evaluation of stent patency was based on the results of duplex Doppler ultrasound and computed tomography.

Results: Immediate technical success was achieved in 41/42 (97.6%) patients, without any major complications. Primary patency, primary assisted patency and secondary patency at the end of the median imaging follow-up of 18.1 months (IQR, 9.7-34.4) were achieved in 29/42 (66.7%) patients, 33/42 (78.6%) patients and 37/42 (88.1%) patients, respectively. Median Villalta and CIVIQ-20 scores decreased from 14 (IQR, 10-19) and 57 (IQR, 39-72) at baseline, respectively, to 5 (IQR, 2-9) and 30 (IQR, 24-50) 3 months after the procedure, respectively ($P < 0.0001$), showing significant decrease in the severity of PTS and improvement in the quality of life. The multiple linear regression model showed that both baseline Villalta and CIVIQ-20 scores ([95% CI, -7.80--3.79; $P < 0.0001$] and [95% CI, 0.07-0.20; $P < 0.0001$], respectively), age (95% CI, 0.04-0.19; $P = 0.002$) and stenting expanse (95% CI, 0.97-5.65; $P = 0.006$) were independent variables related to Villalta gain. Baseline Villalta (95% CI, 0.89-2.23; $P < 0.0001$) was the single independent variable related to CIVIQ-20 gain.

Conclusion: This study confirms the high clinical efficacy and favorable mid-term outcomes of endovascular stenting in patients with chronic symptomatic femoro-iliac venous obstructive lesions.

Keywords: Post-thrombotic syndrome; Endovascular treatment; Self expandable metallic stents; Quality of life; Iliac vein.

Introduction

Deep vein thrombosis (DVT) is a major health care and socio-economical problem, with an incidence of 1 per 1,000 per year in Caucasian population [1-3]. Chronic venous conditions are mostly related to intrinsic venous obstructions and/or valvular reflux (secondary to DVT) but also to extrinsic ones [3]. Extrinsic obstructions are secondary to malignancy or rare anatomic variants such as May-Thurner syndrome [4]. Despite universal usage of anticoagulants, post-thrombotic syndrome (PTS) is the most frequent long-term complication of lower limb DVT, affecting about 23% to 60% of patients within 2 years even with an adequate treatment, major symptoms being chronic pain and edema of the lower limb. PTS is severe in 5-10% of patients, thus degrading the quality of life and inducing an economic burden [1-5]. Patients with proximal thrombosis, involving iliac veins, are more at risk of PTS. The frequency of this complication led to its definition as clinical entity by the European Venous Forum [6]. So far, there is no specific medical treatment for PTS. The outcomes of surgical procedures remain poor, leading to the first venous angioplasties in the late 90s in patients with chronic obstruction or PTS [7]. Since then, percutaneous endovascular venous recanalization techniques have shown encouraging results in terms of safety and effectiveness [2,3,5]. Still, few reports analyzed the impact of angioplasty on quality-of-life scores in patients with PTS.

The purpose of this study was to retrospectively evaluate the clinical efficacy and mid-term outcomes of endovascular treatment for PTS patients with chronic symptomatic femoro-iliac venous obstructive lesions and its impact on quality-of-life scores.

Material and methods

This study was exempted of ethic committee approval because of the observational, retrospective, non-interventional nature of the study. All endovascular procedures were routinely performed as part of clinical practice. Written informed consent was obtained from all patients.

Patients

We retrospectively analysed the files of all consecutive patients with PTS treated endovascularly between March 2012 and October 2017 for chronic symptomatic femoro-iliac venous obstructive lesions in our institution. All patients were referred to our Interventional Radiology Department for venous recanalization and angioplasty. Patients with acute

thrombosis (15 patients), non-thrombotic obstructive lesions (0 patient), mental deficiency (0 patient), age <18 years (0 patient), and both a baseline CIVIQ-20 =20 and a Villalta score ≤ 4 (0 patient) were excluded.

Our study population included 42 patients. There were 27 women and 15 men with a mean age of 47.3 ± 17 (SD) years (range: 22-86 years; median, 47.5 years; IQR, 32-60.8 years).

Preprocedure imaging evaluation

Occluded venous segments were evaluated according to the lower extremity thrombosis (LET) classification as follows: LET class I for isolated calf vein thrombosis; LET class II for femoral-popliteal vein thrombosis; LET class III for common femoral and/or iliac vein thrombosis; and LET class IV for deep vein thrombosis in the inferior vena cava [8,9]. PTS was diagnosed by their angiologist on the basis of clinical and duplex Doppler ultrasound (DUS) features. All patients had computed tomography (CT) angiography before the procedure to make an accurate assessment of location and extent of thrombosis and to evaluate presence of synechiae and morphology of collateral veins. CT acquisition was performed from the dome of diaphragm to the knees at 100 seconds after the start of intravenous administration of 80 cc³ of iomeprol (400 mg of iodine per mL; Iomeron 400[®], Bracco) through the forearm at a rate of 3-4 mL/s, followed by a saline chaser (20 mL). A 128-slice dual source CT (Definition Flash[®], Siemens Healthineers) unit was used for the acquisition, with a routine abdominopelvic CT protocol (slice thickness, 1-3 mm; 80-120 kV; 100-250 mAs). CT acquisitions were obtained in breath-hold inspiration. Multiplanar reconstructions were used for image analysis.

Villalta score and CIVIQ 20 scale evaluation

The Villalta score was used to evaluate the severity of PTS at baseline and 3 months after the procedure. The Villalta score is obtained after a clinical examination of both legs to score five symptoms (pain, heaviness, cramps, pruritus and paresthesia) and six signs (edema, induration, hyperpigmentation, new venous ectasies, redness and pain during calf compression) from 0 to 3. A total score of 0-4 indicates no PTS, a total score of 5-9 indicates mild PTS, a total score 10-14 indicates moderate PTS, and a total score ≥ 15 indicates severe PTS [10]. Pain and edema were also analyzed separately.

The Chronic Venous Insufficiency Questionnaire in 20 questions (CIVIQ 20) was used to assess the quality of life at baseline and 3 months after the procedure. Patients were asked to

complete the CIVIQ-20 consisting in 20 questions designed to assess four quality-of-life dimensions: pain (four items), physical (four items), psychological (nine items) and social (three items). Items on the CIVIQ-20 scale were scored from 1 to 5. A lower score corresponded to greater patient comfort [11]. A score of 20 corresponded to a normal quality of life and a score of 100 corresponded to a maximal quality-of-life alteration. Absolute scores could be converted into an index ranging from 0 to 100, the global index score (GIS), so as to obtain a score directly proportional to the quality of life. Therefore, an improvement of quality of life from baseline to 3 months after the procedure was represented by a decrease in CIVIQ-20 score or an increase in GIS.

Villalta score and CIVIQ-20 scale were considered the most adapted scores for our study due to their specificity in venous disease and their wide validation [10-12,13].

Endovascular intervention

All procedures were performed by 2 interventional radiologists with 15- (R.L.) and 12- (M.M.) years of experience in endovascular interventions, in an Allura Xper[®] FD 20 angio room (Philips Medical Systems). The procedure was usually performed under local anesthesia and sedation (midazolam, 1-2 g IV). Additional analgesics were systematically given during the procedure (paracetamol, 1g IV). Only 4 procedures required general anesthesia because of anxiety. All patients received 5,000 IU of heparin intravenously at the beginning of the procedure. Ipsilateral popliteal vein puncture and cannulation was the first approach, if patent. Indeed, the antegrade and direct way to the lesion made easier recanalization and perprocedural angiographic control. If not possible, contralateral transjugular vein cannulation was the rule. Selective venography of the cavo-ilio-femoral veins through a long 45-70 cm length 6-10-Fr Flexor[®] sheath (Cook Europe,) was performed (*Fig. 1*). Double approach could be required if the recanalization was difficult. Venous puncture and catheterization were always carried out under ultrasonography control. Femoro-iliac occlusion was crossed using a 0.035-inch stiff hydrophilic guidewire (Terumo Interventional Systems, Japan). Then, a 4-Fr catheter (Vertebral catheter, Cook Europe,) was used and interchanged on Amplatz[®] Super stiff guidewire (Boston Scientific). After recanalization, pre-dilation with balloons of 6, 9 and 12 mm in diameter was performed.

Second, extensive stenting was performed as previously described: stents were placed from the inferior vena cava (IVC) or common iliac vein to a stenosis-free landing zone which was often the common femoral vein (*Fig. 1*) [14,15]. If needed, the proximal femoral vein more

than the deep femoral vein was covered too, below the inguinal ligament level, according to the lesion extension. This choice was made based on the best antegrade flow into the vessel. Procedure needed from 2 to 4 stents, whose diameter ranged from 10 to 14 mm at the common femoral and external iliac veins level, and from 14 to 18 mm at the common iliac vein and IVC level, with a 60, 80, 100 or 120 mm in length. Stent diameter and length were selected on both pre-procedural imaging and procedural phlebography. In case of obstructive lesions of the contralateral common iliac vein, kissing stenting of the ilio caval bifurcation was performed. Nitinol stents were used, including Protege[®]GPS Self-Expanding Peripheral System (Covidien), and mainly Sinus-XL Flex[®] Stent (Optimed) or Sinus[®] Superflex-635 (Optimed). A final in-stent angioplasty with a 9 to 16 mm balloon was achieved to restore an optimal stent caliber. When several stents were used, a 1 cm overlap was recommended. A final venogram ensured the final positioning and stent patency (*Fig. 1*).

All patients were hospitalized overnight and returned to their normal daily activities after 24 hours. Heavy physical activities were contraindicated during 15 days. Class II compression socks were recommended for all patients. In absence of consensus, each patient received 3 months of dual-therapy: subcutaneous injections of low molecular weight heparin for 1 month followed by 2 months of antivitamin K (with a target INR of 2.0–3.0) or new oral anticoagulant medication, and antiplatelet drug (acetylsalicylic acid per os; Aspegic[®], 100 mg per day).

Clinical and imaging follow-up

Successful procedure was defined as any clinical improvement assessed according to Villalta and CIVIQ-20 scores at 3 months as described above. Patency data were evaluated with imaging studies (venography, DUS, CT). All patients had DUS examination at 1 day, 1, 3, 6, 12 months after the procedure, and every 6 months until 2 years, and then annually to evaluate the stent patency defined as antegrade and normal flow with <50% residual stenosis. CT angiography at 2 months with the same above-mentioned protocol was also systematically performed to evaluate the stents' integrity, patency and morphology.

Immediate technical success was defined as recanalization restoring patency of the target vessels with antegrade flow and <50% residual stenosis after stent placement on phlebography and confirmed by DUS at day 1. Primary patency, primary assisted patency and secondary patency rates were evaluated as previously described. Early in-stent thrombosis was defined as occlusion or >50% stenosis on DUS examination within 1 month. Late

thrombosis was over 1 month.

Based on the Society of Interventional Radiology (SIR) standards [16], complications were classified as major if they required surgery and/or prolonged hospitalization (≥ 2 weeks) and as minor otherwise. Infectious complication, allergic reaction, renal failure, pain >5 on the visual analogue scale (VAS) for pain, bleeding, thrombosis extension and pulmonary embolism, or even death were screened.

Statistical analyses

Continuous variables were described as medians (with interquartile range). Qualitative variables were described as percentages. Time trend analysis of Villalta and CIVIQ-20 scores was performed using a linear mixed model with potential confounding variables (baseline Villalta and CIVIQ-20, age, sex, body mass index [BMI], thrombophilia, stenting expanse, cause, delay from DVT, total stenting length). A robust estimate of variance was used to test the model stability. A P value of ≤ 0.05 was considered significant. Multivariate analysis was performed using a manual backward procedure. Statistical analyses were performed using STATA software (version 14.0, STATA corp.).

Results

Patient characteristics

Left/right symptomatic limb ratio was 11.3/1, and 3/42 (7.1%) patients had a bilateral iliac stenting for associated contralateral obstructive lesions of the common iliac vein with kissing stenting of the ilio caval bifurcation. PTS was related to an idiopathic thrombosis in 30/42 (71.4%) patients. An extrinsic added condition was noted in 7/42 (16.7%) patients and 5/42 (11.9%) patients were diagnosed with May-Turner syndrome. Overall, 34/42 (80.9%) patients were LET III and 30/42 (71.4%) had moderate to severe PTS. Median baseline Villalta score was 14 (IQR, 10-19) and median baseline CIVIQ 20 score was 57 (IQR, 39-72) in the whole population. Median time from thrombosis diagnosis to endovascular procedure was 31.5 months (IQR, 15.8-69.8 months) and median imaging follow-up was 18.1 months (IQR, 9.7-34.4 months). Demographics are summarized in *Table 1*.

Immediate technical success and stent patency

Median number of stents per patient was 3 (IQR, 2-4). One of the stents ran over the inferior

vena cava in 15/42 (35.7%) patients. Most of stenting procedures, in 27/42 (64.3%) patients, involved very proximal segments only (iliac-common femoral veins). Prime stenting procedure was successful with immediate technical success in 41/42 (97.6%) patients. Only 1/42 (2.4%) immediate failure of an attempt of early in-stent thrombosis recanalization was noted. No major complications occurred. Only 2/42 (4.8%) patients had minor complications as hematoma at the puncture site which resolved spontaneously.

All DUS examinations but one after prime procedure at day 1 showed permeable stents. This patient was successfully treated with thrombectomy and additional stenting. At 1 month, 34/42 (80.9%) patients had patent stents on DUS, and 8/42 (19.1%) patients had not, which required endovascular thrombectomy and extensive stenting. Overall, early in-stent thrombosis within 1 month occurred in 9/42 (21.4%) patients and was successfully managed endovascularly in 8/9 (88.9%) patients. Late thrombosis after 1 month occurred in 5/42 (11.9%) patients. In 3/5 (60%) patients, secondary recanalization attempt failed, 1/5 (20%) patients benefitted from a successful thrombectomy and extensive stenting. The last patient could so far not benefit from a secondary procedure due to complications of anticoagulants. At 3, 6, and 12 months, no other in-stent thrombosis was detected for the rest of the cohort on DUS examination. In total, primary patency, primary assisted patency and secondary patency at the end of the median follow-up of 18.1 months were achieved in 29/42 (66.7%) patients, 33/42 (78.6 %) patients and 37/42 (88.1%), respectively. Outcomes data are summarized in *Table 2*.

Villalta and CIVIQ-20 scores improvement

Villalta scale score showed a significant decrease in the severity of PTS symptoms and signs after the procedure. Mild PTS was noted in 13/42 (30.9%) patients and moderate PTS was noted in 5/42 (11.9%) patients after the procedure. Only 2/42 (4.8%) patients had severe PTS after the procedure. Villalta score was significantly decreased from baseline (median, 14; IQR, 10-19) compared with 3 months after endovascular stenting (median, 5 [IQR, 2-9]) ($P<0.0001$) (*Fig. 2*). Pain and edema scores showed significant decrease between baseline scores (median, 2 [IQR, 2-3] and median, 3 [IQR, 3-3], respectively) and scores at 3 months (median, 1 [IQR, 0-1] and median, 1 [IQR, 0-1], respectively) ($P<0.0001$). Completed pain relief was observed in 16/42 (38.1%) patients and complete edema relief was observed in 18/42 (42.8%) patients.

CIVIQ-20 scale score showed a significant improvement in the quality of life after the

procedure. Indeed, CIVIQ-20 score was significantly decreased from baseline compared with 3 months after endovascular stenting (median, 57 [IQR, 39-72] and median, 30 [IQR, 24-50], respectively) ($P<0.0001$) (Fig. 3). In other terms, from baseline to 3 months after the procedure, the median GIS increased significantly from 54 (IQR, 35-76) to 88 (IQR, 63-94) ($P<0.0001$).

Only 3/42 (7.1%) patients had complete in-stent rethrombosis at 3 months which was impossible to recanalize. Subsequently, their Villalta and CIVIQ-20 scores at 3 months were similar to those at baseline, with mild PTS for one of them and severe PTS for 2 of them.

The multiple linear regression model with robust variance estimator showed that both baseline Villalta and CIVIQ-20 scores ([95% CI, -7.80--3.79; $P<0.0001$] and [95% CI, 0.07-0.20; $P<0.0001$], respectively), age (95% CI, 0.04-0.19; $P=0.002$) and stenting expanse (95% CI, 0.97-5.65; $P=0.006$) were independent factors associated with post-procedural Villalta score and related to Villalta gain. In the robust multiple linear regression model, baseline Villalta (95% CI, 0.89-2.23; $P<0.0001$) was the only independent factor associated with post-procedural CIVIQ-20 score and related to CIVIQ-20 gain. Statistical data are summarized in Table 3 and 4.

Discussion

The present study confirms the high clinical efficacy and favorable mid-term outcomes of endovascular stenting in patients with chronic symptomatic femoro-iliac venous obstructive lesions. Immediate technical success was achieved in 41/42 (97.6%) patients, without any major complications. Early (<1 month) and late (>1 month) in-stent thrombosis occurred in 9/42 (21.4%) patients and 5/42 (11.9%) patients, respectively, and was successfully managed endovascularly in 8 and 1 of them, respectively. Primary patency, primary assisted patency and secondary patency at the end of the median imaging follow-up of 18.1 months were achieved in 29/42 (66.7%) patients, 33/42 (78.6%) patients and 37/42 (88.1%) patients, respectively. Villalta and CIVIQ-20 scores decreased from 14 and 57 at baseline, respectively, to 5 and 30 three months after the procedure, respectively ($P<0.0001$), showing significant decrease in the severity of PTS and improvement in the quality of life.

Despite optimal anticoagulant medication which is the gold standard DVT therapy, PTS remains a frequent complication of DVT and leads to significant morbidity, suffering and high health costs [17]. Endovascular treatment has become a widely accepted treatment option in chronic femoro-iliac venous obstructive lesions with high technical success rates, minimal

complications and short hospital stay as compared with conventional surgical approach [18-25]. Our results are in accordance with a meta-analysis including 1,118 patients and reporting an immediate technical success rate of 96%, comparable with that of our series [3]. Moreover, in the present study we reported an 88.1% patency rate with a median follow-up of 18.1 months comparable with that of meta-analysis (94%) with a median follow-up of 15 months. Comparison of data between studies remains difficult because of imprecise definitions of short-, mid- and long-term patency.

Despite easy endovascular management, early in-stent thrombosis within 1 month occurred in 9/42 (21.4%) patients, which is far away from the 2-10% rate reported in the literature [3,18-26]. Several factors may explain this discrepancy. First, intravascular ultrasound was not used in our study to check final results, especially stents apposition. Its use is now more documented and recommended, providing better depiction of stent malposition and predicting clinical improvement [27]. Second, the type of stents used here may be questioned. Most studies used Wallstent™ (Boston Scientific), whereas others used various types of stents. We preferentially implanted two types of nitinol stent (Protege®GPS Self-Expanding Peripheral System or mainly Sinus-XL Flex® Stent or Sinus® Superflex-635; Optimed) because of their axial and longitudinal flexibility and high radial force [14, 28]. Although the results of venous stenting with nitinol stents are supposed to be comparable to those of series using Wallstent™, no comparative study exists in the literature. There is a growing need for dedicated endovascular devices to treat pathologies affecting the venous system. However, because of a lack of research into venous diseases and treatments, the optimal design, material, and mechanical properties of venous stents remain unknown. Third, the type of anticoagulation used in our series may have influenced short-term patency. Antithrombotic treatment is an integral part of endovascular procedure [29-36]. There is no strong recommendation regarding the best treatment and its duration after venous procedure in standard patients. In this developing domain, it seems essential to estimate the effect of different post-operative drugs on the optimization of endovascular treatment. It is also important to balance the long-term risks of such a treatment with the potential benefits on stent patency.

Very few studies combined Villalta score grading PTS severity and CIVIQ-20 score being relevant for quality of life grading in chronic venous disease [37, 38]. So far, no study has analyzed factors associated with quality of life in such a setting. Ye et al. reported a significant decrease of Villalta score from 22 at baseline to 9.3 after the endovascular

procedure in accordance with our results (14 [range, 11–22] and 5 [range, 1–10], respectively) [38]. Still, this study of life quality may be considered as irrelevant due to a partial analysis of CIVIQ-20. In the study from Sarici et al., Villalta score decreased from 18 (range, 7–30) at baseline to 8 (range, 4–19) at 3 months and CIVIQ-20 (expressed in GIS) increased from 64 (range, 50–75) to 81 (range, 63–90), corroborating our data [37]. To our knowledge, our study is the first one showing first that both baseline Villalta and CIVIQ-20 scores, age and stenting expense were independent factors associated with post-procedural Villalta score, and second that baseline Villalta was the only independent factor associated with post-procedural CIVIQ-20 score. It highlights our belief that these two scores should be seen as complementary for the evaluation of PTS patients.

Our study has some limitations because of its retrospective nature. First, the variety and heterogeneity of stents used could have impacted on the mid-term outcomes. Second, some LET class I-II patients were treated in this study. It is now well-known that such patients should not be treated because outcomes are poorer. Third, calf and thigh circumferences were not considered, it could have strengthened the objectivity of edema decrease.

In conclusion, this study confirms the high technical and clinical success rates and the favorable mid-term outcomes of femoro-iliac venous angioplasty/stenting in PTS patients with symptomatic chronic venous obstructive lesions. It highlights the significant impact of recanalization on the severity of PTS and the quality of life of patients at 3 months. Indeed, the study demonstrates that endovascular treatment can lead to a decrease of the severity of PTS with quality-of-life improvement. Further studies are needed to determine the best timing for intervention and the best stent to be used in order to provide the best results. Long-term follow-up studies are also warranted.

Conflicts of interest

The authors have no conflicts of interest to disclose regarding this study.

Funding source

This study did not receive any funding.

References

- [1]. Lim CS, Shalhoub J, Davies AH. Deep venous procedures performed in the national health service in England between 2005 and 2015. *Eur J Vasc Surg* 2017;54:487-94.
- [2]. Wen-Da W, Yu Z, Yue-Xin C. Stenting for chronic obstructive venous disease: a current comprehensive meta-analysis and systematic review. *Phlebology* 2015;31:376-89.
- [3]. Razavi MK, Jaff MR, Miller LE. Safety and effectiveness of stent placement for iliofemoral venous outflow obstruction: systematic review and meta-analysis. *Circ Cardiovasc Interv* 2015;8:e002772.
- [4]. Spencer FA, Emery C, Joffe SW, Pacifico L, Lessard D, Reed G, et al., Goldberg, Incidence rates, clinical profile, and outcomes of patients with venous thromboembolism. The Worcester VTE study. *J Thromb Thrombolysis* 2009;28:401-9.
- [5]. Falcoz MT, Falvo N, Aho-Glélé S, Demaistre E, Galland C, Favelier S, et al. Endovascular stent placement for chronic post-thrombotic symptomatic ilio-femoral venous obstructive lesions: a single-center study of safety, efficacy and quality-of-life improvement. *Quant Imaging Med Surg* 2016;6:342-52.
- [6]. Kahn SR, Partsch H, Vedantham S, Prandoni P, Kearon C; Subcommittee on Control of Anticoagulation of the Scientific and Standardization Committee of the International Society on Thrombosis and Haemostasis. Definition of post-thrombotic syndrome of the leg for use in clinical investigations: a recommendation for standardization, *J Thromb Haemost* 2009;7:879-83.
- [7]. Akesson H, Brudin L, Dahlström JA, Eklöf B, Ohlin P, Plate G. Venous function assessed during a 5 year period after acute ilio-femoral venous thrombosis treated with anticoagulation. *Eur J Vasc Surg* 1990;4:43-8.

- [8]. Arnoldussen CWKP, Wittens CHA. An imaging approach to deep vein thrombosis and the lower extremity thrombosis classification. *Phlebology* 2012;27:143-8.
- [9]. Strijkers RHW, Arnoldussen CWKP, Wittens CHA. Validation of the LET classification. *Phlebology* 2015;30:14-9.
- [10]. Strijkers RHW, Wittens CHA, Kahn SR. Villalta scale: goals and limitations, *Phlebology* 2012;27:130-5.
- [11]. Launois R, Mansilha, A Jantet G. International psychometric validation of the chronic venous disease quality of life questionnaire (CIVIQ-20). *Eur J Vasc Endovasc Surg* 2010;40:783-9.
- [12]. Launois R, Mansilha A, Lozano F. Linguistic validation of the 20 item-chronic venous disease quality-of-life questionnaire (CIVIQ-20). *Phlebology* 2013;29:484-7.
- [13]. Vedantham S, Grassi CJ, Ferral H, Patel NH, Thorpe PE, Antonacci VP, et al. Reporting standards for endovascular treatment of lower extremity deep vein thrombosis. *J Vasc Interv Radiol* 2009;20:S391–408.
- [14]. Duda SH, Wiskirchen J, Tepe G, Bitzer M, Kaulich TW, Stoeckel D, et al., Physical properties of endovascular stents: an experimental comparison. *J Vasc Interv Radiol* 2000;11:645-54.
- [15]. Neglén P, Hollis KC, Olivier J, Raju S. Stenting of the venous outflow in chronic venous disease: long-term stent-related outcome, clinical, and hemodynamic result. *J Vasc Surg* 2007;46:979-90.
- [16]. Patel N, Sacks D, Patel RI, Moresco KP, Ouriel K, Gray R, et al. SIR reporting standards for the treatment of acute limb ischemia with use of transluminal removal of arterial thrombus. *J Vasc Interv Radiol* 2003;14:S453-65.
- [17]. Ashrani AA, Heit JA. Incidence and cost burden of post-thrombotic syndrome. *J Thromb Thrombolysis* 2009;28:465-76.

- [18]. Hartung O, Otero A, Boufi M, De Caridi G, Barthelemy P, Juhan C, et al. Mid-term results of endovascular treatment for symptomatic chronic nonmalignant ilio caval venous occlusive disease. *J Vasc Surg* 2005;42:1138-44.
- [19]. Seager MJ, Busuttill A, Dharmarajah B, Davies AH. Editor's choice - A systematic review of endovenous stenting in chronic venous disease secondary to iliac vein obstruction. *Eur J Vasc Endovasc Surg* 2015;51:100-20.
- [20]. Murphy EH, Johns B, Varney E, Raju S. Endovascular management of chronic total occlusions of the inferior vena cava and iliac veins. *J Vasc Surg Venous Lymph Disord* 2017;5:47-59.
- [21]. Moeini M, Zafarghandi MR, Shahbandari M, Sayarifard M, Taghavi M, Salimi J, et al. Venoplasty and venous stenting in patients with chronic venous insufficiency in the lower extremities. *J Tehran Heart Cent* 2016;11:174-80.
- [22]. O'Dea J, Schainfeld RM. Venous interventions. *Circ Cardiovasc Interv* 2014;7:256-65.
- [23]. van Vuuren TMAJ, de Wolf MAF, Arnoldussen CWKP, Kurstjens RLM, van Laanen JHH, Jalaie H, et al. Editor's Choice - Reconstruction of the femoro-ilio-caval outflow by percutaneous and hybrid interventions in symptomatic deep venous obstruction. *Eur J Vasc Endovasc Surg* 2017;54:495-503.
- [24]. Oguzkurt L, Tercan F, Ozkan U, Gulcan O. Iliac vein compression syndrome: outcome of endovascular treatment with long-term follow-up. *Eur J Radiol* 2008;68:487-92.
- [25]. Shi WY, Gu JP, Liu CJ, He X, Lou WS. Endovascular treatment for iliac vein compression syndrome with or without lower extremity deep vein thrombosis: a retrospective study on mid-term in-stent patency from a single center. *Eur J Radiol* 2016;85:7-14.
- [26]. Neglén P, Tackett Jr TP, Raju S. Venous stenting across the inguinal ligament. *J Vasc Surg* 2008;48:1255-61.

- [27]. Gagne PJ, Gasparis A, Black S, Thorpe P, Passman M, Vedantham S, et al. Analysis of threshold stenosis by multiplanar venogram and intravascular ultrasound examination for predicting clinical improvement after iliofemoral vein stenting in the VIDIO trial. *J Vasc Surg Venous Lymphat Disord* 2018;6:48-56.e1.
- [28]. de Wolf MAF, de Graaf R, Kurstjens RLM, Penninx S, Jalaie H, Wittens CHA. Short-term clinical experience with a dedicated venous nitinol stent: initial results with the sinus-venous stent. *Eur J Vasc Endovasc Surg* 2015;50:518-26.
- [29]. Khairy SA, Neves RJ, Hartung O, O'Sullivan GJ. Factors associated with contralateral deep venous thrombosis after iliocaval venous stenting. *Eur J Vasc Endovasc Surg* 2017;54:745-51.
- [30]. Langwieser N, Bernlochner I, Wustrow I, Dirschinger RJ, Jaitner J, Dommasch M, et al. Combination of factor Xa inhibition and antiplatelet therapy after stenting in patients with iliofemoral post-thrombotic venous obstruction. *Phlebology* 2015;31:430-7.
- [31]. Meissner MH. Indications for platelet aggregation inhibitors after venous stents. *Phlebology* 2013;28:91-8.
- [32]. Delis KT, Bjarnason H, Wennberg PW, Rooke TW, Gloviczki P. Successful iliac vein and inferior vena cava stenting ameliorates venous claudication and improves venous outflow, calf muscle pump function, and clinical status in post-thrombotic syndrome. *Ann Surg* 2007;245:130-9.
- [33]. Kölbel T, Gottsäter A, Kühme T, Lindh M, Ivancev K. Endovascular treatment of venous occlusive disease. *Ann Vasc Dis* 2008;1:91-101.
- [34]. Rosales A, Sandbæk G, Jørgensen JJ. Stenting for chronic post-thrombotic vena cava and iliofemoral venous occlusions: mid-term patency and clinical outcome. *Eur J Vasc Endovasc Surg* 2010;40:234-40.

- [35]. Neglén P, Raju S. Balloon dilation and stenting of chronic iliac vein obstruction: technical aspects and early clinical outcome. *J Endovasc Ther* 2000;7:79-91.
- [36]. Kearon C, Kahn SR, Agnelli G, Goldhaber S, Raskob GE, Comerota AJ. Antithrombotic therapy for venous thromboembolic disease. *Chest* 2008;133:454S-545S.
- [37]. Sarici IS, Yanar F, Agcaoglu O, Ucar A, Poyanli A, Cakir S, et al. Our early experience with iliofemoral vein stenting in patients with post-thrombotic syndrome. *Phlebology* 2014;29:298-303.
- [38]. Ye K, Lu X, Jiang M, Yang X, Li W, Huang Y, et al. Technical details and clinical outcomes of transpopliteal venous stent placement for postthrombotic chronic total occlusion of the iliofemoral vein. *J Vasc Interv Radiol* 2014;25:925-32.

Figure captions

Figure 1. Endovascular recanalization in a 31-year-old woman with post-thrombotic syndrome (PTS), baseline Villalta and CIVIQ-20 scores were 10 and 59, respectively. **A**, Initial computed tomography (CT) image in the axial plane shows left femoro-iliac vein narrowing (*white arrow*) compared to the normal right side (*black arrow*). **B**, Baseline venography in a supine position by popliteal approach confirming left common femoro-iliac vein obstruction with collaterality (*white arrows*). **C**, Recanalization and deployment of 3 nitinol stents of 14, 12 and 10 mm in diameter, recalibrated by angioplasty (*white arrows*). **D**, Final venogram showing stent patency and disappearance of pelvic varicosities (*white arrows*). **E**, CT angiography with three-dimensional volume-rendering technique reconstructions at 3 months shows well-positioned stents and patency stent (*white arrows*) (E). Post-procedural Villalta and CIVIQ-20 scores at 3 months were 3 and 32, respectively, demonstrating significant quality-of-life improvement.

Figure 2. Villalta score graph change at 3 months. Villalta score graph shows significant Villalta score decrease from baseline (median, 14 [IQR, 10-19]) to 3 months after the endovascular procedure (median, 5 [IQR, 2-9]) ($P<0.0001$). Bars from top to bottom in the plot boxes correspond to maximum, Q3, median, Q1 and minimum.

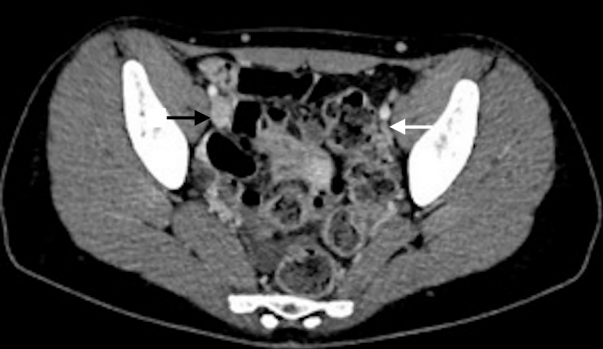Figure 3. CIVIQ-20 score graph change at 3 months. CIVIQ-20 score graph shows significant CIVIQ-20 score decrease from baseline (median, 57 [IQR, 39-72]) to 3 months after the endovascular procedure (median, 30 [IQR, 24-50]) ($P<0.0001$). Bars from top to bottom in the box plots correspond to maximum, Q3, median, Q1 and minimum.

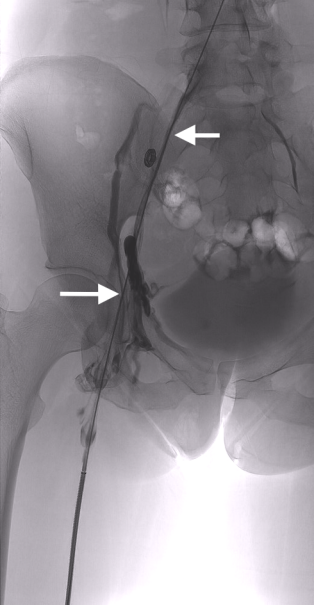
Table 1. Demographics of 42 patients with post-thrombotic syndrome presenting with femoro-iliac venous obstructive lesions treated by endovascular approach.

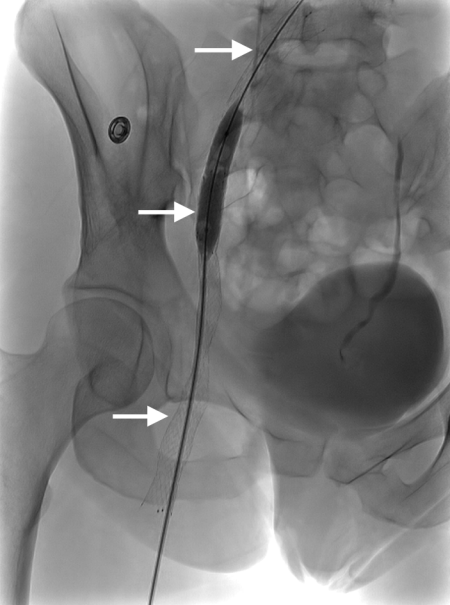
Table 2. Outcomes data of 42 patients with post-thrombotic syndrome presenting with femoro-iliac venous obstructive lesions treated by endovascular approach.

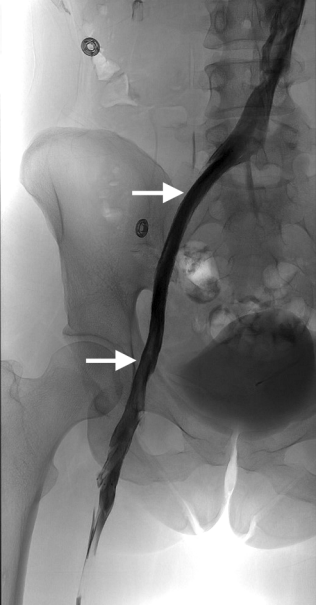
Table 3. Factors independently associated with post-procedural Villalta in the multivariate analysis and the robust multiple linear regression model.

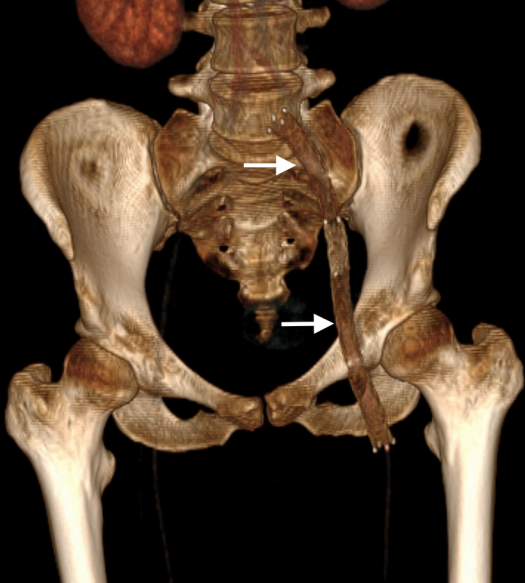
Table 4. Factors independently associated with post-procedural CIVIQ-20 in the multivariate analysis and the robust multiple linear regression model.

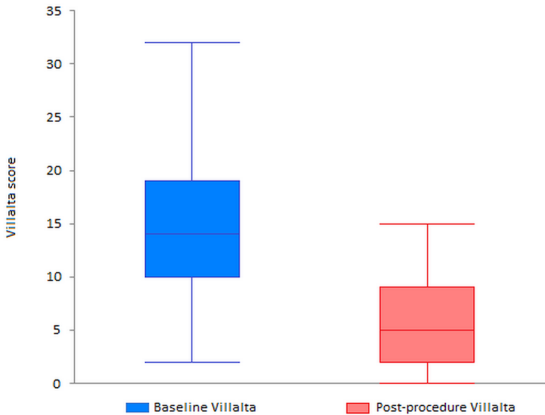


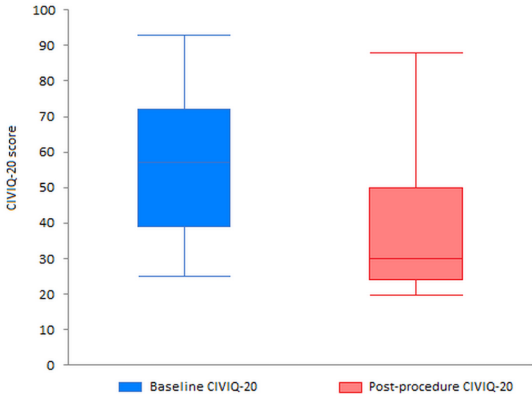












Variable	
Median age (years) (IQR)	47.5 (32, 60.8)
Gender	
<i>Female</i>	27/42 (64.2%)
<i>Male</i>	15/42 (35.7%)
DVT location	
<i>LET I-II</i>	1/42 (2.4%)
<i>LET II-III</i>	14/42 (33.3%)
<i>LET I-II-III</i>	5/42 (11.9%)
<i>LET III</i>	15/42 (35.7%)
<i>LET II-III-IV</i>	1/42 (2.4%)
<i>LET III-IV</i>	3/42 (7.1%)
Cause	
<i>Thrombosis only</i>	30/42 (71.4%)
<i>Extrinsic condition added</i>	7/42 (16.7%)
<i>May Thurner</i>	5/42 (11.9%)
Side of intervention	
<i>Left</i>	31/42 (73.8%)
<i>Right</i>	8/42 (19.0%)
<i>Both sides</i>	3/42 (7.1%)
BMI	
<30	29/42 (69.0%)
>30	13/42 (30.9%)
Median delay from DVT (months) (IQR)	31.5 (13.8, 69.8)
Median baseline Villalta (score) (IQR)	14 (10, 19)
<i>Mild PTS</i>	7/42 (16.6%)
<i>Moderate PTS</i>	14/42 (33.3%)
<i>Severe PTS</i>	16/42 (38.1%)
Median baseline CIVIQ-20 (IQR)	57 (39, 72)

Note. IQR = interquartile range; DVT=deep vein thrombosis; LET = lower extremity thrombosis classification; BMI = body mass index; PTS = post-thrombotic syndrome; CIVIQ-20 = chronic venous disease quality of life questionnaire.

Outcomes data

Stenting zone	
<i>Iliac-common femoral veins</i>	28/42 (66.7%)
<i>Femoral vein</i>	12/42 (28.6%)
<i>Sus-popliteal vein</i>	2/42 (4.8%)
Median imaging follow-up (months) (IQR)	18.1 (9.7, 34.4)
Immediate technical success	41/42 (97.6%)
Long-term secondary patency at follow-up	37/42 (88.1%)
Median post-procedural Villalta* (score) (IQR)	5 (2, 9)
<i>Mild PTS</i>	13/42 (30.9%)
<i>Moderate PTS</i>	5/42 (11.9%)
<i>Severe PTS</i>	2/42 (4.8%)
Median post-procedural CIVIQ-20* (score) (IQR)	30 (24, 50)

Note . IQR = interquartile range; PTS = post-thrombotic syndrome; CIVIQ-20 = chronic venous disease quality of life questionnaire, * at 3 months.

Variables	P	95% CI
Multivariate analysis		
<i>Baseline Villalta</i>	0.000	-10.16--6.24
<i>Delay from DVT</i>	0.029	0.00-0.02
<i>Age</i>	0.010	0.02-0.19
<i>Gender</i>	0.592	-2.12-3.73
<i>BMI</i>	0.002	0.12 -0.50
<i>Cause</i>	0.307	-5.60-1.57
<i>Stenting expanse*</i>	0.005	1.36-7.66
<i>Total stenting length</i>	0.850	-1.59-1.93
<i>Thrombophilia</i>	0.972	-3.73-3.60
<i>Baseline CIVIQ-20</i>	0.000	0.06-0.19
Robust multiple linear regression model		
<i>Baseline Villalta</i>	0.000	-7.80--3.79
<i>BMI</i>	0.326	-0.11-0.34
<i>Baseline CIVIQ-20</i>	0.000	0.07-0.20
<i>Delay from DVT</i>	0.315	-0.01-0.01
<i>Stenting expanse</i>	0.006	0.97-5.65
<i>Age</i>	0.002	0.04-0.19

Footnote: DVT, deep vein thrombosis; BMI, body mass index; CIVIQ-20, chronic venous disease quality of life questionnaire, * corresponds to additional covering of the femoral vein as landing zone.

Variables	P	95% CI
Multivariate analysis		
<i>Baseline CIVIQ-20</i>	0.000	-10.16--6.24
<i>Delay from DVT</i>	0.678	-0.04-0.07
<i>Age</i>	0.755	-0.31-0.43
<i>Gender</i>	0.058	-0.36-21.36
<i>BMI</i>	0.241	-0.32-1.28
<i>Cause</i>	0.806	-38.24-19.14
<i>Stenting expanse*</i>	0.025	1.49-22.76
<i>Total stenting length</i>	0.632	-4.29-7.06
<i>Thrombophilia</i>	0.102	-22.08-1.99
<i>Baseline CIVIQ-20</i>	0.000	-24.12-11.55
Robust multiple linear regression model		
<i>Baseline CIVIQ-20</i>	0.137	-13.39-1.83
<i>Sexe</i>	0.062	-0.45-19.17
<i>Baseline Villalta</i>	0.000	0.89-2.23
<i>Stenting expanse</i>	0.266	-3.99-14.50

Footnote: CIVIQ-20, chronic venous disease quality of life questionnaire; DVT, deep vein thrombosis; BMI, body mass index, * corresponds to additional covering of the femoral vein as landing zone.