



HAL
open science

Diagnostic performance of sacroiliac and spinal MRI for the diagnosis of non-radiographic axial spondyloarthritis in patients with inflammatory back pain

Inès Herrada, Hervé Devilliers, Christine Fayolle, Grégoire Attané, Romaric Loffroy, Frank Verhoeven, Paul Ornetti, André Ramon

► To cite this version:

Inès Herrada, Hervé Devilliers, Christine Fayolle, Grégoire Attané, Romaric Loffroy, et al.. Diagnostic performance of sacroiliac and spinal MRI for the diagnosis of non-radiographic axial spondyloarthritis in patients with inflammatory back pain. *Joint Bone Spine*, 2021, 88 (2), pp.105106. 10.1016/j.jbspin.2020.105106 . hal-03124946

HAL Id: hal-03124946

<https://hal.science/hal-03124946>

Submitted on 3 Feb 2023

HAL is a multi-disciplinary open access archive for the deposit and dissemination of scientific research documents, whether they are published or not. The documents may come from teaching and research institutions in France or abroad, or from public or private research centers.

L'archive ouverte pluridisciplinaire **HAL**, est destinée au dépôt et à la diffusion de documents scientifiques de niveau recherche, publiés ou non, émanant des établissements d'enseignement et de recherche français ou étrangers, des laboratoires publics ou privés.



Distributed under a Creative Commons Attribution - NonCommercial 4.0 International License

Diagnostic performance of sacroiliac and spinal MRI for the diagnosis of non-radiographic axial spondyloarthritis in patients with inflammatory back pain

Inès Herrada¹, Herve Devilliers^{2,3}, Christine Fayolle¹, Grégoire Attané⁴, Romaric Loffroy⁴, Frank Verhoeven⁵, Paul Ornetti^{1,6,7}, André Ramon^{1,8}

1. *Rheumatology Department, CHU Dijon-Burgundy, Dijon, France*
2. *Department of Internal Medicine and Systemic Diseases, Dijon-Burgundy University Hospital, Dijon, France*
3. *Centre d'Investigation Clinique, INSERM, CIC 1432, University of Bourgogne-Franche Comté, Dijon, France*
4. *Diagnostic and Therapeutic Radiology Department, Dijon-Burgundy University Hospital, Dijon, France*
5. *Rheumatology Department, CHU Besançon, EA 4267 PEPITE, FHU INCREASE, University of Bourgogne-Franche Comté, Besançon, France*
6. *INSERM UMR1093-CAPS, Université Bourgogne, UFR des Sciences du Sport, Dijon, France*
7. *CIC-P, Plurithematic Module, Technological Investigation Platform, Dijon-Burgundy University Hospital, Dijon, France*
8. *INSERM EFS BFC, UMR1098, University of Bourgogne-Franche Comté, Dijon, France*

Correspondence

Dr André RAMON

Rheumatology Department, CHU Dijon
14 rue Gaffarel, 21000 Dijon
Tel (33) 3 80 29 37 45
Fax (33) 3 80 29 36 78
Mail: andre.ramon@chu-dijon.fr

Abstract:

Objective

The lack of specificity of the ASAS MRI criteria for non-radiographic axial spondylarthritis (NR-axSpA) justifies the evaluation of the discriminatory capacity of other MRI abnormalities in the sacroiliac joints and dorsolumbar spine.

Methods

In patients hospitalized for inflammatory lumbar back pain, the diagnostic performance (sensitivity, specificity, positive likelihood ratio (PLR)) of MRI abnormalities was calculated using the rheumatologist expert opinion as a reference:

- Sacroiliac joints: Bone marrow edema (BME) (number and location), extended edema >1cm (deep lesion), fatty metaplasia (number), erosion (number and location), backfill.
- Dorsolumbar spine: BME (number and location), fatty metaplasia (number), posterior segment involvement.

Results

In this prospective cohort, 40 NR-axSpA cases and 79 other diagnoses were included. The presence of at least 3 inflammatory signals in the sacroiliac joints (PLR: 25.67 [95% CI: 3.48-48.9]), the presence of at least one sacroiliac erosion (PLR: 12.80 [3.04-54]), the combination of an inflammatory signal and sacroiliac erosion (PLR: 11.85 [2.79-50]), the combination of deep lesion and fatty metaplasia (PLR: 15.80 [2.05-121.9]) or erosion (PLR: 11.86 [1.47-95.01]) had the best diagnostic performance. The combination of spinal and sacroiliac MRI criteria significantly increased diagnostic performance for the diagnosis of NR-axSpA.

Conclusion

When NR-axSpA is suspected, in addition to the presence and number of inflammatory lesions, MRI interpretation should include the location and the extent of the sacroiliac lesions, the presence of erosion or fatty metaplasia, and anterior involvement of the lumbar spine.

Keywords: MRI; diagnostic performance; sacroiliac joint; non-radiographic axial spondyloarthritis

Introduction

The diagnosis of non-radiographic axial spondyloarthritis (NR-axSpA) remains a challenge because of the heterogeneous clinical presentations and the frequency of differential diagnoses such as osteoarthritis of the spine. The involvement of the sacroiliac (SI) joints has become an important part of confirming a diagnosis of NR-axSpA, which explains the primordial role of MRI, the reference imaging method for detecting both active and inflammatory lesions using T2-weighting with fat signal suppression or short-TI inversion recovery (STIR) (1). In clinical practice, when sacroiliac MRI is inconclusive, dorsolumbar MRI could be of interest (2,3).

When patients present inflammatory lower back pain compatible with NR-axSpA, the use of sacroiliac MRI and the lack of specificity of the ASAS definition of sacroiliitis has led to over-diagnosis of the condition (4,5). In misdiagnosed patients, this can lead to inappropriate and costly background treatments such as biotherapies. A recent systematic review of the literature has evaluated the diagnostic utility of MRI in SpA and the importance of quantifying different inflammatory and structural parameters, and the influence of their anatomical localization (6). Thirty-one studies were included, the majority of which demonstrated that sacroiliac bone marrow edema (BME) remained the most sensitive lesion for the diagnosis of SpA. Recently, the concept of inflammatory "deep lesions" has been developed, corresponding to STIR edema extending more than 1 cm from the sacroiliac joint space. This feature has the advantage of being easy to measure and relatively specific to spondyloarthritis (7). Other MRI signs, which were not often used until recently, provide a better understanding of the structural damage caused by SpA, such as the notion of "backfill", which corresponds to filling tissue within the erosion, earlier than subchondral sclerosis or ankylosis. Other advances in MRI sequences, such as the *Volumetric Interpolated Breath hold Examination* (VIBE) sequence, may better characterize sacroiliac joint erosion on MRI. VIBE sequence performance was found to be similar to that of a sacroiliac CT scan in a population of SpA sacroiliitis (8), thus eliminating the need for CT as a complementary examination.

Despite all of these technical advances, non-inflammatory lesions such as fatty metaplasia (9,10), subchondral erosions (11), and backfill (12) are insufficiently taken into account in difficult diagnoses where MRI interpretation is crucial, and the level of interpretation remains inhomogeneous among rheumatologists and radiologists alike. In this context, we evaluated a prospective monocentric cohort of patients hospitalized for suspected NR-axSpA in order to identify the diagnostic performance of different inflammatory and structural dorsolumbar and sacroiliac MRI lesions, alone or in combination.

Methods

This monocentric prospective observational study was carried out in the rheumatology department of a French university hospital from January 2016 to October 2019. The final diagnosis of NR-axSpA was confirmed by the collegial opinion of three senior rheumatologists using the patient's entire clinical record (presence, nature

and progression of symptoms since their appearance, response to treatment, biological and imaging results). The inclusion criteria were as follows: patients ≥ 18 years old, referred to hospital with suspicion of NR-axSpA, presenting inflammatory axial pain for ≥ 3 months, without radiographic sacroiliitis according to modified New York criteria (13) and having undergone a standardized MRI protocol of the sacroiliac joints and the dorsolumbar spine on the same MRI (Siemens TRIO 3 Tesla).

MRI interpretation

A double MRI reading of the sacroiliac joints and dorsolumbar spine was performed by two physicians with expertise in osteoarticular imaging, blinded to clinical data, having validated an international training in MRI reading of the sacroiliac joints and the spine in order to homogenize their MRI reading (<https://www.carearthritis.com/mriportal>) (14). In the event of a discrepancy, a third expert decided whether or not to retain the MRI abnormalities.

For sacroiliac MRI, the MRI sequences followed the protocol proposed by the ASAS (1): T1 weighting SE coronal oblique, T2 weighting with fat signal suppression (or STIR), axial and coronal oblique.

- *BME*: hypersignal in STIR sequence (axial and coronal) in the subchondral bone with semi-quantitative scoring (1, 2 or ≥ 3 hypersignals) and scoring of the location (anterior or posterior portion of the joint, the limit of which was defined by the ligament portion of the joint).

- *Deep lesion*: extended STIR hypersignal (axial or coronal) (7).

- *Fatty metaplasia*: homogeneous hypersignal of more than 1 cm in T1 weighting in subchondral bone with semi-quantitative scoring (1, 2 or ≥ 3 hypersignals). The interforaminal sacral signal of the bone marrow was the reference for the attribution of a normal signal in the bone.

- *Subchondral erosion*: irregularities in the subchondral bone at the sacroiliac joint with hypersignal bone defect T1 SE, with semi quantitative scoring (1, 2 or ≥ 3 erosions) and localization according to the anterior or posterior portion of the joint.

- "*Backfill*" (12): T1 weighted hypersignal in the erosion cavity, corresponding to the fatty metaplasia of the filling tissue that develops in the space left by erosion in place of the cortical sacral or iliac bone.

For dorsolumbar MRI, the T1 and T2 weighting sequences with fat signal suppression (or STIR) in the sagittal section were analysed:

- *BME*: hypersignal in STIR sequence on vertebral corners with semi quantitative rating (1, 2 or ≥ 3 hypersignals, considering each inflammatory corner separately per vertebra).

- *Interspinous bursitis*: hypersignal in STIR sequence between the dorsal or lumbar spines, without distinction.

-*Posterior articular arthritis*: hypersignal in STIR sequence in front of the dorsal or lumbar-posterior articular joint (bone oedema +/- effusion or articular synovitis)

- *Fatty metaplasia*: presence at the vertebral corners of a hypersignal, T1 weighted with a semi-quantitative rating isolation.

MODIC 1 and 2 vertebral injuries related to degenerative disc diseases were systematically excluded from this MRI analysis.

Statistical analysis

The number of subjects needed was estimated at 42 patients in each group for an α risk 0.05 under the unilateral assumption that MRI abnormalities should be more frequent in the NR-axSpA group. The inter-observer reproducibility (Cohen's Kappa coefficient/ICC) of lesions observed on MRI was calculated for both readers (0.81 - 1.00: excellent; 0.61 - 0.80: good; 0.41 - 0.60: moderate) (15).

Demographic, clinical, biological and MRI data were described in terms of percentages and numbers (qualitative) or means and standard deviations (quantitative). Independent quantitative variables were compared between the NR-axSpA group and the "other diagnoses" group using a Student's T-test, qualitative variables were compared using a Fischer's exact test, and qualitative variables were ordered using a Mann-Whitney test.

The diagnostic performance (sensitivity, specificity, positive likelihood ratio (PLR) (with a PLR considered good if > 4) of each of the different MRI parameters were calculated taking as gold standard the opinion of the college of rheumatology experts. The diagnostic performance of the combination of inflammatory and structural abnormalities (sacroiliac MRI alone, dorsolumbar MRI alone, and combination sacroiliac + dorsolumbar MRI) was studied using the area under the curve (AUC) of ROC curves from estimates from a logistic regression model whose dependent variable was the final diagnosis of NR-axSpA and the independent variables :

- For sacroiliac joints: association of BME, erosions, fatty metaplasia, and backfill.

- For the spine: association of BME, fatty metaplasia, interspinous bursitis, and posterior articular arthritis.

The diagnostic performance of the MRI abnormalities of interest were compared using a McNemar test for matched proportions. Confidence intervals (95%CI) of diagnostic performance were calculated according to the binomial law.

Results

Among the 119 patients included (average age 47 years), a final diagnosis of NR-axSpA was confirmed by the college of rheumatologists in 40 cases (38 met the modified Amor criteria and 32 met the ASAS criteria). The remaining 79 diagnoses were: spine osteoarthritis (n=43), other chronic inflammatory rheumatism (n=15),

fibromyalgia (n=15) and osteitis condensans ilii (n=6) (18 patients met the modified Amor criteria and 12 patients met the ASAS criteria).

39.5% of patients had MRI sacroiliitis according to the ASAS criteria (55% of NR-axSpA and 30.4% among other diagnoses).

In the NR-axSpA group (24 women/16 men), 62.5% were HLA B27 carriers, and 22.5% had an inflammatory syndrome (mean CRP 5.7 ± 7.1 mg/L). Eleven patients (27.5%) were treated with non-steroidal anti-inflammatory drugs (NSAIDs) and 10 (25%) with anti-TNF- α within 15 days prior to the MRI.

In the "other diagnoses" group (55 women/24 men), HLAB27 was positive in 12.6% of patients, there was an inflammatory syndrome in 30.4% of cases (mean CRP 5.8 ± 5.6 mg/dl). Fifteen patients (18.9%) were treated with NSAIDs and 5 (6%) with anti-TNF α within 15 days prior to the MRI.

No clinical differences were found between the two groups except for the duration of symptom progression, which was greater in the NR-axSpA group (8.2 ± 6.3 years vs. 5.1 ± 4.5 years, $p = 0.006$), the presence of HLA B27 (62.5% vs. 12.6%, $p < 0.0001$), and anti-TNF α treatment ($p = 0.0003$).

Inter-observer reproducibility between the two osteoarticular imaging experts was considered good to excellent for all MRI abnormalities but varied according to type: deep lesion (kappa: 0.89 [95% CI : 0.74;1.0]), sacroiliac BME (ICC: 0.96 [95% CI:0.95;0.98]), erosion (ICC: 0.95 [95%CI:0.93; 0.96]), sacroiliac metaplasia (ICC: 0.94 [95% CI: 0.91;0.96]), backfill (kappa: 0.64 [95% CI: 0.53;0.74]), spinal BME (ICC: 0.99 [95% CI:0.99;0.99]), spinal metaplasia (ICC : 0.95 [95% CI: 0.93;0.96]), interspinous bursitis (kappa: 0.85 [95% CI: 0.64;1.0]), posterior articular arthritis (kappa: 0.79 [95% CI: 0.56;0.95]).

The performance of the combined sacroiliac and dorsolumbar spinal MRI parameters (both inflammatory and structural) is shown in Figure 1 (ROC curves and areas under the curve (AUC)). The combination of spinal MRI and sacroiliac MRI significantly increased diagnostic performance for NR-axSpA when compared with sacroiliac MRI alone (AUC 0.94 [95% CI: 0.90-0.98] vs. AUC 0.85 [95% CI: 0.77-0.92], $p < 0.05$). However, taken alone, MRI of the lumbar spine had more modest diagnostic performance, with an AUC 0.75 [95% CI 0.67-0.84].

For the sacroiliac joints (Table 1), the MRI parameters significantly associated with the final diagnosis of NR-axSpA were the presence of a deep lesion ($p < 0.001$), the presence of ≥ 1 ($p < 0.05$) or especially ≥ 3 inflammatory lesions ($p < 0.001$) of the sacroiliac joints in STIR, the presence of localized posterior edema, the presence of ≥ 1 erosion ($p < 0.001$) or ≥ 3 erosions ($p < 0.001$) in sacroiliac joints, the presence of ≥ 1 ($p = 0.003$) or ≥ 3 fatty metaplasias ($p < 0.01$) and the presence of backfill ($p < 0.001$) (but low prevalence).

For the dorsolumbar spine (Table 2), the MRI parameters significantly associated with the diagnosis of NR-axSpA were the presence of ≥ 3 lumbar inflammatory lesions, and ≥ 3 inflammatory or fatty lesions.

The performance of MRI criterion taken alone or in combination in the sacroiliac joints (Tables 3 and 4) and the dorsolumbar spine [Appendix A, Table S1-S2; See the supplementary material associated with this article online] made it possible to identify the most discriminating parameters for the interpretation of MRI when NR-axSpA is suspected. No dorsolumbar MRI parameter (alone or combined) reached a PLR > 4 . On the other hand, when we analyzed the results for the sacroiliac joints, deep lesions, BME range number ≥ 3 , and

posterior BME localization and the presence of T1-weighted erosions performed well, taken alone or in combination (inflammatory lesion + structural lesion), with a PLR > 4.

Discussion

This prospective study of the diagnostic performance of different inflammatory and structural MRI parameters illustrates the difficulties that are regularly encountered when attempting to diagnose of non-radiographic axial spondyloarthritis. We underline a specific patient phenotype for NR-axSpA, which includes a female predominance, already reported in other cohorts (16-18), mean age > 45 years, a low frequency of HLA B27 positivity (62.5%) compared to other cohorts of NR-axSpA such as GESPIC (74.1%) (18) or DESIR (83.2%) (16) and a long progression.

Sacroiliac BME was unsurprisingly the most sensitive lesion (55%) for the diagnosis of NR-axSpA of all the parameters studied, but was less sensitive than generally reported (>70%) (6,19,20). The threshold of ≥ 3 inflammatory lesions, arbitrary but already reported, appears to be an effective marker, with a significant increase in specificity (0.99) and a PLR at 25.67, even at the price of a decrease in sensitivity, when the objective is above all to assert the diagnosis in complex forms. In the literature, specificity varies from 75% to 97% depending on the different definitions of BME and the number of affected areas (6). However, our study confirms the significant proportion of sacroiliac BME (30.4%) in patients with conditions like sacroiliac osteoarthritis which can lead to false positive results for NR-axSpA. Studies have found similar results (21) (22) with 20-30% false positive results in primary care lumbago patients and 40% in patients with postpartum pain or certain types of athletes (23,24). The location of the edema is an important consideration because in the "other diagnoses" group the edema was preferentially anterior (92%), while posterior involvement was highly specific for NR-axSpA, which has already been reported (6). Deep lesions, which have been reported as very specific markers (97%), were not very sensitive in our cohort (30%), and there were false positives, especially in cases of osteitis condensans ilii (80% of cases with deep lesions), which had not been reported until now (25).

In terms of structural lesions, erosion seems to be the most informative type of lesion because of its specificity (97%). It was found in 32% of SpA patients vs only 2% of patients with other diagnoses, which is similar to the literature data (26). The presence of at least 3 erosions was highly specific for SpA (spe = 100%). The analysis of fatty metaplasia, which is poorly reproducible, yielded disappointing results. Only the threshold of ≥ 3 appears to have good predictive value, but it is too rare in practice, much like backfill (12), to be discriminating in patients with lower back pain due to inflammation. These results are consistent with those of a cross-sectional study using the DESIR cohort in which the authors compared "typical" sacroiliac radiographic and MRI abnormalities (inflammatory and structural, SPARCC scoring) observed in patients with recent axial spondyloarthritis versus a population of chronic degenerative lower back pain (ILOS cohort) (27). However, the study of the combination of inflammatory and structural parameters did not significantly increase sensitivity in our cohort. Weber et al. reported a specificity of 0.80 and sensitivity of 0.83 for the association of ≥ 3 inflammatory lesions and ≥ 3 erosions (11), but this combination was very rare in our non-radiographic axial spondyloarthritis population.

As expected, MRI of the spine alone was less effective than MRI of the sacroiliac joints (28,29). In our cohort, the threshold of ≥ 3 inflammatory corners (present in only 25% of NR-axSpA) was associated with a high specificity (89%). Weber et al. found similar results, with a specificity of 0.95 and a sensitivity between 0.15 and 0.30, but for ≥ 5 inflammatory wedges (30). However, these inflammatory lesions are frequent in spinal osteoarthritis and their frequency increases with age, as demonstrated in the study by Molto et al. (27), who compared the DESIR and ILOS (degenerative lower back pain) cohorts and found no significant difference in spinal MRI abnormalities (inflammatory wedges, erosions or fatty metaplasia) between the two groups.

We recognize that this observational study has some limitations: recruitment in a single university center is not representative of NR-axSpA in the general population but corresponds to the phenotype that poses a diagnostic problem in current practice, especially when the possibility of biotherapy is raised, which was the case for many of the patients included. The reference SPARCC MRI type rating for sacroiliitis in clinical research (31) was not used because it is not transposable in daily practice to interpret an MRI due to its complexity. The sacroiliac CT scan was not performed as the gold standard for analysis of sacroiliac erosions (32) because this radiographic examination was not systematically possible in a routine care study. Furthermore, the diagnosis used by the college of rheumatologists was dichotomous (SpA: yes/no). A numerical or semi-quantitative scale could have been proposed according to the level of diagnostic certainty, as in other studies (33), but this would have made it more difficult to compare the diagnostic performance of each MRI parameter. Finally, some patients in both groups were treated with NSAIDs and/or anti TNF- α therapy at the time of MRI, which may have led to an underestimation of inflammatory lesions, as reported in the literature (34) (35). This should not however affect the results for the other evaluated MRI parameters.

In conclusion, these results remind us of the importance of focusing not only on BME, the basis of the definition of sacroiliitis MRI according to ASAS criteria, but also on T1-weighted structural damage (fatty metaplasia, erosions, backfill) and the potential added value of supplementing with a dorsolumbar MRI. Recent technological advances such as diffusion MRI with the evaluation of a diffusion coefficient for edema or the T1 VIBE sequence, which has excellent spatial resolution for erosion, are promising (36,37). This exploratory study and its preliminary results are intended to lead to a multicenter study with a larger sample size, but until then our findings support clinicians in their work and should help them to interpret the different types of MRI lesions and their localization in order to diagnose NR-axSpA in challenging cases.

Conflicts of interest: The authors do not declare any conflict of interest.

Acknowledgements: We thank Suzanne Rankin from the Dijon University Hospital for proofreading the article.

Appendix A. Supplementary data

Supplementary data (Table S1-S2) associated with this article can be found in the online version at

...

References

1. Rudwaleit M, Jurik AG, Hermann K-GA, Landewé R, van der Heijde D, Baraliakos X, et al. Defining active sacroiliitis on magnetic resonance imaging (MRI) for classification of axial spondyloarthritis: a consensual approach by the ASAS/OMERACT MRI group. *Ann Rheum Dis*. 2009;68:1520-7.
2. Marzo-Ortega H, McGonagle D, O'Connor P, Hensor EMA, Bennett AN, Green MJ, et al. Baseline and 1-year magnetic resonance imaging of the sacroiliac joint and lumbar spine in very early inflammatory back pain. Relationship between symptoms, HLA-B27 and disease extent and persistence. *Ann Rheum Dis*. 2009;68:1721-7.
3. Althoff CE, Sieper J, Song I-H, Haibel H, Weiß A, Diekhoff T, et al. Active inflammation and structural change in early active axial spondyloarthritis as detected by whole-body MRI. *Ann Rheum Dis*. 2013;72:967-73.
4. Claudepierre P, Wendling D, Breban M, Goupille P, Dougados M. Ankylosing spondylitis, spondyloarthropathy, spondyloarthritis, or spondylarthritis: what's in a name? *Joint Bone Spine*. 2012;79:534-5.
5. Pialat J-B, Di Marco L, Feydy A, Peyron C, Porta B, Himpens P-H, et al. Sacroiliac joints imaging in axial spondyloarthritis. *Diagn Interv Imaging*. 2016;97:697-708.
6. Jones A, Bray TJP, Mandl P, Hall-Craggs MA, Marzo-Ortega H, Machado PM. Performance of magnetic resonance imaging in the diagnosis of axial spondyloarthritis: a systematic literature review. *Rheumatology (Oxford)*. 2019;58:1955-65.
7. de Winter J, de Hooge M, van de Sande M, de Jong H, van Hoeven L, de Koning A, et al. Magnetic Resonance Imaging of the Sacroiliac Joints Indicating Sacroiliitis According to the Assessment of SpondyloArthritis international Society Definition in Healthy Individuals, Runners, and Women With Postpartum Back Pain. *Arthritis Rheumatol*. 2018;70:1042-8.
8. Diekhoff T, Greese J, Sieper J, Poddubnyy D, Hamm B, Hermann K-GA. Improved detection of erosions in the sacroiliac joints on MRI with volumetric interpolated breath-hold examination (VIBE): results from the SIMACT study. *Ann Rheum Dis*. 2018;77:1585-9.
9. de Hooge M, van den Berg R, Navarro-Compán V, Reijnierse M, van Gaalen F, Fagerli K, et al. Patients with chronic back pain of short duration from the SPACE cohort: Which MRI structural lesions in the sacroiliac joints and inflammatory and structural lesions in the spine are most specific for axial spondyloarthritis? *Ann Rheum Dis*. 2016;75:1308-14.
10. Weber U, Pedersen SJ, Zubler V, Rufibach K, Chan SM, Lambert RGW, et al. Fat infiltration on magnetic resonance imaging of the sacroiliac joints has limited diagnostic utility in nonradiographic axial spondyloarthritis. *J Rheumatol*. 2014;41:75-83.
11. Weber U, Østergaard M, Lambert RGW, Pedersen SJ, Chan SM, Zubler V, et al. Candidate lesion-based criteria for defining a positive sacroiliac joint MRI in two cohorts of patients with axial spondyloarthritis. *Ann Rheum Dis*. 2015;74:1976-82.
12. Hu Z, Wang X, Qi J, Kong Q, Zhao M, Gu J. Backfill is a specific sign of axial spondyloarthritis seen on MRI. *Joint Bone Spine*. 2016;83:179-83.
13. van der Linden S, Valkenburg HA, Cats A. Evaluation of diagnostic criteria for ankylosing spondylitis. A proposal for modification of the New York criteria. *Arthritis Rheum*. 1984;27:361-8.

14. Maksymowych WP. The role of imaging in the diagnosis and management of axial spondyloarthritis. *Nat Rev Rheumatol*. 2019;15:657-72.
15. Sim J, Wright CC. The kappa statistic in reliability studies: use, interpretation, and sample size requirements. *Phys Ther*. 2005;85:257-68.
16. Dougados M, d'Agostino M-A, Benessiano J, Berenbaum F, Breban M, Claudepierre P, et al. The DESIR cohort: a 10-year follow-up of early inflammatory back pain in France: study design and baseline characteristics of the 708 recruited patients. *Joint Bone Spine*. 2011;78:598-603.
17. Kiltz U, Baraliakos X, Karakostas P, Igelmann M, Kalthoff L, Klink C, et al. Do patients with non-radiographic axial spondylarthritis differ from patients with ankylosing spondylitis? *Arthritis Care Res (Hoboken)*. 2012;64:1415-22.
18. Rudwaleit M, Haibel H, Baraliakos X, Listing J, Märker-Hermann E, Zeidler H, et al. The early disease stage in axial spondylarthritis: results from the German Spondyloarthritis Inception Cohort. *Arthritis Rheum*. 2009;60:717-27.
19. Sieper J, van der Heijde D, Dougados M, Mease PJ, Maksymowych WP, Brown MA, et al. Efficacy and safety of adalimumab in patients with non-radiographic axial spondyloarthritis: results of a randomised placebo-controlled trial (ABILITY-1). *Ann Rheum Dis*. 2013;72:815-22.
20. Sieper J, van der Heijde D, Dougados M, Maksymowych WP, Scott BB, Boice JA, et al. A randomized, double-blind, placebo-controlled, sixteen-week study of subcutaneous golimumab in patients with active nonradiographic axial spondyloarthritis. *Arthritis Rheumatol*. 2015;67:2702-12.
21. Arnbak B, Grethe Jurik A, Hørslev-Petersen K, Hendricks O, Hermansen LT, Loft AG, et al. Associations Between Spondyloarthritis Features and Magnetic Resonance Imaging Findings: A Cross-Sectional Analysis of 1,020 Patients With Persistent Low Back Pain. *Arthritis Rheumatol*. 2016;68:892-900.
22. Baraliakos X, Richter A, Feldmann D, Ott A, Buelow R, Schmidt CO, et al. Frequency of MRI changes suggestive of axial spondyloarthritis in the axial skeleton in a large population-based cohort of individuals aged <45 years. *Ann Rheum Dis*. 2020;79:186-92.
23. Weber U, Jurik AG, Zejden A, Larsen E, Jørgensen SH, Rufibach K, et al. Frequency and Anatomic Distribution of Magnetic Resonance Imaging Features in the Sacroiliac Joints of Young Athletes: Exploring "Background Noise" Toward a Data-Driven Definition of Sacroiliitis in Early Spondyloarthritis. *Arthritis Rheumatol*. 2018;70:736-45.
24. Eshed I, Miloh-Raz H, Dulitzki M, Lidar Z, Aharoni D, Liberman B, et al. Peripartum changes of the sacroiliac joints on MRI: increasing mechanical load correlating with signs of edema and inflammation kindling spondyloarthropathy in the genetically prone. *Clin Rheumatol*. 2015;34:1419-26.
25. Ma L, Gao Z, Zhong Y, Meng Q. Osteitis condensans ilii may demonstrate bone marrow edema on sacroiliac joint magnetic resonance imaging. *Int J Rheum Dis*. 2018;21:299-307.
26. Wick MC, Weiss RJ, Jaschke W, Klauser AS. Erosions are the most relevant magnetic resonance imaging features in quantification of sacroiliac joints in ankylosing spondylitis. *J Rheumatol*. 2010;37:622-7.
27. Molto A, Gossec L, Lefèvre-Colau M-M, Foltz V, Beaufort R, Laredo J-D, et al. Evaluation of the performances of 'typical' imaging abnormalities of axial spondyloarthritis: results of the cross-sectional ILOS-DESIR study. *RMD Open*. 2019;5: e000918.

28. Hu Z, Xu M, Lin Z, Liao Z, Deng X, Zhang Y, et al. Limitations of lumbar spine MRI in the diagnosis of ankylosing spondylitis. *Clin Exp Rheumatol*. 2014;32:22-7.
29. Weber U, Zhao Z, Rufibach K, Zubler V, Lambert RGW, Chan SM, et al. Diagnostic utility of candidate definitions for demonstrating axial spondyloarthritis on magnetic resonance imaging of the spine. *Arthritis Rheumatol*. 2015;67:924-33.
30. Weber U, Zubler V, Zhao Z, Lambert RGW, Chan SM, Pedersen SJ, et al. Does spinal MRI add incremental diagnostic value to MRI of the sacroiliac joints alone in patients with non-radiographic axial spondyloarthritis? *Ann Rheum Dis*. 2015;74:985-92.
31. Maksymowych WP, Inman RD, Salonen D, Dhillon SS, Williams M, Stone M, et al. Spondyloarthritis research Consortium of Canada magnetic resonance imaging index for assessment of sacroiliac joint inflammation in ankylosing spondylitis. *Arthritis Rheum*. 2005;53:703-9.
32. Devauchelle-Pensec V, D'Agostino MA, Marion J, Lapierre M, Jousse-Joulin S, Colin D, et al. Computed tomography scanning facilitates the diagnosis of sacroiliitis in patients with suspected spondylarthritis: results of a prospective multicenter French cohort study. *Arthritis Rheum*. 2012;64:1412-9.
33. Gazeau P, Cornec D, Timsit MA, Dougados M, Saraux A. Classification criteria versus physician's opinion for considering a patient with inflammatory back pain as suffering from spondyloarthritis. *Joint Bone Spine*. 2018;85:85-91.
34. Jarrett SJ, Sivera F, Cawkwell LS, Marzo-Ortega H, McGonagle D, Hensor E, et al. MRI and clinical findings in patients with ankylosing spondylitis eligible for anti-tumour necrosis factor therapy after a short course of etoricoxib. *Ann Rheum Dis*. 2009;68:1466-9.
35. van der Heijde D, Baraliakos X, Hermann K-GA, Landewé RBM, Machado PM, Maksymowych WP, et al. Limited radiographic progression and sustained reductions in MRI inflammation in patients with axial spondyloarthritis: 4-year imaging outcomes from the RAPID-axSpA phase III randomised trial. *Ann Rheum Dis*. 2018;77:699-705.
36. Bozgeyik Z, Ozgocmen S, Kocakoc E. Role of diffusion-weighted MRI in the detection of early active sacroiliitis. *AJR Am J Roentgenol*. 2008;191:980-6.
37. Baraliakos X, Hoffmann F, Deng X, Wang Y-Y, Huang F, Braun J. Detection of Erosions in Sacroiliac Joints of Patients with Axial Spondyloarthritis Using the Magnetic Resonance Imaging Volumetric Interpolated Breath-hold Examination. *J Rheumatol*. 2019;46:1445-9.

Table 1. Comparison of frequency of inflammatory and structural MRI signs in the sacroiliac joints (non-radiographic axial SpA (NR-axSpA) vs other diagnoses).

	NR-axSpA (n=40) n(%)	Other diagnoses (n=79) n(%)
INFLAMMATORY LESIONS		
- Deep lesion	12/40 (30.0)	5/79 (6.3)*
- ≥ 1	22/40 (55.0)	24/79 (30.4)**
- ≥ 3	13/40 (32.5)	1/79 (1.3)*
Location		
- Anterior	10/22 (45.4)	22/24 (91.7)
- Posterior	12/22 (54.5)	2/24 (8.3)*
SUB CHONDRAL EROSIONS		
- ≥ 1	13/40 (32.5)	2/79 (2.5)*
- ≥ 3	5/40 (12.5)	0*
Location		
- Anterior	6/13 (46.2)	2/2 (100)**
- Posterior	8/13 (61.5)	0*
FATTY METAPLASIA		
- ≥ 1	23/40 (57.5)	22/79 (27.8)***
- ≥ 3	10/40 (25.0)	5/79 (6.3)***
BACKFILL	6/40 (15.0)	0*

*P values : McNemar test for matched proportions. * p<0.001; **p<0.05; ***p<0.01*

Table 2. Comparison of the frequency of inflammatory and structural MRI signs in the dorso-lumbar spine (non-radiographic axial SpA (NR-axSpA) (vs. other diagnoses).

	NR-axSpA (n=40) n (%)	Other diagnoses (n=79) n(%)
INFLAMMATORY LESIONS		
Lumbar		
- ≥ 1	10/40 (25.0)	17/79 (21.5)
- ≥ 3	8/40 (20.0)	5/79 (6.3)*
Dorso-lumbar hinge		
- ≥ 1	3/40 (7.5)	9/79 (11.4)
- ≥ 3	3/40 (7.5)	0*
Total		
- ≥ 1	9/40 (22.5)	18/79 (22.8)
- ≥ 3	10/40 (25)	8/79 (10.1)
FATTY METAPLASIA		
- ≥ 1	8/40 (20.0)	28/79 (35.4)
- ≥ 3	13/40 (32.5)	7/79 (8.9)**
INTERSPINOUS BURSITIS		
	3/40 (7.5)	9/79 (11.4)
POSTERIOR ARTICULAR ARTHRITIS		
	5/40 (12.5)	8/79 (10.1)

*P values : McNemar test for matched proportions. *p<0.05;** p<0.01*

Table 3. Diagnostic performance of inflammatory and structural MRI signs in the sacroiliac joints.

	Specificity (95%CI)	Sensitivity (95%CI)	PLR (95%CI)
INFLAMMATORY LESIONS			
- Deep lesion	0.94 (0.89-0.98)	0.30 (0.22-0.38)	4.74 (1.79-12.5)
- ≥ 1	0.70 (0.58-0.79)	0.55 (0.39-0.69)	1.81 (1.17-2.80)
- ≥ 3	0.99 (0.97-1.01)	0.33 (0.24-0.41)	25.67 (3.48-18.9)
- Anterior	0.73 (0.62-0.82)	0.23 (0.12-0.38)	0.85 (0.43-1.67)
- Posterior	0.96 (0.89-0.99)	0.30 (0.17-0.46)	8.55 (2.58-28.3)
EROSION			
- ≥ 1	0.97 (0.95-1.0)	0.37 (0.29-0.46)	12.80 (3.04-54)
- ≥ 3	1.0 (0.95-1.0)	0.13 (0.054-0.26)	nc
- Anterior	0.97 (0.91-0.99)	0.15 (0.07-0.29)	5.92 (1.25-28)
- Posterior	1.0 (0.95-1.0)	0.2 (0.13-0.27)	nc
FATTY METAPLASIA			
- ≥ 1	0.72 (0.61-0.80)	0.57 (0.42-0.71)	2.01 (1.29-3.1)
- ≥ 3	0.94 (0.86-0.97)	0.25 (0.14-0.40)	3.95 (1.44-10.7)
BACKFILL	1.0 (0.95-1.0)	0.15 (0.09-0.21)	nc

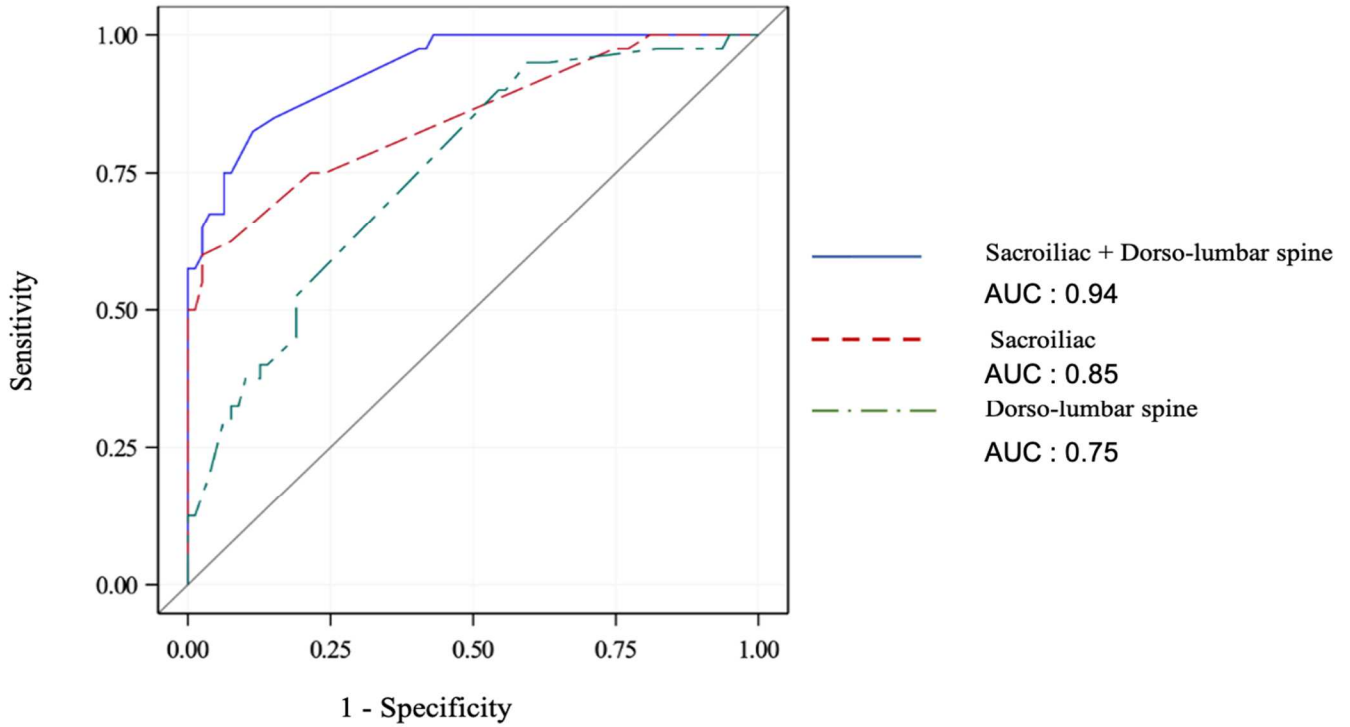
Table 4. Diagnostic performance of combination of inflammatory and structural MRI signs in the sacroiliac joints.

	Specificity (95%CI)	Sensitivity (95%CI)	PLR (95%CI)	
≥ 1 BME + ≥ 1 ERO	0.97 (0.91-0.99)	0.30 (0.18-0.45)	11.85 (2.79-50.0)	
	0.91 (0.82-0.95)	0.38 (0.24-0.53)	4.20 (1.87-9.50)	
	1.0 (0.95-1.0)	0.13 (0.07-0.29)	nc	
≥ 3 BME + ≥ 1 ERO	1.0 (0.95-1.0)	0.20 (0.11-0.35)	nc	
	1.0 (0.95-1.0)	0.25 (0.14-0.40)	nc	
	1.0 (0.95-1.0)	0.13 (0.06-0.26)	nc	
Deep lesion +	≥ 3 BME	1.0 (0.95-1.0)	0.25 (0.14-0.40)	nc
	≥ 1 ERO	0.98 (0.93-0.99)	0.15 (0.07-0.29)	11.86 (1.47-95.01)
	≥ 1 FM	0.98 (0.93-0.99)	0.20 (0.11-0.35)	15.80 (2.05-121.9)
	BF	1.0 (0.95-1.0)	0.08 (0.03-0.19)	nc

ERO = erosion; FM = fatty metaplasia; BF = backfill; BME = Bone marrow oedema; nc = not calculable

FIGURE

Figure 1. Comparative analysis of diagnostic performance of combined inflammatory and structural abnormalities from sacroiliac (SI) MRI vs dorso-lumbar spine MRI vs combined MRI (ROC* and area under the curve (AUC)).



	AUC (95%CI)	
SI + spine MRI	0.94 (0.90-0.98)	p = 0.006
SI MRI	0.85 (0.77-0.92)	
Spine MRI	0.75 (0.67-0.84)	

*The ROC curves were plotted from estimates from a logistic regression model where the dependent variable was the final diagnosis of NR-axSpA and the independent variables:

- for sacroiliacs: BME, erosions, fatty metaplasia, backfill

- for the dorso-lumbar spine: BME, fatty metaplasia, interspinous bursitis, posterior articular arthritis