



HAL
open science

Paroxysmal Dyskinesias Revealing 3-Hydroxy-Isobutyryl-CoA Hydrolase (HIBCH) Deficiency

Marie-Aude Spitz, Guy Lenaers, Majida Charif, Thomas Wirth, Jameleddine Chelly, Marie-Thérèse Abi-Warde, Pierre Meyer, Nicolas Leboucq, Elise Schaefer, Mathieu Anheim, et al.

► **To cite this version:**

Marie-Aude Spitz, Guy Lenaers, Majida Charif, Thomas Wirth, Jameleddine Chelly, et al.. Paroxysmal Dyskinesias Revealing 3-Hydroxy-Isobutyryl-CoA Hydrolase (HIBCH) Deficiency. *Neuropediatrics*, 2021, 52 (5), pp.410-414. 10.1055/s-0040-1722678 . hal-03124166

HAL Id: hal-03124166

<https://hal.science/hal-03124166v1>

Submitted on 22 Jun 2023

HAL is a multi-disciplinary open access archive for the deposit and dissemination of scientific research documents, whether they are published or not. The documents may come from teaching and research institutions in France or abroad, or from public or private research centers.

L'archive ouverte pluridisciplinaire **HAL**, est destinée au dépôt et à la diffusion de documents scientifiques de niveau recherche, publiés ou non, émanant des établissements d'enseignement et de recherche français ou étrangers, des laboratoires publics ou privés.

Paroxysmal Dyskinesias Revealing 3-Hydroxy- Isobutyryl-CoA Hydrolase (HIBCH) Deficiency

Marie-Aude Spitz¹_ Guy Lenaers² Majida Charif² Thomas Wirth^{3,4,5} Jameleddine Chelly⁴
Marie-Thérèse Abi-Warde¹ Pierre Meyer⁶ Nicolas Leboucq⁷ Elise Schaefer⁸ Mathieu
Anheim³ Agathe Roubertie^{6,9}

1 Service de Pédiatrie 1, CHRU Strasbourg, Strasbourg, France

2 Équipe Mitolab, Institut MITOVASC, INSERM U1083, CNRS 6015, Université d'Angers, Angers, France

3 Service de Neurologie, CHRU Strasbourg, Strasbourg, France

4 Institut de Génétique et de Biologie Moléculaire et Cellulaire (IGBMC), UMR 7104 CNRS/Unistra, INSERM U1258, Illkirch, France

5 Unit of Functional Neurosurgery, National Hospital for Neurology and Neurosurgery, London, United Kingdom

6 Département de Neuropédiatrie, CHU Gui de Chauliac, Montpellier, France

7 Service de Neuroradiologie, Hôpital Gui de Chauliac, CHRU Montpellier, Montpellier, France

8 Service de Génétique Médicale, CHRU Strasbourg, Strasbourg, France

9 INSERM U 1051, Institut des Neurosciences de Montpellier, Montpellier, France

Address for correspondence

Marie-Aude Spitz, MD, Service de Pédiatrie 1, CHRU Hautepierre, Avenue Molière, 67098 STRASBOURG Cedex, France (e-mail: marie-aude.spitz@chru-strasbourg.fr).

Keywords

Paroxysmal; dyskinesias, HIBCH deficiency, mild phenotype, NGS.

--

Abstract

Paroxysmal dyskinesias (PD) are rare movement disorders characterized by recurrent attacks of dystonia, chorea, athetosis, or their combination, with large phenotypic and genetic heterogeneity. 3-Hydroxy-isobutyryl-CoA hydrolase (HIBCH) deficiency is a neurodegenerative disease characterized in most patients by a continuous decline in psychomotor abilities or a secondary regression triggered by febrile infections and metabolic crises. We describe two PD patients from two pedigrees, both carrying a homozygous c.913A>G, p.Thr305Ala mutation in the HIBCH gene, associated with an unusual clinical presentation. The first patient presented in the second year of life with right paroxysmal hemidystonia lasting for 30 minutes, without any loss of consciousness and without any triggering factor. The second patient has presented since the age of 3 recurrent exercise-induced PD episodes which have been described as abnormal equinovarus, contractures of the lower limbs, lasting for 1 to 4 hours, associated with choreic movements of the hands. Their neurological examination and metabolic screening were normal, while brain magnetic resonance imaging showed abnormal signal of the pallidi.

We suggest that HIBCH deficiency, through the accumulation of metabolic intermediates of the valine catabolic pathway, leads to a secondary defect in respiratory chain activity and pyruvate dehydrogenase (PDH) activity and to a broad phenotypic spectrum ranging from Leigh syndrome to milder phenotypes. The two patients presented herein expand the spectrum of the disease to include unusual paroxysmal phenotypes and HIBCH deficiency should be considered in the diagnostic strategy of PD to enable adequate preventive treatment.

Introduction

Paroxysmal dyskinesias (PD) are movement disorders with recurrent attacks of involuntary dystonia, chorea, athetosis, or their combination, without loss of consciousness.^{1,2} These disorders are traditionally classified in three subtypes encompassing paroxysmal kinesigenic dyskinesia, paroxysmal non-kinesigenic dyskinesia, and paroxysmal exercise-induced dyskinesia (PED). Recent reports have shown evidence of clinical and genetical heterogeneity in PD.³ 3-Hydroxy-isobutyryl-CoA hydrolase (HIBCH) deficiency is a rare neurodegenerative disease characterized by a continuous decline in the psychomotor capabilities^{4,5} or by secondary regression triggered by febrile infections and metabolic crisis,⁵ and leading usually to early death or severe impairment. Xu et al⁶ recently described that HIBCH deficiency could be responsible for PD. Schottmann et al⁷ also described a milder phenotype of the disease. Here, we describe two novel PD patients from two geographically distinct regions who harbor the same homozygous HIBCH mutation and further expand the clinical spectrum of this recent entity.

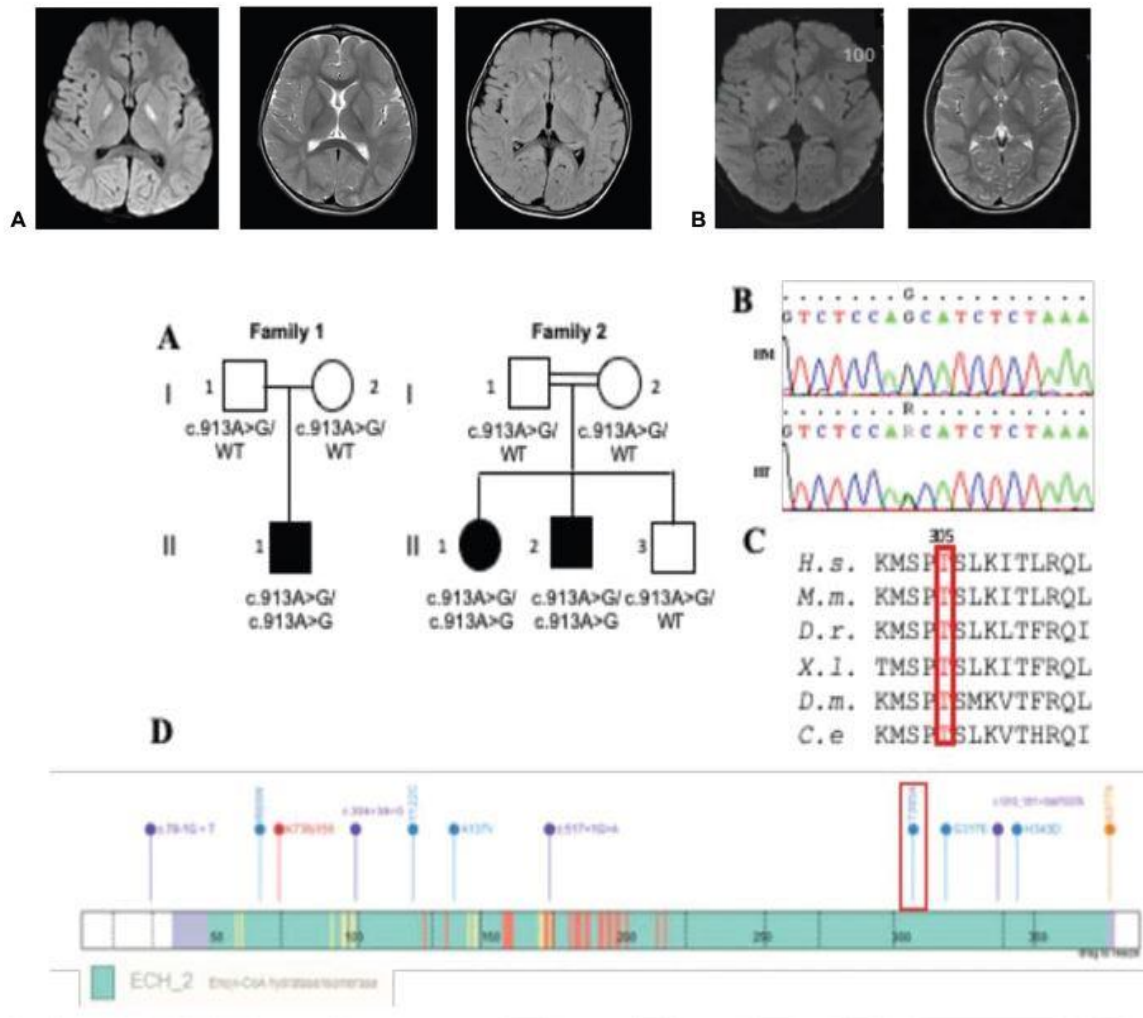


Fig. 1 (A) Brain magnetic resonance imaging (MRI) of patient 1: diffusion, T2, and fluid-attenuated inversion recovery (FLAIR) hyperintensity in the globi pallidi. (B) Brain MRI of patient 2: diffusion and T2 hyperintensity in the globi pallidi. (C) Segregation of the HIBCH mutation, and evolutionary conservation and localization of the amino acid changes: A: Pedigree showing the segregation of the HIBCH: c.913A>G (p.Thr305Ala) mutation in the families; black symbols indicate affected patients. B: Electropherograms showing the homozygous and heterozygous sequence of HIBCH. C: Evolutionary conservation of the p.Thr305 residues (in red) and their neighbor amino acids in eukaryotic HIBCH sequences of metazoans (Homosapiens, Musmusculus, Xenopus laevis, and Danio rerio) and invertebrates (Drosophila melanogaster and Caenorhabditis elegans). D: Localization of HIBCH mutations in the protein: the structures of HIBCH protein (enoyl-CoA hydratase/isomerase domain and amino acid positions) are described with all the pathogenic missense (green) and nonsense (violet) mutations reported to date and in present case (in red).

Methods and Clinical Reports

Molecular Analysis

Genomic deoxyribonucleic acid from peripheral blood samples was extracted according to standard procedures. An exome capture kit (SeqCap EZ Exome probes; Roche-Nimble Gen)

was used to target all exons, followed by massive parallel 150 pb paired-end sequencing (Illumina, San Diego, California, United States). Read mapping and variant calling were performed following standard bioinformatics procedures.⁸ Filtering and prioritization of the variants were conducted using an in-house interactive Paris Descartes bioinformatics platform pipeline based on the Ensemble database (release 67).⁹ Variants were filtered according to their frequency (1%) against the db SNP (<https://www.ncbi.nlm.nih.gov/projects/SNP/>), 1000 Genome Project (<http://www.internationalgenome.org/>), ExAC (<http://exac.broadinstitute.org/>), and GenomAD (<http://gnomad.broadinstitute.org/about>) databases. In silico prediction of variants' pathogenicity was performed using SIFT, PolyPhen, and Mutation Taster. Combined Annotation Dependent Depletion score was also integrated to the prioritization criteria, and a cutoff of 20 was used to determine deleteriousness. The causative HIBCH variant was confirmed by Sanger sequencing.

Clinical Reports

Family 1

This boy was the first child of healthy non-consanguineous Middle Eastern parents. His psychomotor development was normal. He has presented since the age of 15 months recurrent episodes of paroxysmal right hemidystonia, occurring every 1 or 2 weeks and lasting for less than 30 minutes, without impaired consciousness. No particular trigger could be found. Brain magnetic resonance imaging (MRI) revealed bilateral pallidal hyperintensity (► Fig. 1A). Lactate and pyruvate levels in venous blood and in cerebrospinal fluid (CSF) measured in a non-acute phase were normal. Other biochemical investigations were normal (► Table 1). Sequencing of a panel of 127 target genes associated with movement disorders was negative. At the age of 3 his neurological examination and his psychomotor development remained normal. PD episodes then became scarcer and the parents described short paroxysmal events with contractures of the lower limbs. Whole-exome sequencing (WES) identified a homozygous HIBCH variant c.913A>G, p.Thr305Ala (► Fig. 1C). Sanger sequencing confirmed the homozygous mutation and showed that each parent carried a single mutated allele. Thiamine treatment (250mg per day) was introduced and an emergency procedure consisting of glucose infusion and protein restriction was implemented in case of infection or fasting conditions.

Family 2

This boy was the second child of second degree consanguineous Turkish parents. His developmental milestones were normal. He has presented since the age of 3 with numerous PD episodes described as dystonic posture of both feet, contractures of the lower limbs, sometimes associated with choreic movements of the hands. These events were triggered by prolonged physical efforts, lasted for 1 to 4 hours and occurred 5 to 10 times a week. Neurological examinations between these episodes were normal. Brain MRI showed symmetrical T2 and diffusion hyperintensity of the pallidi (► Fig. 1B). Standard biochemical investigations were normal (► Table 1). Molecular analyses including SLC2A1 and PRRT2 sequencing were normal.

Table 1 Main biochemical investigations and MRI results

| | Patient 1 (Nonacute phase) | Patient 2 (Nonacute phase) | Patient 3 (sister of patient 2) (Acute phase) |
|--|--|--|---|
| Metabolic screening | | | |
| Blood | | | |
| Creatine kinase | 112 U/L (40–250) | 231 UI/L (24–247) | 134 UI/L (< 149) |
| Metabolic acidosis | No | No | No |
| Lactate / Pyruvate | L: 1.25 mmol/L (0.4–2) P: 41 µmol/L (35–80) | L: 1.4 mmol/L (0.5–2.2) P: ND | L: 2.2 mmol/L (0.5–2.2) |
| Acylcarnitines analysis | N | ND | N |
| Ammoniemia | 52 µmol/L (14.7–55.3) | ND | N |
| AAC | N | N | Increased alanine 606 µmol/L (168–510) |
| PDHc activity | ND | ND | Decreased activity 1169 pmol/min/mg prot (1570–3430) |
| Biotinidase activity | ND | ND | N |
| Cerebrospinal fluid | | | |
| Proteins | 0.15 g/L (0.15–0.45) | 0.21 g/L (0.15–0.35) | 0.15 g/L (0.15–0.35) |
| Glucose (Glc) | 2.3 mmol/L R Glc (CSF/blood): 0.61 | 3.3 mmol/L (3.3–4.4) R Glc (CSF/blood): 0.71 | 5.2 mmol/L (3.3–4.4) |
| Lactate/Pyruvate | L: 1.39 mmol/L (1.20–2.10) P: 88.199 µmol/L (< 70) | L: 1.5 mmol/L (1.1–2.4) | L: 2.8 mmol/L (1.1–2.4) |
| Cell count | WC 3/mm ³ ; RC < 1/mm ³ | WC 10/mm ³ ; RC 120/mm ³ | WC 30/mm ³ ; RC 10/mm ³ |
| AAC | N | ND | ND |
| Neurotransmitters profile | N | N | N |
| Urines | | | |
| AAC | N | ND | N |
| OAC | N | ND | N |
| Other results | | | |
| Fibroblasts HIBCH activity | ND | ND | 3 and 2.8 nmol/(min.mg prot) on 2 experiments, respectively (5.3–10.5) |
| Respiratory chain enzymes activity measurement | ND | ND | N on muscle, liver, and fibroblasts ADNmt sequencing N |
| Brain MRI | T2, FLAIR, and diffusion hyperintensity in the globi pallidi | T2 and diffusion hyperintensity in the globi pallidi | Symmetrical diffusion hyperintensity of globi pallidi with hypointensity on ADC sequence (initial MRI) Lactate peak (MRI at day 7) |
| HIBCH mutations | Homozygous c.913A>G, p.Thr305Ala | Homozygous c.913A>G, p.Thr305Ala | Homozygous c.913A>G, p.Thr305Ala |

Abbreviations: AAC, amino acids chromatography; CSF, cerebrospinal fluid; FLAIR, fluid-attenuated inversion recovery; MRI, magnetic resonance imaging; N, normal; ND, not done; OAC, organic acids chromatography; PDHc, pyruvate dehydrogenase complex; RC, red blood cell; WC, white blood cell.

His younger sister presented at the age of 2.5 an acute neurological event with impaired consciousness during a fever. Initial brain MRI showed symmetrical diffusion hyperintensity of both pallidi with hypo-intensity on apparent diffusion coefficient sequences. Biochemical investigations showed lactate elevation in the CSF. Pyruvate dehydrogenase (PDH) activity was decreased, while PDHA1 sequencing did not reveal any pathogenic variant (► Table 1). Her examination evolved into a spastic and dystonic encephalopathy.

WES identified the same HIBCH homozygous variant c.913A>G, p.Thr305Ala in the two siblings (► Fig. 1C). Sanger sequencing confirmed this homozygous variant and showed that the mother and father were heterozygous for the variant.

The boy was transiently treated by carbamazepine and avoided prolonged efforts. At the age of 11 he had experienced several similar episodes on a yearly basis, without any treatment. His neurological examination was normal and school achievements were adequate for his age. An emergency treatment procedure was proposed for both siblings including glucose infusion and protein restriction in case of infection or fasting conditions.

Discussion

We describe two unrelated patients, harboring the same homozygous HIBCH mutation, who exhibited attacks of paroxysmal movement disorders characterized by (1) onset in early childhood, (2) prolonged episodes, (3) unexpected fluctuating course with exercise as a trigger, or no triggering factor, (4) normal interictal clinical examination, and (5) pallidal hyperintensity on brain MRI. PD are a group of clinically and genetically heterogeneous disorders, mutations in PRRT2 being the major cause known to date.¹ In the patients reported here, paroxysmal attacks can be distinguished from primary PD by the prolonged duration of the attacks, a symptom which is not concordant with the common PRRT2-linked PD and by the presence of associated brain abnormalities resembling the anomalies often described in PDH deficiency. Metabolic screening and usual sequencing strategies were negative for both patients, while WES finally identified a similar HIBCH deficiency in both cases.

These case reports are unusual presentations of HIBCH deficiency, which is mostly characterized by an early-onset in the first year of life and by a continuous decline in the psychomotor abilities,^{4,5} or by acute regression triggered by febrile infections with episodes of severe ketoacidosis, mimicking Leigh syndrome.⁵ To date, some 20 HIBCH patients from 15 families have been reported,^{4–7,10} mostly presenting with motor impairment, axial hypotonia and limb hypertonia or dystonia, feeding difficulties, and severe cognitive disabilities associated with hyperintensity of the basal ganglia on brain MRI. Importantly, the clinical phenotype of the sister of patient 2 is consistent with this usual pattern, while those of the two index cases with PD and normal interictal motor and cognitive abilities are distinct from this more usual picture. Schottmann et al already has broadened the HIBCH-related clinical phenotypes by describing Turkish patients with a milder phenotype including nonprogressive ataxia, dysarthria, muscular hypotonia, and mild intellectual disabilities, allowing survival until adulthood, with stabilization or even improvement of their condition.⁷ Recently, Xu et al reported a 6-year-old Chinese girl presenting PED, with normal interictal examination and normal psychomotor development,⁶ which closely resembles the clinical picture of the two index cases presented herein.

The homozygous HIBCH mutation found in our patients has already been reported in two families presenting different phenotypes. Members of one family showed the mild phenotype described here, including nonprogressive ataxia, whereas those of the second family exhibited a spastic dystonic movement disorder, which was either stable or progressive.⁷ This mutation, together with another one, was also found in heterozygous state in another patient presenting with a severe phenotype.¹⁰ This observation fits with what we observed in our second family, highlighting a significant intra-familial phenotypic heterogeneity, already known in many energy metabolism defects, and emphasizing the challenges in establishing genotype–phenotype or residual enzyme activity–phenotype correlations.

From a mechanistic viewpoint, HIBCH is a mitochondrial enzyme that catalyzes the fifth step of the valine catabolic pathway and HIBCH recessive mutations should result in the accumulation of metabolic intermediates, such as hydroxyl- C4-carnitine and methacrylyl-CoA.^{4,5} Methacrylyl-CoA is hypothesized to reduce the activity of mitochondrial enzymes by reacting with exposed thiol groups. HIBCH deficiency can also lead to secondary multiple mitochondrial respiratory chain deficiencies and/or PDHc deficiency leading to an energy metabolism breakdown. Elevation of lactate and alanine, which are biomarkers for mitochondrial dysfunction, in the CSF of the sister, is consistent with this hypothesis of secondary respiratory chain complexes deficiencies. A similar pathophysiological process has been suggested in patients with enoyl-CoA hydratase, short-chain 1 (ECHS1) deficiency, which disrupts valine catabolism upstream of HIBCH.¹¹ Paroxysmal movement disorders with pallidal hyperintensity on brain MRI are a mode of onset in PDH deficiency, and have been recently reported in ECHS1 deficiency.^{12,13} We suggest that HIBCH deficiency, like PDH or ECHS1 deficiency, leads to a broad phenotypic spectrum ranging from Leigh syndrome to milder phenotypes characterized by isolated paroxysmal movement disorders.

There are currently no clear treatment guidelines of HIBCH deficiency. Carbohydrate-rich meals, low valine diet, antioxidants, and carnitine supplementation could improve some neurological symptoms and MRI abnormalities, but are unable to prevent acute episodes.^{4,5} As HIBCH deficiency is considered as a cerebral organic aciduria, we proposed an emergency procedure consisting of glucose infusion and protein restriction in case of infection or fasting conditions.

We suggest to add HIBCH gene to the growing list of secondary PD causes.^{2,3,14} Brain MRI, together with next-generation sequencing (panels including HIBCH gene or exome sequencing) are the gold standard for early diagnosis in patients with the classical Leigh or Leigh-like phenotype and in patients exhibiting PD with abnormal pallidal signal on brain imaging. Our cases extend the clinical spectrum of HIBCH deficiency and point to this gene for secondary PD diagnosis and for the implementation of adequate preventive treatment.

Conflict of Interest

None of the authors has any conflict of interest to disclose.

Acknowledgment

We thank the patients and their families.

References

- 1 Bhatia KP. Paroxysmal dyskinesias. *Mov Disord* 2011;26(06): 1157–1165
- 2 Méneret A, Roze E. Paroxysmal movement disorders: an update. *Rev Neurol (Paris)* 2016;172(8-9):433–445
- 3 Erro R, Bhatia KP. Unravelling of the paroxysmal dyskinesias. *J Neurol Neurosurg Psychiatry* 2019;90(02):227–234
- 4 Ferdinandusse S, Waterham HR, Heales SJ, et al. HIBCH mutations can cause Leigh-like disease with combined deficiency of multiple mitochondrial respiratory chain enzymes and pyruvate dehydrogenase. *Orphanet J Rare Dis* 2013;8:188
- 5 Yamada K, Naiki M, Hoshino S, et al. Clinical and biochemical characterization of 3-hydroxyisobutyryl-CoA hydrolase (HIBCH) deficiency that causes Leigh-like disease and ketoacidosis. *Mol Genet Metab Rep* 2014;1:455–460
- 6 Xu Y, Zhang J, Yu K, et al. A therapeutic regimen for 3-hydroxyisobutyryl-CoA hydrolase deficiency with exercise-induced dystonia. *Eur J Paediatr Neurol* 2019;23(05):755–759
- 7 Schottmann G, Sarpong A, Lorenz C, et al. A movement disorder with dystonia and ataxia caused by a mutation in the HIBCH gene. *Mov Disord* 2016;31(11):1733–1739
- 8 Broix L, Jagline H, Ivanova E, et al; Deciphering Developmental Disorders study. Mutations in the HECT domain of NEDD4L lead to AKT-mTOR pathway deregulation and cause periventricular nodular heterotopia. *Nat Genet* 2016;48(11):1349–1358
- 9 Flicek P, Amode MR, Barrell D, et al. Ensembl 2012. *Nucleic Acids Res* 2012;40(Database issue):D84–D90
- 10 Karimzadeh P, Saberi M, Sheidaee K, Nourbakhsh M, Keramatipour M. 3-Hydroxyisobutyryl-CoA hydrolase deficiency in an Iranian child with novel HIBCH compound heterozygous mutations. *Clin Case Rep* 2019;7(02):375–380
- 11 Peters H, Buck N, Wanders R, et al. ECHS1 mutations in Leigh disease: a new inborn error of metabolism affecting valine metabolism. *Brain* 2014;137(Pt 11):2903–2908
- 12 Mahajan A, Constantinou J, Sidiropoulos C. ECHS1 deficiency-associated paroxysmal exercise-induced dyskinesias: case presentation and initial benefit of intervention. *J Neurol* 2017;264(01):185–187
- 13 Olgiati S, Skorvanek M, Quadri M, et al. Paroxysmal exercise-induced dystonia within the phenotypic spectrum of ECHS1 deficiency. *Mov Disord* 2016;31(07):1041–1048
- 14 Ogawa Y, Nakamura K, Ezawa N, et al. A novel CACNA1A nonsense variant in a patient presenting with paroxysmal exertion-induced dyskinesia. *J Neurol Sci* 2019;399:214–216