



HAL
open science

Case of Primary Aldosteronism With Discordant Hormonal and Computed Tomographic Findings

Laurence Amar, Gian Paolo Rossi, Yehonatan Sharabi, Gian Paolo Rossi, Emmanuelle Vidal-Petiot, Anna F Dominiczak, Paolo Mulatero, Anne-Laure Faucon, Neeraj Dhaun, Rhian M Touyz, et al.

► **To cite this version:**

Laurence Amar, Gian Paolo Rossi, Yehonatan Sharabi, Gian Paolo Rossi, Emmanuelle Vidal-Petiot, et al.. Case of Primary Aldosteronism With Discordant Hormonal and Computed Tomographic Findings. Hypertension, In press, 69 (4), pp.529-535. 10.1161/HYPERTENSIONAHA.116.08751 . hal-03121288

HAL Id: hal-03121288

<https://hal.science/hal-03121288>

Submitted on 30 Mar 2023

HAL is a multi-disciplinary open access archive for the deposit and dissemination of scientific research documents, whether they are published or not. The documents may come from teaching and research institutions in France or abroad, or from public or private research centers.

L'archive ouverte pluridisciplinaire **HAL**, est destinée au dépôt et à la diffusion de documents scientifiques de niveau recherche, publiés ou non, émanant des établissements d'enseignement et de recherche français ou étrangers, des laboratoires publics ou privés.

Case of Primary Aldosteronism With Discordant Hormonal and Computed Tomographic Findings

Laurence Amar, Yehonatan Sharabi, Gian Paolo Rossi, Emmanuelle Vidal-Petiot, Anna F. Dominiczak, Paolo Mulatero, Anne-Laure Faucon, Neeraj Dhaun, Rhian M. Touyz, Mohammed Barigou, Aurelien Lorthioir

A nonsmoking 46-year-old male was referred to our hypertension excellence center at the Hospital Georges Pompidou in Paris because of hypertension associated with hypokalemia. His past medical history listed asthma treated by inhaled corticosteroid therapy, corneal transplant, and prostatic adenoma. He had neither been diagnosed with diabetes mellitus nor lipid disorder. His body mass index was 24.7 kg/m². No family history of cardiovascular disease was known. Hypertension was diagnosed incidentally in 2011 at the age of 43 when he consulted his physician for a sport certification. Maximum systolic blood pressure was 190 mmHg, blood test at that time revealed hypokalemia, with a minimum potassium level of 3 mmol/L.

At the time of his first consultation at our department, the patient was already being treated with amlodipine and perindopril once a day. In addition, he received corticoid inhalation for asthma and an α -blocker (tamsulosin) for his prostate adenoma. The patient complained of headaches and dizziness. Diurnal ambulatory blood pressure was very high, 167/112 mmHg. Blood potassium level was 2.9 mmol/L with inappropriate urinary excretion of potassium (93 mmol/d). Fasting plasma glucose was 5.7 mmol/L, and low-density lipoprotein cholesterol was 3.88 mmol/L.

The patient was diagnosed with grade 3 hypertension and hypokalemia. Secondary causes of hypertension were explored, and treatment was modified accordingly. Amlodipine

and perindopril administration was terminated, and urapidil was prescribed. Despite oral potassium supplements of 9 g/d, potassium levels remained at 3.0 mmol/L. Estimated glomerular filtration rate was 88 mL min⁻¹ 1.73 m⁻², and urinary potassium excretion remained elevated (51 mmol/d). Renin and aldosterone levels were assessed in the seated position. Renin was measured at 1.7 mIU/L, and aldosterone at 933 pmol/L (33.7 ng/dL) with an elevated aldosterone:renin ratio. Urinary aldosterone was also elevated (71 mmol/d). And a saline suppression test confirmed the diagnosis of primary aldosteronism with unsuppressed aldosterone secretion at 426 pmol/L (15.7 ng/dL).

Dr Amar: Considering the target organ damage observed during this outpatient visit, left ventricular hypertrophy was proposed based on the Cornell index and confirmed with echocardiography (left ventricular mass index=121 g/m^{2.7} mass). The patient did not have microalbuminuria. Pulse wave velocity and carotid wall thickness measurements were not performed. The patient underwent a computed tomographic (CT) scan. The slides show normal adrenals without any adenoma or hyperplasia (Figure).

We have a 46-year-old male with a 3-year history of hypertension associated with hypokalemia. He has been diagnosed with primary aldosteronism with normal adrenals. We know we could make another clinical–pathological conference on the diagnosis of primary aldosteronism, but I think this is not the case today. Maybe we should discuss what we should do now that we agree that this patient has primary aldosteronism.

Professor Touyz: This opens up the discussion to the audience. We have a very nice presentation of a young man with high aldosterone but normal adrenals. Does anybody have any suggestions?

Dr Sharabi: The fact that the patient does not have an adenoma does not rule out the possibility of a unilateral secreting hyperplasia. In addition, in many histological evaluations of adrenal glands, microscopic adenomas are observed. Therefore, if he can tolerate or responds to medical treatment, because of his age and the short disease duration, I would consider adrenal vein sampling (AVS). AVS would allow us to determine whether he has unilateral adrenal hyperplasia or secreting adenoma, despite the negative CT scan results. Since the patient is young, he can be cured if indeed a unilateral adrenal lesion is found and resected.

Dr Amar: I agree with you. We have 3 alternatives

1. I do not want or need to know whether he has uni- or bilateral production of aldosterone.
2. I want or need to know whether the secretion is uni- or bilateral.
3. I already know that the secretion is bilateral.

The opinions expressed in this article are not necessarily those of the editors or of the American Heart Association.

From the University Paris Descartes, AP-HP, Hypertension Unit, Hospital European Georges Pompidou, France (L.A., A.-L.F., M.B., A.L.); Hypertension Unit, Sheba Medical Center, Tel Hashomer and Sackler Faculty of Medicine, Tel Aviv University, Israel (Y.S.); Clinica dell'Ipertensione, Department of Medicine, DIMED, University Hospital, Padova, Italy (G.P.R.); Physiology Department, DHU FIRE, Bichat Hospital, AP-HP, Inserm, University Paris Diderot, Sorbonne Paris Cité, France (E.V.P.); Institute of Cardiovascular and Medical Sciences, College of Medical Veterinary and Life Sciences, University of Glasgow, United Kingdom (A.F.D., R.M.T.); Division of Internal Medicine and Hypertension Unit, Department of Medical Science, University of Turin, Italy (P.M.); and University/BHF Centre for Cardiovascular Science, University of Edinburgh, United Kingdom (N.D.).

Presented in part at the Clinical–Pathological conference chaired by Anna F. Dominiczak and Rhian M. Touyz at the 26th European Meeting on Hypertension and Cardiovascular Protection, Paris, France, June 11, 2016. Laurence Amar presented the case and led the discussion.

Correspondence to Laurence Amar, University Paris Descartes, AP-HP, Hospital European Georges Pompidou, 20 rue Leblanc, Paris F-75015, France. E-mail laurence.amar@aphp.fr

(*Hypertension*. 2017;69:529–535.)

DOI: 10.1161/HYPERTENSIONAHA.116.08751.)

© 2017 American Heart Association, Inc.

Hypertension is available at <http://hyper.ahajournals.org>

DOI: 10.1161/HYPERTENSIONAHA.116.08751

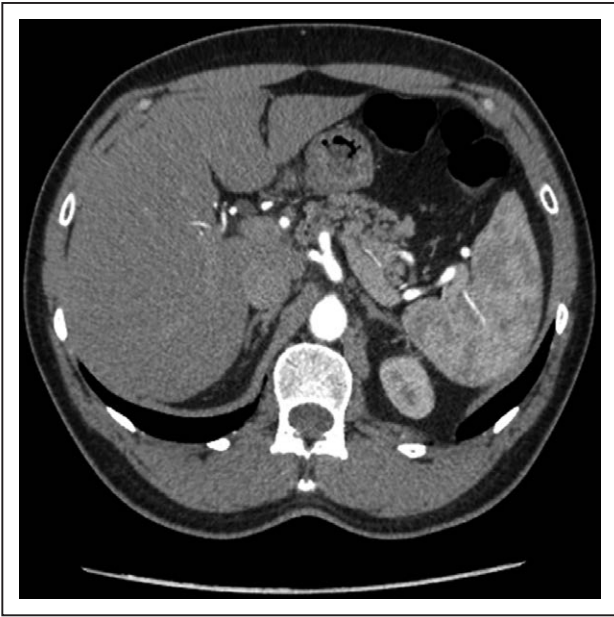


Figure. Computed tomographic scan showing 2 normal adrenals.

Therefore, your point is that we do not know whether aldosterone secretion is bilateral or not. If we want to know whether the secretion is uni- or bilateral, we have the following options.

Determining Unilateral Versus Bilateral Secretion: Medical Therapy or Surgery

The first option to consider is whether uni- versus bilateral disease can be predicted without performing AVS. This was attempted by working on a prediction score for lateralized PA based on kalemia, estimated glomerular filtration rate, and imaging results.¹ However, it could not be reproduced by other teams.

Other techniques for aldosterone detection have been published. The first option is metomidate positron emission tomography.² However, my unit does not have easy access to metomidate. The second option is the measurement of 18 oxocortisol.³ Indeed, liquid tandem mass spectrometry would allow blood measurements that would help the diagnosis of uni- versus bilateral overproduction of aldosterone.

The final option to discuss is AVS.

There also are other possibilities. However, it might be decided that it is not necessary to know whether the patient has uni- or bilateral disease. Surgery might not be proposed to the patient because of his comorbidities such as severe asthma. Additionally, performing AVS in our centers might not be possible, and it may be complicated to send this patient to another hospital. Finally, the patient may not want to know whether he has uni- or bilateral disease because he may not want to undergo surgery.

To summarize, there are several options, but no specific answers. What would be the outcome of the surgery? What are the risks of AVS? What should we propose?

1. Administration of mineralocorticoid antagonists could be tried. These drugs are known to work. There could be some adverse reactions to spironolactone. However,

eplerenone is typically well tolerated. According to the literature, success of medical treatment is approximately equal to the success of surgical treatment.⁴ For the above reason, medical treatment is a valuable therapeutic option.

2. The patient appears to have 2 normal adrenals on the CT scan. Therefore, the disease must be bilateral and must be addressed accordingly.

Discussion Continues

Dr Amar: As Dr Sharabi pointed out, there may be nodules that are not visible on the CT scan. Thus, option 1 does not address the problem. In addition, it has been reported that 48% of patients appear to have normal adrenals on the CT scan. A recent study reported that 32.6% of patients have lateralized production of aldosterone.^{5,6} Therefore, I would also say proceed to AVS.

Professor Rossi: I have no doubts that AVS should be performed in this patient. He is a young active man who underwent a medical examination to obtain a sports certificate, perhaps for a competitive sport. He needs to have the best chances for long-term definitive cure of his hypertension. I would like to make a point that in my experience is very important. A hypertension specialist or endocrinologist should personally examine the adrenal glands visualized with CT or magnetic resonance. Here, on the left side, I see a small enlargement (pseudonodule) at the confluence of the 3 leaflets and a small lump in the lateral leaflet. These cannot be disregarded by the hypertension specialist because often aldosterone-producing adenomas are really tiny, sometimes <10 mm at maximum diameter. If the CT is not done with 2- to 3-mm-thick slices and someone, who does not know the clinical case, does not look very carefully, (if necessary using the coronal reconstruction of the images) these tumors can easily be overlooked. I am really curious to see the histology if you operated on this patient.

Dr Amar: I agree, it is really complicated to decide whether an adrenal gland is normal. If we consider surgical cases, of course there is a bias: patients with more florid clinical phenotypes receive surgical treatment. Do normal adrenals exist? All of us in our centers have experienced some cases of removal of normal adrenals, usually taken from patients with kidney carcinoma. If we look at them carefully, they may have some nodules. It is always difficult to differentiate between nodules that are linked to hormone secretion and nodules that are just physiological.

Dr Vidal-Petiot: Even if there was an obvious nodule, the risk of assuming it is lateralized when it is not would remain. Therefore, in any case, we would go with AVS.

Dr Steichen: You mentioned that the perspective of the patient is important. This patient may not be willing to be operated. In your experience, what percentage of patients with normal adrenals refuses to undergo surgery (AVS)?

Dr Amar: I think this proportion depends on the physicians who take care of the patients. In the end, the patient's decision depends on what we say. Honestly saying, "it is benign and will not necessarily worsen without surgery," is different from saying "without surgery it will get worse." Sometimes patients believe that drugs will not work in the long-term. For a patient

of 46 years, as in this case, we might be more inclined to say “Okay, this patient should have surgery” than for a patient with exactly the same history but 65 or 70 years of age. Therefore, I think your question is difficult to answer. There are also cases in which patients cannot be recommended for surgery because of comorbidities. Having said this, I would estimate that 15% of patients refuse to have surgery after an explanation of the risks and options. Most of the patients do accept.

Professor Dominiczak: I have a comment based on my experience with a real patient. You are absolutely right; it is very difficult to make a decision at this stage. Although we all agree on the next step of your management, some patients are difficult. I remember one patient who still attends my clinic where we did the sampling. His disease was lateralized and we decided to operate. The patient was in his 50s at the time and was himself a physician. He wanted surgery, and he underwent surgery, and the surgery was successful. However, his blood pressure did not normalize after surgery. A few years later we realized that he also had a secreting adenoma in the other adrenal. However, at the time we did the sampling, the lateralization was obvious.

Professor Mulatero: I absolutely agree with you and Professor Rossi. We should absolutely perform an AVS unless the patient refuses to have surgery. I think we can discuss the CT scan or the clinical criteria. We can have a high suspicion. We can suspect that there is probably something on the left adrenal. However, we should in any case perform AVS. At the moment, there is no evidence suggesting unilateral versus bilateral form. A recent article, published in the last year, suggests that steroid profiling could indicate the presence of a unilateral adenoma versus bilateral hyperplasia or even more specifically, the presence or absence of a mutated adenoma.⁷ We might, in the future, have more profound reasons to perform AVS. Nevertheless, considering everything at this particular moment, AVS should be performed on this patient.

Dr Faucon: I agree with you, AVS is recommended for this patient because he is young and he seems to have severe hypertension. But my question is, generally, what are other criteria to perform AVS?

Dr Amar: According to the literature, AVS can be skipped in patients with a single nodule and younger than 35 years of age.⁸ In all other cases, if the physician and the patient are willing to go to surgery, we have to propose AVS.

Professor Rossi: Actually, the decision not to perform AVS is based on the idea that the presence of a tumor in a young person with a clear-cut biochemical picture of primary aldosteronism strongly suggests that this node is an aldosterone-producing adenoma. This might be correct, but from the strictly logical standpoint, it does not make any sense. The 2 things are not related to one another. You may have a nonfunctioning adenoma in a 35-year-old person and a microadenoma contralaterally. At our institution, we do not perform surgery without AVS. I think this has to be said very clearly, because otherwise the wrong adrenal might be removed, harboring a nonfunctioning adenoma.

Dr Amar: Yes, the point is that you are at an expert center with easy access to AVS. However, if the patient is below 35 years old, the proportion of the discrepancies is very low

between AVS and CT scan. At our unit we also routinely perform AVS, because it is easy for us. However, if you have to refer your patients to another center, the case is more complicated. Jaap Deinum is leading a prospective randomized study to evaluate the diagnostic performances of AVS and CT scan. The results were published at the end of 2016.⁹

Dr Dhaun: My question is from a nephrology point of view. May I ask 2 questions relating to the hypokalemia? Was it symptomatic and did the patient’s ECG show any suggestive changes?

Dr Amar: No, there were no abnormalities on the ECG. In patients with primary aldosteronism, we are dealing with chronic hypokalemia. Usually, we do not see many complications in these patients.

Dr Dhaun: Perhaps, I missed this: while you were waiting to discuss AVS with the patient, did you treat him with a mineralocorticoid receptor antagonist?

Dr Amar: No, because once we commence mineralocorticoid antagonist therapy we have to wait 6 weeks to perform AVS. As long as we are in the exploratory phase of patient management, we prescribe amiloride. Amiloride has a good effect on hypokalemia, and facilitates the preparation for AVS because it can be administered up to 15 days before hormonal assessment.

Dr Denolle: Do you want to try spironolactone or mineralocorticoid antagonist before surgery, even after AVS?

Dr Amar: Yes, I would.

AVS and Results

The standard operating procedure in our center is to perform AVS in the morning without interfering drugs.¹⁰ Adrenocorticotrophic hormone (ACTH) stimulation is not used. Two catheters are used: one for the right adrenal and one for the left adrenal. The anatomy of the adrenal veins is not the same. Therefore, differently shaped catheters are necessary. Bilaterally simultaneous blood sampling is performed in our center: first the right adrenal vein, then the left adrenal vein, and last the femoral vein. We have a standardized procedure for the management of the samples because any mistake in the management of the samples might lead to surgery on the wrong side. The patient signs a consent form before the procedure. The form contains everything we discussed, including the indications and the risks.

Results of AVS sampling in this patient showed elevated selectivity index (ratio of cortisol concentration between each adrenal vein and the femoral vein) on the right and the left side (10.7 and 15.8, respectively). The lateralization index was 0.2 in the right adrenal and 3.6 in the left adrenal. Thus, we concluded that this patient has a left lateralization of aldosterone production.

Dr Vidal-Petiot: Given your considerable experience in adrenal veins, I would be very interested to know the following: what do you think about the different criteria to verify that you were indeed in the adrenal vein? Cortisol is usually used to confirm the correct location. However, I have recently read metanephrine use is suggested, for instance. Or in our case, we have had samples with normal cortisol levels and elevated aldosterone. Therefore, I always wonder whether cortisol is selective or not. Could you tell us what you think about that?

Dr Amar: We have been using cortisol for years. However, as you pointed, we now have data showing that there may be other options. Several other hormones have been tested, and a whole new field was opened by mass spectrometry. Several hormones have been shown to have a higher step-up between the adrenal vein and the peripheral blood than cortisol, for example, metanephrine, as you pointed out.¹¹ Therefore, these hormones may show selectivity even when cortisol does not. Cutoffs used for the selectivity index on the basis of cortisol ranges from 1.10 to 3.00. ACTH would increase this ratio, thus enhancing the assessment of selectivity just because the levels of cortisol will be much higher. Regarding the discrepancies, you are correct; sometimes patients are judged to be nonselective based on cortisol, because adrenal vein levels do not exceed peripheral levels (for example, in the presence of aldosterone- and cortisol-cosecreting tumors). This underscores the need for other hormonal indicators as discussed previously. I believe that in the coming years, we will have other indicators for the interpretation of AVS. I think metanephrine is an interesting option.

Dr Tropeano: Do you always stop interfering drugs in order to determine whether there is a lateralization?

Dr Amar: Usually we try to stop interfering drugs. However, renin levels at the time of AVS are the most important thing to consider. Some centers continue interfering drugs and only check on renin levels. If renin levels are low, the chances of secondary aldosteronism causing aldosterone secretion in the unaffected (contralateral) adrenal gland are slim. We all avoid spironolactone, even though 1 article including only 4 selected patients who underwent AVS under spironolactone (1.7% of the patients in the cohort), claimed that these patients did have an elevated lateralization index and had remission of primary aldosteronism after adrenalectomy.¹² It is easier to perform AVS without interfering drugs. However, if interfering drugs cannot be discontinued, specifically in patients with very severe hypertension, renin must be checked before performing AVS.

Professor Touyz: You mentioned amiloride. What other drugs would you use as your drug of choice in patients with really severe hypertension?

Dr Amar: For hypertension or for kalemia?

Professor Touyz: For both as they are linked.

Dr Amar: Patients with hyperkalemia need diuretics. During the work-up, we avoid mineralocorticoid blockers and use classical diuretics. Amiloride is added to control hypokalemia.

Dr Sharabi: Just a comment. Aliskiren would have been handy in this situation, because it does not increase renin. However, we do not have it anymore. I have a question: Is there a reason not to infuse ACTH during the AVS? In our experience, ACTH infusion increases the selectivity index, and it helps us in having clear results. We use ACTH infusion as part of the protocol.

Dr Amar: With simultaneous procedures or sequential procedure?

Dr Sharabi: Bilaterally simultaneous.

Dr Amar: So the question is: How do we interpret the data? There are several protocols, several cutoffs. In addition, it increases AVS duration and complexity for the radiologist.

Dr Sharabi: Selectivity and aldosterone secretion are enhanced.

Dr Amar: So it increases the numbers. However, it does not change whether the radiologist or the cardiologist catheterize the adrenal veins or not.

Dr Sharabi: Just to complete the ACTH issue, the Australia group has collected data from 800 cases. They strongly advocate the use of ACTH. And as I said, in our small sample, not even hundreds, ACTH usage did help us in getting clear results. But I understand, having a slot of 1 hour in the radiology room is a hassle. Therefore, we start the ACTH infusion an hour in advance and then move the patient supine to the table in the invasive radiology room to perform the AVS. I recommend considering the use of ACTH infusion wherever it is feasible.

Dr Amar: I think you have to use ACTH when you use sequential measurement. When you do simultaneous measurement, it has not been proven to improve the results.

Dr Dhaun: Could I ask you what the risks associated with AVS are in your center and how these vary between centers? Also, is there an increased risk of catheter-related thrombosis depending on the subsequent histology?

Dr Amar: The expert of the complications of AVS is present in this room. Professor Mulatero has collected all the cases that have been published. There were 24 cases of adrenal hemorrhage. It happened more often in the right adrenal.¹³ The training of the radiologist was not very different. Professor Mulatero also performed a retrospective study among several centers performing AVS. Among 2604 patients only 16 adrenal vein ruptures occurred. Can it happen? Yes it can happen. Does it happen often? No, it is very rare. However, a full discussion of possible risks and complications is essential before AVS. Overall, complications resolved with conservative treatment in 100% of the cases.

In the subsequent histology, we did not observe any differences. Histology is difficult because the classical pathological report would say "Conn adenoma." In fact, what they see is an adenoma of the cortex. However, determining whether it is secreting aldosterone is impossible without immunostaining, which in our center is not routinely performed. Therefore, the answer to the question about the adenoma is usually not precise; pathologists are not that interested in it because it is benign.

Dr Barigou: You cited a selectivity index of 2.0. However, in some cases, we would not reach this selectivity index in both adrenal veins. In this situation, some studies suggest to interpret AVS relative to vena cava values.¹⁴ What do you think about that?

Dr Amar: There are studies about the contralateral suppression index, which is the third index.¹⁴ The aldosterone:cortisol ratio in 1 adrenal vein is compared with that in the peripheral vein. The idea is that lower levels of aldosterone in the adrenal vein than in the peripheral vein, indicate elevated aldosterone production in the contralateral adrenal.

If it is not possible to examine both adrenal veins, 1 adrenal vein that shows suppressed production of aldosterone could indicate that the other vein is producing too much

aldosterone. This study showed that all patients with bilateral aldosterone hyperplasia were in the range between the lowest and the highest cutoff. Therefore, by looking at the suppression index, it is possible to identify the patients with overproduction of aldosterone.¹⁴

Low suppression indices on both adrenal veins are also possible. The aldosterone:cortisol ratio is low in the right adrenal vein, low in the left adrenal vein, and is higher in the peripheral vein. What do you do with this data? More patients and more studies are needed to be able to determine whether it is possible to decide on AVS without having results of both sides.

Post-AVS

AVS was performed. The patient had left lateralization of the production of aldosterone. The case of this patient was discussed during a routine multidisciplinary meeting with the hypertension specialist, physiologist, radiologist, the surgeon, and the geneticist.

Left adrenalectomy was proposed to the patient and was performed laparoscopically. Before the adrenalectomy, the patient was treated with spironolactone and verapamil, because all blood tests required for a diagnosis were complete and normal kalemia and controlled blood pressure were desired before surgery. We also believed that this course of action would result in less difficulty with hyperkalemia after surgery. Cases of mineralocorticoid insufficiency have been published. In our center, no patient was diagnosed with mineralocorticoid insufficiency after surgery. This may be related to the use of spironolactone before surgery. When patients come to surgery, they have nonsuppressed renin levels.

The day after surgery, the patient had a potassium level of 4.8 mmol/L. Six months after surgery, without any treatment since surgery, he had diurnal ambulatory blood pressure of 134/94 mm Hg. His blood pressure values are improved, but he is not totally cured of hypertension. His kalemia had normalized. Hormone measurements showed unsuppressed renin and normal aldosterone:renin ratios. He underwent a saline suppression test. Aldosterone was suppressed after the saline infusion. In summary, this patient was cured hormonally of his primary aldosteronism, but he still has hypertension, likely concomitant essential hypertension. The patient was then treated with 300 mg per day of diltiazem.

Table. Characteristics of the Patient Before and After Surgery

Characteristic	Before Surgery	After Surgery (6 mo)
Diurnal ABPM, mm Hg	167/112	138/94
Treatment score	2	0
Kalemia, mmol/L	2.9	4.5
Urinary potassium, mmol/d	51	82
Renin, mUI/L	1.7	17.2
Aldosterone, pmol/L	933	245
Aldosterone postsaline infusion test, pmol/L	426	130

ABPM indicates ambulatory blood pressure measurement.

At the most recent follow-up with the patient, he had ceased taking his tablets because he did not see a reason for drug therapy after having undergone surgery. In the office, his blood pressure was 132/88 mm Hg. He was asked to also complete ambulatory blood pressure measurement or home blood pressure measurement. The results of the measurements are still pending. Kalemia was 4.6 mmol/L, and he was generally well (Table).

Professor Dominiczak: You stated that there was a geneticist at your multidisciplinary meeting, but you did not tell us what the geneticist added to the discussion. Clearly, there are beautiful causative mutations in some patients that predict the clinical course. There is a lot of work in your own center, as we heard in the morning session, trying to use genetics to help predict the outcome of these patients. What was the geneticist's view?

Dr Amar: The problem is that there is a clinical routine for these patients. We know the somatic mutation only after surgery. For now, we cannot use this knowledge in the everyday routine for the decisions on the management of the patient. Usually, we propose a genetic test for all patients with hypertension before the age of 30, which is not the case for this patient.

After surgery, if the patient agreed to be part of the ENSAT cohort (European Network for the Study of Adrenal Tumors), we collect all the tumors in the research laboratory to look for mutations. Actually, I still do not have the answer for this patient because the tumors have only recently been collected. At the moment, I cannot tell you if he has a mutation or not.

Professor Mulatero: I go back to the point of the ACTH stimulation or not. Simultaneous sampling is not a frequent procedure and AVS is already difficult. Few radiologists know how to do the simultaneous sampling. Thus, there is a point for ACTH. In the 2 studies that have compared the performance of ACTH versus nonstimulated procedure in a large series, the result when you take into account a conservative ratio is more or less the same. So at the end of the day, each center could decide the preferred strategy.

ACTH is indispensable if the procedure is not done early in the morning, or, if, for example, the patient had an allergic reaction during the contrast CT scan and needs to be prepared with steroid treatment before the AVS. ACTH can confound results if the nodule cosecretes cortisol with aldosterone. Therefore, you want to be sure to stimulate the cortisol production in the other adrenal gland. Alternatively, you can use another normalization hormone such as metanephrine.

Dr Amar: This patient had asthma as I said in the beginning. He was treated with inhaled corticoid drugs; thus, we were confronted with this question. In fact, we consulted with his lung physician and stopped all the corticoids before doing the explorations. We checked that he still did not have corticotropin insufficiency.

Dr Faucon: In this case, you stop the corticotherapy before the AVS. What do we do in practice with corticotherapy?

Dr Amar: When patients take corticoids, there can be a corticotropin insufficiency, even if the steroid is inhaled. Usually the habit is to lower the dose and then to check if there is corticotropin insufficiency.

Dr Lorthioir: I understand that AVS must always be performed. Why do you perform the CT scan before doing AVS if you won't change your mind based on the CT data?

Dr Amar: This is a good point. There are 2 answers. The first is that 1% of the patients do have adrenal cortical cancer, and for these patients, AVS is not performed, because they need surgery. The second is that a lot of radiologists use the CT scan to localize adrenal veins to improve accuracy for AVS.

In the German Conn registry when viewing cases retrospectively, it was found to be very complicated to have good results on AVS procedures performed by radiologists in several centers.¹⁵ Few patients (from 8% to 48%) had bilateral selective cannulations at the German center. The radiologist or cardiologist was then trained and asked to view procedures in other more successful centers. Rapid cortisol assay was requested to provide cortisol levels during the procedures, and radiologists were asked to locate the adrenal vein. For these radiologists, the success rate of the procedure increased.

Dr Lorthioir: It is a little bit confusing. Some people say that when you are screening for endocrine hypertension, you should perform a CT scan first, and if you have normal adrenal glands, you should not do biological tests and change the treatments. It is sometimes difficult to give neutral treatments. Do you confirm that there is no need to wait for the results of the CT scan to perform biological testing to confirm if there is hyperaldosteronism?

Dr Amar: If there is hypertension and you are looking for endocrine causes of hypertension, you have to perform hormone assessment before doing a CT scan and not the opposite. This is recommended by all guidelines.

Dr Vidal-Petiot: Physiologically it is indeed expected that ACTH will increase selectivity as it stimulates cortisol. We also have to keep in mind that acutely given ACTH stimulates aldosterone, and we don't know to what extent ACTH will stimulate more adenoma from physiologically secreted aldosterone and whether ACTH will impact the interpretation of lateralization of the AVS.

This patient was lucky his estimated glomerular filtration rate remained unchanged after his blood pressure dropped 50 mm Hg. When we cure these patients, whether it is medically or surgically, we often find the underlying nephroangiosclerosis, and estimated glomerular filtration rate drops a lot.

Dr Amar: The patient is only 46 years old and he does not have any other vascular risk factors. I think that might be an explanation. But you are right, there often are underlying preexisting renal insufficiencies in these patients.

Dr Dhaun: My first question is whether this patient had a classic dipping diurnal variation in blood pressure at diagnosis and whether this changed with treatment? And the second question relates to your choice of antihypertensive drug, verapamil. I was wondering why you chose verapamil as this is not a classic antihypertensive agent.

Dr Amar: In patients with aldosterone overproduction, we sometime see a nondipper profile on ambulatory blood pressure measurement. Also, there are some patients with primary aldosteronism who have obstructive sleep apnea syndrome. Considering the series of patients, the mean body mass index among 500 patients was elevated to 27 or 30 kg/m². There are some physiopathological explanations for the correlation between primary aldosterone and sleep apnea syndrome.

This particular patient had a classical dipper profile, which remained unchanged after treatment.

We chose verapamil because we wanted only noninterfering drugs during the work-up of the patient. It has been shown that dihydropyridine increases renin, specifically, in the acute state. Therefore, usually nondihydropyridine drugs are used.

Dr Dhaun: You would not use an agent from another group, such as a noncalcium channel blocker antihypertensive?

Dr Amar: During the exploration phase, angiotensin-converting enzyme inhibitor, angiotensin receptor blocker (ARB) diuretics, and mineralocorticoid antagonists cannot be used. Basically, we are left with α -blockers, calcium channel blockers, or a combination of both. Verapamil is an excellent choice unless the patient has hypokalemia, in which case it can prolong the PQ interval and cause AV block.

Dr Turc: Before the treatment, we sometimes use eplerenone which might be more selective than spironolactone.

Dr Amar: Before surgery, we want to treat the patient. In France, eplerenone cannot be prescribed for hypertension. Eplerenone may only be used for cardiac insufficiency. Therefore, we usually prescribe low doses of spironolactone, for men 25 mg per day. In case of intolerance, a switch to eplerenone is made. We begin with spironolactone to prove to our authorities that the recommended and less expensive drug was tried first.

Dr Colussi: I have a question about another technique to check the laterality of the adenoma. There is a rapid improvement of imaging techniques like the CT spector, for example, scintigraphy with radiolabeled cholesterol. Could this technique substitute for AVS? Are you aware of some studies, some data, about this new technique?

Dr Amar: You are correct. There are new imaging techniques, for example, using ¹¹C-metomidate positron emission tomography-CT. Maybe in a few years AVS will not be required anymore. But for now, in the clinical routine, it is the gold standard, because most centers do not have access to a cyclotron and thus to ¹¹C-metomidate synthesis.

Dr Barigou: Do you perform a saline suppression test at the postoperative visit even if renin and aldosterone were normal? Is this recommended? And what is the rationale?

Dr Amar: We begin with renin and aldosterone levels. If the aldosterone:renin ratio is normal, it is not necessary to perform the saline suppression test.

Before surgery, the patients are usually willing to come back to the outpatient clinics for everything we ask of him. After surgery, particularly if the patient is cured, it is more difficult to have them return for follow-up testing.

Dr Vidal-Petiot: I just wanted to point out an article from Dr Amar's team showing that criteria from different places in the world applied to the same patient with the same procedure will yield different clinical outcomes.¹⁶ We really need to move forward because 5% to 10% of patients with resistant hypertension have primary aldosteronism. Obviously, we really have an issue with interpreting this crucial procedure.

Dr Amar: It is true that the discrepancies between the interpretations of AVS in different centers are similar to the number of discrepancies between the interpretations of the CT scan and AVS.¹⁶

Dr Marcus: In my center and I believe in my country (Portugal), we do not perform AVS sampling. You talked about

other techniques for the diagnosis. Do you think the other techniques could potentially substitute the need for AVS?

Dr Amar: Metomidate TEP is a very promising technique. However, currently metomidate preparation is very difficult, because it requires a very expensive cyclotron facility on-site. If oxocortisol levels can be evaluated on the basis of blood tests, then hormonal assessments would be suitable.

A large European project ENSAT-HT is starting now with the aim of using omics to diagnose PA and other endocrine hypertension starting from just one blood sample. The project is part of Horizon 2020, so maybe in 2020 we will have the answers.

Professor Dominiczak: I would like to make one comment about metomidate. The center in Cambridge, in particular Professor Brown, whom we invited but who could not attend, is using metomidate extensively with very good results. In the centers that can produce metomidate close to the patient, AVS might eventually be replaced with this test. Professor Brown was able to diagnose very small nodules and cure young people successfully. Therefore, I refer you to the studies published by Professor Brown.¹⁷

Dr Sharabi: I am familiar with the recent literature about the genetics of aldosterone-producing adenomas. However, I do not know how to incorporate it into understanding the patient's condition, diagnosis, and treatment choices. Largely, these are somatic mutations.

Dr Amar: In fact, some, very rarely, are also germ-line mutations, albeit with different clinical phenotypes. But indeed for somatic mutations, we know the mutation(s) only after surgery.¹⁸ However, we are now trying to see if we can detect the presence of somatic mutations before surgery by analyzing the blood obtained from the AVS.

Professor Dominiczak: Yes, we would need to rely on the cells present in the AVS in a sufficient quantity for the DNA analysis. Once we have more large collections of patients, we will be able to predict genotype based on phenotype, hormones, and biology. That would be another way to go.

Conclusions

This case and the discussion illustrate the difficulties in managing patients with primary aldosteronism. AVS is a key step in the diagnosis of lateralized primary aldosteronism. The randomized study on AVS mentioned earlier in this discussion has since been published. The study raises several new questions on (1) the use of AVS as a gold standard, (2) the procedures of AVS, (3) the interpretations of AVS,⁹ and (4) opens the field for new multicentric prospective studies.

Acknowledgments

We thank Denise Kuo for her careful reading and corrections of the manuscript.

Disclosures

None.

References

1. Küpers EM, Amar L, Raynaud A, Plouin PF, Steichen O. A clinical prediction score to diagnose unilateral primary aldosteronism. *J Clin Endocrinol Metab.* 2012;97:3530–3537. doi: 10.1210/jc.2012-1917.

2. Powlson AS, Gurnell M, Brown MJ. Nuclear imaging in the diagnosis of primary aldosteronism. *Curr Opin Endocrinol Diabetes Obes.* 2015;22:150–156. doi: 10.1097/MED.0000000000000148.
3. Satoh F, Morimoto R, Ono Y, et al. Measurement of peripheral plasma 18-oxocortisol can discriminate unilateral adenoma from bilateral diseases in patients with primary aldosteronism. *Hypertension.* 2015;65:1096–1102. doi: 10.1161/HYPERTENSIONAHA.114.04453.
4. Steichen O, Lorthioir A, Zinzindohoue F, Plouin PF, Amar L. Outcomes of drug-based and surgical treatments for primary aldosteronism. *Adv Chronic Kidney Dis.* 2015;22:196–203. doi: 10.1053/j.ackd.2014.10.003.
5. Kempers MJ, Lenders JW, van Outhousden L, van der Wilt GJ, Schultze Kool LJ, Hermus AR, Deinum J. Systematic review: diagnostic procedures to differentiate unilateral from bilateral adrenal abnormality in primary aldosteronism. *Ann Intern Med.* 2009;151:329–337.
6. Kline GA, Dias VC, So B, Harvey A, Pasiaka JL. Despite limited specificity, computed tomography predicts lateralization and clinical outcome in primary aldosteronism. *World J Surg.* 2014;38:2855–2862. doi: 10.1007/s00268-014-2694-9.
7. Eisenhofer G, Dekkers T, Peitzsch M, Dietz AS, Bidlingmaier M, Treitl M, Williams TA, Bornstein SR, Haase M, Rump LC, Willenberg HS, Beuschlein F, Deinum J, Lenders JW, Reincke M. Mass spectrometry-based adrenal and peripheral venous steroid profiling for subtyping primary aldosteronism. *Clin Chem.* 2016;62:514–524. doi: 10.1373/clinchem.2015.251199.
8. Lim V, Guo Q, Grant CS, Thompson GB, Richards ML, Farley DR, Young WF Jr. Accuracy of adrenal imaging and adrenal venous sampling in predicting surgical cure of primary aldosteronism. *J Clin Endocrinol Metab.* 2014;99:2712–2719. doi: 10.1210/jc.2013-4146.
9. Dekkers T, Prejbisz A, Kool LJ, et al; SPARTACUS Investigators. Adrenal vein sampling versus CT scan to determine treatment in primary aldosteronism: an outcome-based randomised diagnostic trial. *Lancet Diabetes Endocrinol.* 2016;4:739–746. doi: 10.1016/S2213-8587(16)30100-0.
10. Rossi GP, Auchus RJ, Brown M, Lenders JW, Naruse M, Plouin PF, Satoh F, Young WF Jr. An expert consensus statement on use of adrenal vein sampling for the subtyping of primary aldosteronism. *Hypertension.* 2014;63:151–160. doi: 10.1161/HYPERTENSIONAHA.113.02097.
11. Dekkers T, Deinum J, Schultzekool LJ, Blondin D, Vonend O, Hermus AR, Peitzsch M, Rump LC, Antoch G, Sweep FC, Bornstein SR, Lenders JW, Willenberg HS, Eisenhofer G. Plasma metanephrine for assessing the selectivity of adrenal venous sampling. *Hypertension.* 2013;62:1152–1157. doi: 10.1161/HYPERTENSIONAHA.113.01601.
12. Haase M, Riester A, Kröpil P, Hahner S, Degenhart C, Willenberg HS, Reincke M. Outcome of adrenal vein sampling performed during concurrent mineralocorticoid receptor antagonist therapy. *J Clin Endocrinol Metab.* 2014;99:4397–4402. doi: 10.1210/jc.2014-2788.
13. Monticone S, Satoh F, Dietz AS, Goupil R, Lang K, Pizzolo F, Gordon RD, Morimoto R, Reincke M, Stowasser M, Mulatero P. Clinical management and outcomes of adrenal hemorrhage following adrenal vein sampling in primary aldosteronism. *Hypertension.* 2016;67:146–152. doi: 10.1161/HYPERTENSIONAHA.115.06305.
14. Pasternak JD, Epelboym I, Seiser N, Wingo M, Herman M, Cowan V, Gosnell JE, Shen WT, Kerlan RK Jr, Lee JA, Duh QY, Suh I. Diagnostic utility of data from adrenal venous sampling for primary aldosteronism despite failed cannulation of the right adrenal vein. *Surgery.* 2016;159:267–273. doi: 10.1016/j.surg.2015.06.048.
15. Vonend O, Ockenfels N, Gao X, et al; German Conn's Registry. Adrenal venous sampling: evaluation of the German Conn's registry. *Hypertension.* 2011;57:990–995. doi: 10.1161/HYPERTENSIONAHA.110.168484.
16. Lethielleux G, Amar L, Raynaud A, Plouin PF, Steichen O. Influence of diagnostic criteria on the interpretation of adrenal vein sampling. *Hypertension.* 2015;65:849–854. doi: 10.1161/HYPERTENSIONAHA.114.04812.
17. Burton TJ, Mackenzie IS, Balan K, Koo B, Bird N, Soloviev DV, Azizan EA, Aigbirhio F, Gurnell M, Brown MJ. Evaluation of the sensitivity and specificity of (11)C-metomidate positron emission tomography (PET)-CT for lateralizing aldosterone secretion by Conn's adenomas. *J Clin Endocrinol Metab.* 2012;97:100–109. doi: 10.1210/jc.2011-1537.
18. Fernandes-Rosa FL, Giscos-Douriez I, Amar L, Gomez-Sanchez CE, Meatchi T, Boulkroun S, Zennaro MC. Different somatic mutations in multinodular adrenals with aldosterone-producing adenoma. *Hypertension.* 2015;66:1014–1022. doi: 10.1161/HYPERTENSIONAHA.115.05993.