



**HAL**  
open science

## A Case of Disseminated Tuberculosis in a Child with Crohn's Disease After Treatment with Azathioprine, Adalimumab and Ustekinumab

Marie Catherine Renoux, Sarah Dutronc, Laura Kollen, Sarah Theret, Johan Moreau

► **To cite this version:**

Marie Catherine Renoux, Sarah Dutronc, Laura Kollen, Sarah Theret, Johan Moreau. A Case of Disseminated Tuberculosis in a Child with Crohn's Disease After Treatment with Azathioprine, Adalimumab and Ustekinumab. *Archivos de Bronconeumología*, 2020, 10.1016/j.arbres.2020.11.008 . hal-03109966

**HAL Id: hal-03109966**

**<https://hal.science/hal-03109966v1>**

Submitted on 2 Aug 2021

**HAL** is a multi-disciplinary open access archive for the deposit and dissemination of scientific research documents, whether they are published or not. The documents may come from teaching and research institutions in France or abroad, or from public or private research centers.

L'archive ouverte pluridisciplinaire **HAL**, est destinée au dépôt et à la diffusion de documents scientifiques de niveau recherche, publiés ou non, émanant des établissements d'enseignement et de recherche français ou étrangers, des laboratoires publics ou privés.

Marie Catherine Renoux<sup>a,\*</sup> Sarah Dutronc<sup>b</sup> Laura Kollen<sup>c</sup>  
Sarah Theret<sup>d</sup> Johan Moreau<sup>a,e</sup>

<sup>a</sup> Paediatric Pulmonology Department, Montpellier University Hospital, Montpellier, France

<sup>b</sup> Pediatric Immunology and Infectiology, Montpellier University Hospital, Montpellier, France

<sup>c</sup> Pediatric Hepato-gastroenterology Unit, Montpellier University Hospital, Montpellier, France

<sup>d</sup> East Occitania Regional Pharmacovigilance Centre, Montpellier University Hospital, Montpellier, France

<sup>e</sup> Unit Physiology and Experimental Biology of Heart and Muscles Laboratory-PHYMEDEXP, UMR CNRS 9214, INSERM U1046, University of Montpellier, Montpellier, France

\* Corresponding author.

E-mail address: [mc-renoux@chu-montpellier.fr](mailto:mc-renoux@chu-montpellier.fr) (M.C. Renoux).

---

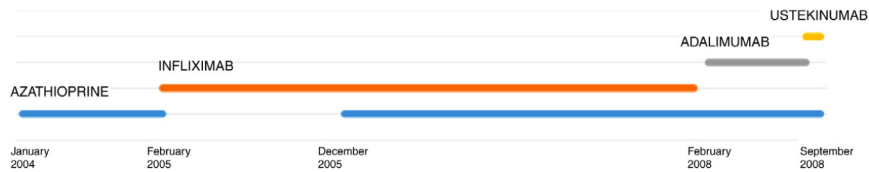
### **A Case of Disseminated Tuberculosis in a Child with Crohn's Disease After Treatment with Azathioprine, Adalimumab and Ustekinumab**

#### ***Un caso de tuberculosis diseminada en un niño con enfermedad de Crohn tras tratamiento con azatioprina, adalimumab y ustekinumab***

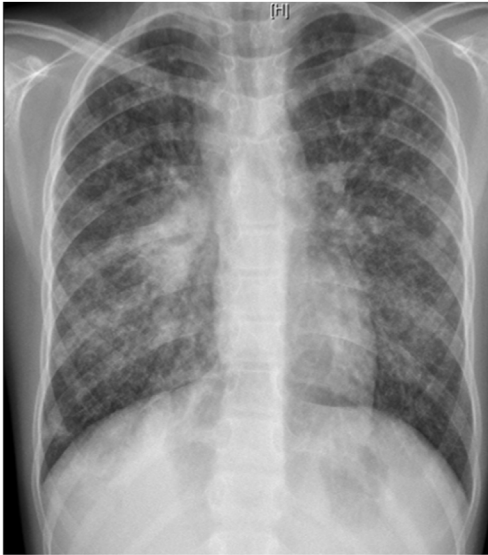We report the case of an 11-year-old girl with refractory Crohn's disease treated with ustekinumab, hospitalized for disseminated tuberculosis. This is the first case of disseminated tuberculosis in a child under anti-IL12 - IL23 treatment described in literature.

L. was diagnosed with Crohn's disease at the age of 7. She was first treated with oral corticosteroids for 9 months, then aza-

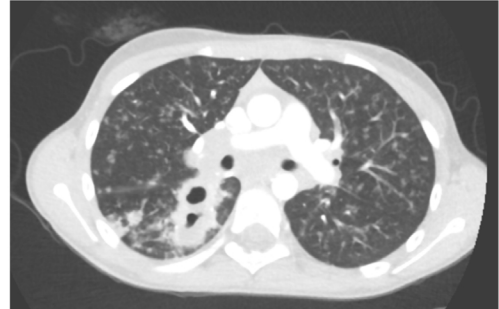thioprine. Because of persistent symptoms, anti-tumor necrosis factor agents (first infliximab during 3 years, and then adalimumab for 6 months) were added to azathioprine. The child had received BCG vaccination when aged 2 months. The tuberculin skin test was negative, and IGRAs (interferon gamma release assays = QuantiFERON-TB-Gold Cellestis) results were indeterminate before starting anti TNF agents. Abdominal pain, diarrhea, with evening rise fever were persistent despite anti TNF agents. One month after adalimumab was dropped when the child was eleven; ustekinumab treatment was started together with azathioprine, after a collective decision of pediatric and adult gastroenterologists (Fig. 1). No chest X-ray was performed before starting ustekinumab. It was started after 15 days of oral corticosteroids (budesonide 9 mg per day). Fifteen days after the first injection of ustekinumab (6 mg/kg intravenously), she was referred to our pediatric pul-



**Fig. 1.** Chronology of treatments for Chron's disease.



**Fig. 2.** Chest X-ray: diffuse alveolo-interstitial opacities, with right parahilar consolidation with central cavitation.



**Fig. 3.** Thoracic computed tomography: disseminated tuberculosis.

punctiform enhancement consistent with a right and left cerebellous granuloma, lumbar puncture was sterile, and neurological examination was normal with no cerebellous syndrome. Tuberculosis treatment was started with 2 months of quadritherapy: isoniazid–rifampicin–ethambutol and pyrazinamide, followed by 10 months of isoniazid and rifampicin (because of cerebral involvement). Azathioprine was temporarily suspended. The young patient was treated with corticosteroids (prednisolone 1 mg/kg/day 15 days, with progressive weaning) in prevention of immune reconstitution inflammatory syndrome, and because of bronchial obstruction. Enteral nutrition was added because of undernourishment. On follow up, apyrexia was prolonged, the cough disappeared and the patient gained weight. Chest X-ray after 1 month of treatment was back to normal.

This is the first case described of disseminated TB in a child under ustekinumab for Chron's disease. Disseminated TB in this child was suspected on chest X-ray (and CT scan) and confirmed by the presence of *Mycobacterium tuberculosis* on sputum smear, BAL, and post FB gastric aspirate.

Miliary or disseminated tuberculosis results from massive lymphohematogenous dissemination of *Mycobacterium tuberculosis*. Miliary TB represents 1–2% of TB cases. It occurs 2–6 months after initial infection, but can be more precocious in infants. Diagnosing miliary tuberculosis can be a challenge:

- Clinical manifestations are nonspecific as in this case. Miliary TB develops less often in children than in infants, especially if BCG vaccination was done.
- IGRA or tuberculin skin test can be negative (in 35–74% of miliary cases), as in our case.
- Typical chest radiograph findings may not be obvious until late in the disease. Typical findings on chest X-ray are collections of tiny discrete pulmonary opacities that are generally uniform in size and widespread in distribution, each of them measuring 2 mm or less in diameter. In 10% of cases, nodules can be wider than 3 mm in diameter, as in this case.
- Mycobacterial identification is positive in less than 50% of cases with FB.

It is rare in developed countries, and usually happens in infants or immunocompromised children (such as HIV infection)<sup>1,2</sup> and in adults after organ transplant, in chronic hemodialysis programs,

monology unit for persistent fever, dry cough and weight loss. On clinical examination: oxygen pulse oximetry: 97% (room air); temperature: 39 °C; no tachypnea or retraction signs; auscultation showed crackles in the right inferior lobe. Chest X-ray (Fig. 2) showed diffuse alveolo-interstitial opacities, with right parahilar consolidation with central cavitation that is over the helium of 51 mm × 36 mm, and nodules with diffuse distribution of 2–4 mm. Blood test showed moderate inflammation (C-reactive protein 80 mg/l). Viral and bacterial nasopharyngeal aspirates were negative (*Mycoplasma* and *Chlamydia pneumoniae*, multiplex viral PCR). Fiberoptic bronchoscopy showed obstruction of the apical bronchi of the right inferior lobe by endobronchial granuloma. Bronchoalveolar lavage showed normal cellularity, with lymphocytosis (=135 cells/mm<sup>3</sup>, with 33% macrophages, 51% lymphocytes, 16% neutrophils). Bacterial culture was negative, as well as respiratory viruses and mycology culture (*Pneumocystis jirovecii*) on BAL. Acid fast bacilli (AFB) was detected by microscopy using Ziehl Neelsen stain on BAL, sputum smear and post bronchoscopy gastric aspirate. Culture grew for multisensibile *Mycobacterium tuberculosis*. At that time, tuberculin skin test was negative, and IGRA (QuantiFERON-TB-Gold Cellestis) was indeterminate. There were no close contacts with tuberculosis. Thoracic computed tomography (Fig. 3) was consistent with disseminated tuberculosis. In both lungs there are multiple nodules being the largest in the superior segment of the right lobe where there are bigger than those located in other lobes; multiple adenopathy in the right hilar and interlobar regions; and condensation of 35 mm × 26 mm of the apical segment of the right inferior lobe, with two central excavation of 12 mm × 5 mm and 10 mm × 7 mm.

Because of disseminated tuberculosis, a search for multiorgan involvement was carried out: urinary culture was negative; abdominorenal echography, echocardiography, bone scintigraphy, ophthalmoscopic examination were normal. Cerebral MRI showed

or in cases of use of immunosuppressive drugs such as anti-TNF. Recently because of novel therapies, cases of tuberculosis have been rising in adult patients under anti-tumor necrosis factor agents, such as infliximab, adalimumab or etanercept.<sup>3</sup> In this case, ustekinumab, adalimumab or azathioprine may be responsible of disseminated TB or even the association of these immunosuppressive treatments. A pharmacovigilance study was conducted in this case: imputability score of ustekinumab was 5/6 according to French imputability scoring method.<sup>4</sup>

Ustekinumab is a human monoclonal antibody against interleukin IL12 and IL23 p40. It is indicated in moderate to severe Crohn's disease in adults, with incomplete response, loss of response, intolerance of conventional treatment or anti TNF agents, contraindications to these. Its major contraindication is infection, especially TB. Nevertheless, the risk of tuberculosis infection was observed to be lower than in patients who had received anti-TNF agents. Only 11 publications relate drug-induced respiratory disease with ustekinumab: eosinophilic pneumonia, interstitial pneumonia, organizing pneumonia, hypersensitivity pneumonitis, *Mycobacterium abscessus* infection, *Legionella pneumophila* pneumonia. Only few cases of TB (latent tuberculosis reactivation, peripheral lymph node recurrence, peritoneal tuberculosis) under ustekinumab in adult patients have been published.<sup>6-9</sup> IL12 has a role, so as IL23, in initiation and control of cellular response against TB. Individuals having deficiency in IL12B gene coding for p40 have a mendelian susceptibility to mycobacterial infections. This suggests that IL12/23/INF gamma axis is specifically dedicated in controlling mycobacterial infections, and inhibiting these cytokines can favor such infections. National OMS database "Vigibase" reports 88 cases of TB with ustekinumab being suspected, with no children. Such arguments are in favor of ustekinumab imputability in disseminated TB in this child.

Nevertheless, azathioprine and adalimumab can potentially be implicated in this disseminated TB:

- Azathioprine as an immunosuppressive treatment can be responsible of pulmonary infections (viral, fungal or bacterial); but she already had this treatment for many years.
- Anti TNF agents: risks of TB, specially under adalimumab are well described. In a prospective study of patients under anti TNF-alpha agents: miliary TB represented 27, 5% of all cases of TB, TB was more frequent in patients under infliximab and adalimumab.<sup>3</sup>

Before starting ustekinumab, LTBI (latent tuberculosis infection) should be screened. There are few data available on the effect of immunomodulatory/biological therapy on the accuracy of TST and IGRA in BCG vaccinated immunosuppressed patients with inflammatory bowel disease (IBD). IGRA alone was more effective to detect LTBI than TST alone in a Brazilian IBD cohort ( $n=103$ ) (endemic area for TB, vaccinated population). In addition, IGRA had a ~60% added value as an add-on sequential test, particularly important in CD patients.<sup>5</sup>

Although currently there is no gold standard for screening LTBI, especially in the immunosuppressed population, IGRA has become the preferred method in countries with low TB incidence. The combination of TST and IGRA (even using the two commercial IGRAs

available, QuantiFERON and T-Spot. TB), can improve the diagnosis sensitivity of LTBI and the initiation of its treatment.<sup>10</sup>

This is the first case described of disseminated TB in a child under ustekinumab, azathioprine and adalimumab, for Chron's disease.

IGRA and/or tuberculin skin test should be performed before initiating any immunosuppressive treatment in case of Crohn's disease, especially if anti-TNF agents or ustekinumab could be used during follow-up.

## References

1. Underwood J, Cresswell F, Salam AP, Keeley AJ, Cleland C, John L, et al. Complications of miliary tuberculosis: low mortality and predictive biomarkers from a UK cohort. *BMC Infect Dis.* 2017;17:295.
2. Hussey G, Chilsom T, Kibel M. Miliary tuberculosis in children: a review of 94 cases. *Pediatr Infect Dis J.* 1991;10:832-6.
3. Dixon WG, Hyrich KL, Watson KD, Lunt M, Galloway J, Ustianowski A. Drug-specific risk of tuberculosis in patients with rheumatoid arthritis treated with anti TNF therapy: results from the British Society for Rheumatology Biologics Register. *Ann Rheum Dis.* 2010;69:552-8.
4. Update of the French drug reaction assessment method. Cercle de réflexion sur l'imputabilité (CRI). *Thérapie.* 2011;66:517-25.
5. Amorim R, Viegas E, Carneiro A, Esberard B, Chinem E, Correa R. Superiority of interferon gamma assay over tuberculin skin test for latent tuberculosis in inflammatory bowel disease patients in Brazil. *Dig Dis Sci.* 2019;64:1916-22.
6. Errichetti E, Piccirillo A. Latent tuberculosis reactivation in a patient with erythrodermic psoriasis under treatment with ustekinumab and a low dose steroid, despite isoniazid chemoprophylaxis. *Eur J Dermatol.* 2014;24:508-9.
7. Tsai TF, Chiu HY, Song M, Chan D. A case of latent tuberculosis reactivation in a patient treated with ustekinumab without concomitant isoniazid chemoprophylaxis in the PEARL trial. *Br J Dermatol.* 2013;168:444-6.
8. Sanchez-Moya A, Dauden E. Peripheral lymph node recurrence of tuberculosis after ustekinumab treatment. *Arch Dermatol.* 2012;148:1332-3.
9. Lynch M, Roche L, Horgan M, Ahmad K, Hackett C, Ramsay B. Peritoneal tuberculosis in the setting of ustekinumab treatment for psoriasis. *JAAD Case Rep.* 2017;3:230-2.
10. Fernández-Blázquez A, Argüelles Menéndez P, Sabater-Cabrera C, García-García JM, Asensi-Álvarez V, Palacios-Gutiérrez JJ. Diagnosis of tuberculous infection in immunosuppressed patients and/or candidates for biologics using a combination of 2 IGRA tests: T-SPOT.TB/QuantiFERON TB Gold In-Tube vs T-SPOT.TB/QuantiFERON TB Gold Plus. *Arch Bronconeumol.* 2020. S0300-2896(20)30128-9.

Marie Catherine Renoux<sup>a,\*</sup> Sarah Dutronc<sup>b</sup> Laura Kollen<sup>c</sup>  
Sarah Theret<sup>d</sup> Johan Moreau<sup>a,e</sup>

<sup>a</sup> Paediatric Pulmonology Department, Montpellier University Hospital, Montpellier, France

<sup>b</sup> Pediatric Immunology and Infectiology, Montpellier University Hospital, Montpellier, France

<sup>c</sup> Pediatric Hepato-gastroenterology Unit, Montpellier University Hospital, Montpellier, France

<sup>d</sup> East Occitania Regional Pharmacovigilance Centre, Montpellier University Hospital, Montpellier, France

<sup>e</sup> Unit Physiology and Experimental Biology of Heart and Muscles Laboratory-PHYMEDEXP, UMR CNRS 9214, INSERM U1046, University of Montpellier, Montpellier, France

\* Corresponding author.

E-mail address: [mc-renoux@chu-montpellier.fr](mailto:mc-renoux@chu-montpellier.fr) (M.C. Renoux).