



**HAL**  
open science

## Exploring copy number variants in deceased fetuses and neonates with abnormal vertebral patterns and cervical ribs

Pauline Schut, Erwin Brosens, Tom Van J M Dooren, Frietson Galis, Clara Broek, Inge Baijens, Marjolein Dremmen, Dick Tibboel, Martin Schol, Annelies Klein, et al.

► **To cite this version:**

Pauline Schut, Erwin Brosens, Tom Van J M Dooren, Frietson Galis, Clara Broek, et al.. Exploring copy number variants in deceased fetuses and neonates with abnormal vertebral patterns and cervical ribs. *Birth Defects Research*, In press, 112 (18), pp.1513-1525. 10.1002/bdr2.1786 . hal-03096273

**HAL Id: hal-03096273**

**<https://hal.science/hal-03096273>**

Submitted on 27 Jun 2023



**HAL** is a multi-disciplinary open access archive for the deposit and dissemination of scientific research documents, whether they are published or not. The documents may come from teaching and research institutions in France or abroad, or from public or private research centers.

L'archive ouverte pluridisciplinaire **HAL**, est destinée au dépôt et à la diffusion de documents scientifiques de niveau recherche, publiés ou non, émanant des établissements d'enseignement et de recherche français ou étrangers, des laboratoires publics ou privés.



Distributed under a Creative Commons Attribution - NonCommercial 4.0 International License

# Exploring copy number variants in deceased fetuses and neonates with abnormal vertebral patterns and cervical ribs

Pauline C. Schut<sup>1</sup>  | Erwin Brosens<sup>2</sup>  | Tom J. M. Van Dooren<sup>3,4</sup> |  
Frietson Galis<sup>3</sup> | Clara M. A. ten Broek<sup>3</sup> | Inge M. M. Baijens<sup>1</sup> |  
Marjolein H. G. Dremmen<sup>5</sup> | Dick Tibboel<sup>6</sup> | Martin P. Schol<sup>2</sup> |  
Annelies de Klein<sup>2</sup> | Alex J. Eggink<sup>1</sup> | Titia E. Cohen-Overbeek<sup>1</sup>

<sup>1</sup>Department of Obstetrics and Gynecology, Division of Obstetrics and Fetal Medicine, Erasmus MC, University Medical Center Rotterdam, Rotterdam, The Netherlands

<sup>2</sup>Department of Clinical Genetics, Erasmus MC, University Medical Center Rotterdam, Rotterdam, The Netherlands

<sup>3</sup>Naturalis Biodiversity Center, Leiden, The Netherlands

<sup>4</sup>CNRS, Institute of Ecology and Environmental Sciences iEES Paris, Sorbonne University, Paris, France

<sup>5</sup>Department of Radiology, Division of Paediatric Radiology, Erasmus MC, University Medical Center Rotterdam, Rotterdam, The Netherlands

<sup>6</sup>Department of Paediatric Surgery, Erasmus MC, Erasmus University Medical Center Sophia Children's Hospital, Rotterdam, The Netherlands

## Correspondence

Pauline C. Schut, Department of Obstetrics and Gynecology, Erasmus, MC, Division of Obstetrics and Fetal Medicine, University Medical Center Rotterdam, Rotterdam, The Netherlands; Room Na-1608 Postbus 2040 3000 CA Rotterdam, The Netherlands.  
Email: p.schut@erasmusmc.nl

## Abstract

**Background:** Cervical patterning abnormalities are rare in the general population, but one variant, cervical ribs, is particularly common in deceased fetuses and neonates. The discrepancy between the incidence in the general population and early mortality is likely due to indirect selection against cervical ribs. The cause for the co-occurrence of cervical ribs and adverse outcome remains unidentified. Copy number variations resulting in gain or loss of specific genes involved in development and patterning could play a causative role.

**Methods:** Radiographs of 374 deceased fetuses and infants, including terminations of pregnancies, stillbirths and neonatal deaths, were assessed. Copy number profiles of 265 patients were determined using single nucleotide polymorphism array.

**Results:** 274/374 patients (73.3%) had an abnormal vertebral pattern, which was associated with congenital abnormalities. Cervical ribs were present in 188/374 (50.3%) and were more common in stillbirths (69/128 [53.9%]) and terminations of pregnancies (101/188 [53.7%]), compared to live births (18/58, 31.0%). Large (likely) deleterious copy number variants and aneuploidies were prevalent in these patients. None of the rare copy number variants were recurrent or overlapped with candidate genes for vertebral patterning.

**Conclusions:** The large variety of copy number variants in deceased fetuses and neonates with similar abnormalities of the vertebral pattern probably reflects the etiological heterogeneity of vertebral patterning abnormalities. This genetic heterogeneity corresponds with the hypothesis that cervical ribs can be regarded as a sign of disruption of critical, highly interactive stages of embryogenesis. The vertebral pattern can probably provide valuable information regarding fetal and neonatal outcome.

## KEYWORDS

cervical ribs, congenital anomalies, copy number variations, SNP arrays, vertebral pattern

This is an open access article under the terms of the Creative Commons Attribution-NonCommercial License, which permits use, distribution and reproduction in any medium, provided the original work is properly cited and is not used for commercial purposes.

© 2020 The Authors. *Birth Defects Research* published by Wiley Periodicals LLC.

## 1 | INTRODUCTION

The human vertebral column normally consists of 7 cervical, 12 thoracic, 5 lumbar, 5 sacral and 3–4 coccygeal vertebrae. Only the thoracic vertebrae are rib-bearing. Deviations from this vertebral pattern are rare in healthy individuals, particularly in the cervical region (Galis, 1999); (Henry et al., 2018). However, variations in cervical patterning, including (rudimentary) cervical ribs, have been described to be common in specific populations (Brewin, Hill, & Ellis, 2009; Etter, 1944). In case of cervical ribs, a partial or full posterior homeotic transformation of the seventh cervical vertebra has occurred, because the vertebra has features of a rib-bearing thoracic vertebra. This results in a change in the number of true cervical and thoracic vertebrae and consequently to a shift of the cervicothoracic boundary (Bots et al., 2011).

It has been hypothesized that the lack of variation in cervical vertebral patterning in the general population is the result of strong selection against changes (Galis et al., 2006; Narita & Kuratani, 2005; Ten Broek et al., 2012; Varela-Lasheras et al., 2011). The low prevalence of cervical ribs in healthy pediatric or adult populations, compared to the high prevalence in deceased fetuses and neonates, supports this hypothesis of selection (Galis et al., 2006; Schut et al., 2016). A high prevalence of abnormalities in vertebral patterning is also found in children with specific pediatric malignancies (Loder, Huffman, Toney, Wurtz, & Fallon, 2007; Merks et al., 2005; Schumacher, Mai, & Gutjahr, 1992; Zierhut, Murati, Holm, Hoggard, & Spector, 2011). Galis et al. (2006) concluded that the majority of individuals with cervical ribs are not expected to reach reproductive age. While the presence of cervical ribs is usually not direct life-threatening, cervical ribs could be regarded as markers of disadvantageous embryonic development, which in turn can result in an adverse outcome (Furtado, Thaker, Erickson, Shirts, & Opitz, 2011). The underlying causal mechanism of the association between abnormalities in vertebral patterning and other adverse developmental effects is currently unknown, but the strong interactions between anterior–posterior patterning and the development of different organ systems at early embryonic stages are thought to play a key role (Schut et al., 2019; Ten Broek et al., 2012). Disruption of the cervical vertebral pattern is expected to be more harmful than disruptions at the thoracic or lumbar level, because the caudal regions of the vertebral column develop later, during less vulnerable and interactive stages (Galis et al., 2006; Ten Broek et al., 2012).

Abnormal Homeobox (*HOX*) gene expression is known to be a causal factor (Galis, 1999). *HOX* genes are a group of highly conserved genes that have an important function in various developmental processes, including anteroposterior

patterning and determination of vertebral identity (Lappin, Grier, Thompson, & Halliday, 2006; Mallo, Wellik, & Deschamps, 2010; Quinonez & Innis, 2014). A large body of experiments on mice, chicks and other animals, have shown that changed expression of specific *HOX* genes leads to homeotic transformations of vertebrae and abnormalities in different organ systems (Horan, Wu, Wolgemuth, & Behringer, 1994; Mallo et al., 2010; Manley & Capecchi, 1998; Wellik, Hawkes, & Capecchi, 2002). Altered *HOX* gene expression has also been associated with the development of a large number of malignancies (Li, Huang, & Wei, 2019; J. Smith, Zyoud, & Allegrucci, 2019).

The expression of *HOX* genes can be influenced by a large variety of genetic and non-genetic factors (Casaca, Santos, & Mallo, 2014; Giampietro et al., 2013), and mechanisms involved in the timing of *HOX* gene expression have also been shown to influence vertebral patterning (Casaca et al., 2014). We therefore predict that similar abnormalities of the vertebral pattern in different individuals can have different genetic or non-genetic causes.

To detect chromosomal anomalies, copy number profiling has largely replaced karyotyping in the prenatal detection of chromosomal aberrations. Microarray diagnostic yield is 3–9% in patients with a structural anatomical anomaly on ultrasound and 1–2% without (de Wit et al., 2014; Wapner et al., 2012). The diagnostic yield depends on the type and number of anatomical systems affected (de Wit et al., 2014) and we hypothesize that the prevalence of an abnormal vertebral pattern is similarly indicative of the presence of structural and/or chromosomal anomalies. We aimed to study the possible impact of DNA Copy Number Variations (CNVs) in coding regions and/or disturbing enhancers on the development of the pattern of the vertebral column in a cohort of deceased fetuses and neonates, of whom, based on the literature (Ten Broek et al., 2012), most are expected to have an abnormal vertebral pattern.

The presence of various CNVs in patients with similar abnormalities of the vertebral pattern and the absence of a unifying CNV would support the expected genetic heterogeneity of vertebral patterning abnormalities. Other aims of the current study were to determine whether abnormal vertebral patterns or cervical ribs are associated with (specific) structural anomalies, or whether these seem to be independently associated with stillbirth in this cohort.

## 2 | METHODS

### 2.1 | Study population

The cohort consisted of fetuses and infants, younger than 1-year-old, deceased between 2009 and 2015 in the

Erasmus University Medical Center Sophia Children's Hospital, of whom a babygram, autopsy report and/or SNP Array was available. Spontaneous intrauterine fetal demise and medically indicated terminations of pregnancies were included. Medical information about mothers, fetuses and neonates were retrieved from electronic medical records. Pregnant women were routinely questioned concerning their smoking behavior and the periconceptional use of folic acid at their initial appointment and this information was also collected from the medical file.

Babygrams were made routinely if autopsy was performed. Autopsies were performed according to the national guidelines. ("https://www.nvk.nl/Nieuws/Dossiers/NODO," September 12th 2018) Congenital anomalies were categorized according to the European Registry of Congenital Anomalies and Twins (Eurocat) classification system. (EUROCAT, 2012) If autopsy had not been performed, the presence of malformations was based on the report of the prenatal advanced ultrasound scan, pre- or postnatal radiographic investigations or post-mortem external inspection. If none of these investigations had been requested, or the results were inconclusive (e.g., due to maceration), the presence of congenital anomalies was categorized as non-available.

Babygrams were evaluated for assessment of the vertebral pattern. Radiographs were made both ventrally and laterally (5.6–12.6 mAs, 40–50 kV, Philips Optimus ZBM3/NZR91, Philips Medical Systems, Eindhoven, the Netherlands). Radiographs performed at other hospitals were requested. All radiographs were assessed by one

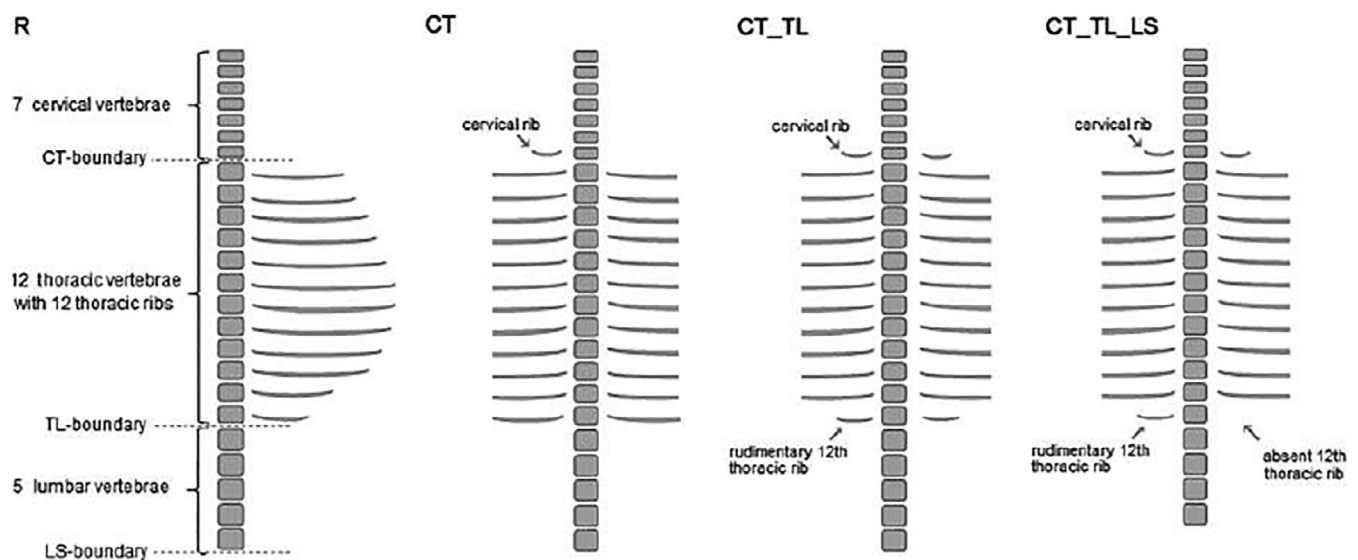
reviewer (PS), who was blinded for the autopsy results and the results of genetic investigations. Rudimentary ribs and the vertebral pattern were defined following Ten Broek et al. (2012): if a rib on the most cranial or most caudal thoracic vertebra had a length of less than half of the rib of the adjacent thoracic vertebra, it was considered rudimentary. Rudimentary cervical ribs were scored if the length of the transverse processes of the seventh cervical vertebra was more than the transverse process of the first thoracic vertebra, but less than half of the first thoracic rib. If the rib was longer than half of the first thoracic rib, it was considered a (complete) cervical rib. Deviations from the normal vertebral pattern were classified as more severe when cranially located vertebral regions and multiple vertebral regions were involved (Figure 1).

A subset of 30 randomly chosen radiographs was assessed twice by the same reviewer and by a second reviewer (SH), to determine the intraobserver and interobserver variability.

The study protocol was approved by the institutional ethics committee (Medical Research Ethics Committee Erasmus MC, MEC-2014-098). All methods were performed in accordance with relevant guidelines and regulations.

## 2.2 | Analysis of copy number variation

DNA was isolated from material that was collected in patients opting for invasive prenatal or postnatal



**FIGURE 1** Overview of different vertebral columns and number on severity scale. From left to right: R, Regular pattern, severity scale value 0; CT, shift at the cervicothoracic boundary, severity scale value 4; CT\_TL, shift at the cervicothoracic and thoracolumbar boundary, severity scale value 6; CT\_TL\_LS, shift at cervicothoracic, thoracolumbar and lumbosacral boundary, severity scale value 7

diagnostic tests. We determined genome wide CNV profiles in all coding and non-coding regions of patients ( $n = 265$ ) using methods and analysis settings previously described (Brosens et al., 2016). We focused on relatively large CNVs (>50 kb) that are present in less than 1 in 4,000 unaffected individuals (Coe et al., 2014; Cooper et al., 2011), as it is unlikely that more prevalent large CNV contribute to structural anatomical malformations. CNV profiles were inspected visually in Biodiscovery Nexus CN8.0. (Biodiscovery Inc., Hawthorne, CA). Rare CNVs were classified as (likely) deleterious, variants of uncertain significance or likely benign (see Table 1) and inspected for overlap with candidate genes, such as HOX genes and genes previously reported to be associated with vertebral anomalies in VACTER-L patients (Chen et al., 2016; Solomon et al., 2012). A Gene Ontology term enrichment analysis was performed in order to determine whether genes impacted by the rare CNVs were enriched for relevant biological processes compared to the *Homo sapiens* reference gene set in three groups of patients: patients with extra cervical ribs and vertebral patterning abnormalities (CNV<sub>n</sub> = 42, group 1), patients without extra cervical ribs but with other vertebral patterning abnormalities (CNV<sub>n</sub> = 23, group 2) and patients without cervical ribs nor other vertebral patterning abnormalities (CNV<sub>n</sub> = 23, group 3). A more detailed description of this analysis can be found in the Supporting Information.

**TABLE 1** Rare CNVs in prenatal cohort

Copy number loss		Number of CNVs
Deleterious	≥2 Mb <sup>a</sup>	10
Likely deleterious	≥1 Mb	6
VOUS	≤1 Mb inheritance unspecified	20
Likely benign	Present in DDD controls	7
		43
Copy number gain		
Deleterious	≥3 Mb or overlapping dominant disease genes	4
Likely deleterious	≥2 Mb	3
VOUS	≤1 Mb inheritance unspecified	17
Likely benign	Present in DDD controls	5
		29

<sup>a</sup>The rare CNVs at 6q27 are classified as Deleterious. Abbreviations: CNV, copy number variant; DDD, deciphering developmental disorders.

## 2.3 | Statistical analysis

Statistical analysis was performed using SPSS Statistics (IBM Corp. Released 2013. IBM SPSS Statistics for Windows, Version 21.0. Armonk, NY: IBM Corp.) and R (RCT 2017). Descriptive statistics were used to evaluate outcome occurrences. To study associations while accounting for the overall relative occurrences of each outcome, we carried out log-linear statistical modeling of the numbers of observations for each combination of categorical variables (Agresti, 2018). These analyses started from maximal log-linear models fitted to the data including up to three-way interactions between variables (vertebral pattern, presence of congenital anomalies and other explanatory variables). We subsequently tested using likelihood ratio tests whether interactions could be removed from the model. Interactions were also removed when their parameter estimates were very imprecise (standard deviations orders of magnitude larger than estimates). An iterative simplification procedure of this kind resulted in models for associations that only contained significant interactions between variables, which we inspected and interpreted. Main effects were never removed. Our main interest was in associations involving vertebral and congenital anomalies. Any remaining third-order interactions in the selected models involving them were interpreted following Elliott (1988): the associations between these anomalies for each level of the third variable involved were estimated and compared. In order to limit the number of models to compare and tests to perform, the number of categories for many variables was reduced, which also applied to the categories of the vertebral pattern. Separate log-linear models for the presence of an abnormal vertebral pattern and for the presence of a cervical rib among the cases with an abnormal vertebral pattern were thus compared. In addition, to study non-additive and cumulative effects of the presence of different congenital anomalies on vertebral patterning, models that included interactions between the presence of each category of congenital anomaly or regression slopes of the number of organ systems affected by congenital anomalies were fitted. To assess the effects of maternal BMI and gestational age, logistic regressions for the presence of an abnormal vertebral pattern or the presence of a cervical rib among the cases that included these variables were fitted. For data assessment, differences between groups were assessed using independent sample *t*-tests for continuous data and chi-squared tests and Fisher's exact tests for categorical data. To assess effects and associations in the logistic regressions and log-linear models, we carried out *z*-tests on the parameter estimates of the models. Tail probabilities below 0.05 were considered statistically significant. Kappa's test was

performed in order to determine the interobserver and intraobserver reliability. Kappa values between 0.61 and 0.80 were considered to be substantial and kappa values between 0.81 and 1.00 were considered almost perfect (Landis & Koch, 1977).

### 3 | RESULTS

The study population consisted of 374 fetuses and 71 neonates. In 71 fetuses and neonates (16.0%), the vertebral pattern could not be reliably assessed by radiography. This was due to inadequate positioning of the fetus or neonate, overprojection of the maxilla, clavicles or umbilical cord clamp, or low quality of the babygram. Excluding these 71 patients, 316 fetuses and 58 neonates were available for analysis of the pattern of the vertebral column. No statistically significant differences were found between the included and excluded patients in gestational age, presence or type of congenital anomaly and

pregnancy outcome (Table S1). Of the 374 included fetuses and neonates, 188 (50.3%) pregnancies were terminated because of medical reasons, mostly (suspected) fetal structural, chromosomal or other genetic anomalies ( $N = 180/188$ , 95.7%). Other medical indications for pregnancy terminations were severe fetal growth restriction ( $N = 1$ , 0.5%), preterm premature rupture of membranes ( $N = 3$ , 1.6%) or poor maternal condition in pregnancies with early onset severe pre-eclampsia or HELLP syndrome ( $N = 4$ , 2.1%). The second largest group consisted of miscarriages or intrauterine fetal demises (128/374, 34.2%). The majority of the 58 neonatal deaths was related to structural anomalies (43/58, 74.1%). Most other causes of neonatal death were associated with prematurity (Table S2).

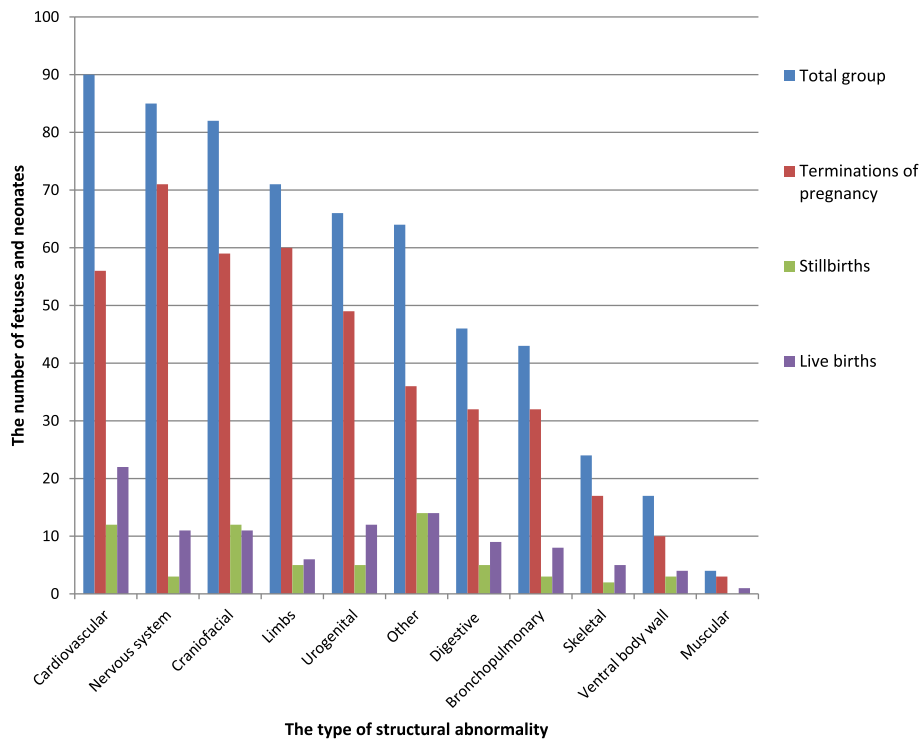
An overview of maternal, fetal and neonatal characteristics is provided in Table 2. The inclusion of multiple pregnancies and more than one pregnancy per mother resulted in a total number of 366 included mothers. Autopsy was performed in the majority of patients

**TABLE 2** Characteristics of mothers, fetuses and neonates with a known vertebral pattern of the fetuses and neonates

Mothers	N (366) (%)	Fetuses/neonates	N (374) (%)
Age (years)	31.0 (15–44)	Sex	
BMI (kg/m <sup>2</sup> )	23.6 (16.4–44.6)	Male	208 (55.6)
Missing	73	Female	166 (44.4)
Smoking		Pregnancy outcome	
Yes	44 (12.0)	Miscarriages and stillbirths	128 (34.2)
Quit	15 (4.1)	Live births	58 (15.5)
No	259 (70.8)	Neonatal death < 1wk	45 (77.6)
Unknown	48 (13.1)	Termination of pregnancy	188 (50.3)
Parity		Gestational age at birth (weeks)	22.7 (11.9–41.3)
Primigravida	125 (34.2)	Live births	30.9 (22.3–41.3)
Multigravida	239 (65.3)	Miscarriages and stillbirths	22.6 (13.6–40.3)
Unknown	2 (0.5)	Terminations of pregnancy	22.0 (11.9–33.6)
Folic acid		Multiple pregnancies	
Yes, preconception	140 (38.3)	Single	347 (92.8)
Yes, postconception	118 (32.2)	Twins	26 (7.0)
No	38 (10.4)	Triplets	1 (0.3)
Unknown	70 (19.2)		
Conception		Birth weight	
Spontaneous	289 (79.0)	<p5	125 (33.4)
IVF	7 (1.9)	P5–p95	192 (51.3)
ICSI	7 (1.9)	>p95	31 (8.3)
Other	12 (3.3)	Unknown	26 (7.0)
Unknown	51 (13.9)		

Note: Data are presented as number (percentage) or median and (range).

Abbreviations: BMI, body mass index; ICSI, intracytoplasmic sperm injection; IVF, in vitro fertilization.

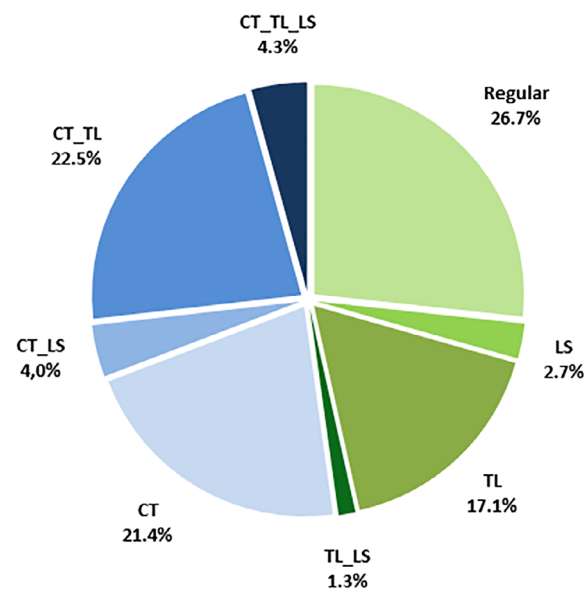


**FIGURE 2** The distribution of structural abnormalities in the total study population and subgroups of live births, stillbirths and terminations of pregnancy. CT, shift at the cervicothoracic boundary; CT\_LS, shift at cervicothoracic and lumbosacral boundary; CT\_TL\_LS, shift at cervicothoracic, thoracolumbar and lumbosacral boundary; CT\_TL, shift at the cervicothoracic and thoracolumbar boundary; TL\_LS, shift at thoracolumbar and lumbosacral boundary

( $N = 305$ , 81.6%). In 35 of the 69 patients in whom no autopsy was performed, an advanced ultrasound examination was carried out (9.4%). The presence of structural abnormalities could not be ascertained in 40 patients. This included 31 still births, 6 terminations of pregnancy and 3 live births. In 33 of these patients, neither autopsy nor advanced ultrasound examination had been performed. In 7 patients, the results of autopsy or advanced ultrasound examination were inconclusive.

Structural anomalies were present in a large proportion of the group (256/334, 76.6%) and the prevalence was highest in the subgroup of pregnancy terminations (173/182, 95.1%), compared to 43/55 (78.2%) in live births and 40/97 (41.2%) in stillbirths. In more than half of the patients with a structural anomaly, more than one organ system was affected (146/256, 57.0%). The most frequently affected organ systems were the cardiovascular ( $N = 90$ ), nervous ( $N = 85$ ), craniofacial ( $N = 82$ ), limbs ( $N = 71$ ) and urogenital ( $N = 66$ ) system (Figure 2).

A regular vertebral pattern was identified in approximately one quarter of patients (100/374, 26.7%, Figure 3). Of the 274 patients (73.3%) with an abnormal vertebral pattern, the cervicothoracic (CT) region was most often affected ( $N = 195/274$ , 71.2%), either exclusively, or in combination with thoracolumbar (TL) and/or lumbosacral (LS) shifts (CT ( $N = 80$ , 21.4%), CT\_LS ( $N = 15$ , 4.0%), CT\_TL ( $N = 84$ , 22.5%), CT\_TL\_LS ( $N = 16$ , 4.3%)). Cervical ribs were seen in approximately half of the patients (188/374, 50.3%). In the majority, cervical ribs were bilateral ( $N = 128$ , 68.1%); of the unilateral

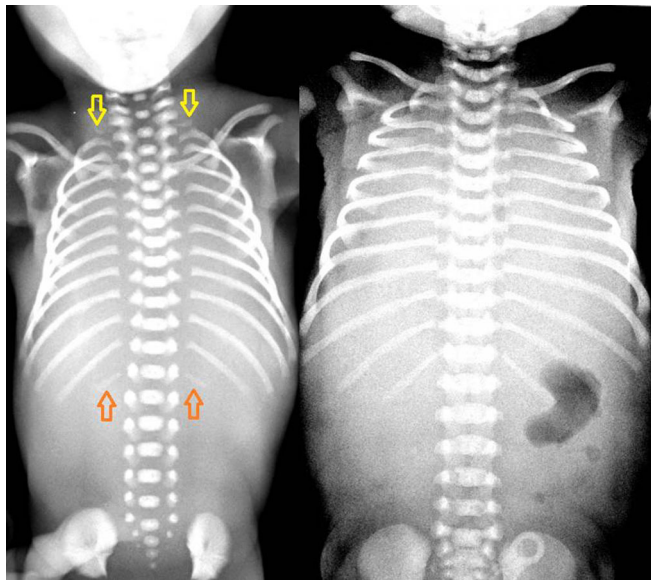


**FIGURE 3** The distribution of the different patterns of the vertebral column in the total study population ( $N = 374$ ). CT, shift at the cervicothoracic boundary; CT\_LS, shift at cervicothoracic and lumbosacral boundary; CT\_TL, shift at the cervicothoracic and thoracolumbar boundary; CT\_TL\_LS, shift at cervicothoracic, thoracolumbar and lumbosacral boundary; TL\_LS, shift at thoracolumbar and lumbosacral boundary

cervical ribs, most were left sided ( $N = 37/60$ , 61.7%). Figure 4 shows a babygram of a fetus with rudimentary cervical ribs and rudimentary twelfth thoracic ribs, and a babygram of a neonate with a regular vertebral pattern.

The distribution of the vertebral pattern categorized according to structural abnormality is shown in Figure 5. The prevalence of a regular vertebral pattern ranged between 18.6 and 33.3% and was highest in the group without structural abnormalities (26/78) and lowest in the group with bronchopulmonary abnormalities (8/43, 18.6%). Changes involving the cervicothoracic region occurred most frequently in patients with skeletal abnormalities (17/24, 70.8%), abnormalities involving the digestive system (28/46, 60.9%) and limb defects (43/71, 60.6%). The most disturbed vertebral pattern (CT\_TL\_LS) was frequently seen in patients with ventral body wall defects (3/17, 17.6%), skeletal (3/24, 12.5%) and craniofacial (9/82, 11.0%) abnormalities.

The log-linear analyses started from models with interactions between the presence of an abnormal vertebral pattern (respectively the presence of a cervical rib among these cases) and the presence of a congenital anomaly, a history of smoking (current smoking or quit smoking during pregnancy), birth outcome, fetal gender, assisted pregnancy and periconceptional supplementation of folic acid. A positive association was found between the occurrence of an abnormal vertebral pattern and a congenital anomaly ( $\chi^2[1] = 6.16, p = .013$ ). Abnormalities of the vertebral pattern were more frequent in the presence of a congenital anomaly (parameter estimate 1.01 (*SE* 0.41), *z*-test  $p = .014$ ). The presence of abnormalities of the vertebral pattern was negatively



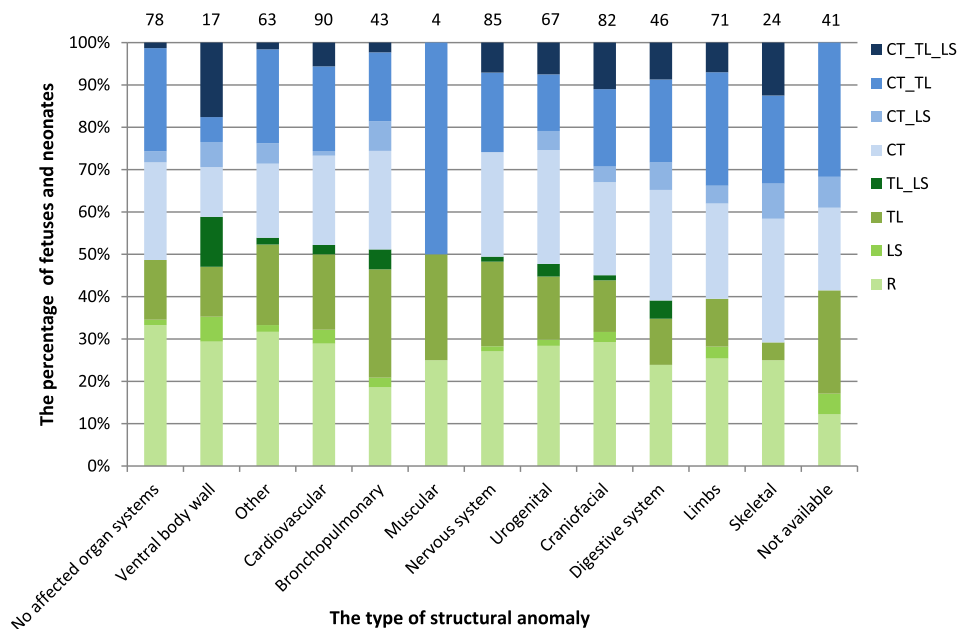
**FIGURE 4** Babygram of a fetus at 20.1 weeks' gestation (left) and a deceased term neonate (right). The babygram on the left shows rudimentary 12th thoracic ribs (orange arrows) and the presence of rudimentary cervical ribs (yellow arrows); the babygram on the right shows 12 thoracic rib pairs and the absence of cervical ribs

associated with smoking in individuals who did not use periconceptional folic acid (parameter estimate  $-2.61729$  (*SE* 0.84328),  $p(>|z|) = .002$ ). However, this group consisted of only 39 individuals and an association between smoking and the vertebral pattern was not found in the two groups with the largest number of individuals (non-smoking ( $n = 218$ ) or smoking ( $n = 45$ ) and periconceptional supplementation of folic acid). Within the smoking group, there was a positive association between the presence of a vertebral patterning anomaly and the supplementation of folic acid (estimate 2.07273 (*SE* 0.90766)  $p(>|z|) = .022$ ). Among the non-smokers there was a trend for a negative association which was not significant ( $-1.18420$  (*SE* 0.63883)  $p(>|z|) = .064$ ). The prevalence of a normal vertebral pattern differed between the birth outcomes ( $\chi^2[2] = 11.81, p = .003$ ). The proportion of fetuses and neonates with a regular vertebral pattern was significantly higher in live births (25/58, 43.1%), compared to stillbirths (29/128, 22.7%) and terminations of pregnancies (46/188, 24.5%). From the logistic regressions we conclude that maternal BMI and gestational age did not explain the presence of a normal vertebral pattern.

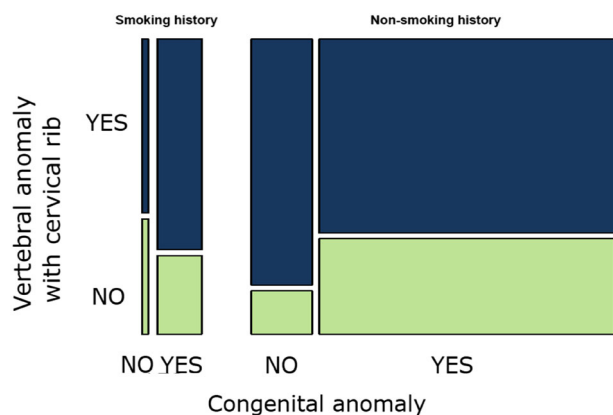
Among the patients with an abnormal vertebral pattern, the presence of a cervical rib was associated in a three-way interaction with the presence of a structural anomaly and a history of smoking ( $X^2 = 5.02, p = .03$ ). Among the individuals in the largest group of observations (non-smoking and abnormal vertebral pattern,  $n = 193$ ), the association between the presence of a cervical rib and a structural anomaly was negative ( $-1.68$  estimate [*SE* 0.76],  $p = .027$ ). This implies that other vertebral patterning anomalies were more positively associated with structural anomalies in this dataset. In the small group of smokers ( $n = 38$ ), we could not demonstrate a significant association with the occurrence of a cervical rib, see Figure 6.

When we removed this three-way interaction from a model for the overall occurrence of cervical ribs as a check, the presence of a cervical rib and a structural anomaly were not significantly associated. Marginal chi-squared tests were in agreement with this last conclusion: the prevalence of cervical ribs did not differ significantly between fetuses and neonates with and without structural anomalies in the total group (126/256 vs. 40/78,  $X^2[1] = 0.10, p = .80$ ), nor in the subgroups of live births (13/43 vs. 4/12,  $p = 1.0$ ), stillbirths (21/40 vs. 32/57,  $X^2[1] = 0.13, p = .72$ ), or terminations of pregnancies (92/173, vs. 4/9,  $p = .74$ ). Cervical ribs were significantly more common in stillbirths (69/128 (53.9%) and terminations of pregnancies (101/188 (53.7%)), compared to live births (18/58, 31.0%,  $\chi^2[2] = 12.38, p = .002$ ). The distribution of the vertebral pattern in these subgroups is





**FIGURE 5** The pattern of the vertebral column in fetuses and neonates categorized according to the presence and type of structural anomaly. The total number of cases in each group is depicted above the bars. CT, shift at the cervicothoracic boundary; CT\_LS, shift at cervicothoracic and lumbosacral boundary; CT\_TL, shift at the cervicothoracic and thoracolumbar boundary; CT\_TL\_LS, shift at cervicothoracic, thoracolumbar and lumbosacral boundary; R, regular pattern; TL\_LS, shift at thoracolumbar and lumbosacral boundary



**FIGURE 6** The proportion of fetuses and neonates with and without cervical ribs according to the presence of a structural abnormality and a history of smoking. Among the individuals in the largest group of observations (non-smoking and abnormal vertebral pattern,  $n = 193$ ), the association between the presence of a cervical rib and a structural anomaly was negative ( $-1.68$  estimate [ $SE\ 0.76$ ],  $p = .027$ ). In the small group of smokers ( $n = 38$ ), a significant association with the occurrence of a cervical rib was not demonstrated. The size of the box reflects the group size

shown in Figure 7. The four live births with cervical ribs, but without structural abnormalities died because of a subgaleal hemorrhage, sepsis, asphyxia and uterine rupture, respectively. Autopsy was performed in all of these neonates. The asphyctic neonate had mild dysmorphic features, but a normal karyotype. The pregnancy in which a uterine rupture occurred was complicated by polyhydramnios and macrosomia. Maternal diabetes was ruled out. The macrosomic neonate had mild dysmorphic features and was suspected of having an overgrowth

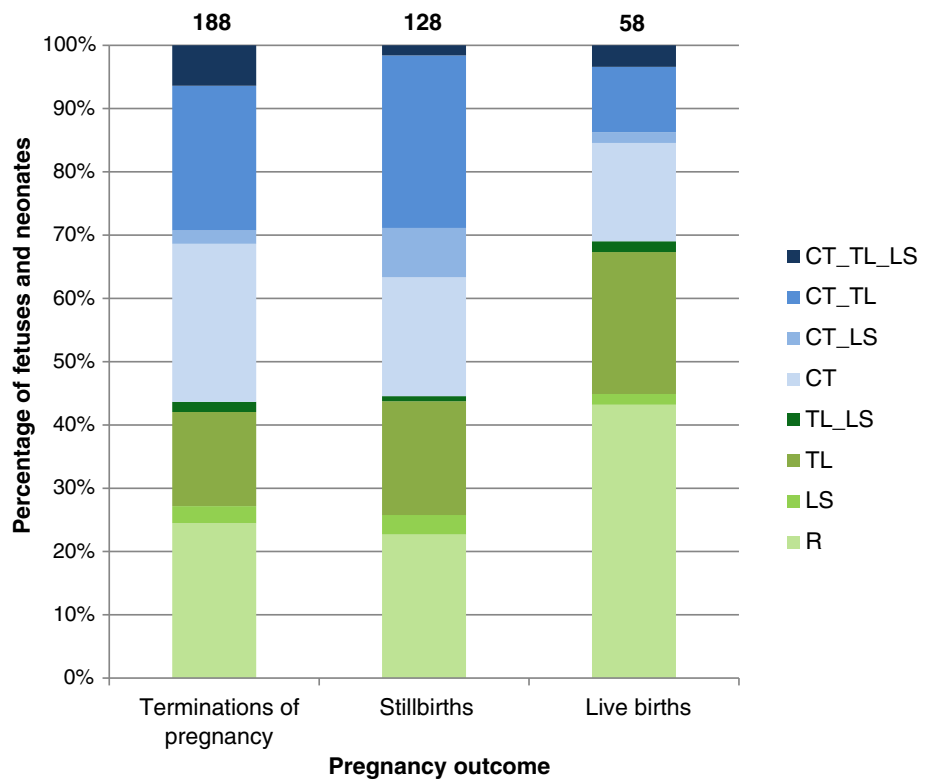
syndrome, but additional DNA-testing did not reveal a genetic mutation. Chromosomal or genetic analyses were not performed in the remaining 2 neonates.

No statistically significant association was found between the prevalence of cervical ribs and fetal gender (109/208 vs. 79/166, marginal  $\chi^2 [1] = 0.86$ ,  $p = .36$ ). Interactions between the presence of a cervical rib and assisted conception or the periconceptional use of folic acid were not retained in the log-linear models. Gestational age at birth ( $M = 23.5$  weeks,  $SD = 6.2$ , vs.  $M = 23.7$  weeks,  $SD = 6.3$ ) and maternal BMI ( $M = 24.8$ ,  $SD = 5.3$ , vs.  $M = 24.7$ ,  $SD = 4.7$ ) were not significantly different between fetuses and neonates with and without cervical ribs and these variables did not predict the presence of a cervical rib, neither in interactions with other variables nor as a main effect.

We did not find any significant associations between the presence of an abnormal vertebral pattern or a cervical rib and separate categories of congenital anomalies. The prevalence of an abnormal vertebral pattern or the presence of a cervical rib among these cases was not significantly associated with the number of affected organ systems, see Figure S1. The intra-observer reliability was almost perfect for determination of the number of thoracic ribs (Kappa = 0.84) and substantial for assessment of the presence of cervical ribs (Kappa = 0.78). The interrater reliability was substantial for both determination of the number of thoracic ribs (Kappa = 0.77) and cervical ribs (Kappa = 0.74).

Karyotype was available in 221 (59.1%) patients. Aneuploidies were detected in 15 (6.8%) patients; 10 (66.7%) of these had cervical ribs. Microarray tests were performed in 265 (70.9%) of patients. Neither

**FIGURE 7** The distribution of the vertebral pattern in terminations of pregnancies, still births and live births. The total number of cases is depicted above the bars. CT, shift at the cervicothoracic boundary; CT\_LS, shift at cervicothoracic and lumbosacral boundary; CT\_TL, shift at the cervicothoracic and thoracolumbar boundary; CT\_TL\_LS, shift at cervicothoracic, thoracolumbar and lumbosacral boundary; R, Regular pattern; TL\_LS, shift at thoracolumbar and lumbosacral boundary



karyotype nor array was available in 54 patients (14.4%). In 31 patients (31/265, 11.7%) microarray showed an abnormality. Cervical ribs were present in 20/31 (64.5%) patients with an abnormal microarray result. The presence of cervical ribs in patients with a pathogenic or (likely) deleterious CNV was 50.0% (6/12) and 57.1% (4/7), respectively. These data are summarized by subgroup in Table S3.

### 3.1 | CNV profiling

The prevalence of large (likely) deleterious CNV (Table 1) and aneuploidies was high. However, there were no recurrent or overlapping rare CNVs. Some of the rare CNVs have overlap with dominant disease genes (see Table S4). There was no overlap with candidate genes (e.g., the *HOX* gene cluster). An overview of all genes that are involved in the rare CNVs identified in the cohort is provided in Table S5. Pathway enrichment analysis of genes affected by a rare CNV did not provide evidence of enrichment of relevant pathways. Analysis of the gene content of the rare CNVs of patients with extra cervical ribs and vertebral patterning abnormalities (CNV<sub>n</sub> = 42, Group 1), patients without extra cervical ribs but with other vertebral patterning abnormalities (CNV<sub>n</sub> = 23, Group 2) and patients without cervical ribs nor other vertebral patterning abnormalities (CNV<sub>n</sub> = 23,

Group 3) did not show statistical significant overrepresentation in Group 1. In Group 2 and Group 3 several immune response and neuronal signaling functions were overrepresented, which was not considered relevant for the occurrence of vertebral patterning abnormalities. Full results are depicted in Table S6.

## 4 | DISCUSSION

An abnormal pattern of the vertebral column, in particular the presence of cervical ribs, was frequently found in deceased fetuses and neonates. The prevalence was noticeably higher in this population, compared to living children or adults without identified structural, chromosomal or genetic abnormalities, as reported in the literature (Schut et al., 2016). These findings are in line with the study of Ten Broek et al., who included a similar study population (Ten Broek et al., 2012). The differences in vertebral pattern between subgroups categorized into affected organ system were less striking compared to the study of Ten Broek et al. (2012), which could be due to the smaller number of included patients in our study. Although a significant difference was not found, the frequency of the most severely disturbed vertebral pattern in the subgroups with ventral body wall defects, craniofacial malformations and skeletal malformations was high. The co-occurrence of an abnormal vertebral pattern and

these abnormalities could be explained by the close spatial relationship and the intense interaction of signaling pathways between the embryonic precursors of these organ systems and the vertebral column in early embryogenesis (Mekonen, Hikspoors, Mommen, Kohler, & Lamers, 2015; Rajion et al., 2006; Sonnesen, 2010). For instance, signaling from the somites influences the migration of neural crest cells, from which the craniofacial skeleton is derived, whereas somites themselves give rise to the vertebrae and ribs, ventral body wall skeleton, abdominal muscles, skeletal muscles and cartilage. Because of the intense interactions between developmental processes during somitogenesis, this period is considered as extremely vulnerable (Galis & Metz, 2001; Lubinsky, 2015). Consequently, disruptions in vertebral patterning would often be accompanied by disruptions of other developmental processes. As expected, the most severely disturbed vertebral pattern was most frequent in patients with more than four affected organ systems. This might be due to a prolonged disturbance of developmental processes.

A higher prevalence of abnormal vertebral patterns was found among fetuses and neonates with congenital anomalies. The prevalence of cervical ribs was not significantly different between the total group of fetuses and neonates with and without structural abnormalities. This is in contrast to Galis et al. (2006) and Ten Broek et al. (2012), which may be due to the smaller study population in the current study. Other support for the association between cervical ribs and congenital abnormalities comes from studies on live patients (Naik, Lendon, & Barson, 1978; Schut et al., 2019) and various mammalian species (Varela-Lasheras et al., 2011).

Alternatively, the presence of cervical ribs might not only be associated with the presence of structural abnormalities, but also with the occurrence of intrauterine fetal demise itself. This has been suggested by Furtado et al. (2011), who found cervical ribs to be associated with stillbirth, but did not observe a significant association between congenital abnormalities and the presence of cervical ribs. The significantly higher prevalence of cervical ribs in the subpopulation of stillbirths compared to live births is in line with this theory. In addition, structural abnormalities or other signs of disturbed embryonic development resulting in fetal or neonatal death may not always be detected by autopsy. This is illustrated by a study on patients with limb reduction defects; in 15% of the patients who died within the first year of life associated abnormalities were not identified, while these patients presumably did not die because of the limb reduction defect itself (Froster-Iskenius & Baird, 1989). Considering the high percentage of unexplained stillbirths in the general population (Dudley et al., 2010;

Lawn et al., 2011; G. C. Smith & Fretts, 2007), the high frequency of cervical ribs in stillbirths warrants further attention and may help in directing further research on the pathophysiology of unexplained stillbirths.

The relatively high prevalence of cervical ribs within the subpopulation of deceased neonates without proven structural abnormalities (4/11, 36.4%) remains unexplained, although these neonates were not proven to be healthy and died. The regression of cervical ribs later in fetal life or childhood has also been considered, but seems less plausible, as cervical ribs are frequently encountered in specific (adult) patient groups (Merks et al., 2005; Weber & Criado, 2014; Zierhut et al., 2011) and rare in the general population. In addition, no age-effect is seen in the prevalence of cervical ribs (Galis et al., 2006; Schut et al., 2016).

Cervical ribs were detected in the majority of patients with an aneuploidy or abnormal microarray result. The reported prevalence of cervical ribs in aneuploidies ranges between 12.5 and 100% (Furtado et al., 2011; Schut, Ten Broek, et al., 2018). Studies reporting on cervical ribs in populations with microarray abnormalities are lacking. A wide variety of aneuploidies and CNV (losses and gains) were identified in this cohort. Both the absence of rare recurrent CNVs involving candidate genes, and the fact that several patients included in this study population proved to have different chromosomal or genetic abnormalities are an indication of the genetic heterogeneity that is involved in the development of an abnormal vertebral pattern. However, this does not rule out a common genetic basis for the abnormalities of the vertebral pattern, because the presence of structural DNA variations, such as point mutations, are not detected by SNP array and CNV analyses. Overlapping abnormalities involving *HOX*-genes or other candidate genes were not identified within this cohort. Therefore, it is unlikely that half of the stillbirths (those with cervical ribs) have had a common underlying genetic basis. Accumulation of multiple singleton loss of function variants has been shown to be associated with the risk of structural abnormalities, such as neural tube defects (Chen et al., 2016). A comparable process could also contribute to the presence of abnormalities of the vertebral pattern. The low number of patients with multiple singleton CNVs did not enable analysis of a possible association between an abnormal vertebral pattern and accumulation of multiple singleton CNVs.

The occurrence of similar segmentation anomalies in patients with various structural, chromosomal and genetic abnormalities and prenatal exposure to different teratogens, seems to be a reflection of the different underlying etiologies of vertebral homeotic transformations (Giampietro et al., 2013; Martinez-Frias, 2004). This

heterogeneity can be explained by the intense interaction during the head-to-tail patterning of the cervical vertebrae, such that many disturbances can disrupt this patterning. The specific timing and duration of the disruption has greater influence on the type of abnormality than the cause of the disruption itself (De Sesso, 1996; JG, 1965; C. C. Lu, Matsumoto, & Iijima, 1979; F. Lu, 1991; Lubinsky, 1985; Opitz, 1985; Sadler, 1980). Abnormalities in vertebral patterning, such as cervical ribs, can probably be regarded as a sign of abnormal embryonic development, irrespective of the causative event. The remarkably high frequency of cervical ribs and other deviations from the regular pattern of the vertebral column in this study population of deceased fetuses and neonates supports the hypothesized selection against variations in the conserved process of vertebral patterning.

These findings indicate that assessment of the vertebral pattern is probably of added value in postnatal or post-mortem examinations of fetuses and neonates with adverse outcome, such as unexplained stillbirth. Prenatal assessment of the vertebral pattern, including the detection of rudimentary cervical ribs, using (3-dimensional) ultrasound seems feasible and warrants further attention. (Dall'Asta, Paramasivam, & Lees, 2016; Gindes, Benoit, Pretorius, & Achiron, 2008; Hershkovitz, 2008; Khodair & Hassanen, 2014; Schut, Verdijk, Joosten, & Eggink, 2018; Esser, Rogalla, Sarioglu, & Kalache, 2006).

Strengths of the study are the large study population and the good intraobserver and interobserver reliability for the assessment of the vertebral pattern and cervical ribs on radiographs. Limitations are the small sizes of the subgroups with specific structural, chromosomal or genetic abnormalities and the fact that autopsy had not been performed in all patients. Although the presence of a healthy control group was lacking, literature regarding the prevalence of cervical ribs in healthy populations was available for comparison.

## 5 | CONCLUSIONS

The presence of abnormalities in the pattern of the vertebral column, particularly in the cervical region, could be regarded as a sign of disruption at critical, interactive and conserved stages of early embryonic development. The absence of rare recurrent CNVs, and the presence of similar vertebral patterning abnormalities in patients with different chromosomal or genetic abnormalities are an indication of the genetic heterogeneity that appears to be involved in the development of an abnormal vertebral pattern. Assessment of the vertebral pattern could provide valuable information in fetuses and neonates with adverse outcome.

Further studies regarding the feasibility and value of prenatal (3-dimensional) ultrasound assessment of the number of vertebrae and ribs are warranted. Whole exome sequencing on subjects with (isolated) vertebral patterning abnormalities might provide more insight into the presumably heterogeneous genetic causes of these patterning defects.

## ACKNOWLEDGMENT

The authors thank Ms. S.C. Husen, for the assessment of the subset of radiographs for determination of the inter-observer reliability.

## CONFLICT OF INTEREST

The authors declare no potential conflict of interest.

## AUTHOR CONTRIBUTIONS

Titia E. Cohen-Overbeek, Alex J. Eggink, Frietson Galis, Clara M. A. ten Broek, Erwin Brosens, Annelies de Klein, and Pauline C. Schut designed the study. Inge M.M. Baijens and Pauline C. Schut collected patient data. Pauline C. Schut reviewed the radiographs. Tom J.M. Van Dooren and Pauline C. Schut analyzed and interpreted the data. Erwin Brosens and Martin P. Schol performed the genetic analyses. Pauline C. Schut, Erwin Brosens, and Tom J.M. Van Dooren wrote the manuscript. All authors revised the manuscript critically and all authors approved the final version of the manuscript.

## DATA AVAILABILITY STATEMENT

The datasets generated during and/or analyzed during the current study are available from the corresponding author on reasonable request.

## ORCID

Pauline C. Schut  <https://orcid.org/0000-0002-3898-5701>

Erwin Brosens  <https://orcid.org/0000-0001-8235-4010>

## REFERENCES

- Dall'Asta, A., Paramasivam, G., & Lees, C. C. (2016). Crystal Vue technique for imaging fetal spine and ribs. *Ultrasound in Obstetrics & Gynecology*, 47(3), 383–384.
- Agresti, A. (2018). *An introduction to categorical data analysis* (3rd ed.). New Jersey: John Wiley & Sons.
- Bots, J., Wijnaendts, L. C. D., Delen, S., van Dongen, S., Heikinheimo, K., & Galis, F. (2011). Analysis of cervical ribs in a series of human fetuses. *Journal of Anatomy*, 219(3), 403–409.
- Brewin, J., Hill, M., & Ellis, H. (2009). The prevalence of cervical ribs in a London population. *Clinical Anatomy*, 22(3), 331–336.
- Brosens, E., Marsch, F., de Jong, E. M., Zaveri, H. P., Hilger, A. C., Choinitzki, V. G., ... de Klein, A. (2016). Copy number variations in 375 patients with oesophageal atresia and/or tracheoesophageal fistula. *European Journal of Human Genetics*, 24(12), 1715–1723.

- Casaca, A., Santos, A. C., & Mallo, M. (2014). Controlling Hox gene expression and activity to build the vertebrate axial skeleton. *Developmental Dynamics*, 243(1), 24–36. <https://doi.org/10.1002/dvdy.24007>
- Chen, Y., Liu, Z., Chen, J., Zuo, Y., Liu, S., Chen, W., ... Wu, Z. (2016). The genetic landscape and clinical implications of vertebral anomalies in VACTERL association. *Journal of Medical Genetics*, 53(7), 431–437. <https://doi.org/10.1136/jmedgenet-2015-103554>
- Coe, B. P., Witherspoon, K., Rosenfeld, J. A., van Bon, B. W., Vultovan Silfhout, A. T., Bosco, P., ... Eichler, E. E. (2014). Refining analyses of copy number variation identifies specific genes associated with developmental delay. *Nature Genetics*, 46(10), 1063–1071.
- Cooper, G. M., Coe, B. P., Girirajan, S., Rosenfeld, J. A., Vu, T. H., Baker, C., ... Eichler, E. E. (2011). A copy number variation morbidity map of developmental delay. *Nature Genetics*, 43(9), 838–846. <https://doi.org/10.1038/ng.909>
- De Sesso, J. M. (1996). Principles underlying developmental toxicity. In A. M. Fan & L. W. Chang (Eds.), *Toxicology and risk assessment principles, methods, and applications* (pp. 37–56). New York: Marcel Dekker.
- de Wit, M. C., Srebniak, M. I., Govaerts, L. C., Van Opstal, D., Galjaard, R. J., & Go, A. T. (2014). Additional value of prenatal genomic array testing in fetuses with isolated structural ultrasound abnormalities and a normal karyotype: A systematic review of the literature. *Ultrasound in Obstetrics & Gynecology*, 43(2), 139–146. <https://doi.org/10.1002/uog.12575>
- Dudley, D. J., Goldenberg, R., Conway, D., Silver, R. M., Saade, G. R., Varner, M. W., ... Stillbirth Research Collaborative, N. (2010). A new system for determining the causes of stillbirth. *Obstetrics and Gynecology*, 116(2 Pt 1), 254–260. <https://doi.org/10.1097/AOG.0b013e3181e7d97500006250-201008000-00004>
- Elliott, G. C. (1988). Interpreting higher order interactions in log-linear analysis. *Psychological Bulletin*, 103(1), 121–130. <https://doi.org/10.1037/0033-2909.103.1.121>
- Etter, M. (1944). Osseous abnormalities of the thoracic cage seen in forty thousand consecutive chest photoroentgenograms. *American Journal of Roentgenology*, 51, 359–363.
- EUROCAT. (2012). *Coding of EUROCAT subgroups of congenital anomalies*. Chapter 3.3, Guide 1.4. Instruction for the registration of congenital anomalies, Northern Ireland: EUROCAT Central Registry, University of Ulster.
- Froster-Iskenius, U. G., & Baird, P. A. (1989). Limb reduction defects in over one million consecutive livebirths. *Teratology*, 39(2), 127–135. <https://doi.org/10.1002/tera.1420390205>
- Furtado, L. V., Thaker, H. M., Erickson, L. K., Shirts, B. H., & Opitz, J. M. (2011). Cervical ribs are more prevalent in stillborn fetuses than in live-born infants and are strongly associated with fetal aneuploidy. *Pediatric and Developmental Pathology*, 14(6), 431–437.
- Galis, F. (1999). Why do almost all mammals have seven cervical vertebrae? Developmental constraints, Hox genes, and cancer. *The Journal of Experimental Zoology*, 285(1), 19–26.
- Galis, F., & Metz, J. A. (2001). Testing the vulnerability of the phylotypic stage: On modularity and evolutionary conservation. *The Journal of Experimental Zoology*, 291(2), 195–204. <https://doi.org/10.1002/jez.1069>
- Galis, F., Van Dooren, T. J. M., Feuth, J. D., Metz, J. A. J., Witkam, A., Ruinard, S., ... Wijnaendts, L. C. D. (2006). Extreme selection in humans against homeotic transformations of cervical vertebrae. *Evolution*, 60(12), 2643–2654.
- Giampietro, P. F., Raggio, C. L., Blank, R. D., McCarty, C., Broeckel, U., & Pickart, M. A. (2013). Clinical, genetic and environmental factors associated with congenital vertebral malformations. *Molecular Syndromology*, 4(1–2), 94–105.
- Gindes, L., Benoit, B., Pretorius, D. H., & Achiron, R. (2008). Abnormal number of fetal ribs on 3-dimensional ultrasonography: Associated anomalies and outcomes in 75 fetuses. *Journal of Ultrasound in Medicine*, 27(9), 1263–1271.
- Henry, B. M., Vikse, J., Sanna, B., Tattera, D., Gomulska, M., Pekala, P. A., ... Tomaszewski, K. A. (2018). Cervical rib prevalence and its association with thoracic outlet syndrome: A meta-analysis of 141 studies with surgical considerations. *World Neurosurgery*, 110, e965–e978. <https://doi.org/10.1016/j.wneu.2017.11.148>
- Hershkovitz, R. (2008). Prenatal diagnosis of isolated abnormal number of ribs. *Ultrasound in Obstetrics & Gynecology*, 32(4), 506–509.
- Horan, G. S., Wu, K., Wolgemuth, D. J., & Behringer, R. R. (1994). Homeotic transformation of cervical vertebrae in Hoxa-4 mutant mice. *Proceedings of the National Academy of Sciences of the United States of America*, 91(26), 12644–12648.
- JG, W. (1965). Methods for administering agents and detecting malformations in experimental animals. In J. G. Wilson & J. Warkany (Eds.), *Teratology: Principles and techniques* (pp. 262–277). Chicago: University of Chicago Press.
- Khodair, S. A., & Hassan, O. A. (2014). Abnormalities of fetal rib number and associated fetal anomalies using three dimensional ultrasonography. *The Egyptian Journal of Radiology and Nuclear Medicine*, 45(3), 689–694.
- Landis, J. R., & Koch, G. G. (1977). The measurement of observer agreement for categorical data. *Biometrics*, 33(1), 159–174.
- Lappin, T. R., Grier, D. G., Thompson, A., & Halliday, H. L. (2006). HOX genes: Seductive science, mysterious mechanisms. *The Ulster Medical Journal*, 75(1), 23–31.
- Lawn, J. E., Blencowe, H., Pattinson, R., Cousens, S., Kumar, R., Ibiebele, I., ... Lancet's Stillbirths Series steering committee. (2011). Stillbirths: Where? When? Why? How to make the data count? *Lancet*, 377(9775), 1448–1463. [https://doi.org/10.1016/S0140-6736\(10\)62187-3](https://doi.org/10.1016/S0140-6736(10)62187-3)
- Li, B., Huang, Q., & Wei, G. H. (2019). The role of HOX transcription factors in cancer predisposition and progression. *Cancers (Basel)*, 11(4), 528. <https://doi.org/10.3390/cancers11040528>
- Loder, R. T., Huffman, G., Toney, E., Wurtz, L. D., & Fallon, R. (2007). Abnormal rib number in childhood malignancy: Implications for the scoliosis surgeon. *Spine*, 32(8), 904–910.
- Lu, C. C., Matsumoto, N., & Iijima, S. (1979). Teratogenic effects of nickel chloride on embryonic mice and its transfer to embryonic mice. *Teratology*, 19(2), 137–142. <https://doi.org/10.1002/tera.1420190202>
- Lu, F. (1991). *Basic toxicology. Fundamentals, target organs and risk assessment*. Bristol, PA: Taylor and Francis.
- Lubinsky, M. (1985). Associations in clinical genetics with a comment on the paper by Evans et al. on tracheal agenesis. *American Journal of Medical Genetics*, 21, 35–38.

- Lubinsky, M. (2015). Blastogenetic associations: General considerations. *American Journal of Medical Genetics. Part A*, 167A(11), 2589–2593.
- Mallo, M., Wellik, D. M., & Deschamps, J. (2010). Hox genes and regional patterning of the vertebrate body plan. *Developmental Biology*, 344(1), 7–15.
- Manley, N. R., & Capecchi, M. R. (1998). Hox group 3 paralogs regulate the development and migration of the thymus, thyroid, and parathyroid glands. *Developmental Biology*, 195(1), 1–15.
- Martinez-Frias, M. L. (2004). Segmentation anomalies of the vertebrae and ribs: One expression of the primary developmental field. *American Journal of Medical Genetics. Part A*, 128A(2), 127–131. <https://doi.org/10.1002/ajmg.a.30016>
- Mekonen, H. K., Hikspoors, J. P., Mommen, G., Kohler, S. E., & Lamers, W. H. (2015). Development of the ventral body wall in the human embryo. *Journal of Anatomy*, 227(5), 673–685.
- Merks, J. H. M., Smets, A. M., Van Rijn, R. R., Kobes, J., Caron, H. N., Maas, M., & Hennekam, R. C. M. (2005). Prevalence of RIB anomalies in normal Caucasian children and childhood cancer patients. *European Journal of Medical Genetics*, 48(2), 113–129.
- Naik, D. R., Lendon, R. G., & Barson, A. J. (1978). A radiological study of vertebral and rib malformations in children with myelomeningocele. *Clinical Radiology*, 29(4), 427–430.
- Narita, Y., & Kuratani, S. (2005). Evolution of the vertebral formulae in mammals: A perspective on developmental constraints. *Journal of Experimental Zoology. Part B, Molecular and Developmental Evolution*, 304(2), 91–106.
- Opitz, J. M. (1985). The developmental field concept. *American Journal of Medical Genetics*, 21(1), 1–11. <https://doi.org/10.1002/ajmg.1320210102>
- Quinonez, S. C., & Innis, J. W. (2014). Human HOX gene disorders. *Molecular Genetics and Metabolism*, 111(1), 4–15.
- Rajion, Z. A., Townsend, G. C., Netherway, D. J., Anderson, P. J., Yusof, A., Hughes, T., ... David, D. J. (2006). A three-dimensional computed tomographic analysis of the cervical spine in unoperated infants with cleft lip and palate. *The Cleft Palate-Craniofacial Journal*, 43(5), 513–518.
- Sadler, T. W. (1980). Effects of maternal diabetes on early embryogenesis: II. Hyperglycemia-induced exencephaly. *Teratology*, 21(3), 349–356. <https://doi.org/10.1002/tera.1420210311>
- Schumacher, R., Mai, A., & Gutjahr, P. (1992). Association of rib anomalies and malignancy in childhood. *European Journal of Pediatrics*, 151(6), 432–434.
- Schut, P., Verdijk, R. M., Joosten, M., & Eggink, A. J. (2018). Prenatal diagnosis of cervical ribs by three-dimensional ultrasound in a foetus with a herniated Dandy-Walker cyst. *BML Case Reports*, 11(1), e225381. <https://doi.org/10.1136/bcr-2018-225381>
- Schut, P. C., Cohen-Overbeek, T. E., Galis, F., Ten Broek, C. M. A., Steegers, E. A., & Eggink, A. J. (2016). Adverse fetal and neonatal outcome and an abnormal vertebral pattern: A systematic review. *Obstetrical & Gynecological Survey*, 71(12), 741–750.
- Schut, P. C., Eggink, A. J., Boersma, M., Tibboel, D., Wijnen, R. M. H., Brosens, E., ... Cohen-Overbeek, T. E. (2019). Cervical ribs and other abnormalities of the vertebral pattern in children with esophageal atresia and anorectal malformations. *Pediatric Research*, 87(4), 773–778. <https://doi.org/10.1038/s41390-019-0631-110.1038/s41390-019-0631-1>
- Schut, P. C., Ten Broek, C. M. A., Cohen-Overbeek, T. E., Bugiani, M., Steegers, E. A. P., Eggink, A. J., & Galis, F. (2018). Increased prevalence of abnormal vertebral patterning in fetuses and neonates with trisomy 21. *The Journal of Maternal-Fetal & Neonatal Medicine*, 32(14), 2280–2286.
- Smith, G. C., & Fretts, R. C. (2007). Stillbirth. *Lancet*, 370(9600), 1715–1725. [https://doi.org/10.1016/S0140-6736\(07\)61723-1](https://doi.org/10.1016/S0140-6736(07)61723-1)
- Smith, J., Zyoud, A., & Allegrucci, C. (2019). A case of identity: HOX genes in Normal and cancer stem cells. *Cancers (Basel)*, 11(4), 1–13. <https://doi.org/10.3390/cancers11040512>
- Solomon, B. D., Bear, K. A., Kimonis, V., de Klein, A., Scott, D. A., Shaw-Smith, C., ... Giampietro, P. F. (2012). Clinical geneticists' views of VACTERL/VATER association. *American Journal of Medical Genetics. Part A*, 158A(12), 3087–3100.
- Sonnesen, L. (2010). Associations between the cervical vertebral column and craniofacial morphology. *Int J Dent*, 2010, 295728.
- Esser, T., Rogalla, P., Sarioglu, N., & Kalache, K. D. (2006). Three-dimensional ultrasonographic demonstration of agenesis of the 12th rib in a fetus with trisomy 21. *Ultrasound in Obstetrics & Gynecology*, 27, 712–715.
- Ten Broek, C. M., Bakker, A. J., Varela-Lasheras, I., Bugiani, M., Van Dongen, S., & Galis, F. (2012). Evo-devo of the human vertebral column: On homeotic transformations, pathologies and prenatal selection. *Evolutionary Biology*, 39(4), 456–471.
- Varela-Lasheras, I., Bakker, A. J., van der Mije, S. D., Metz, J. A., van Alphen, J., & Galis, F. (2011). Breaking evolutionary and pleiotropic constraints in mammals: On sloths, manatees and homeotic mutations. *EvoDevo*, 2, 11.
- Wapner, R. J., Martin, C. L., Levy, B., Ballif, B. C., Eng, C. M., Zachary, J. M., ... Jackson, L. (2012). Chromosomal microarray versus karyotyping for prenatal diagnosis. *The New England Journal of Medicine*, 367(23), 2175–2184. <https://doi.org/10.1056/NEJMoa1203382>
- Weber, A. E., & Criado, E. (2014). Relevance of bone anomalies in patients with thoracic outlet syndrome. *Annals of Vascular Surgery*, 28(4), 924–932.
- Wellik, D. M., Hawkes, P. J., & Capecchi, M. R. (2002). Hox11 paralogous genes are essential for metanephric kidney induction. *Genes & Development*, 16(11), 1423–1432.
- Zierhut, H., Murati, M., Holm, T., Hoggard, E., & Spector, L. G. (2011). Association of rib anomalies and childhood cancers. *British Journal of Cancer*, 105(9), 1392–1395.

## SUPPORTING INFORMATION

Additional supporting information may be found online in the Supporting Information section at the end of this article.

**How to cite this article:** Schut PC, Brosens E, Van Dooren TJM, et al. Exploring copy number variants in deceased fetuses and neonates with abnormal vertebral patterns and cervical ribs. *Birth Defects Research*. 2020;112:1513–1525. <https://doi.org/10.1002/bdr2.1786>