



**HAL**  
open science

## Enhancing digestive fistula healing by the off-label use of a thermoresponsive vessel occluder polymer associated with esophageal stent placement: A case report

Amanda K.A. Silva, Arthur Berger, Eric Caudron, Guillaume Perrod, Imane Boucenna, Florence Gazeau, Claire Wilhelm, Anne Berger, Olivier Clément, Christophe Cellier, et al.

### ► To cite this version:

Amanda K.A. Silva, Arthur Berger, Eric Caudron, Guillaume Perrod, Imane Boucenna, et al.. Enhancing digestive fistula healing by the off-label use of a thermoresponsive vessel occluder polymer associated with esophageal stent placement: A case report. Clinics and Research in Hepatology and Gastroenterology, In press, 10.1016/j.clinre.2020.06.001 . hal-03095755

**HAL Id: hal-03095755**

**<https://hal.science/hal-03095755>**

Submitted on 4 Jan 2021

**HAL** is a multi-disciplinary open access archive for the deposit and dissemination of scientific research documents, whether they are published or not. The documents may come from teaching and research institutions in France or abroad, or from public or private research centers.

L'archive ouverte pluridisciplinaire **HAL**, est destinée au dépôt et à la diffusion de documents scientifiques de niveau recherche, publiés ou non, émanant des établissements d'enseignement et de recherche français ou étrangers, des laboratoires publics ou privés.

**Enhancing digestive fistula healing by the off-label use of a thermoresponsive vessel occluder polymer associated with esophageal stent placement: a case report**

Arthur Berger, MD<sup>1,2</sup>, Eric Caudron, PharmD, PhD<sup>3</sup>, Guillaume Perrod<sup>1,2</sup>, Imane Boucenna, PhD<sup>4</sup>, Florence Gazeau, PhD<sup>4</sup>, Claire Wilhelm, PhD<sup>4</sup>, Anne Berger, MD, PhD<sup>1</sup>, Olivier Clément, MD, PhD<sup>5</sup>, Christophe Cellier, MD, PhD<sup>1</sup>, Amanda K. A. Silva, PharmD, PhD<sup>4†</sup>, Gabriel Rahmi, MD, PhD<sup>1,2†\*</sup>.

<sup>1</sup> Department of Gastroenterology and Endoscopy, Hôpital Européen Georges Pompidou, Assistance Publique Hôpitaux de Paris, Paris, France.

<sup>2</sup> Inserm UMR970, Paris Cardiovascular Research Center, Paris, France

<sup>3</sup> Department of Pharmacy, Hôpital Européen Georges Pompidou, Assistance Publique Hôpitaux de Paris, Paris, France.

<sup>4</sup> Laboratoire Matière et Systèmes Complexes (MSC), Université de Paris / CNRS (UMR 7057), Paris, France

<sup>5</sup> Department of Radiology, Hôpital Européen Georges Pompidou, Assistance Publique Hôpitaux de Paris, Paris, France.

†These authors equally contributed to this work.

\*Correspondence: Gabriel Rahmi, MD, PhD, Department of Gastroenterology and Endoscopy, Hôpital Européen Georges Pompidou, Assistance Publique Hôpitaux de Paris, 20 rue Leblanc, 75015, Paris, France. E-mail: gabriel.rahmi@aphp.fr.

Conflicts of interest: C.W., F.G., A.K.A.S and G.R. are co-founders and shareholder of Evora Biosciences. The other authors declare no financial conflict of interest.

Informed patient consent was obtained for publication of patient information.

**Keywords:** Fistula, endoscopic treatment, thermoresponsive vessel occluder polymer

**Abbreviations:**

SEMS: self-expandable metal stent

VEGF: vascular endothelial growth factor

TGF- $\beta$ 1: transforming growth factor-beta 1

**Summary**

This case report relates to the first-in-man use of a vessel occluder gel medical device as a fistula occluder in a repurposing strategy. A patient with chronic colocutaneous fistula received an off-label treatment with a thermoresponsive Poloxamer 407 gel (20%) via percutaneous administration and injected under endoscopic control. Treatment consisted in the association of esophageal stent placement and gel injection. The product was administered just after the stent placement at  $<20^{\circ}\text{C}$  in its liquid form, gelling at body temperature to form a fistula plug. However, the stent was removed at day 26 because of major pain and the fistula was still present. Treatment was continued a total of 14 administrations of thermoresponsive Poloxamer 407 gel during 7 weeks via the external fistula orifice. The treatment reduced fistula orifice diameter from  $4.0 \pm 0.5$  to 1 mm and fistula daily output decreased from  $425 \pm 65$  to  $23 \pm 4$  mL, when comparing the months before and after treatment. Gel administration was not associated with any toxic effects. The therapeutic outcome remained stable 1 year after treatment. The external fistula diameter and the fistula output were similar to what observed after the last Poloxamer 407 gel administration.

## **Introduction**

Fistulas are a challenging public health burden related to Crohn's disease or secondary to surgery affecting millions of people worldwide with a high morbidity [1–4]. We present evidence of the potential therapeutic benefit of an intra-fistula treatment with a thermoresponsive Poloxamer 407 gel (20%) as a fistula occluder. It consisted in the first-in-man off-label use of this vessel occluder polymer gel that received market authorization in the US and Europe (LeGoo<sup>®</sup>, Sanofi) as a IIb medical device.

## **Case**

A 21-year-old male patient presented a colo-gastric anastomotic stenosis complicated by a supra-anastomotic colo-cutaneous fistula in the median supraumbilical region. A colon interposition procedure was indicated following a post-natal diagnostic of esophageal atresia. This patient had a complex medical history with prenatal diagnostic of diaphragmatic cupola hernia, chronic multifactorial respiratory failure and neuro-cognitive disorders. Three attempts to dilate endoscopically the colo-gastric anastomotic stenosis were unsuccessful. The last dilation was complicated by a perforation, which was closed by endoscopic through-the-scope clips (Boston Scientific, USA). The use of a standard clip approach for fistula management failed, due to the fistula location and the difficulty to position the clips appropriately. Then, a combined technique was proposed: a covered self-expandable metal stent (SEMS) 8 cm in length (MI TECH, South Korea), placed into the stenosis under radiological control (Figure 1A-C), in association an application of Poloxamer 407 gel as a fistula occluder. This strategy was accepted by the patient after ethical consideration in accordance with the results provided by our preclinical study [5]. Informed patient consent and a written patient's mother consent were obtained before therapy. Poloxamer 407 gel 20% in saline magistral formula was prepared in the Pharmacy Department of HEGP (Supplementary Figure 1). Rheological analysis was performed indicating a sol-gel transition temperature at about 20°C (Supplementary Figure 2). The procedure was carried out using a standard adult gastroscope (GIF-H190, Olympus, Japan) under general anesthesia with oro-tracheal intubation. The endoscopy evidenced a normal eso-colic anastomosis but a severe stenosis at the colo-gastric anastomosis. The internal fistula orifice was situated 2 cm above the colo-gastric anastomosis. A macroscopic view and

an endoscopic one of external and internal fistula orifice, respectively, are shown in Figure 1D and E. The radiological analysis evidenced a short fistula track of about 10 mm long and 3 mm wide with an important fibrosis in the internal orifice. In a first step, the internal orifice was intensively abraded and after stents placement, the Poloxamer 407 gel at 20% was injected percutaneously. A total of 1 ml of gel was injected under endoscopic control before and after stent placement, as indicated in Figures 1F and G. However, due to a severe abdominal pain, the stent was removed 26 days after its placement. Even if the fistula output decreased significantly, the external fistula orifice diameter was still present with daily digestive secretions. Therefore, the patient received 1 mL of Poloxamer 407 gel twice a week during 7 weeks via percutaneous administration without anesthesia.

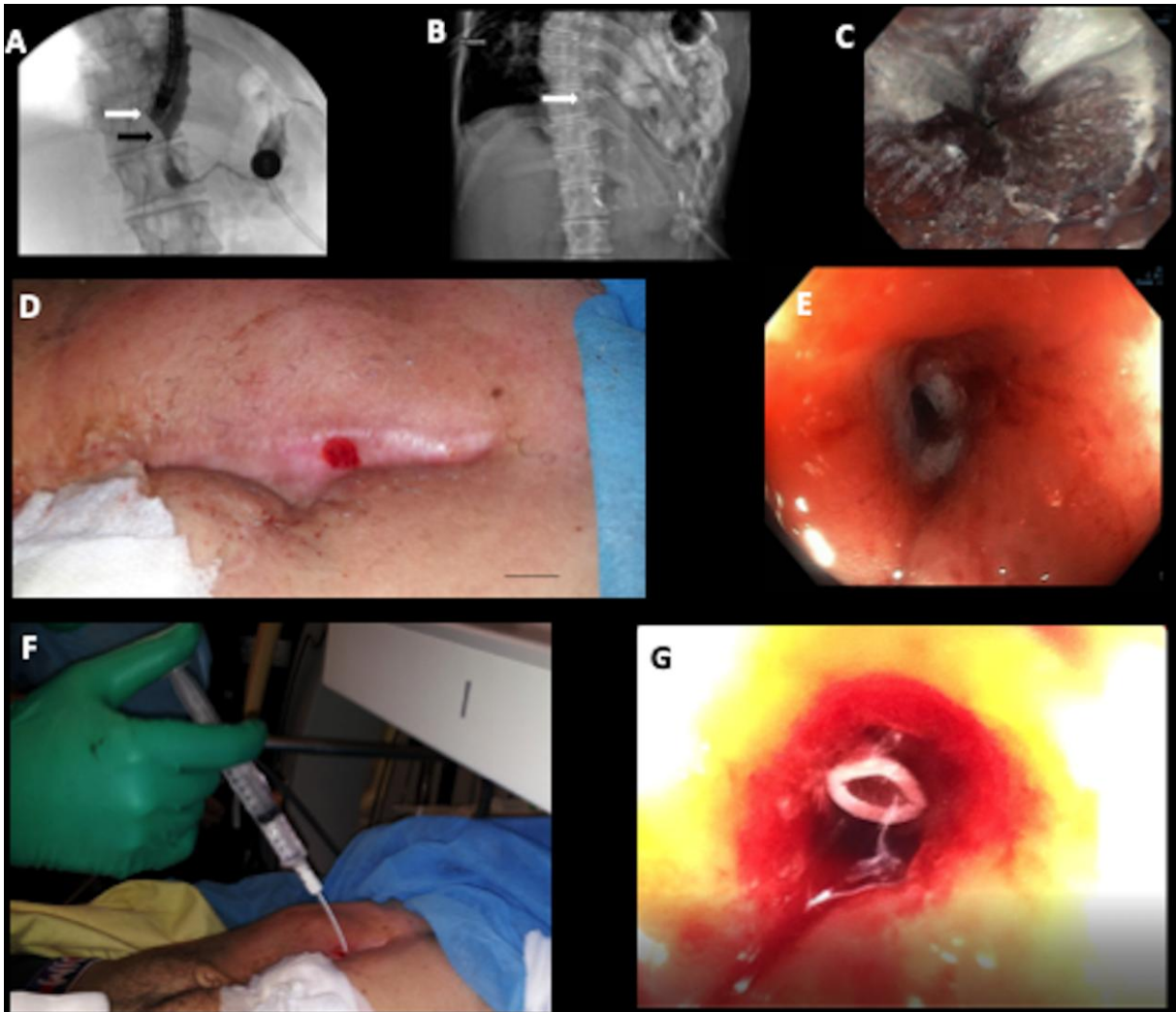
Fistula external orifice diameter progressively reduced from  $4.0 \pm 0.5$  mm to  $1.0 \pm 0.5$  mm during the 7 weeks of therapy (Figure 2A). Fistula output drastically decreased from  $425 \pm 65$  mL to  $23 \pm 6$  mL in the following days post-treatment. The output continued to decrease slightly and remained stable at  $10 \pm 1$  mL from the 4<sup>th</sup> to 7<sup>th</sup> week of gel application (Figure 2B). The observed therapeutic benefit (Figure 2A-C) was probably due to the combined effect of the stent, by alleviating stenosis pressure, and the gel, by promoting fistula occlusion. At 1 year, the external orifice had a dot shape without significant digestive secretions. The patient did not heal from the stenosis nor the fistula. After one year, the external fistula diameter and the fistula output were similar to what observed after the last Poloxamer 407 gel administration.

## **Discussion**

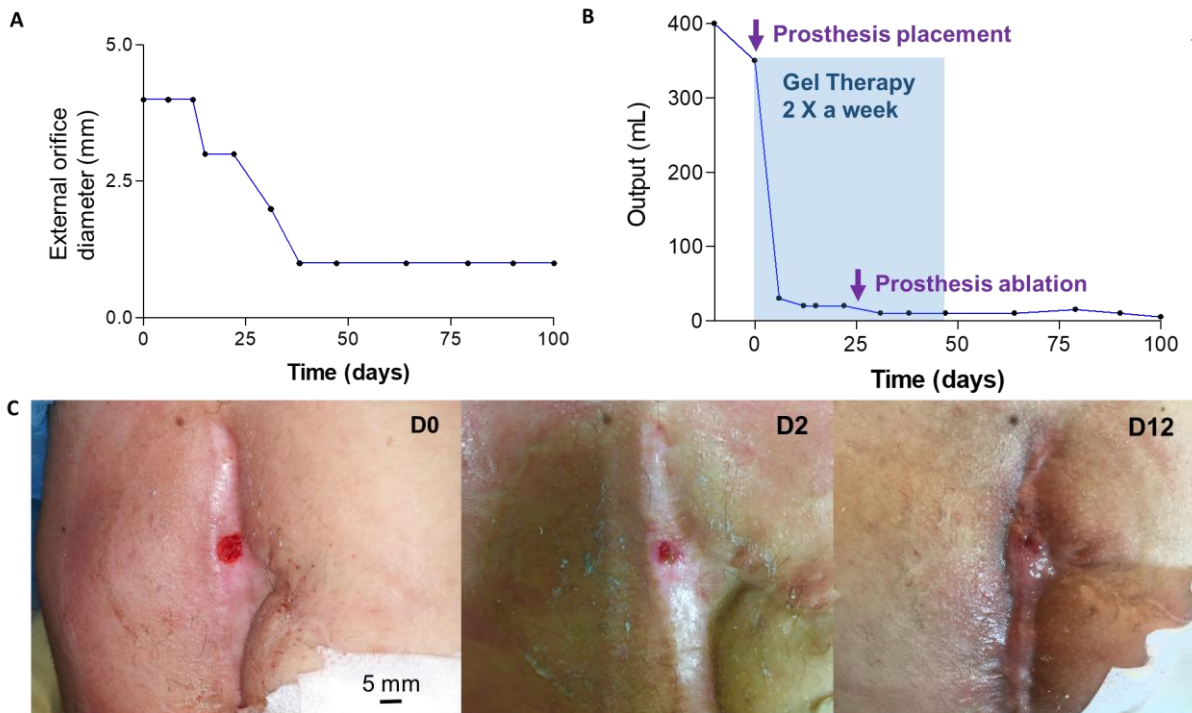
We showed for the first time that digestive fistula therapy may be enhanced by the percutaneous administration of thermoresponsive polymer gel in association with an esophageal stent placement. The thermoresponsive Poloxamer 407 hydrogels offer the advantage of filling irregular defects and reaching low-accessible areas while bypassing surgical interventions and the related discomfort as well as complications. Due to its thermoresponsive properties, the product could be administrated as a liquid injected through a catheter, whose gelation *in situ* at body temperature enabled it to be retained at the fistula site. Poloxamer 407 hydrogel is expected to act mechanically limiting the circulation of secretions through the fistula orifice, which has a beneficial effect in the healing process.

The main limitations of esophageal stent placement are stent migration and abdominal pain. In our case, the stent was removed because of major pain. Poloxamer 407 hydrogel could be regarded as an additional treatment associated with an endoscopic technique or alone after endoscopic failure. In addition to the mechanical effect, an ancillary effect may be related to the intrinsic properties of Poloxamer 407 hydrogel, which is known to favor healing by increasing microvessel density while enhancing the expression of vascular endothelial growth factor (VEGF) and transforming growth factor-beta 1 (TGF- $\beta$ 1) [6–9]. Poloxamer 407 hydrogel has been investigated for burn [10] and wound healing [7]. The Poloxamer 407 gel is expected to be eliminated via dilution with fistula secretions. Renal excretion is reported for Poloxamer 407 gel vessel occluder product (PMA P110003: FDA Summary of Safety and Effectiveness Data for Legoo®).

In conclusion, we report herein the first-in-man clinical report on the use of Poloxamer 407 gel as fistula occluder product combined with an esophageal stent placement. The treatment reduced fistula orifice diameter and fistula daily output decreased. The therapeutic outcome persisted 1 year after treatment. Importantly, Poloxamer 407 gel may benefit from a quite straightforward regulatory pathway considering that the gel has received FDA and EMA approval as a vessel occluder.



**Figure 1:** Treatment of a patient presenting a chronic colo-cutaneous fistula with a self-expansible metallic stent (SEMS) and poloxamer 407 gel as a fistula occluder. Fluoroscopy image showing the occlusion of the fistula after gel injection (white arrow) and the anastomotic stenosis (black arrow) just before stent placement (A). Radiological monitoring after stent placement into the stenosis (white arrow) (B). Proximal part of the fully covered SEMS (endoscopic view) (C). Macroscopic view of fistula external orifice (D). Endoscopic view of fistula internal orifice (E). Poloxamer 407 gel administration via a catheter positioned into the external fistula orifice (F). fistula tract reaching the internal fistula orifice (G).



**Figure 2:** Partial fistula healing via stent placement and poloxamer 407 gel injection. Fistula external orifice diameter (A) and output (B) as a function of the time as well as its aspect at days 0 (just before therapy), 2 and 12.

**Acknowledgements:** The authors thank BASF for kindly supplying poloxamer 407 polymer.

## References

- [1] Araujo Filho I, Meneses Rego AC. Digestive Fistulas: The Challenge Continues. *Transl Biomed* 2016;7. <https://doi.org/10.21767/2172-0479.100069>.
- [2] Quinn M, Falconer S, McKee RF. Management of Enterocutaneous Fistula: Outcomes in 276 Patients. *World J Surg* 2017;41:2502–11. <https://doi.org/10.1007/s00268-017-4063-y>.
- [3] Lloyd D a. J, Gabe SM, Windsor ACJ. Nutrition and management of enterocutaneous fistula. *Br J Surg* 2006;93:1045–55. <https://doi.org/10.1002/bjs.5396>.
- [4] Williams LJ, Zolfaghari S, Boushey RP. Complications of enterocutaneous fistulas and their management. *Clin Colon Rectal Surg* 2010;23:209–20. <https://doi.org/10.1055/s-0030-1263062>.
- [5] Silva AKA, Perretta S, Perrod G, Pidal L, Lindner V, Carn F, et al. Thermo-responsive Gel Embedded with Adipose Stem-Cell-Derived Extracellular Vesicles Promotes Esophageal Fistula Healing in a Thermo-Actuated Delivery Strategy. *ACS Nano* 2018;12:9800–14. <https://doi.org/10.1021/acsnano.8b00117>.
- [6] Dumortier G, Grossiord JL, Agnely F, Chaumeil JC. A review of poloxamer 407 pharmaceutical and pharmacological characteristics. *Pharm Res* 2006;23:2709–28. <https://doi.org/10.1007/s11095-006-9104-4>.



- [7] Kant V, Gopal A, Kumar D, Gopalkrishnan A, Pathak NN, Kurade NP, et al. Topical pluronic F-127 gel application enhances cutaneous wound healing in rats. *Acta Histochem* 2014;116:5–13. <https://doi.org/10.1016/j.acthis.2013.04.010>.
- [8] Nalbandian RM, Henry RL, Balko KW, Adams DV, Neuman NR. Pluronic F-127 gel preparation as an artificial skin in the treatment of third-degree burns in pigs. *J Biomed Mater Res* 1987;21:1135–48. <https://doi.org/10.1002/jbm.820210907>.
- [9] Hokett SD, Cuenin MF, O'Neal RB, Brennan WA, Strong SL, Runner RR, et al. Pluronic Polyol Effects on Human Gingival Fibroblast Attachment and Growth. *Journal of Periodontology* 2000;71:803–9. <https://doi.org/10.1902/jop.2000.71.5.803>.
- [10] Demirci S, Doğan A, Karakuş E, Halıcı Z, Topçu A, Demirci E, et al. Boron and Poloxamer (F68 and F127) Containing Hydrogel Formulation for Burn Wound Healing. *Biol Trace Elem Res* 2015;168:169–80. <https://doi.org/10.1007/s12011-015-0338-z>.