



HAL
open science

Early Left-Planum Temporale Asymmetry in newborn monkeys (*Papio anubis*): A longitudinal structural MRI study at two stages of development

Yannick Becker, Julien Sein, Lionel Velly, Laura Giacomino, Luc Renaud, Romain Lacoste, Jean-Luc Anton, Bruno Nazarian, Cammie Berne, Adrien Meguerditchian

► To cite this version:

Yannick Becker, Julien Sein, Lionel Velly, Laura Giacomino, Luc Renaud, et al.. Early Left-Planum Temporale Asymmetry in newborn monkeys (*Papio anubis*): A longitudinal structural MRI study at two stages of development. *NeuroImage*, 2021, 227, pp.117575. 10.1016/j.neuroimage.2020.117575 . hal-03086011v1

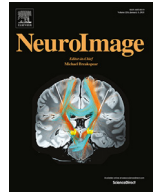HAL Id: hal-03086011

<https://hal.science/hal-03086011v1>

Submitted on 22 Dec 2020 (v1), last revised 13 Apr 2021 (v2)

HAL is a multi-disciplinary open access archive for the deposit and dissemination of scientific research documents, whether they are published or not. The documents may come from teaching and research institutions in France or abroad, or from public or private research centers.

L'archive ouverte pluridisciplinaire **HAL**, est destinée au dépôt et à la diffusion de documents scientifiques de niveau recherche, publiés ou non, émanant des établissements d'enseignement et de recherche français ou étrangers, des laboratoires publics ou privés.



Early Left-Planum Temporale Asymmetry in newborn monkeys (*Papio anubis*): A longitudinal structural MRI study at two stages of development

Yannick Becker^{a,b}, Julien Sein^b, Lionel Velly^b, Laura Giacomino^b, Luc Renaud^b,
Romain Lacoste^c, Jean-Luc Anton^b, Bruno Nazarian^b, Cammie Berne^a,
Adrien Meguerditchian^{a,c,*}

^a Laboratoire de Psychologie Cognitive, UMR 7290, Université Aix-Marseille / CNRS, 13331 Marseille, France

^b Institut des Neurosciences de la Timone, UMR 7289, Université Aix-Marseille / CNRS, 13005 Marseille, France

^c Station de Primatologie, CNRS, UPS846, 13790 Rousset, France

ARTICLE INFO

Keywords:

Hemispheric specialization
Lateralization
Language evolution
Development
MRI
Baboon

ABSTRACT

The “language-ready” brain theory suggests that the infant brain is pre-wired for language acquisition prior to language exposure. As a potential brain marker of such a language readiness, a leftward structural brain asymmetry was found in human infants for the Planum Temporale (PT), which overlaps with Wernicke’s area. In the present longitudinal *in vivo* MRI study conducted in 35 newborn monkeys (*Papio anubis*), we found a similar leftward PT surface asymmetry. Follow-up rescanning sessions on 29 juvenile baboons at 7–10 months showed that such an asymmetry increases across the two ages classes. These original findings in non-linguistic primate infants strongly question the idea that the early PT asymmetry constitutes a human infant-specific marker for language development. Such a shared early perisylvian organization provides additional support that PT asymmetry might be related to a lateralized system inherited from our last common ancestor with Old-World monkeys at least 25–35 million years ago.

1. Introduction

Language and its typical functional and structural asymmetric brain organization were initially considered as unique to *Homo sapiens* evolution (Crow, 2004), suggesting a specific “language-ready” brain dating back to 350 000 ago. Therefore, brain lateralization in several regions was hypothesized as one of the key features of the language-ready brain, as most humans show a greater cortical activation in the left hemisphere for most language functions (Vigneau et al., 2006). For instance, the left Planum Temporale (PT) - a region which overlaps with Wernicke’s area - was found particularly activated in a variety of auditory language processing tasks like phonological auditory decoding (Shapleske et al., 1999) and including the main perception component of the audio-motor loop for phonological processing (Vigneau et al., 2006). In the pioneering work of Geschwind and Levitsky (1968), a leftward PT asymmetry was also found at the anatomical level, suggesting its relationship with functional brain asymmetry for language tasks (Josse et al., 2006; Tzourio-Mazoyer et al., 2018).

Additionally, the “language-ready” brain theory suggests that the infant brain is pre-wired for language acquisition (e.g. Dehaene-Lambertz et al., 2002). Indeed, studies have reported that all human infants seem to have an innate, inherited readiness for language acquisition, independently from culture. For instance, newborns are initially able to distinguish every phoneme before selectively discriminating only phonemes related to the language they are exposed to Kuhl et al. (2008).

During their first year, infants will be also sensitive to vocal sounds, their native prosody and vowels, infer the abstract structure of speech and connect words to their referents (Dehaene-Lambertz and Spelke, 2015).

The neural structure for such a language readiness remains unclear. Nevertheless, white and grey matter organization in infants reveals similar architecture in comparison with adults (Dubois et al., 2010). Interestingly, similar to adults, three-month-old infants’ BOLD responses to speech showed a more pronounced activation of the PT in the left hemisphere (Dehaene-Lambertz et al., 2002), raising the question whether or not the PT might be functionally lateralized from birth on. Addition-

Abbreviation: PT, Planum Temporale.

* Corresponding author at: Laboratoire de Psychologie Cognitive, UMR 7290, Université Aix-Marseille / CNRS, 13331 Marseille, France.

E-mail address: adrien.meguerditchian@univ-amu.fr (A. Meguerditchian).

<https://doi.org/10.1016/j.neuroimage.2020.117575>

Received 27 July 2020; Received in revised form 8 October 2020; Accepted 16 November 2020

Available online 4 December 2020

1053-8119/© 2020 The Author(s). Published by Elsevier Inc. This is an open access article under the CC BY-NC-ND license (<http://creativecommons.org/licenses/by-nc-nd/4.0/>)

ally, structural *PT* leftward asymmetry was also shown in *post-mortem* fetuses or infant brains in early development (Witelson and Pallie, 1973; Wada, 1975; Chi et al., 1977) and with *in-vivo* structural MRI images (Dubois et al., 2010; Hill et al., 2010; Glasel et al., 2011). Such a structural *PT* left asymmetry may be established during the last trimester of fetal life (Chi et al., 1977) and are later increasing during development, suggesting its links with language development (Chi et al., 1977).

However, several studies in nonhuman primates questioned the structural *PT* asymmetry as a human-specific marker for the brain specialization for language. Manual delineation of *post-mortem* brain (Gannon et al., 1998) and *in-vivo* MRI scans (Hopkins et al., 1998; Hopkins and Nir, 2010; Marie et al., 2018), showed larger left *PT*s in both apes and baboons, suggesting that this neuroanatomical feature is shared also with Old-World monkeys.

Whether such an early neuroanatomical feature extended to other nonhuman primate infants is unknown although this comparative question remains critical for determining its supposed human uniqueness through evolution and its relation to a pre-wired brain for language acquisition.

Therefore, the aim of the present longitudinal *in-vivo* MRI study in nonhuman primates is to investigate, the structural neuroanatomical *PT* asymmetries in 35 baboon infants (*Papio anubis*) and its development across age through manual delineation of the region's surface. The earliest post-natal age class includes 33 newborns at the critical neurodevelopmental period below 3 months (as well as two 5-months old outliers) in which the synaptogenesis is maximal and the myelin, synapses and cell bodies are thus not fully mature (Scott et al., 2016). The follow-up MRI longitudinal scanning and *PT* delineation includes 29 of those 35 baboons at the older juvenile age class (i.e., from 7 to 10 months).

2. Methods

2.1. Subjects

Subjects ranged from 4 to 165 days of age (*Mean*: 32.63; *SD*: 6.13) and included 21 males and 14 females. Out of those 35 baboons, 29 were later rescanned a second time, ranging from 218 to 362 days of age (*Mean* = 278.62; *SD* = 30.11) (see table in supplementary methods with subjects' details).

All monkeys are housed in social groups at the Station de Primatologie CNRS (UPS 846, Rousset, France) and have free access to outdoor areas connected to indoor areas. All subjects are born in captivity from 1 (F1) or 2 generations (F2). Wooden and metallic structures enrich the enclosures. Feeding times are held four times a day with seeds, monkey pellets and fresh fruits and vegetables. Water is available *ad libitum*.

2.2. Animal handling

Minimally invasive medication was realized, and no premedication was needed. Mothers from the newborn subjects were captured with their infant the night before the scan at the Station de Primatologie for check-ups and were transported together the following day of the MRI session.

Upon arrival at the MRI center, the mother of the focal subject was sedated with an intramuscular injection of ketamine (3mg/kg) and medetomidine (30 μ g/Kg) as well as their focal infant if above 5 months old. Focal newborn below 5 months were not sedated and directly brought to the preparation room for the following procedures. Focal infants were then anesthetized under 6-8% sevoflurane induction with a mask. A catheter was then inserted into the caudal artery for blood-gas sampling, and tracheal intubation was performed for steady controlled ventilation using an anesthetic ventilator (Cato, Dräger, Germany). End-tidal carbon dioxide was monitored and used to adjust ventilation rate (0.2 to 0.3 Hz) and end-tidal volume. The anesthesia inside the MRI machine was then maintained using 3% sevoflurane via a calibrated

vaporizer with a mixture of air 0.75 L/min and O₂ 0.1 L/min). Peripheral oxygen saturation, heart rate and breathing rate, were monitored throughout experiments.

All animal procedures were approved by the "C2EA -71 Ethical Committee of neurosciences" (INT Marseille) under the number APAFIS#13553-201802151547729 v4, and has been conducted at the Station de Primatologie under the number agreement C130877 for conducting experiments on vertebrate animals (Rousset-Sur-Arc, France). All methods were performed in accordance with the relevant French law, CNRS guidelines and the European Union regulations (Directive 2010/63/EU).

2.2.1. Imaging protocol

From September 2017 to March 2020, *in-vivo* imaging was performed using a 3T clinical MRI scanner (MAGNETOM Prisma, Siemens, Erlangen, Germany) equipped with 80 mT/m gradients (XR 80/200 gradient system with slew rate 200 T/m/s) and a 2-channel B1 transmit array (TimTX TrueForm). For the sessions at t0 ("newborn" age class) and at t1 (i.e., from 7 to 10 months old), the animals were scanned in the supine position, with two 11 cm receive-only loop coils: one under the head and another one around the face of the animal. The holding of the two coils and the animal head was provided through the use of a pearl-tec bag (Vac Fix System) and some straps. Protection for noise reduction was attached around the ears. At the end of the MRI session, when fully awaked from anesthesia, baboons were carefully put back with their mother and then transported back at the Station de Primatologie for immediate (or delayed) reintroduction into their social groups under staff monitoring.

2.2.2. Structural acquisition protocol

T1w images were acquired using a 3D Magnetization Prepared Rapid Acquisition Gradient Echo (MPRAGE) (Mugler and Brookeman, 1990) sequence (0.4 mm isotropic, FOV = 103 × 103 × 102.4 mm, matrix=256 × 256 slices per slab=256, sagittal orientation, read-out direction of inferior (I) to superior (S), phase oversampling = 10%, averages=3, TR = 2500 ms, TE = 3.01 ms, TI = 900 ms, flip-angle = 8°, bandwidth=300 Hz/pixel, no fat suppression, pre-scan normalization). T2w images were acquired using a Sampling Perfection with Application optimized Contrast using different angle Evolutions (SPACE) sequence (Mugler et al., 2000) (0.4 mm isotropic, FOV = 154 × 115.5 × 102.4 mm, matrix=384 × 288, slice per slab=256, sagittal orientation, read-out direction I to S, phase oversampling=0%, averages=2, TR = 3200 ms, TE = 393 ms, bandwidth = 566 Hz/pixel, no fat suppression, echo train length = 790 ms and pre-scan normalization). The total acquisition time for structural scans was 65 min (35 min for T1w and 30 min for T2w).

2.3. Preprocessing of anatomical MRI

Anatomical T2w images of the first scanning session and anatomical T1w images of the second scanning session were noise corrected with the spatially adaptive nonlocal means denoising filter (Manjón et al., 2010) implemented in Cat12 toolbox (<http://www.neuro.uni-jena.de/cat/>) included in SPM12 (<http://www.fil.ion.ucl.ac.uk/>), which runs on MATLAB (R2014a).

Next, each image was manually oriented using ITK-Snap 3.6 according anterior and posterior commissures plane and the interhemispheric fissure plane.

2.4. Manual delineation of the *PT*

Manual delineation of the *PT* in the present study followed the same procedure than the previous MRI study on the *PT* asymmetry of adult baboons (Marie et al., 2018). However, because of the immature brains of the newborn subjects, T2w MRI signal was used instead of T1w MRI signal for manual delineation for the first longitudinal scans.

In fact, the T2w MRI signal is sensitive to the free water present in voxels. The proliferation of membranes due to synaptogenesis and the process of myelination will decrease the proportion of free water in the gray matter voxels and thus darken the images during maturation of the first human year post-natal. Therefore, a higher contrast is generated in comparison to T1w images in early immature brains, which helps for better delimitation (Dehaene-Lambertz and Spelke, 2015).

Following the procedures used in humans (Larsen et al., 1989), great apes (Hopkins et al., 1998; Hopkins and Nir, 2010; Cantalupo et al., 2003) and Old-World monkeys (Marie et al., 2018; Lyn et al., 2011), the surface of the *PT* homolog was measured in the coronal plane.

The T2w images of every subject were imported in ITK-Snap. In there, the region of interest was manually traced in the coronal plan on the individual native space with the ITK-Snap tool “Paint-Brush Mode” with feature round brush size 1, using a touchpad-driven pointer (Wacom Cintiq® 13HD).

Coronal planes were used because they display the full depth of the Sylvian fissure, of which the Planum Temporale is its floor. As described by Marie et al. (2018), delineation of the *PT* was performed as followed: The posterior border of the *PT* was characterized by the last caudal slice displaying the Sylvian fissure. The anterior border was defined by the full closure of the Insula sulcus and grey matter. This technique was chosen due to the inconsistency of the presence of the Heschl’s gyrus (see Marie et al., 2018; Lyn et al., 2011 for discussions).

For each slice, the delineation was traced on the most ventral boundary between the sulcus and the grey matter. In order to balance the rater’s possible handedness bias, tracing for each subject was randomly undertaken either from the most medial to the most lateral pixel of the Sylvian fissure or from the most lateral to the most medial pixel. This step was repeated on the next slice, moving posteriorly until the Sylvian fissure fell out of view.

Next, a surface area was generated across all slices for each hemisphere independently in a given subject (see Fig. 1.A). For each subject, an Asymmetry Quotient (AQ) of the left (L) and the right (R) surface areas was computed $AQ = (R - L) / [(R + L) \times 0.5]$ with the sign indicating the direction of asymmetry (negative: left side, positive: right side) and the value, the strength of asymmetry. Further, as reported by Hopkins and Nir (2010) for humans and great apes, the AQ was also used to classify the subjects as left-hemispheric biased ($AQ \leq -0.025$), right biased ($AQ \geq 0.025$), or nonbiased ($-0.025 < AQ < 0.025$). A threshold of 0.025 represents a 2.5% difference in surface area between left and right *PT*.

A second rater, blind to the side, confirmed the measures of the *PT* in a subsample of 15 individuals for both hemispheres (interrater correlation coefficient for 30 *PT* tracing was $r(30) = 0.94$, $p < 0.0001$).

2.5. Statistics

Statistics were conducted with R 3.6.1 (R Core Team (2017). R: A language and environment for statistical computing. R Foundation for Statistical Computing, Vienna, Austria. URL <https://www.R-project.org/>).

3. Results

3.1. *PT* structural asymmetry

We found a significant leftward asymmetry of the *PT* surface at a group-level in 35 newborn baboons (t0) according to a one sample t-test in the 35 subjects’ AQ scores (see Fig. 1.B), Mean AQ = -0.058 ± 0.067 SD; $t(34) = -5.15$, $p < 0.0001$. Categorization of individual AQ showed also a majority of leftward *PT*-biased individuals (see Fig. 1.C): 25 baboons exhibited a leftward hemispheric *PT* bias (71.4%) whereas 2 exhibited a rightward *PT* bias (5.7%) and 8 no *PT* bias (22.9%), a distribution quasi-identical than the one found in human infants (Wada, 1975). We found no difference of distribution between infant baboons and infant humans according to chi-square ($p = 0.25$ for three groups “Left

bias, Right bias, no bias” and $p = 0.20$ for two groups “Left bias, Right bias”). The number of leftward *PT*-biased baboons was significantly greater than the number of rightward *PT*-biased subjects according to chi-square test ($\chi^2 = 19.59$, $p < 0.0001$).

3.2. Age classes’ comparison of *PT* lateralization’s strength

Follow-up analysis among the 29 rescanned baboons when reaching 7 to 10 months of age (t1) showed a significant increased strength of the *PT* asymmetry (Mean Absolute AQ score, $M. = 0.105 \pm 0.065$ SD) in comparison to their earliest age class according to a paired sample t-test (Mean Absolute AQ score, $M. = 0.073 \pm 0.049$ SD), $t(28) = -2.39$, $p = 0.024$ (see Fig. 1.D) as well as a significant correlation between the two MRI sessions, $r(29) = 0.55$, $p < 0.002$.

3.3. Left, right *PT* surface areas

At t0, the mean *PT* surface areas were in the left hemisphere: $M. = 50.34 \text{ mm}^2 \pm 9.27$ SD (in males $M. = 51.07 \text{ mm}^2 \pm 9.80$ SD; in Females $M. = 49.24 \text{ mm}^2 \pm 9.17$ SD); and in the right hemisphere: $M. = 47.44 \text{ mm}^2 \pm 8.93$ SD (in males $M. = 48.53 \text{ mm}^2 \pm 9.35$ SD; in Females $M. = 45.79 \text{ mm}^2 \pm 7.78$ SD).

At t1, the mean *PT* surface areas were in the left hemisphere: $M. = 58.48 \text{ mm}^2 \pm 8.0$ SD (in males $M. = 59.23 \text{ mm}^2 \pm 8.07$ SD; in Females $M. = 57.67 \text{ mm}^2 \pm 7.75$ SD); and in the right hemisphere: $M. = 55.73 \text{ mm}^2 \pm 8.65$ SD (in males $M. = 57.07 \text{ mm}^2 \pm 9.99$ SD; in Females $M. = 54.28 \text{ mm}^2 \pm 6.64$ SD).

3.4. Age, sex, brain size effect

Multiple linear regression analyses showed that the right *PT* surface ($p = 0.001$), the left *PT* surface ($p = 0.02$) and age ($p = 0.033$) predict *PT* asymmetry strength but not the subject’s sex and brain volume. At t0 and t1, no significant differences of mean AQs, mean Left *PT* surface, and of mean Right *PT* surface were found between males and females.

4. Discussion

Our results showed that early post-natal nonhuman primate infants present a significant human-like neuroanatomical asymmetry of the Planum Temporale surface (*PT*) in favor of the left hemisphere. This finding is clearly consistent with early *PT* asymmetry found in human newborns and infants (Chi et al., 1977; Dubois et al., 2010; Glasel et al., 2011; Hill et al., 2010; Wada, 1975; Witelson and Pallie, 1973) although measurement methods, Left-Right-Ambi classification threshold and statistical power in terms of sample size differ as well as age class equivalence which overall make interspecies comparison challenging. Nevertheless, the distribution is quasi-identical to the ones reported in both human infants and human adults (Geschwind and Levitsky, 1968) but also in adult chimpanzees (Hopkins and Nir, 2010) and adult baboons (Marie et al., 2018). Our findings are also somewhat consistent with averaged-brain leftward asymmetries found in infant Rhesus macaques within large temporal clusters which seem to overlap with *PT* according to an automated source-based method (Xia et al., 2019). Such a similar age-related phenomenon was also described in human infants by Wada (1975). Interestingly, we found that the direction of individual *PT* asymmetry is consistent across age classes while its strength is increasing with age. In contrast, no sex or brain size effects were found on direction or strength of *PT* asymmetry. This finding is not consistent with the idea that increase in *PT* asymmetry in *Hominidae* evolution was due to increase in brain volume (Pilcher et al. 2001). Additionally, if strength of *PT* asymmetry is affected by sex in human adults (Hirnstain et al., 2019), it seems not the case in adult baboons (Marie et al., 2018), infant baboons and human infants (Dubois et al. 2010).

This finding in a non-linguistic species clearly questions the historical idea that such a maturational effect of the *PT* asymmetry’s strength

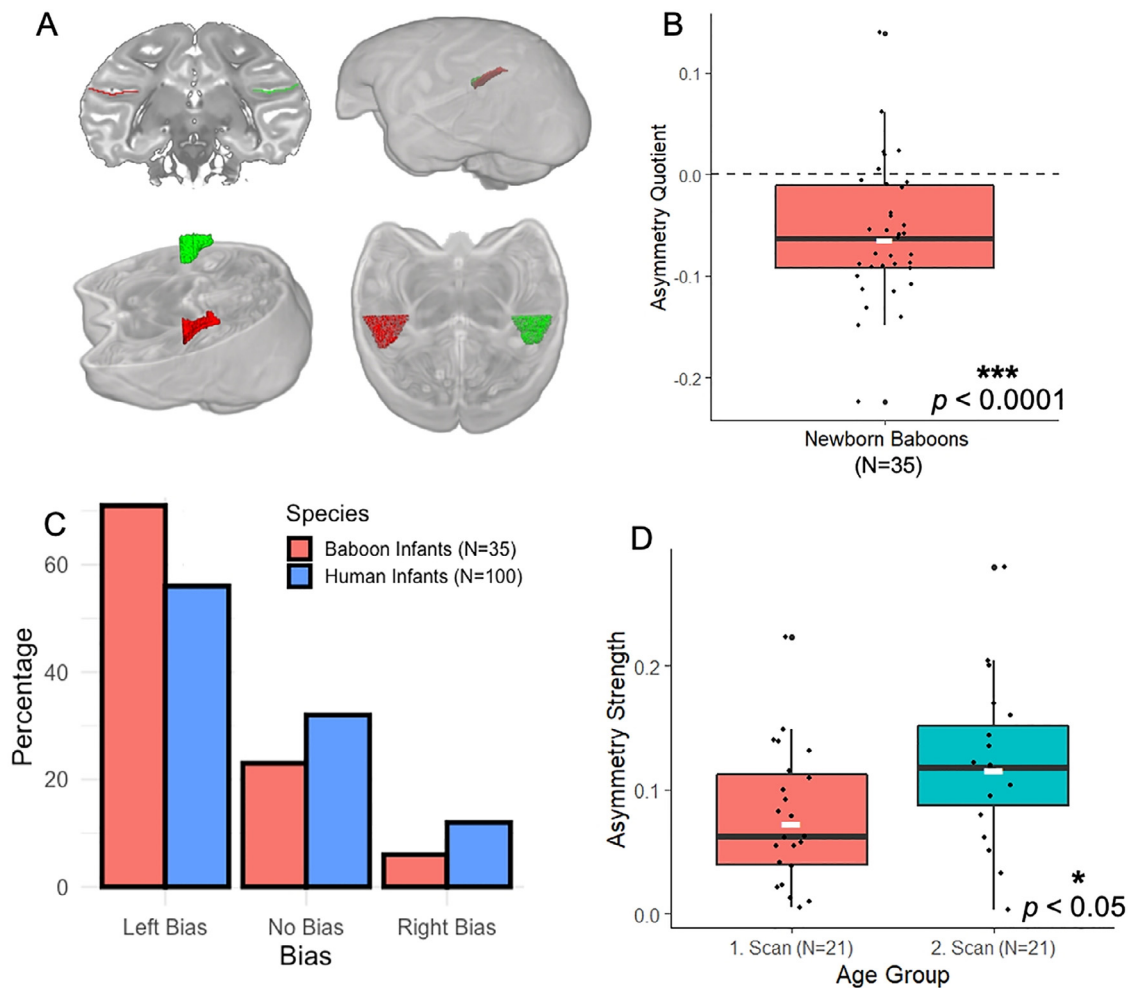


Fig. 1. (A) Representation of the asymmetric Planum Temporale (PT) in the baboon brain on a T2w image according to a coronal section, 3D brain render and oblique section oriented along the Sylvian Fissure (the left PT is in red and the right PT in green). (B) Mean Asymmetry quotient (AQ) for the Planum Temporale surface of the newborn infant baboons (N = 35). Negative Mean AQ score indicates leftward hemispheric asymmetry at a population-level. The long black line represents the median, the white short line the mean. $***p < 0.0001$ (C) Subjects distribution (in percentage) as a function of the direction of their PT asymmetry in baboon infants (N = 35, in red) versus in human infants (N = 100, in blue, from Wada, 1975). (D) Variation of strength of the Planum Temporale surface's asymmetry (Mean absolute AQ score) among the 29 baboons scanned longitudinally at two early stages of development: Newborn (in red) versus Juveniles (i.e., from 7 to 10 months in blue). $*p < 0.05$.

is related to language development in human infants (Wada, 1975). One could ask whether the existence of the asymmetry shortly after birth has an innate, and thus, genetic component as hypothesized for human infants (Hill et al., 2010) or to what extent it is rather influenced by pre- and post-natal experience. In any case, the collective findings clearly provide additional support for the phylogenetic continuity between human and nonhuman primate species about such a brain asymmetric feature. Such a continuity extended at the earliest postnatal stage of development across both species may question the early PT asymmetry as a human newborn-specific marker of the language-ready brain.

Structural lateralization of such a language area may not solely account for a pre-wired brain for language acquisition as it was supposed for human babies (Dehaene-Lambertz et al., 2002).

However, it remains unclear which factor is driving such a common early asymmetric feature of the brain anatomy among human and nonhuman infants. One potential explanation is that early PT structural asymmetry might have nothing to do with development of language lateralization, given some studies in adults reported no match between structural and functional asymmetry of this region (Keller, 2011; Greve, 2013).

Nevertheless, the most recent study addressing this question in adults contradicts such a hypothesis (Tzourio-Mazoyer et al., 2018). Although the lack of match was confirmed between structural and functional asymmetry of the PT in a language task, structural PT asymmetry was found associated with functional lateralization of an adjacent auditory area at the end of the Sylvian fissure, suggesting its links with language lateralization.

Therefore, another potential explanation is that the early PT structural asymmetry in both human and nonhuman infants might predict the development of homolog communicative functions, which still form a foundation for core aspects of the human language system. Determining such common developing functions between species remains highly speculative, given the lack of longitudinal studies in infants on the emergence of brain-behavior relationships. Nevertheless, based on neuroimaging studies in nonhuman primate focusing on adults, it might be not excluded that shared properties of communicative systems in human and nonhuman primates could be related to PT structural asymmetry. For instance, previous studies in monkeys and apes have reported human-like functional lateralization for processing conspecific calls. However, its overlap with PT anatomical region remains unclear as well as the direction of the functional lateralization (i.e., toward left

versus right hemisphere) which are inconsistent across the literature (e.g. Poremba et al.; 2004; Gil-da-Costa and Hauser 2006; Petkov et al. 2008; Joly et al., 2012). Alternatively, some authors have proposed that properties of the communicative gestural system in non-human primates could constitute another potential functional candidate of *PT* specialization. In fact, whereas production of communicative manual gestures have been found highly lateralized in favor of the right-hand in both baboons and chimpanzees (Meguerditchian et al., 2013), a contralateral relation between *PT* structural asymmetry and hand preferences for communicative gesture was reported in adult chimpanzees (Hopkins and Nir, 2010; Meguerditchian et al., 2012). These latter findings have thus suggested that shared property between gesture signaling in apes and language system in humans might be both ultimately related to this asymmetry feature of the temporal lobe anatomy (Meguerditchian et al., 2012). Whether similar gestural functional specialization of the structural *PT* asymmetry exists in baboons has been not investigated yet although both chimpanzees and baboons have shown similar leftward structural asymmetry of the *PT* as well as similar rightward patterns of gestural communication's manual lateralization.

Further studies in our sample of infant baboons would help us determine the potential relationship between these early *PT* structural asymmetry and development of manual lateralization of communicative gestures.

In conclusion, the present finding in nonhuman infants provides additional support to the hypothesis of a continuity between nonhuman and human primates concerning leftward structural *PT* asymmetry. Sharing such an anatomical feature of the brain at this earlier postnatal stage of development reinforced thus the idea of its common origins from our distant evolutionary ancestor, dated back 25–35 million years ago, although its potential link with the language-ready brain remains an open question.

Declaration of Competing Interest

Authors declare no competing interests.

Acknowledgments

General: We are very grateful to the vet Marie Dumasy for supervising the first health and anesthesia monitoring, Emilie Rapha for great assistance and animal care, Frederic Charlin, as well as the care staff of the Station de Primatologie, such as Valérie Moulin, Brigitte Rimbaud, Richard Francioly, the vets Pascaline Boitelle, Alexia Cermolacce & Janneke Verschoor, and the behavioral manager Pau Molina. We thank also Kep Kee Loh for English corrections.

Funding

The project has received funding from the European Research Council under the European Union's Horizon 2020 research and innovation program grant agreement No 716931 - GESTIMAGE - ERC-2016-STG (P.I. Adrien Meguerditchian), from the French "Agence Nationale de la Recherche" ANR-16-CONV-0002 (ILCB) and the Excellence Initiative of Aix-Marseille University (A*MIDEX). This MRI acquisitions were done at the Center IRM-INT (UMR 7289, AMU-CNRS), platform member of France Life Imaging network (grant ANR-11-INBS-0006).

Author contributions

Y.B and A.M prepared the paper and the revision. Y.B. performed the tracing and analyses. C.B. performed the interrater tracing. J.S. parametrized the MRI sequences and optimized the MRI acquisition setup. B.N. designed the baboons' monitoring programs. L.V., L.R., R.L. and L.G. designed the specific procedures of welfare, anesthesia, monitoring and preparation of baboons in the MRI machine. J.L.A supervised and coordinated the MRI session. A.M. designed and supervised the study and MRI acquisitions.

Data and materials availability

All data is available in the supplementary materials.

Data availability statement

Our data will be available online upon publication and is attached to this submission in the supplementary material.

Supplementary materials

Supplementary material associated with this article can be found, in the online version, at doi:10.1016/j.neuroimage.2020.117575.

References

- Cantalupo, C., Pilcher, D.L., Hopkins, W.D., 2003. Are planum temporale and sylvian fissure asymmetries directly related?: A MRI study in great apes. *Neuropsychologia* 41, 1975–1981. doi:10.1016/S0028-3932(02)00288-9.
- Chi, J.G., Dooling, E.C., Gilles, F.H., 1977. Gyral development of the human brain. *Ann. Neurol.* 1, 86–93. doi:10.1002/ana.410010109.
- Crow, T.J., 2004. *The Speciation of Modern Homo Sapiens*. OUP/British Academy.
- Dehaene-Lambertz, G., Dehaene, S., Hertz-Pannier, L., 2002. Functional neuroimaging of speech perception in infants. *Science* 298, 2013–2015. doi:10.1126/science.1077066.
- Dehaene-Lambertz, G., Spelke, E.S., 2015. The infancy of the human brain. *Neuron* 88, 93–109. doi:10.1016/j.neuron.2015.09.026.
- Dubois, J., Benders, M., Lazeyras, F., Borradori-Tolsa, C., Leuchter, R.H.-V., Mangin, J.F., Hüppi, P.S., 2010. Structural asymmetries of perisylvian regions in the preterm newborn. *NeuroImage* 52, 32–42. doi:10.1016/j.neuroimage.2010.03.054.
- Gannon, P.J., Holloway, R.L., Broadfield, D.C., Braun, A.R., 1998. Asymmetry of chimpanzee planum temporale: humanlike pattern of Wernicke's brain language area homologue. *Science* 279, 220–222. doi:10.1126/science.279.5348.220.
- Geschwind, N., Levitsky, W., 1968. Human brain: left-right asymmetries in temporal speech region. *Science* 161, 186–187. doi:10.1126/science.161.3837.186.
- Gil-da-Costa, R., Hauser, M.D., 2006. Vervet monkeys and humans show brain asymmetries for processing conspecific vocalizations, but with opposite patterns of laterality. *Proc. R. Soc. B: Biol. Sci.* 273, 2313–2318. doi:10.1098/rspb.2006.3580.
- Glaser, H., Leroy, F., Dubois, J., Hertz-Pannier, L., Mangin, J.F., Dehaene-Lambertz, G., 2011. A robust cerebral asymmetry in the infant brain: the rightward superior temporal sulcus. *NeuroImage* 58, 716–723. doi:10.1016/j.neuroimage.2011.06.016.
- Greve, D.N., Van der Haegen, L., Cai, Q., Stufflebeam, S., Sabuncu, M.R., Fischl, B., Brysbaert, M., 2013. A surface-based analysis of language lateralization and cortical asymmetry. *J. Cogn. Neurosci.* 25, 1477–1492. doi:10.1162/jocn_a.00405.
- Hill, J., Inder, T., Neil, J., Dierker, D., Harwell, J., Van Essen, D., 2010. Similar patterns of cortical expansion during human development and evolution. *Proc. Natl. Acad. Sci.* 107, 13135–13140. doi:10.1073/pnas.1001229107.
- Hirnstein, M., Hugdahl, K., Hausmann, M., 2019. Cognitive sex differences and hemispheric asymmetry: a critical review of 40 years of research. *Laterality* 24, 204–252. doi:10.1080/1357650X.2018.1497044.
- Hopkins, W.D., Marino, L., Rilling, J.K., MacGregor, L.A., 1998. Planum temporale asymmetries in great apes as revealed by magnetic resonance imaging (MRI). *NeuroReport* 9, 2913–2918.
- Hopkins, W.D., Nir, T.M., 2010. Planum temporale surface area and grey matter asymmetries in chimpanzees (Pan troglodytes): the effect of handedness and comparison with findings in humans. *Behav. Brain Res.* 208, 436–443. doi:10.1016/j.bbr.2009.12.012.
- Joly, O., Ramus, F., Pressnitzer, D., Vanduffel, W., Orban, G.A., 2012. Interhemispheric differences in auditory processing revealed by fMRI in awake Rhesus monkeys. *Cerebral Cortex* 22, 838–853. doi:10.1093/cercor/bhr150.
- Josse, G., Hervé, P.-Y., Crivello, F., Mazoyer, B., Tzourio-Mazoyer, N., 2006. Hemispheric specialization for language: brain volume matters. *Brain Res.* 1068, 184–193. doi:10.1016/j.brainres.2005.11.037.
- Keller, S.S., Roberts, N., García-Piñana, M., Mohammadi, S., Ringelstein, E.B., Knecht, S., Deppe, M., 2011. Can the language-dominant hemisphere be predicted by brain anatomy? *J. Cognit. Neurosci.* 23, 2013–2029. doi:10.1162/jocn.2010.21563.
- Kuhl, P.K., Conboy, B.T., Coffey-Corina, S., Padden, D., Rivera-Gaxiola, M., Nelson, T., 2008. Phonetic learning as a pathway to language: new data and native language magnet theory expanded (NLM-e). *Philos. Trans. R. Soc. B: Biol. Sci.* 363, 979–1000. doi:10.1098/rstb.2007.2154.
- Larsen, J.P., Ødegaard, H., Grude, T.H., Høien, T., 1989. Magnetic resonance imaging - a method of studying the size and asymmetry of the planum temporale. *Acta Neurologica Scandinavica* 80, 438–443. doi:10.1111/j.1600-0404.1989.tb03906.x.
- Lyn, H., Pierre, P., Bennett, A.J., Fears, S., Woods, R., Hopkins, W.D., 2011. Planum temporale grey matter asymmetries in chimpanzees (Pan troglodytes), vervet (Chlorocebus aethiops sabaeus), rhesus (Macaca mulatta) and bonnet (Macaca radiata) monkeys. *Neuropsychologia* 49, 2004–2012. doi:10.1016/j.neuropsychologia.2011.03.030.
- Manjón, J.V., Coupé, P., Martí-Bonmatí, L., Collins, D.L., Robles, M., 2010. Adaptive non-local means denoising of MR images with spatially varying noise levels. *J. Magn. Resonance Imaging* 31, 192–203. doi:10.1002/jmri.22003.
- Marie, D., Roth, M., Lacoste, R., Nazarian, B., Bertello, A., Anton, J.-L., Hopkins, W.D., Margiotoudi, K., Love, S.A., Meguerditchian, A., 2018. Left brain asymmetry of the Planum Temporale in a nonhominid primate: redefining the origin of brain specialization for language. *Cereb Cortex* 28, 1808–1815. doi:10.1093/cercor/bhx096.

- Meguerditchian, A., Gardner, M.J., Schapiro, S.J., Hopkins, W.D., 2012. The sound of one-hand clapping: handedness and perisylvian neural correlates of a communicative gesture in chimpanzees. *Proc. Biol. Sci.* 279, 1959–1966. doi:10.1098/rspb.2011.2485.
- Meguerditchian, A., Vauclair, J., Hopkins, W.D., 2013. On the origins of human handedness and language: a comparative review of hand preferences for bimanual coordinated actions and gestural communication in nonhuman primates. *Dev. Psychobiol.* 55, 637–650. doi:10.1002/dev.21150.
- Mugler, J.P., Bao, S., Mulkern, R.V., Guttman, C.R.G., Robertson, R.L., Jolesz, F.A., Brookeman, J.R., 2000. Optimized single-slab three-dimensional spin-echo MR Imaging of the brain. *Radiology* 216, 891–899. doi:10.1148/radiology.216.3.r00au46891.
- Mugler, J.P., Brookeman, J.R., 1990. Three-dimensional magnetization-prepared rapid gradient-echo imaging (3D MP RAGE). *Magn. Reson. Med.* 15, 152–157. doi:10.1002/mrm.1910150117.
- Petkov, C.I., Kayser, C., Steudel, T., Whittingstall, K., Augath, M., Logothetis, N.K., 2008. A voice region in the monkey brain. *Nat. Neurosci.* 11, 367–374. doi:10.1038/nn2043.
- Pilcher, D.L., Hammock, E.A.D., Hopkins, W.D., 2001. Cerebral volumetric asymmetries in non-human primates: a magnetic resonance imaging study. *Laterality* 6, 165–179. doi:10.1080/713754406.
- Poremba, A., Malloy, M., Saunders, R.C., Carson, R.E., Herscovitch, P., Mishkin, M., 2004. Species-specific calls evoke asymmetric activity in the monkey's temporal poles. *Nature* 427, 448–451. doi:10.1038/nature02268.
- Scott, J.A., Grayson, D., Fletcher, E., Lee, A., Bauman, M.D., Schumann, C.M., Buonocore, M.H., Amaral, D.G., 2016. Longitudinal analysis of the developing rhesus monkey brain using magnetic resonance imaging: birth to adulthood. *Brain Struct. Funct.* 221, 2847–2871. doi:10.1007/s00429-015-1076-x.
- Shapleske, J., Rossell, S.L., Woodruff, P.W.R., David, A.S., 1999. The planum temporale: a systematic, quantitative review of its structural, functional and clinical significance. *Brain Res. Rev.* 29, 26–49. doi:10.1016/S0165-0173(98)00047-2.
- Tzourio-Mazoyer, N., Crivello, F., Mazoyer, B., 2018. Is the planum temporale surface area a marker of hemispheric or regional language lateralization? *Brain Struct. Funct.* 223, 1217–1228. doi:10.1007/s00429-017-1551-7.
- Vigneau, M., Beaucousin, V., Hervé, P.Y., Duffau, H., Crivello, F., Houdé, O., Mazoyer, B., Tzourio-Mazoyer, N., 2006. Meta-analyzing left hemisphere language areas: Phonology, semantics, and sentence processing. *NeuroImage* 30, 1414–1432. doi:10.1016/j.neuroimage.2005.11.002.
- Wada, J.A., 1975. Cerebral hemispheric asymmetry in humans: cortical speech zones in 100 adult and 100 infant brains. *Arch. Neurol.* 32, 239. doi:10.1001/archneur.1975.00490460055007.
- Witelson, S.F., Pallie, W., 1973. Left hemisphere specialization for language in the newborn: neuroanatomical evidence of asymmetry. *Brain* 96, 641–646. doi:10.1093/brain/96.3.641.
- Xia, J., Wang, F., Wu, Z., Wang, L., Zhang, C., Shen, D., Li, G., 2019. Mapping hemispheric asymmetries of the macaque cerebral cortex during early brain development. *Hum. Brain Map.* doi:10.1002/hbm.24789.