



HAL
open science

Metal-Metal Hip Prosthesis and Kidney Cancer: Assumed Role of Chromium and Cobalt Overload

Valentin Massardier, Mickaël Catinon, Ana-Maria Trunfio-Sfarghiu, Jacques Hubert, Michel Vincent

► **To cite this version:**

Valentin Massardier, Mickaël Catinon, Ana-Maria Trunfio-Sfarghiu, Jacques Hubert, Michel Vincent. Metal-Metal Hip Prosthesis and Kidney Cancer: Assumed Role of Chromium and Cobalt Overload. The American journal of case reports, 2020, 10.12659/AJCR.923416 . hal-03083759

HAL Id: hal-03083759

<https://hal.science/hal-03083759>

Submitted on 21 Dec 2020

HAL is a multi-disciplinary open access archive for the deposit and dissemination of scientific research documents, whether they are published or not. The documents may come from teaching and research institutions in France or abroad, or from public or private research centers.

L'archive ouverte pluridisciplinaire **HAL**, est destinée au dépôt et à la diffusion de documents scientifiques de niveau recherche, publiés ou non, émanant des établissements d'enseignement et de recherche français ou étrangers, des laboratoires publics ou privés.

Received: 2020.02.10

Accepted: 2020.05.08

Available online: 2020.07.24

Published: 2020.XX.XX

Metal-Metal Hip Prosthesis and Kidney Cancer: Assumed Role of Chromium and Cobalt Overload

Authors' Contribution:

Study Design A
Data Collection B
Statistical Analysis C
Data Interpretation D
Manuscript Preparation E
Literature Search F
Funds Collection GEF 1,2 **Valentin Massardier**
ABCDF 1 **Mickaël Catinon**
DG 2 **Ana-Maria Trunfio-Sfarghiu**
B 3,4 **Jacques Hubert**
ACDEFG 1 **Michel Vincent**

1 Minapath Development, Villeurbanne, France

2 Contact and Structure Mechanics Laboratory (LaMCoS), National Institute of Applied Sciences of Lyon (INSA Lyon), University of Lyon, Villeurbanne, France

3 Department of Urology, University Hospital, Vandoeuvre-les-Nancy, France

4 Diagnosis and International Adaptive Imaging (IADI) INSERM (U1254), Lorraine University (UL), Vandoeuvre-les-Nancy, France

Corresponding Author: Valentin Massardier: e-mail: valentin.massardier@insa-lyon.fr**Conflict of interest:** Dr. Michel Vincent is CEO of Minapath Development**Source of support:** This study was funded by the french Association Against Thoracic Cancers and Mineralopathologies (ALCTMP), the European FEDER fund and the Auvergne-Rhône-Alpes region

Patient: Female, 68-year-old

Final Diagnosis: Bilateral renal carcinoma

Symptoms: Bleeding of renal track • discomfort

Medication: —

Clinical Procedure: Cancer nodule removal • prosthesis replacement • radiotherapy

Specialty: Neurology • Orthopedics and Traumatology

Objective: Unusual clinical course


Background: The case of a patient with bilateral renal cancers diagnosed at 94 and 120 months after metal-on-metal hip placement may serve as a warning. It suggests that there may be a need for kidney echography observation of patients with similar types of prostheses.

Case Report: A 61-year-old woman received a metal-on-metal hip prosthesis for degenerative arthritis in January 2007. In November 2014, after bleeding from the renal tract, she was diagnosed with clear cell carcinoma of the right kidney. When she returned to her orthopaedic surgeon 1 year later, a blood test showed a serum cobalt level that exceeded the French medical agency recommendation. After the patient's metallic acetabulum was replaced in September 2015, her blood cobalt level fell. However, in February 2017, she was diagnosed with adenocarcinoma of the left kidney. Laser-induced breakdown spectroscopy (LIBS) showed cobalt, chromium, and silica overload in both the patient's kidneys despite the drop in serum levels.

Conclusions: In this case, exposure to a cobalt-chromium implant with high particulate wear, LIBS results showing chromium overload of the kidneys, diagnosis of renal cancer at 7 years, 10 months and 10 years in a patient with a metal-on-metal hip prosthesis suggests that there may be a causal relationship between the implant, carcinogenic chromium intoxication, and development of renal cancer.

MeSH Keywords: Hip Prosthesis • Kidney Neoplasms • Metal Nanoparticles • Nephrology

Full-text PDF: <https://www.amjcaserep.com/abstract/index/idArt/923416>




1101



—



1



19



Background

A hip joint prosthesis may generate metal or polyethylene wear particles, which can lead to locoregional or systemic reactions such as metallosis, granuloma or aseptic loosening [1–5]. Since 2008, national registries in several countries [6,7] have shown that metal-to-metal prostheses are associated with more revisions than conventional metal-polyethylene prostheses. Incidence of revisions is reported to be 30% after 17 years for metal-on-metal prostheses carrying with a high head diameter greater than 32 mm, versus 5% to 15% for conventional prostheses [8]. In 2012, the French Agency of Health Safety of Medical Devices (AFSSAPS) [9,10] advised orthopedic surgeons to perform cobalt testing on patients with metal-on-metal hip prostheses with large heads and to counsel them about removal if the results showed a cobalt level greater than $10 \mu\text{g}\cdot\text{l}^{-1}$, which is suggestive of excessive wear. They only identify a risk for people allergic to metals, with a higher risk of metallosis, and for women in childbearing age because metallic ions could have effects on the embryo [11]. Here, we present a case study that suggests a causal relationship between chromium intoxication and bilateral renal cancer.

Case Report

In January 2007, a 61-year-old woman with degenerative arthritis received a metal-on-metal hip prosthesis with a head diameter of 28 mm. Her body mass index (BMI) was 31.07 (reported as obesity), her systolic blood pressure was 182 mmHg, and her diastolic blood pressure was 74 mmHg. In November 2014, she presented with bleeding from the renal tract and a urologic checkup with echography revealed a voluminous lesion inside the right kidney. In January 2015, a nephrectomy was performed. A pT3a renal clear cell carcinoma (RCC) measuring $10.2 \times 6.7 \times 5.5$ cm with extension to peri-renal fat and tracking conduct without extension to the lymph node was removed.

In May 2015, the patient was seen by her orthopedic surgeon after he received a warning from the AFSSAPS about risks linked to metal-on-metal prostheses. At that time, she had some discomfort when pressure was applied to or she slept on her right side. Hip x-ray showed no anomaly but the patient's serum cobalt level was 13.39 nmol/L. Based on the AFSSAPS recommendations, the surgeon recommended replacement of the prosthesis. The surgery was performed in September 2015. The original implant was replaced with an ultra-high mass weight polyethylene cotyle and a cobalt chromium head with a diameter of 28 mm.

In December 2015, during a check-up for RCC, a nodule was detected in the patient's left lung. It was surgically removed in May 2016 and subsequently identified as a secondary RCC

lesion. In February 2016, a blood test showed that the patient's cobalt blood level had gone down to 3.7 nmol/L.

A year later, renal echography revealed a 24-mm suspect nodule on the woman's left kidney. Puncture identified another RCC, but because of its aggressive pathology, it was difficult to determine whether the mass was a new cancer or a secondary metastasis. That tumor was treated with focal external radiation therapy.

The embedded paraffin block from the patient's first nephrectomy was sent to Minapath Development for detection of potential mineral particles in the parenchyma by scanning electron microscopy coupled with energy-dispersive x-ray spectrometry (SEM-EDX) and then by laser-induced breakdown spectroscopy (LIBS, ABLATOM, Villeurbanne, France). Three kidney samples from the Lyon's Forensic Institute, which families have authorized for use in research, were used as references.

SEM-EDX did not identify chromium or cobalt particles, but LIBS analysis showed chromium, cobalt, and silicon overload levels of 72.5, 27.1, and 6.1 times higher, respectively, than the average in the three control kidneys (Figure 1).

The patient completed an in-depth questionnaire about occupational and environmental exposure to minerals, which failed to identify specific exposure except that she had worked for about 8 years in a school that probably contaminated by asbestos. (One co-teacher there presented with mesothelioma).

Discussion

A search of the literature failed to identify any other studies reporting a connection between hip prostheses and renal cancer. However, an association between hexavalent chromium and colorectal, stomach, and prostate cancer has been documented [12–14]. When placed in an oxidative medium, bulk chromium develops a thin layer of passivation [15]. This layer consists of chromium oxides that protect the material, but it can be worn off by friction. Chromium (VI) compounds are classified as Group 1 carcinogenic agents by the IARC [16] with renal elimination, and accumulation of this material in the renal parenchyma may induce development of tumors. The proximity between the particles and the tumor as well as the plausibility of an RCC due to the demonstration of the carcinogenic effect of hexavalent chromium on other organs provides support for seriously considering a causal relationship between exposure to this element and the tumor observed, despite the presence in this patient of other risk factors such as high BMI and hypertension.

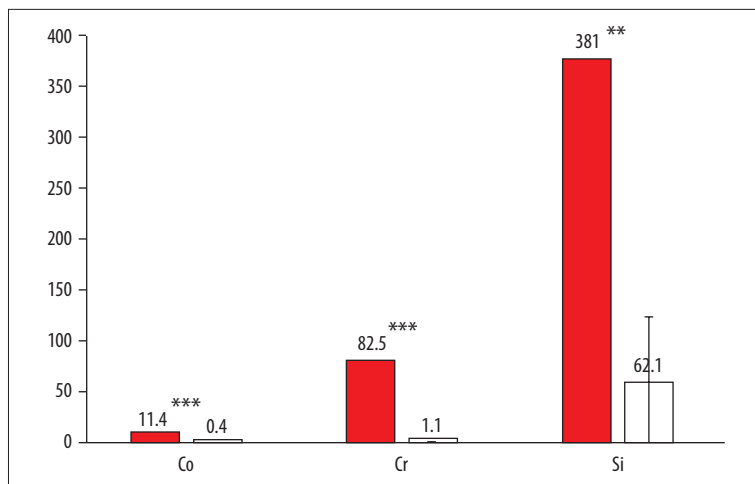


Figure 1. Concentration in spots/cm² of different elements obtained by LIBS. White box – reference, red box – patient sample. Asterisks represent significance level: ** 0.01 and *** 0.001.

Mineralogical analysis of tissue from a cancer-bearing organ by digestion or by *in situ* studies can identify the pathogenic mineral agent, as has been well demonstrated in reports on the search for asbestos bodies [17].

In the patient described in this case, the SEM-EDX study of a 5- μ m section of renal tissue compared to that of three renal tissues of Lyon Forensic Institute patients did not show specific chromium overload because our microscope only allows for visualization of micron-size particles, and not circulating ions or nano-size particles in the tissue. By contrast, LIBS analysis of the surface of the same paraffin block can identify elements in ionic form, such as chromium [18,19].

The association of exposure to a cobalt-chromium implant with high particulate wear, a demonstration by LIBS of a chromium overload of the kidney and the occurrence at 7 years and 10 months and 10 years of two kidney cancers supports a possible causal relationship between prosthesis implantation, carcinogenic chromium intoxication, and renal cancer.

It is particularly alarming to note that despite a reduction in blood chromium level after implant removal, particles continued

to be fixed in the renal parenchyma, placing the patient at continued high risk of cancer of the kidney.

Conclusions

Given the high risk of chromium dissemination and despite the reduced incidence of metal-on-metal hip prosthesis placement, this index case should prompt retrospective studies with a large group of patients over a long period of time. If other cases of kidney cancer are confirmed, patients with significant cobalt levels should undergo regular renal ultrasound monitoring to ensure early detection and management of RCC.

Acknowledgements

We thank ALCTMP, the Auvergne-Rhône-Alpes region and the European FEDER fund for funding the project and ABLATOM (Villeurbanne, France) for the LIBS analysis.

Conflict of interest

Dr. Michel Vincent is CEO of Minapath Development.

References:

- Case CP, Langkamer VG, James C et al: Widespread dissemination of metal debris from implants. *J Bone Joint Surg*, 1994; 76: 701–12
- Peoch M, Moulin C, Pasquer B: Systemic granulomatous reaction to Foreign body after hip replacement. *N Engl J Med* 1996; 335: 133–34
- Doom PF, Campbell PA, Amstutz HC: Metal versus polyethylene wear particles in total hip replacements. *Clin Orthop Relat Res*, 1996; 329S: S206–16
- Urban RM, Tomlison MJ, Hall DJ, Jacobs JJ: Dissemination of wear particles to the liver, spleen, and abdominal lymph nodes of patients with hip or knee replacement. *J Bone Joint Surg*, 2000; 82-A: 457–77
- Bittar D, Parvizi J: Biological response to prosthetic debris. *World J Orthop*, 2015; 6: 172–89
- Drummond J, Phong T, Fary C: Metal-on-Metal hip arthroplasty: A review of adverse reactions and patient management. *J Funct Biomater*, 2015; 6: 486–99
- Dapunt U, Giese T, Lasitschka F et al: The inflammatory response in metal-on-metal implants. *J Transl Med*, 2014; 12: 74
- Australian Orthopaedic Association National Joint Replacement Registry (AOANJRR). Hip, Knee & Shoulder Arthroplasty: 2019 Annual Report. Adelaide: AOA, 2019. <https://aoanjrr.sahmri.com/annual-reports-2019>
- The French Agency for the Safety of Health Products (AFSSAPS). [ASR hip prostheses from the manufacturer DePuy recalled in July 2010: AFSSAPS recommendations – Information point.] 2012. <https://ansm.sante.fr/S-informer/Points-d-information-Points-d-information/Protheses-de-hanche-ASR-du-fabricant-DePuy-rappelees-en-juillet-2010-recommandations-de-l-Afssaps-Point-d-information> [in French]
- National Agency for the Safety of Medicines and Health Products (ANSM). [Methods of monitoring patients with total hip prosthesis with metal-metal coupled friction.] https://ansm.sante.fr/var/ansm_site/storage/original/application/0adb46da3096f9ce463611b830d170d1.pdf [in French]

11. National Agency for the Safety of Medicines and Health Products (ANSM). [Warning concerning hip prostheses with metal-metal coupled friction.] <https://ansm.sante.fr/S-informer/Informations-de-securite-Autres-mesures-de-securite/Mise-en-garde-concernant-les-protheses-de-hanche-a-couple-de-frottement-metal-metal-Information-de-securite> [in French]
12. Zhang Z, Cao H, Song N et al: Long-term hexavalent chromium exposure facilitates colorectal cancer in mice associated with changes in gut microbiota composition. *Food Chem Toxicol*, 2020; 138: 111237
13. Suh M, Wikoff D, Lipworth L et al. Hexavalent chromium and stomach cancer: A systematic review and meta-analysis. *Crit Rev Toxicol*, 2019; 49(2): 140–59
14. Zhang C, Cai K, Feng Q et al: Chromium(VI) promotes cell migration through targeting epithelial-mesenchymal transition in prostate cancer. *Toxicol Lett*, 2019; 300: 10–17
15. Dobruchowska E, Paziewska M, Przybyl K, Reszka K: Structure and corrosion resistance of Co-Cr-Mo alloy used in Birmingham Hip Resurfacing system. *Acta Bioeng Biomech*, 2017; 19(2): 31–39
16. Beyersmann D, Hartwig A. Carcinogenic metal compounds: Recent insight into molecular and cellular mechanisms. *Arch Toxicol*, 2008; 82: 493–512
17. Roggli VL, Vollmer RT: Twenty-five years of fiber analysis: What have we learned? *Hum Pathol* 2016; 39: 307–15
18. Sancey L, Motto-Ros V, Busser B et al: Laser spectroscopy for multi-elemental imaging of biological tissues. *Sci Rep*, 2014; 4: 6065
19. Busser B, Moncayo S, Col JL, Sancey L, Motto-Ros V: Elemental imaging using laser-induced breakdown spectroscopy: A new and promising approach for biological and medical application. *Coord Chem Rev*, 2018; 358: 70–79