



HAL
open science

MRI evaluation of the hydration status of non-pathological lumbar intervertebral discs in a pediatric population

Manon Bolzinger, Erik Estivalèzes, Adeline Gallini, Eva Polirsztok, Kariman Abelin-Genevois, Christiane Baunin, Jérôme Sales de Gauzy, Pascal Swider

► **To cite this version:**

Manon Bolzinger, Erik Estivalèzes, Adeline Gallini, Eva Polirsztok, Kariman Abelin-Genevois, et al.. MRI evaluation of the hydration status of non-pathological lumbar intervertebral discs in a pediatric population. *Orthopaedics & Traumatology: Surgery & Research*, 2020, 106 (7), pp.1281-1285. 10.1016/j.otsr.2019.11.034 . hal-03034231

HAL Id: hal-03034231

<https://hal.science/hal-03034231v1>

Submitted on 14 Dec 2020

HAL is a multi-disciplinary open access archive for the deposit and dissemination of scientific research documents, whether they are published or not. The documents may come from teaching and research institutions in France or abroad, or from public or private research centers.

L'archive ouverte pluridisciplinaire **HAL**, est destinée au dépôt et à la diffusion de documents scientifiques de niveau recherche, publiés ou non, émanant des établissements d'enseignement et de recherche français ou étrangers, des laboratoires publics ou privés.



Open Archive Toulouse Archive Ouverte

OATAO is an open access repository that collects the work of Toulouse researchers and makes it freely available over the web where possible

This is an author's version published in: <https://oatao.univ-toulouse.fr/26772>

Official URL:

<https://doi.org/10.1016/j.otsr.2019.11.034>

To cite this version:

Bolzinger, Manon and Estivalèzes, Erik and Gallini, Adeline and Polirsztok, Eva and Abelin-Genevois, Kariman and Baunin, Christiane and Sales de Gauzy, Jérôme and Swider, Pascal MRI evaluation of the hydration status of non-pathological lumbar intervertebral discs in a pediatric population. (2020) Orthopaedics & Traumatology: Surgery & Research, 106 (7). 1281-1285. ISSN 1877-0568

Any correspondence concerning this service should be sent to the repository administrator: tech-oatao@listes-diff.inp-toulouse.fr

MRI evaluation of the hydration status of non-pathological lumbar intervertebral discs in a pediatric population

Manon Bolzinger ^{a,b,*}, Erik Estivalèzes ^a, Adeline Gallini ^c, Eva Polirsztok ^d, Kariman Abelin-Genevois ^e, Christiane Baunin ^b, Jérôme Sales de Gauzy ^{a,b}, Pascal Swider ^a

^a IMFT UMR 5502 CNRS, Toulouse, France

^b Hôpital des enfants, Toulouse, France

^c UMR 1027 Inserm Toulouse 3, Toulouse, France

^d Hôpital universitaire de Nancy, Nancy, France

^e CMCR des Massues, Lyon, France

A B S T R A C T

Keywords:
Intervertebral disc
MRI
Image processing

Introduction: The intervertebral disc (IVD) is made up of the annulus fibrosus (AF) and the nucleus pulposus (NP) – an inert hydrated complex. The ability of the IVD to deform is correlated to that of the NP and depends on its hydration. As the IVD ages, its hydration decreases along with its ability to deform. In adolescent idiopathic scoliosis, one of the etiological hypotheses pertains to the IVD, thus making its condition relevant for the diagnosis and monitoring of this pathology.

Hypothesis: IVD hydration depends on sex, age and spine level in an asymptomatic pediatric population. The corollary is data on a control group of healthy subjects.

Material and methods: A cohort of 98 subjects with normal spine MRI was enrolled; their mean age was 13.3 years. The disc volume and hydration of each IVD was evaluated on T2-weighted MRI sequences, using previously validated image processing software. This evaluation focused on the lumbar spine, from the thoracolumbar junction to the lumbosacral junction. It was assumed that IVD hydration was related to the ratio of NP and AF volumes. A mixed multivariate linear analysis was used to explore the impact of age, sex and spinal level on disc hydration.

Results: Disc hydration was higher overall in boys than in girls, but this difference was not significant. Hydration increased with age by +0.005 for each additional year ($p = 0.0213$). Disc hydration appears to be higher at the thoracolumbar junction than the lumbar spine, although this difference was not significant.

Conclusion: Through this MRI study, we established a database of non-pathological lumbar disc hydration as a function of age, sex and spinal segment along with 95% confidence intervals.

Level of evidence: IV.

1. Introduction

Homeostasis of the vertebral segment is associated with diffusion between the intervertebral disc (IVD) and the adjacent vertebral body through the cartilaginous endplate [1]. In adults, the IVD is an avascular structure in which liquids pass from the nucleus pulposus (NP) (hydrated complex) toward a peripheral laminal structure, the annulus fibrosus (AF). The disc's vascularization changes gradually during growth to dwindle at the end of the trunk's growth in pre-adulthood.

IVD hydration depends on its proteoglycan content. Under physiological conditions, fluid and proteins are exchanged by a mechanotransduction process, involving hydrostatic and cyclic osmotic pressure associated to the circadian rhythm [2,3]. The composition and organization of the IVD extracellular matrix determines its biomechanical properties. These vary with age, physiological status and spinal level. Water loss is one of the first signs of IVD pathology [4]. Our study focused on a pediatric population that will serve as a control group for the study of adolescent idiopathic scoliosis (AIS). Among the multiple etiological factors for AIS, one of the hypotheses is based on the IVD. MRI is used for the diagnosis and follow-up of this disease [5–7]. After posterior spinal fusion, the reaction of the instrumented discs subjected to additional stresses is related to the instrumentation level and the number of levels fused [8,9]. A landmark study [10] suggested that

* Corresponding author. Hôpital des enfants, 30, avenue de Grande-Bretagne, 31059 Toulouse, France.

E-mail address: manon.bolzinger@outlook.fr (M. Bolzinger).

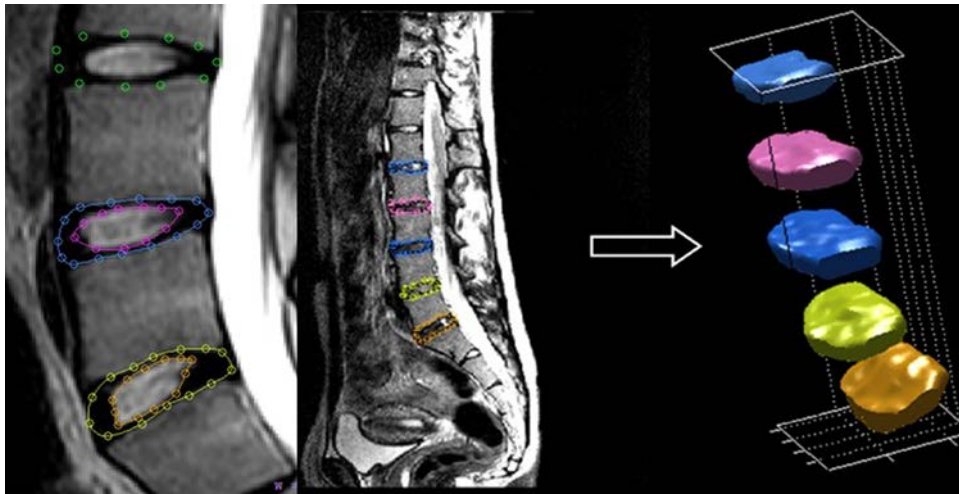


Fig. 1. Semi-automated segmentation and automated volume reconstruction (Biomechlab®) of IVD from MRI slices (L5-S1 to L1-L2).

three clusters exist based on the composition of the IVD's extracellular matrix and its hydration: less than 5 years, between 25 and 40 years, between 40 and 80 years. A follow-up study [11] showed that lumbar IVD maturation is related to increased hydration.

We hypothesized that between 7 and 20 years, the hydration of non-pathological IVDs depends on sex, age and spinal level. The primary aim of this study was to determine the relationship between lumbar IVD hydration and sex, age, and spinal level in a pediatric population free of spinal conditions. The secondary aim was to generate mathematical curves to predict lumbar IVD hydration as a function of sex, age and spinal level in a pediatric population.

2. Materials and methods

2.1. Patient population

This retrospective study included 98 consecutive subjects (50% girls) between 7 and 20 years of age who underwent a spinal MRI at the Toulouse University Hospital that was considered normal. These subjects had undergone an MRI for the diagnosis of a urological or neurological disease, or lumbar pain over a 2-year period (04/2015-04/2017). To be included, no spinal disease or spinal postural disease could be detected after the MRI images were read by a pediatric imaging specialist.

The mean age of the included subjects was 13.3 years (SD = 2.92). Our evaluation focused on the lumbar spine, from the thoracolumbar junction to the lumbosacral junction. The MRI acquisition consisted of T2-weighted sequences in the sagittal plane with 15 to 20 consecutive slices per patient. The MRI unit was a PHILIPS Achieva X-Series 3.0T.

2.2. Disc volume

Automatic IVD detection and segmentation on MRI images is not yet optimized despite recent progress [12,13]. Thus, our procedure made use of previously validated Biomechlab® image processing software [5,6,14], which was developed in the MATLAB environment (MathWorks®). After automated decoding of the DICOM images, the disc volume was extrapolated using semi-automated detection of the AF and NP outlines. The protocol was repeated by a spine surgeon on each sagittal slice. Each disc was visible on an average of 10 sequential slices. The IVD segmentation and 3D reconstruction based on MRI data is shown in Fig. 1. The discs from T12-L1 to L5-S1 were evaluated. Anatomically, the NP was identified as a highly hydrated tissue resembling a viscous fluid, appearing as a

hyperintense signal on T2-weighted images. The 2D segmentation of MRI slices and the 3D reconstruction were used to define the disc hydration as the ratio of NP volume to AF volume. The water content is concentrated in the NP; its volume gets smaller when the IVD is dehydrated, while the IVD's overall volume does not change. This relationship between IVD hydration and the NP/IVD volume is anatomically reliable.

2.3. Statistical analysis

For the statistical analysis, a mixed multivariable linear model was used to take into consideration the interindividual variation in patients. We sought to set up a hydration model by spinal level (T12-L1 to L5-S1), sex (boy or girl) and age. The age of the cohort corresponds to the ages at which AIS evolves [15,16]. Significant findings were defined as those with $p < 0.05$.

A generic statistical model of IVD hydration distribution was proposed by age, sex and spinal level. Twelve models were generated with 95% confidence intervals (CI).

3. Results

Table 1 summarizes the raw values of the disc volume based on the segmentation of the MRI images by spinal level and for the entire cohort ($n = 98$). The mean IVD volume was 8973 mm³ and the mean NP volume was 2823 mm³. The mean hydration ratio was 0.335. The findings are summarized in Fig. 2.

Table 2 summarizes the statistical analysis of hydration by age, sex and spinal level based on the mixed multivariate linear model.

The T12-L1 disc was used as the reference when investigating the effect of spinal level. Hydration in the lower levels was always less than in the T12-L1 disc, but not significantly ($0.1 \leq p \leq 0.8$). Also, hydration decreases along with spinal column, but not significantly ($p = 0.4915$).

As for sex, the boys were used as a reference. Disc hydration was lower in girls by an average of -0.0158 although this was not significant ($p = 0.21$).

A generic statistical model of the population was generated based on linear regression with 95% CI. The variations in hydration by age, sex and spinal level are shown in Fig. 3. These models showed that hydration increased in boys independent of the spinal level and was slightly higher than in girls. In girls, age had no impact on T12-L1 and L5-S1 hydration while it had minimal impact on discs L1-L2 to L4-L5.

Table 1

Distribution of quantitative variables in the pediatric cohort ($n=98$). The volume and hydration ratio are classified by spinal segment with $p25=25$ th percentile, $p50=50$ th percentile, $p75=75$ th percentile and SD = standard deviation.

Parameter	Mean	SD	Min	p25	p50	p75	Max
IVD volume (mm^3)							
T12.L1	7611.3	3175.7	2127.4	5327.4	7183.6	9310.0	17863.1
L1.L2	9593.0	3934.2	2325.5	6874.8	8836.1	12023.9	21111.2
L2.L3	10012.5	3624.9	2821.3	7770.0	9480.4	11766.2	19257.0
L3.L4	10039.8	3261.9	3365.4	8304.6	9324.5	11394.7	20510.0
L4.L5	9169.9	3031.4	3184.0	6997.4	8680.8	10822.1	19394.5
L5.S1	7407.2	2526.0	1541.6	5725.1	6979.9	8907.7	13586.8
NP volume (mm^3)							
T12.L1	2496.3	1585.7	338.2	1234.9	1890.7	3633.5	7715.4
L1.L2	3091.5	1787.7	499.0	1685.5	2808.5	3916.2	7756.3
L2.L3	3196.0	1625.6	563.0	2092.4	2699.0	3996.4	8135.0
L3.L4	3110.0	1516.1	839.2	2047.4	2777.8	3955.5	7291.2
L4.L5	2830.7	1195.6	837.5	1891.0	2570.1	3586.7	5727.2
L5.S1	2216.8	905.0	348.0	1596.6	2072.7	2795.8	4824.7
Hydration							
T12.L1	0.31	0.10	0.13	0.23	0.30	0.37	0.81
L1.L2	0.31	0.07	0.14	0.26	0.31	0.35	0.50
L2.L3	0.31	0.06	0.16	0.26	0.30	0.35	0.51
L3.L4	0.30	0.07	0.15	0.25	0.30	0.35	0.50
L4.L5	0.31	0.07	0.16	0.26	0.30	0.35	0.48
L5.S1	0.30	0.07	0.15	0.26	0.29	0.34	0.68

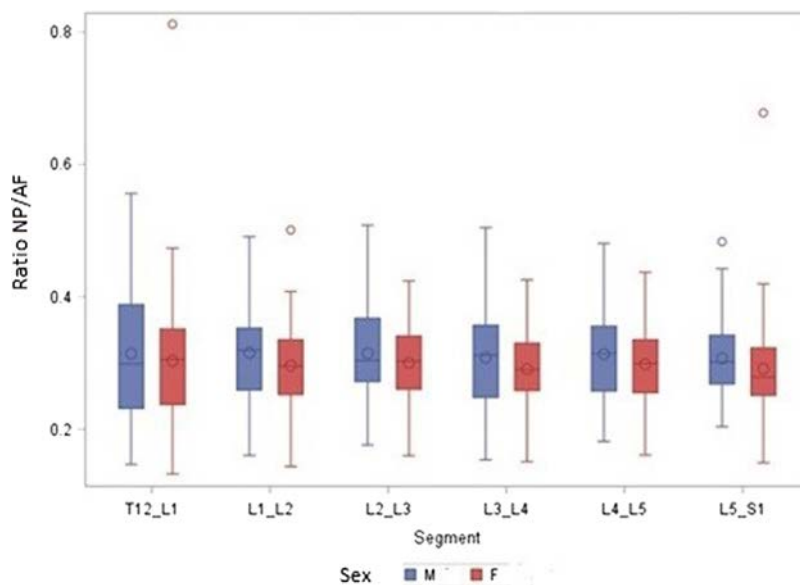


Fig. 2. Distribution of IVD hydration along the lumbar spine (T12-L1 to L5-S1) and by sex.

Table 2

Description of the mixed multivariate linear model for the pediatric cohort. Disc hydration was determined relative to spinal level, age, and sex. Hydration in the T12-L1 disc was used as a reference.

Parameter	Mean	SD	t test	p	Min	Max
Segment						
L1.L2	-0.00315	0.0068	-0.52	0.60	-0.01514	0.008842
Segment						
L2.L3	-0.00143	0.0059	-0.23	0.81	-0.01342	0.01056
Segment						
L3.L4	-0.00928	0.0065	-1.52	0.13	-0.02127	0.002711
Segment						
L4.L5	-0.00298	0.0061	-0.49	0.62	-0.01497	0.009010
Segment						
L5.S1	-0.00957	0.0071	-1.57	0.12	-0.02156	0.002422
Gender						
Female	-0.01580	0.0126	-1.25	0.21	-0.04055	0.008953
Age	0.005007	0.0021	2.31	0.021	0.000747	0.009266

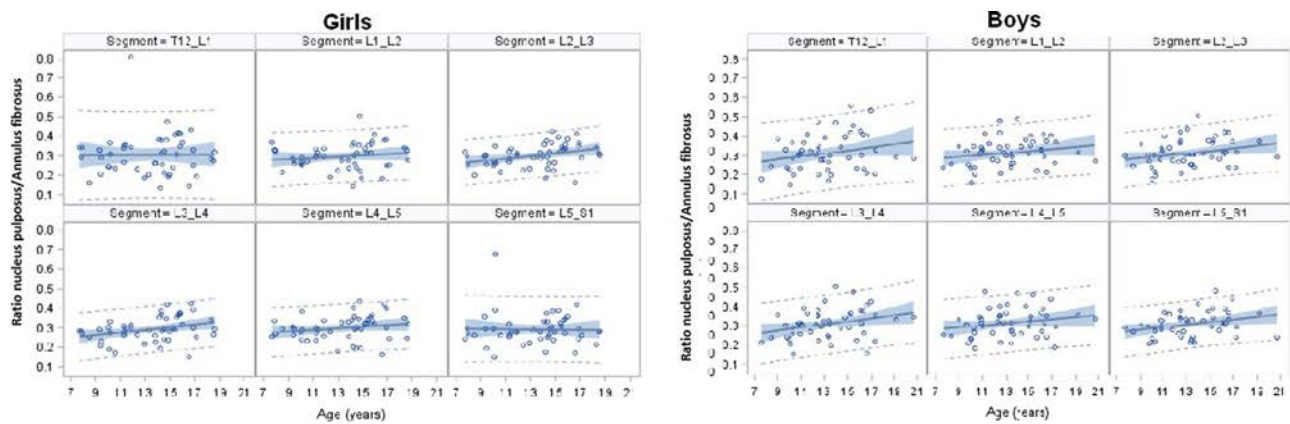


Fig. 3. Distribution of IVD hydration for the pediatric cohort ($n=98$) by sex, age and spinal segment. The solid line is the best linear fit. The blue area is the 95% confidence interval and the dotted lines are the limits of the 95% prediction interval.

Our models allowed us to generate IVD hydration prediction intervals. As expected, these had a wide range because of the additional uncertainty related to predicting individual values.

4. Discussion

Our main hypothesis – that IVD hydration was related to sex, age and spinal level – was partially confirmed. The influence of sex was not statistically significant although disc hydration level was generally lower in girls. The two subgroups were comparable in terms of age: mean age in girls was 13.4 years (range, 7.0–18.6), mean age in boys was 13.3 years (range, 7.0–19.2). This sex-related trend could be an argument in favor of the IVD being involved in the development of IAS, which is more common in girls. This hypothesis must be explored further, especially on IVD in the thoracic region, since our study was done solely on the lumbar spine whereas AIS has a right thoracic curvature.

The impact of spinal level was also investigated. While the thoracolumbar discs had higher hydration, this finding was not statistically significant. Hydration increases with age and appears to level off in the oldest patients of this cohort. An increase of +0.005 in the NP/AF ratio for each additional year was found in the overall cohort.

Histology studies have shown the IVD is a very specific structure, whose role is closely related to the adjacent cartilage. The chondrocyte-like cells in the NP produce type II collagen, while the chondrocyte-like cells in the cartilage and AF produce both type I and II collagen [17]. Unlike in adults, during the first decade of life, blood vessels are visible in the AF and adjacent cartilage. The number of blood vessels decreases over time [17]. The water content depends on the presence of proteoglycans and collagen fibers forming the retentive framework [10,18]. The proteoglycans and water on one hand, and the collagen fibers on the other, have opposing distributions in the IVD. The amount of the former increases while the amount of collagen decreases from the periphery towards the NP. In the literature, there is a distinction between maturation and degeneration, separating processes before 10 years and after 20 years [19]. The lumbar IVD hydration increases with maturation during the first two decades [11] then decreases after 25 years of age. IVD hydration peaks around 2 to 5 years of age, then decreases after 25 years [10], although there is no data on the in-between ages. In this symptomatic pediatric population, the hydration increased between 7 and 20 years of age. These results should be applicable to children 5 to 11 years; however, no MRI of normal spines were available for analysis in children of this age.

Homeostasis of a spinal level is due to mass transport between the disc and vertebral body through the vertebral end plates. The

disc's vascularization decreases gradually from childhood though pre-adulthood, at which point it is non-existent. The disc has very good clinical and mechanical properties when these exchanges are well established. The NP is highly hydrated relative to the AF. Consequently, the ratio between the NP volume and the IVD volume can be used as an index of disc hydration and may represent the health of the spinal segment. In a clinical context, hydration can be measured on MRI slices. When following patients with scoliosis, adding disc hydration to the MRI assessment allows us to explore the poromechanical behavior of the segments and can guide the clinical decision making (location and extension of the instrumentation). Restoring the hydration levels postoperatively may be used to predict future clinical complications.

While this study is original, it has certain limitations. Most subjects had undergone the MRI in the context of urological or neurological conditions; however, 14% of subjects had an MRI for a low-back pain. Spine pathology was ruled out by the radiologist reading the images. Since this was a retrospective study, the time of day at which the MRI scans were completed was not controlled. The acquisitions were generally done in the morning to get around the influence of daily activities. This non-controlled parameter may be considered as a randomization element that contributes favorably to the reliability of our findings. Not every subject had a full set of data available; for example, morphological data such as kyphosis, lordosis and pelvic incidence were not always available [19,20]. The skeletal maturity and level of puberty were not known. Despite these limitations, the size of this cohort (98 subjects) is acceptable, given the challenges associated with creating a pediatric database.

5. Conclusion

This description of IVD hydration in a pediatric population free of spinal pathology during peak growth years is novel. We believe this cohort can be used as a control group for clinical studies. The generic model created based on sex, age and spinal level is at the heart of this study. It could be a reference database for studying how the IVD impacts the changes in spinal curvature and stability in adolescents with AIS.

Disclosure of interest

The authors declare that they have no competing interest.

Funding

Master scholarship from the SOFCOT.

Author contributions

Contributed to the research work (M. Bolzinger, E. Estivalèzes, J. Sales de Gauzy, P. Swider), data acquisition (C. Baunin), data analysis or interpretation (M. Bolzinger, E. Estivalèzes, E. Polirsztok, K. Abelin-Genevois, A. Gallini, P. Swider).

Writing of article or substantial revision (M. Bolzinger, E. Estivalèzes, A. Gallini, J. Sales de Gauzy, P. Swider).

Validation of submitted version (M. Bolzinger, J. Sales de Gauzy, P. Swider).

Acknowledgements

We are grateful to the SOFCOT (France) for the scholarship awarded to Manon Bolzinger and to the Fondation Cotrel (Institut de France) for its on-going support of our research on idiopathic scoliosis. We are also grateful to Jérôme Briot PhD, who developed the Biomechlab[®] software, for his help.

References

- [1] Urban JP, Smith S, Fairbank JC. Nutrition of the intervertebral disc. *Spine* 2004;23:2700–9.
- [2] Setton LA, Chen J. Mechanobiology of the intervertebral disc and relevance to disc degeneration. *J Bone Joint Surg Am* 2006;88:52–7.
- [3] Henriksson H, Thormemo M, Karlsson C. Identification of cell proliferation zones, progenitor cells and a potential stem cell niche in the intervertebral disc region: a study in four species. *Spine* 2009;34:2278–87.
- [4] Benneker LM, Heini PF, Anderson SE. Correlation of radiographic and MRI parameters to morphological and biochemical assessment of intervertebral disc degeneration. *Eur Spine J* 2005;14:27–35.
- [5] Violas P, Estivalèzes E, Pédrone A, et al. A method to investigate intervertebral disc morphology from MRI in early idiopathic scoliosis: a preliminary evaluation in a group of 14 patients. *Magn Reson Imaging* 2005;23:475–9.
- [6] Abelin-Genevois K, Estivalèzes E, Briot J, et al. Spino-pelvic alignment influences disc hydration properties after AIS surgery: a prospective MRI-based study. *Eur Spine J* 2015;24:1183–90.
- [7] Waldenberg C, Hebelka H, Brisby H, et al. MRI histogram analysis enables objective and continuous classification of intervertebral disc degeneration. *Eur Spine J* 2018;27:1042–8.
- [8] Green DW, Lawhorne 3rd TW, Widmann RF, et al. Long-term magnetic resonance imaging follow-up demonstrates minimal transitional level lumbar disc degeneration after posterior spine fusion for adolescent idiopathic scoliosis. *Spine* 2011;36:1948–54.
- [9] Pesenti S, Jouve JL, Morin C, et al. Evolution of adolescent idiopathic scoliosis: results of a multicenter study at 20 years' follow-up. *Orthop Traumatol Surg Res* 2015;101:619–22.
- [10] Antoniou J, Steffen T, Nelson F, et al. The human lumbar intervertebral disc: evidence for changes in the biosynthesis and denaturation of the extracellular matrix with growth, maturation, ageing, and degeneration. *J Clin Invest* 1996;98:996–1003.
- [11] Krueger EC, Perry JO, Wu Y, et al. Changes in T2 relaxation times associated with maturation of the human intervertebral disk. *Am J Neuroradiol* 2007;28:1237–41.
- [12] Zheng G, Chu C, et al. Evaluation and comparison of 3D intervertebral disc localization and segmentation methods for 3D T2 MR data: a grand challenge. *Med Image Anal* 2017;35:327–44.
- [13] Gervais J, Périé D, Parent S, et al. MRI signal distribution within the intervertebral disc as a biomarker of adolescent idiopathic scoliosis and spondylolisthesis. *BMC Musculoskelet Disord* 2012;13:239.
- [14] Violas P, Estivalèzes E, Briot J, et al. Quantification of intervertebral disc volume properties below spine fusion, using Magnetic resonance imaging, in adolescent idiopathic scoliosis surgery. *Spine* 2007;32:405–12.
- [15] Duval-Beaupère G, Dubouset J, Queneau P, et al. Pour une théorie unique de l'évaluation des scolioses. *Presse Med* 1970;78:1141–6.
- [16] Duval-Beaupère G, Barthel F. Growth in scoliotics. *Rev Chir Orthop* 1983;69:201–6.
- [17] Roberts S, Evans H, Trivedi J, et al. Histology and Pathology of the human intervertebral disc. *JMJS* 2006;88:10–4.
- [18] Mwale F, Iatridis JC, Antoniou J. Quantitative MRI as a diagnostic tool of intervertebral disc matrix composition and integrity. *Eur Spine J* 2008;17: S432–40.
- [19] Rajasekaran S, Naresh Babu J, Arun R, et al. ISSLS prize winner: a study of diffusion in human lumbar discs: a serial magnetic resonance imaging study documenting the influence of the endplate on diffusion in normal and degenerate discs. *Spine* 2004;29:2654–67.
- [20] Janssen MM, Vincken KL, van Raak SM. Sagittal spinal profile and spinopelvic balance in parents of scoliotic children. *Spine* 2013;13:1789–800.