



HAL
open science

Biomechanical Evaluation of Intercostal Muscles in Healthy Children and Adolescent Idiopathic Scoliosis: A Preliminary Study

Raphaël Pietton, Mercedes David, Alisa Hisaund, Tristan Langlais, Wafa Skalli, Raphaël Vialle, Claudio Vergari

► To cite this version:

Raphaël Pietton, Mercedes David, Alisa Hisaund, Tristan Langlais, Wafa Skalli, et al.. Biomechanical Evaluation of Intercostal Muscles in Healthy Children and Adolescent Idiopathic Scoliosis: A Preliminary Study. *Ultrasound in Medicine & Biology*, 2021, 47 (1), pp.51-57. 10.1016/j.ultrasmedbio.2020.09.011 . hal-03031970

HAL Id: hal-03031970

<https://hal.science/hal-03031970>

Submitted on 30 Nov 2020

HAL is a multi-disciplinary open access archive for the deposit and dissemination of scientific research documents, whether they are published or not. The documents may come from teaching and research institutions in France or abroad, or from public or private research centers.

L'archive ouverte pluridisciplinaire **HAL**, est destinée au dépôt et à la diffusion de documents scientifiques de niveau recherche, publiés ou non, émanant des établissements d'enseignement et de recherche français ou étrangers, des laboratoires publics ou privés.

BIOMECHANICAL EVALUATION OF INTERCOSTAL MUSCLES IN HEALTHY CHILDREN AND ADOLESCENT IDIOPATHIC SCOLIOSIS: A PRELIMINARY STUDY

RAPHAËL PIETTON,^{*,†} MERCEDES DAVID,[‡] ALISA HISAUND,[‡] TRISTAN LANGLAIS,^{*,†} WAFI SKALLI,[‡]
RAPHAËL VIALLE,^{*,†} and CLAUDIO VERGARI[‡]

* Sorbonne Université, Department of Paediatric Orthopaedics, Armand Trousseau Hospital, APHP, Paris, France; † Sorbonne Université, Hospital-University Department for Innovative Therapies in Musculoskeletal Diseases DHU-MAMUTH, APHP, Paris, France; and ‡ Arts et Metiers ParisTech, LBM/Institut de Biomécanique Humaine Georges Charpak, Paris, France

Abstract—Spine deformity during adolescent idiopathic scoliosis can induce a rib-cage deformity. This bone deformity can have direct consequences on the chest-wall muscles, including intercostal muscles, leading to respiratory impairments in individuals with severe cases. The aim of this study was to determine whether shear-wave elastography can be used to measure intercostal-muscle shear-wave speed (SWS) in healthy children and those with adolescent idiopathic scoliosis (AIS). Nineteen healthy participants and 16 with AIS took part. SWS measurements were taken by three operators, twice each. Average SWS was 2.3 ± 0.4 m/s, and inter-operator reproducibility was 0.2 m/s. SWS was significantly higher during apnea than in normal breathing ($p < 0.01$) in both groups. No significant difference was observed between groups in apnea or in normal breathing. Characterization of the intercostal muscles by ultrasound elastography is therefore feasible and reliable for children and adolescents with and without scoliosis. (E-mail: raphael.pietton@aphp.fr)

Key Words: Respiratory muscles, Elasticity imaging techniques, Elastography, Young modulus, Intercostal muscles, Adolescent idiopathic scoliosis, Rib cage, Feasibility study.

INTRODUCTION

Adolescent idiopathic scoliosis (AIS) is a trunk deformity with no obvious cause, which begins at the time of the pubertal peak after the age of 10 y. The 3-D deformation of the spine can cause rib-cage deformity (Dreimann et al. 2014). In severe cases, spinal penetration into the rib cage on the concave side (Dubousset et al. 2003) and rib changes (Erkula et al. 2003) can lead to respiratory impairment. Respiratory involvement is most often manifested by the appearance of a restrictive syndrome (Pehrsson et al. 2001). An obstructive effect can also be caused by inflammation of the respiratory routes (Tsiliogiannis and Grivas 2012). Pulmonary function tests currently represent the standard of reference for evaluating the restrictive syndrome, but obtaining reliable spirometry depends on the individual's compliance. Bouloussa et al. (2019) were able to highlight the relationship between 3-D rib-cage volume using biplanar radiographs

and total lung capacity assessed by pulmonary function tests. However, this estimate remains imperfect. Characterization of the muscular and tendinous repercussions of rib-cage deformity could therefore improve estimation of the functional consequences of scoliosis on the trunk.

The intercostal muscles (ICMs) actively participate in respiratory mechanics. Several studies have shown that pulmonary ventilation asymmetry can be observed in AIS, albeit not correlated with scoliosis severity as estimated by the Cobb angle (Redding et al. 2008; Martínez-Llorens et al. 2010). Another study has investigated the electromyographic activity of the ICMs and found that ICM activity appears to be affected by scoliosis deformity (Mohammadi et al. 2014). It is therefore of interest to characterize *in vivo* the biomechanical characteristics of the ICMs in healthy individuals and those with scoliosis. Alterations of these properties might be related to the changes in respiratory function of individuals with AIS.

Ultrasound techniques have shown potential in evaluating muscle disorders (Chang et al. 2018, 2019). Shear-wave elastography (SWE) is a good candidate for

Address correspondence to: Raphael Pietton, Sorbonne Université, Department of Paediatric orthopaedics, Armand Trousseau Hospital, APHP, Paris France E-mail: raphael.pietton@aphp.fr

such measurement, as it is a non-invasive, ultrasound-based imaging technique that enables quantitative mapping of tissue mechanical properties (Gennisson et al. 2013). SWE can be used to measure the shear-wave speed (SWS) within tissue, and this speed is directly related to the tissue's mechanical properties. In particular, $SWS \approx (E/3\rho)^{0.5}$, where E is the tissue's Young modulus and ρ its mass density. This technique has been used in clinical practice to evaluate breast, liver, prostate and muscle lesions (Tanter et al. 2008; Rouvière et al. 2017; Yoon et al. 2017). More recently, an *in vivo* study has demonstrated the potential of SWE of the lumbar intervertebral disc in the study of disc changes in AIS (Langlais et al. 2018). Such a non-invasive and accessible means of evaluating the ICMs could provide a better understanding of the pathophysiology of respiratory involvement and the modification of the chest wall in AIS. Nevertheless, measurement can be operator dependent, and its reliability depends on operator experience as well as the anatomic structure being measured and the protocol adopted (Dubois et al. 2015). The rib cage presents the added difficulty of the individual's respiration; contraction or elongation of the muscle changes the tissue's elasticity, so this has to be accounted for in the measurement.

The main objective of the present work was to establish a protocol to measure SWS of the ICMs, establish its reliability and perform a preliminary comparison between children and adolescents with and without AIS.

MATERIALS AND METHODS

Participants

Data were collected prospectively from a pediatric spine center between December 2018 and April 2019; 420 elastographic acquisitions were performed with 35 participants (age, 12.8 ± 2.1 y; range, 9–16; 29 girls and six boys), which were divided in two age-matched groups. Nineteen asymptomatic participants (age, 12.6 ± 1.7 y; range, 10–15; 14 girls and five boys) were included in the first group if they had no history of spinal pathology. Clinical examination was performed in all asymptomatic children to ensure that there was no spinal deformity. Sixteen children and adolescents with AIS were included in the second group (age, 13 ± 2.5 y; range, 9–16; 15 girls and one boy; average Cobb angle, $31.5^\circ \pm 16.3^\circ$). This group was composed of patients followed for AIS at stages of varying severity, either in the pre-treatment stage ($n=11$; Cobb angle, $29^\circ \pm 16^\circ$) or during brace treatment ($n=5$; Cobb angle, $36^\circ \pm 18^\circ$). Each AIS patient underwent low-dose radiographs in a standing position. Spinal deformity was assessed by two independent observers, and the Cobb angle was measured to quantify the curve severity. The Cobb angle was

measured by drawing two lines parallel to the endplates of the vertebral bodies at the beginning and the end of the curve in the anteroposterior radiograph. A third and fourth line were drawn perpendicular to the first two lines to measure the Cobb angle. Trustees of parental authority gave informed consent, as approved by the institutional review board (C.P.P. Île de France IV, Records 14 409).

Intercostal acquisition and protocol

All SWS measurements were made with an Aixplorer (Supersonic Imagine, Aix-en-provence, France) and a linear SL10-2 probe. The depth, size of the elastographic image and position of the focus were adapted for each measurement. Participants were in a supine position, with the arms along the body, and measurements were made at the T5–T6 right intercostal space both during normal breathing and in apnea. Apnea was performed at tidal volume. The probe was placed orthogonally to the skin and to the courses of the ribs at the level of the mid-axillary line. The fascia between the anterior serratus and latissimus dorsi was used as a sonographic anteroposterior reference, as previously described in a serratus plane block protocol (Blanco et al., 2016). Ribs appeared as ovoid structures connected by a muscle band whose leaflets could be distinguished, and which corresponded to the ICMs (Fig. 1).

Two 10-s clips were recorded, one during normal breathing and one in apnea, and measurements were performed twice by each of three operators. The probe was repositioned after each measurement. This represented a total of 420 clips for the entire study (2 conditions \times 2 repetitions \times 3 operators \times 35 participants).

The data were then post-processed by dedicated software (Vergari et al. 2016) written in MATLAB

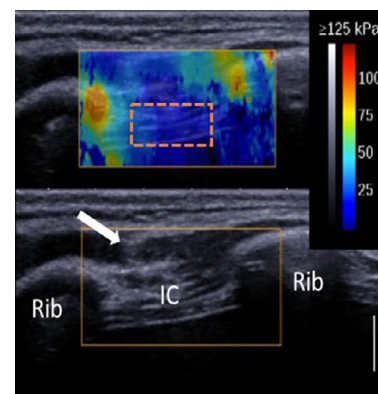


Fig. 1. Example of elastography image (top) and ultrasound (bottom) of intercostal muscles in an 11-y-old girl. The white arrow shows the limit between the serratus anterior and latissimus dorsi. The intercostal muscles are visible between the ribs. The dashed rectangle is the region of interest in the intercostal muscles.

Table 1. Repeatability and reproducibility of intercostal-muscle shear-wave speed

Measurement (m/s)	Mean \pm SD	Reproducibility (CV%)	Repeatability (CV%)	ICC (95% CI)
Healthy, apnea	2.2 \pm 0.5	0.3 (12.7)	0.2 (8)	0.8 (0.6, 0.9)
Healthy, respiration	2.1 \pm 0.4	0.2 (10.6)	0.1 (6.5)	0.8 (0.7, 0.9)
Scoliosis, apnea	2.5 \pm 0.6	0.3 (10.8)	0.2 (6.4)	0.9 (0.7, 0.9)
Scoliosis, respiration	2.2 \pm 0.3	0.2 (9.0)	0.1 (6.0)	0.8 (0.6, 0.9)
All participants	2.3 \pm 0.4	0.3 (12.6)	0.2 (10.4)	0.8 (0.7, 0.9)

CI = confidence interval; CV = coefficient of variation; ICC = intra-class correlation coefficient.

version 2016b (The MathWorks Inc., Natick, MA, USA). A region of interest (ROI) was defined in the ICM width, without including the ribs. The average SWS was calculated for the entire surface of the ROI, then ROIs of all frames (10 frames/clip) were averaged to obtain one SWS per clip. Frames with too much noise or saturation were discarded. The acquisition lasted about 10 min per operator (four clips).

Statistical analysis

Reproducibility and repeatability were evaluated according to the ISO 5725 standard in terms of standard deviation and coefficient of variation (CV). Intra-class correlation coefficients (ICC_{A-1}) and their 95% confidence intervals were also calculated to assess inter-operator reproducibility; an ICC greater than 0.75 was considered to signify good agreement. Bland–Altman plots were used to represent the limits of agreement (Bland and Altman 1986). Data were not normally distributed, according to the Lilliefors normality test, so non-parametric tests were used: differences between conditions were analyzed with a paired Wilcoxon rank test, and differences between groups with non-paired tests. Correlations were tested with the Spearman

correlation test. The statistical analysis was performed using IBM SPSS. Significance was set at 0.05.

RESULTS

Average weight in the healthy group was 48.7 ± 7 kg, and body mass index (BMI) was 19.3 ± 2 kg/m², whereas for the AIS group, average weight was 44.2 ± 9.3 kg and BMI was 17.9 ± 1.6 kg/m². The BMI of the AIS was significantly lower than in the healthy group ($p=0.03$). The mean of SWS and ICC values for both groups are given in Table 1.

Asymptomatic group

The average SWS of the ICMs in apnea (2.2 ± 0.5 m/s) was slightly but significantly higher than in normal breathing (2.1 ± 0.4 m/s, $p < 0.01$, paired statistical test). There was a significant correlation of BMI with both apnea ($p=0.02$, Spearman $\rho = -0.53$; Fig. 2) and normal respiration measurements ($p=0.04$, Spearman $\rho = -0.48$). A weak correlation was also observed between weight and apnea measurements ($p=0.045$, Spearman $\rho = 0.46$). Inter-operator reproducibility (Table 1) was 0.3 m/s in apnea (CV=12.7%) and 0.2 m/s in normal breathing (CV: 10.6%). The average

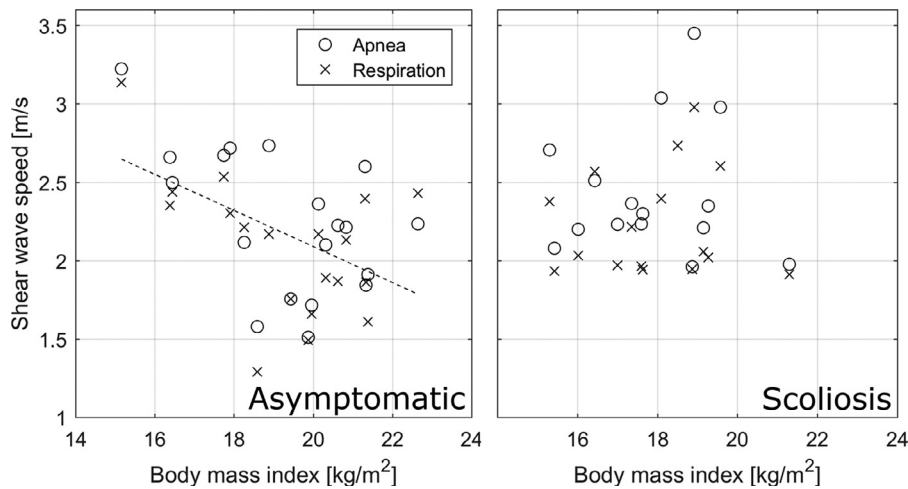


Fig. 2. Relationship between shear-wave speed measurement and body mass index. Correlations were significant in healthy individuals during apnea ($p=0.02$, Spearman $\rho = -0.53$) and normal respiration ($p=0.04$, Spearman $\rho = -0.48$). No correlation was observed in participants with scoliosis.

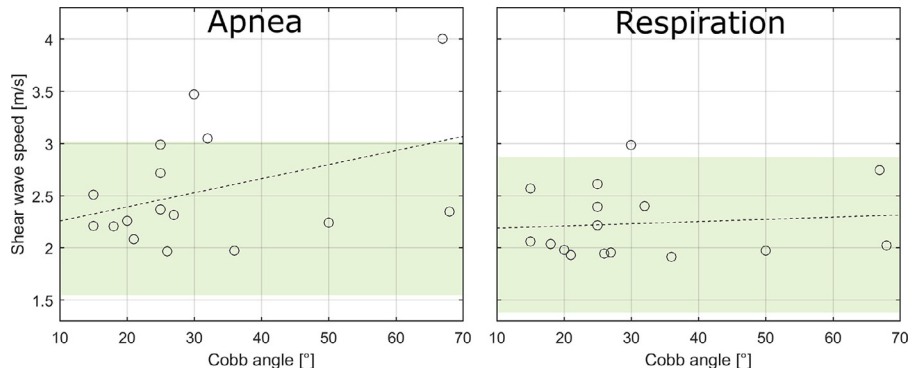


Fig. 3. Relationship between Cobb angle and shear-wave speed in participants with scoliosis during apnea and normal respiration. The relationships were not significant ($p = 0.3$ and 0.9 , respectively). The *horizontal shaded areas* represent the 5th and 95th quartiles of the healthy population; in other words, 90% of the healthy population was within the shaded area.

inter-operator ICC was 0.77 in apnea and 0.83 in normal breathing.

Scoliosis group

The average SWS in apnea was 2.5 ± 0.6 m/s, and it was significantly lower in normal breathing (2.2 ± 0.3 m/s, $p < 0.01$). There was no significant correlation with height, weight or BMI. A tendency was observed for SWE in apnea to increase with Cobb angle, although this relationship was not significant ($p = 0.3$; Fig. 3). No tendency was observed with measurement during normal respiration ($p = 0.9$).

Inter-operator reproducibility was 0.3 m/s in apnea (CV = 10.8%) and 0.2 m/s in normal breathing (CV = 9%). The average inter-operator ICC was 0.81 in apnea and 0.85 in normal breathing.

Group comparison

As shown in Figure 4, there was no significant difference between groups in either apnea or normal breathing ($p > 0.05$). However, no participant with AIS presented an SWS lower than 1.9 m/s, either in apnea or in normal respiration, whereas eight participants in the healthy group (42%) were below this threshold during normal respiration (six during apnea).

Bland–Altman plots for both groups in breathing and apnea are represented in Figure 5. They show good agreement between operators, and no outliers. Better reliability can be noticed for measurement in normal breathing than in apnea.

DISCUSSION

The present study shows that biomechanical assessment of the ICMs by shear-wave elastography is feasible and reliable, in both healthy individuals and those with scoliosis. The images obtained provide two types of

information: an echographic image allowing access to static structural characteristics and dynamic behavior of the ribs and inter-costal membranes and an elastographic clip reflecting the intrinsic stiffness of the muscle. In recent years, the contribution of this new imaging method has been highlighted for biomechanical evaluation of the musculoskeletal system (Hardy et al. 2017; Vola et al. 2018). Recent studies have been able to clarify the biomechanical behavior of the intervertebral disc in adolescent idiopathic scoliosis (Vergari et al. 2016; Langlais et al. 2018).

This imaging technique could allow a refinement of the current knowledge of respiratory involvement secondary to scoliosis (Ito et al. 2012). It is conventionally accepted that in severe cases of thoracic scoliosis, a

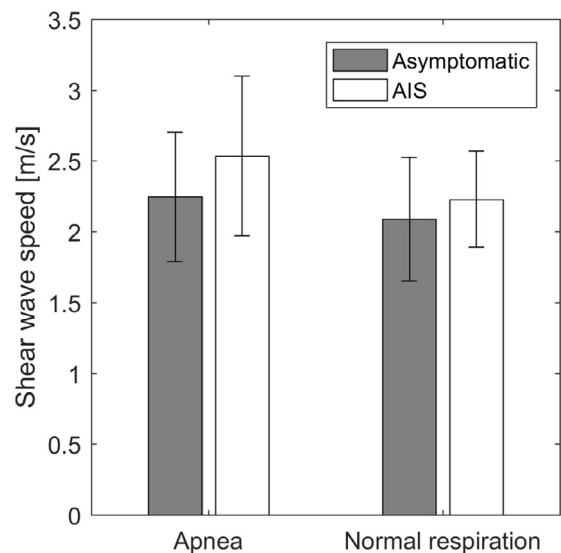


Fig. 4. Shear-wave speed differences between participants with and without adolescent idiopathic scoliosis during apnea and normal respiration.

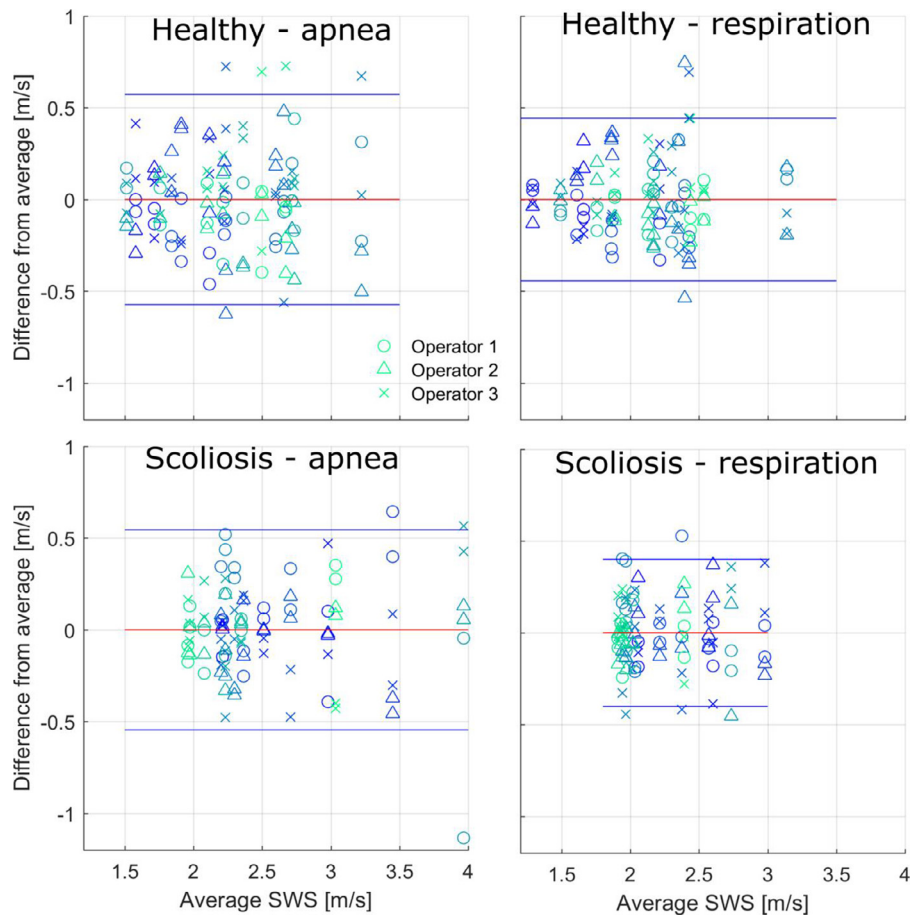


Fig. 5. Bland–Altman plots representing the limits of agreement of shear-wave speed measurements. *Horizontal lines* represent 95% confidence intervals.

restrictive syndrome can develop as a result of spinal penetration into the rib cage on the concave side. Asymmetry of pulmonary perfusion on the concave side has also been reported (Redding et al. 2008). However, respiratory involvement in this pathology is more complex, with an increase in the inspiratory pressure of the chest wall and obstructive phenomena that can occur (McPhail et al. 2015).

It has recently been shown that inspiratory muscle dysfunction can be observed in mild scoliosis before the diagnosis of restrictive syndrome. Mohammadi et al. (2014) have observed a decrease in strength for fatigue exercise in individuals with scoliosis, and shown a decrease of surface electromyographic activity of the ICMs on the concave side. The ICMs therefore seem to be involved in the respiratory dysfunction in these individuals.

The relatively long duration of the examination required for this first validation step (about 10 min) can easily be shortened to a few min by an operator in current practice. The inter-operator reproducibility of the measurements in this study was 0.2 m/s (10.6% coefficient of variation). This is similar to the uncertainty

obtained *in vivo* with other musculoskeletal tissues, such as muscles of the lower and upper limbs (between 4% and 20% CV; Lacourpaille et al. 2012; Dubois et al. 2015), the multifidus (1.3–4.3 m/s, 11%–19% CV;) and the intervertebral disc (0.25 m/s, 9% CV; Vergari et al. 2016). More recently, several studies have shown the value of elastography in diaphragm assessment (Chino et al. 2018). Some biomechanical studies have focused on sternocostal movement (Beyer et al. 2016) or on the effect of ICM contraction on rib motion (Zhang et al. 2018). To our knowledge, this is the first work on ICM elastography.

No significant difference was observed between participants with and without scoliosis. This could be explained by the small size of our cohort and the diversity in the severity of scoliosis. Nevertheless, participants in the AIS group showed a tendency toward higher SWS than in the healthy group, both in apnea and during normal respiration. Moreover, no participant with AIS had an SWS lower than 1.9 m/s, whereas 42% of those without did.

For this feasibility study, measurements were performed on participants' right side. It is possible that

more severe alterations could have been measured on the left side—that is, the concave side, with AIS being mainly thoracic right. However, in this preliminary study the aim was to compare individuals with and without AIS, not to assess the potential ICM asymmetry in these individuals; that will be the object of further studies.

Some limitations to this work may be noted. This examination uses ultrasound, which is operator dependent—hence the need to establish inter-operator reproducibility—and it requires a learning curve. The three operators had 2 y, 6 mo and 2 mo experience of ultrasound measurements, respectively. A training period was necessary to obtain reliable measurements, as shown by preliminary tests not included in this study. The most important points are learning to apply the lowest pressure possible with the probe, avoiding any trembling of the probe by finding a suitable and comfortable position and finding the correct anatomic landmarks in the image to maintain a repeatable probe position and orientation. The second main limitation is that the cohorts could be too small to prove a significant difference. A *post hoc* analysis based on the current preliminary data shows that 43 participants in each group would be needed to show a statistical difference in measurement during apnea ($\alpha = 0.05$, $1 - \beta = 0.8$). Although measurement during normal breathing was more reliable than during apnea, the latter seems to accentuate the difference between groups.

However, it was difficult to standardize rib-cage volume in apnea for the different operators, which could explain the better reproducibility in normal breathing. Participants could fill their lungs to a different degree for each measurement, stretching or contracting the intercostal membrane and therefore altering its mechanical properties. Moreover, measurement during normal breathing was more comfortable for the participants; further work should concentrate on measurement during breathing, as it is easier to perform and produces more reliable results. Differences in reproducibility between breathing conditions were expected because muscle activation and stretch have already been shown to significantly affect shear-wave elastography. However, in the case of the intercostal muscles it was difficult to hypothesize *a priori* whether breathing or apnea would be more reproducible. Hence, both conditions were tested. Furthermore, several parameters may alter ICM activity and stiffness that are not under the individual's voluntary control. However, these confounding factors were taken into account when repeating measurements in the reproducibility study.

On the other hand, if the current results on measurements during normal breathing were to be confirmed on a larger cohort, the actual difference between individuals with and without AIS might be too small to be clinically useful. The difference between groups (0.3 m/s in apnea

and 0.1 m/s during respiration) was similar to the measurement reproducibility (0.1–0.2 m/s), and therefore such a small deviation from the normal value might be difficult to detect. Other parameters should be further investigated, such as the asymmetry between the convex and concave sides or the variation of SWS throughout the respiratory cycle. Still, a small but significant alteration of the ICMs of individuals with AIS could open the way to new research questions on respiratory impairment due to scoliosis.

In this work it was possible, after the implementation of a controlled measurement protocol, to demonstrate that intercostal ultrasound elastography is reliable, especially during normal breathing. This paves the way for further studies of the functional consequences on respiratory-muscle adaptation of chest-wall deformity or any pathologic phenomenon affecting inspiratory pressure.

CONCLUSION

This study describes a reliable and reproducible imaging technique to evaluate the biomechanical behavior of the intercostal muscles in individuals with and without AIS. This opens the way to further studies that may lead to a better understanding of respiratory failure in AIS.

Conflict of interest disclosure—No funds were received in support of this work. No benefits in any forms have been or will be received from a commercial party related directly or indirectly to the subject of this manuscript.

REFERENCES

- Beyer B, Van Sint Jan S, Chèze L, Sholukha V, Feipel V. Relationship between costovertebral joint kinematics and lung volume in supine humans. *Respir Physiol Neurobiol* 2016;232:57–65.
- Blanco R, Parras T, McDonnell JG, Prats-Galino A. Serratus plane block: A novel ultrasound-guided thoracic wall nerve block. *Anaesthesia* 2016;68:1107–1113.
- Bland JM, Altman DG. Statistical methods for assessing agreement between two methods of clinical measurement. *Lancet* 1986;1:307–310.
- Bouloussa H, Pietton R, Vergari C, Haen TX, Skalli W, Vialle R. Biplanar stereoradiography predicts pulmonary function tests in adolescent idiopathic scoliosis: A cross-sectional study. *Eur Spine J* 2019;28:1962–1969.
- Chang K-V, Wu W-T, Huang K-C, Jan WH, Han D-S. Limb muscle quality and quantity in elderly adults with dynapenia but not sarcopenia: An ultrasound imaging study. *Exp Gerontol* 2018;108:54–61.
- Chang K-V, Yang K-C, Wu W-T, Huang K-C, Han D-S. Association between metabolic syndrome and limb muscle quantity and quality in older adults: A pilot ultrasound study. *Diabetes Metab Syndr Obes* 2019;12:1821–1830.
- Chino K, Ohya T, Katayama K, Suzuki Y. Diaphragmatic shear modulus at various submaximal inspiratory mouth pressure levels. *Respir Physiol Neurobiol* 2018;252–253:52–57.
- Dreimann M, Hoffmann M, Kossow K, Hitzl W, Meier O, Koller H. Scoliosis and chest cage deformity measures predicting impairments in pulmonary function: A cross-sectional study of 492 patients with scoliosis to improve the early identification of patients at risk. *Spine (Phila Pa 1976)* 2014;39:2024–2033.

- Dubois G, Kheireddine W, Vergari C, Bonneau D, Thoreux P, Rouch P, Tanter M, Gennisson J-L, Skalli W. Reliable protocol for shear wave elastography of lower limb muscles at rest and during passive stretching. *Ultrasound Med Biol* 2015;41:2284–2291.
- Dubousset J, Wicart P, Pomeroy V, Barois A, Estournet B. Spinal penetration index: New three-dimensional quantified reference for lordo-scoliosis and other spinal deformities. *J Orthop Sci* 2003;8:41–49.
- Erkula G, Sponseller PD, Kiter AE. Rib deformity in scoliosis. *Eur Spine J* 2003;12:281–287.
- Gennisson JL, Deffieux T, Fink M, Tanter M. Ultrasound elastography: Principles and techniques. *Diagn Interv Imaging* 2013;94:487–495.
- Hardy A, Rodaix C, Vergari C, Vialle R. Normal range of patellar tendon elasticity using the shearwave elastography technique: An in vivo study in normal volunteers. *Surg Technol Int* 2017;31:227–230.
- Ito K, Kawakami N, Miyasaka K, Tsuji T, Ohara T, Nohara A. Scoliosis associated with airflow obstruction due to endothoracic vertebral hump. *Spine (Phila Pa 1976)* 2012;37:2094–2098.
- Lacourpaille L, Hug F, Bouillard K, Hogrel J-Y, Nordez A. Supersonic shear imaging provides a reliable measurement of resting muscle shear elastic modulus. *Physiol Meas* 2012;33:N19–N28.
- Langlais T, Vergari C, Pietton R, Dubousset J, Skalli W, Vialle R. Shear wave elastography can evaluate annulus fibrosus alteration in adolescent scoliosis. *Eur Radiol* 2018;28:2830–2837.
- Martínez-Llorens J, Ramírez M, Colomina MJ, Bagó J, Molina A, Cáceres E, Gea J. Muscle dysfunction and exercise limitation in adolescent idiopathic scoliosis. *Eur Respir J* 2010;36:393–400.
- McPhail GL, Ehsan Z, Howells SA, Boesch RP, Fenchel MC, Szczesniak R, Jain V, Agabegi S, Sturm P, Wall E, Redding GJ. Obstructive lung disease in children with idiopathic scoliosis. *J Pediatr* 2015;166:1018–1021.
- Mohammadi P, Akbari M, Sarrafzadeh J, Moradi Z. Comparison of respiratory muscles activity and exercise capacity in patients with idiopathic scoliosis and healthy individuals. *Physiother Theory Pract* 2014;30:552–556.
- Pehrsson K, Danielsson A, Nachemson A. Pulmonary function in adolescent idiopathic scoliosis: A 25 year follow up after surgery or start of brace treatment. *Thorax* 2001;56:388–393.
- Redding G, Song K, Inscore S, Effmann E, Campbell R. Lung function asymmetry in children with congenital and infantile scoliosis. *Spine J* 2008;8:639–644.
- Rouvière O, Melodelima C, Dinh AH, Bratan F, Pagnoux G, Sanzalone T, Crouzet S, Colombel M, Mège-Lechevallier F, Souchon R. Stiffness of benign and malignant prostate tissue measured by shear-wave elastography: A preliminary study. *Eur Radiol* 2017;27:1858–1866.
- Tanter M, Bercoff J, Athanasiou A, Deffieux T, Gennisson J-L, Montaldo G, Muller M, Tardivon A, Fink M. Quantitative assessment of breast lesion viscoelasticity: Initial clinical results using super-sonic shear imaging. *Ultrasound Med Biol* 2008;34:1373–1386.
- Tsiligiannis T, Grivas T. Pulmonary function in children with idiopathic scoliosis. *Scoliosis* 2012;7:7.
- Vergari C, Dubois G, Vialle R, Gennisson J-L, Tanter M, Dubousset J, Rouch P, Skalli W. Lumbar annulus fibrosus biomechanical characterization in healthy children by ultrasound shear wave elastography. *Eur Radiol* 2016;26:1213–1217.
- Vola EA, Albano M, Di Luise C, Servodidio V, Sansone M, Russo S, Corrado B, Servodio Iammarrone C, Caprio MG, Vallone G. Use of ultrasound shear wave to measure muscle stiffness in children with cerebral palsy. *J Ultrasound* 2018;21:241–247.
- Yoon HM, Kim SY, Kim KM, Oh SH, Ko G-Y, Park Y, Lee JS, Jung AY, Cho YA. Liver stiffness measured by shear-wave elastography for evaluating intrahepatic portal hypertension in children. *J Pediatr Gastroenterol Nutr* 2017;64:892–897.
- Zhang G, Chen X, Ohgi J, Jiang F, Sugiura S, Hisada T. Effect of intercostal muscle contraction on rib motion in humans studied by finite element analysis. *J Appl Physiol (1985)* 2018;125:1165–1170.