



**HAL**  
open science

## **Antenatal finding of 16q24.1 duplication including FOXF1, revealing an autosomal dominant familial pathology with congenital short bowel, malrotation and renal abnormalities**

Alineo Lavillaureix, Gauthier Foulon, Erika Launay, Marc-Antoine Belaud-Rotureau, Ronan Thibault, Cécile Lambe, Dominique Aussel, Laurent Pasquier, Sylvie Odent, Alexis Arnaud, et al.

### ► **To cite this version:**

Alineo Lavillaureix, Gauthier Foulon, Erika Launay, Marc-Antoine Belaud-Rotureau, Ronan Thibault, et al.. Antenatal finding of 16q24.1 duplication including FOXF1, revealing an autosomal dominant familial pathology with congenital short bowel, malrotation and renal abnormalities. *Clinics and Research in Hepatology and Gastroenterology*, 2021, 45 (5), pp.101562. 10.1016/j.clinre.2020.10.007 . hal-03030364

**HAL Id: hal-03030364**

**<https://hal.science/hal-03030364>**

Submitted on 18 Dec 2020

**HAL** is a multi-disciplinary open access archive for the deposit and dissemination of scientific research documents, whether they are published or not. The documents may come from teaching and research institutions in France or abroad, or from public or private research centers.

L'archive ouverte pluridisciplinaire **HAL**, est destinée au dépôt et à la diffusion de documents scientifiques de niveau recherche, publiés ou non, émanant des établissements d'enseignement et de recherche français ou étrangers, des laboratoires publics ou privés.

## Title page:

### Title:

Antenatal finding of 16q24.1 duplication including *FOXF1*, revealing an autosomal dominant familial pathology with congenital short bowel, malrotation and renal abnormalities

### Short title

16q24.1 duplication and congenital short bowel syndrome

### Authors

Alinoë **LAVILLAUREIX** (1,2), Gauthier **FOULON** (3) Erika **LAUNAY** (4), Marc-Antoine **BELAUD-ROTUREAU** (4,5), Ronan **THIBAUT** (6), Cécile **LAMBE** (7), Dominique **AUSSEL** (8), Laurent **PASQUIER** (1), Sylvie **ODENT** (1,2), Alexis **ARNAUD** (9), Edouard **HABONIMANA** (9), Alain **DABADIE** (10), Sylvie **JAILLARD** (4,5)

1 CHU Rennes, Service de Génétique Clinique, Centre de Référence Maladies Rares CLAD-Ouest, ERN ITHACA, Hôpital Sud, Rennes, France;

2 Univ Rennes, CNRS, IGDR, UMR 6290, F-35000 Rennes, France

3 CHU Rennes, Pédiatrie - Maladies rares digestives (MaRD<sub>i</sub>), Hôpital Sud, Rennes, F-35000 Rennes, France;

4 CHU Rennes, Service de Cytogénétique et Biologie Cellulaire, F-35033 Rennes, France

5 Univ Rennes, CHU Rennes, INSERM, EHESP, IRSET (Institut de recherche en santé, environnement et travail) – UMR\_S 1085, F-35000 Rennes, France

6 Unité de Nutrition, Maladies rares digestives (MaRD<sub>i</sub>), CHU Rennes, INRAE, INSERM, Univ Rennes, Nutrition Metabolisms and Cancer, NuMeCan, Rennes, France

1  
2  
3  
4  
5  
6  
7  
8  
9  
10  
11  
12  
13  
14  
15  
16  
17  
18  
19  
20  
21  
22  
23  
24  
25  
26  
27  
28  
29  
30  
31  
32  
33  
34  
35  
36  
37  
38  
39  
40  
41  
42  
43  
44  
45  
46  
47  
48  
49  
50  
51  
52  
53  
54  
55  
56  
57  
58  
59  
60  
61  
62  
63  
64  
65

7 Hopital Necker-Enfants Malades, Service de gastro-entérologie, Paris, France

8 Diagnostic anténatal, Clinique La Sagesse, Rennes, France

9 CHU Rennes, Service de chirurgie pédiatrique, Maladies rares digestives (MaRD),

Hôpital Sud, Rennes, F-35000 Rennes, France

10 CHU Rennes, INRAe, INSERM, Univ Rennes, Institut NUMECAN (Nutrition

Metabolism and Cancer), Pédiatrie - Maladies rares digestives (MaRD), Hôpital Sud,

Rennes, F-35000 Rennes, France

Corresponding author :

**Dr Alinoë Lavillaureix**

**alinoe.lavillaureix@chu-rennes.fr**

**Service de génétique clinique**

**CHU de Rennes - Hôpital Sud**

**16 Boulevard de Bulgarie**

**35203 RENNES CEDEX 2**

**FRANCE**

**Phone : +33 (0)2 99 26 67 44 / +33 660462256**

**Fax : +33 (0)2 99 26 67 45**

ACKNOWLEDGEMENTS

The authors are grateful to the members of the family who participated in this study. Clinical data and samples were obtained with informed consent of the patients or their parents (legal representatives of minor patients) according to the Declaration of Helsinki and the national legal regulations.

Funding

1 This research did not receive any specific grant from funding agencies in the  
2 public, commercial, or not-for-profit sectors.  
3

4  
5 Disclosure of interest:  
6

7  
8 The authors declare that they have no competing interest.  
9

10  
11  
12  
13  
14 Authorship  
15

16  
17 Conception and design of study: AL, EL. Acquisition of data or analysis and  
18 interpretation of data: AL, GF, EL, MB, RT, CL, DA, LP, SO, AA, EH, AD, SJ  
19

20  
21 Drafting of manuscript: AL, AD, SJ. Critical revision and final approval: AL,  
22 GF, EL, MB, RT, CL, DA, LP, SO, AA, EH, AD, SJ  
23  
24  
25  
26  
27

28 Data Availability Statement :  
29

30  
31 The 16q24.1 duplication and the associated phenotype have been submitted to the  
32 DECIPHER database at <https://decipher.sanger.ac.uk/>, (ID LDC367088). Further  
33 data supporting the findings of this study are available from the corresponding  
34 author upon reasonable request.  
35  
36  
37  
38  
39  
40  
41  
42  
43  
44  
45  
46  
47  
48  
49  
50  
51  
52  
53  
54  
55  
56  
57  
58  
59  
60  
61  
62  
63  
64  
65

**Manuscript:**

**Keywords:**

FOXF1; 16q24.1 duplication; Malrotation; Short Bowel Syndrome; Renal dysplasia; Renal  
Insufficiency;

Accepted manuscript

1  
2  
3  
4  
5  
6  
7  
8  
9  
10  
11  
12  
13  
14  
15  
16  
17  
18  
19  
20  
21  
22  
23  
24  
25  
26  
27  
28  
29  
30  
31  
32  
33  
34  
35  
36  
37  
38  
39  
40  
41  
42  
43  
44  
45  
46  
47  
48  
49  
50  
51  
52  
53  
54  
55  
56  
57  
58  
59  
60  
61  
62  
63  
64  
65

1 Patients with congenital short-bowel syndrome (CSBS) are born with a substantial shortening  
2 of the small intestine, and malrotation of the small bowel is always present. Patients with  
3  
4 CSBS develop intestinal failure and malabsorption, requiring long term home parenteral  
5  
6 nutrition (PN). CSBS was first described by Hamilton *et al* and it is thought to have a genetic  
7  
8 cause[1]. Mutations in *CLMP* and *FLNA* cause recessive and X-linked forms of CSBS,  
9  
10 respectively[2]. We describe the antenatal finding of a 16q24.1 duplication including *FOXF1*,  
11  
12 revealing an autosomal dominant familial pathology with CSBS, malrotation and renal  
13  
14 abnormalities.  
15  
16  
17  
18  
19

20 Family tree is described in figure 1. The proband (III-2) is the second male child of a non-  
21  
22 consanguineous couple. He was antenatally diagnosed with 16q24.1 duplication and has  
23  
24 intestinal malrotation, CSBS, unilateral kidney duplicity with cysts.  
25  
26  
27

28 His mother (II-2) presented with volvulus at three weeks of age, and CSBS (65cm) with a  
29  
30 complete intestinal malrotation diagnosed during the laparotomy. She had fifteen months of  
31  
32 PN. She also had kidney abnormalities, with unilateral renal duplication, kidney cysts, several  
33  
34 episodes of pyelonephritis and renal lithiasis in childhood and adulthood. During the  
35  
36 pregnancy, antenatal ultrasound examinations in the second trimester showed high suspicion  
37  
38 of intestinal malrotation and kidney duplication. The possibility of an autosomal dominant  
39  
40 pathology inherited from the mother (II-2) was explained to the parents, who accepted an  
41  
42 amniocentesis. Array-CGH analysis performed on DNA obtained from amniotic liquid  
43  
44 revealed heterozygous 16q24.1 duplication (768 kb) including *FOXF1*. The variant  
45  
46 nomenclature, according to ISCN 2016 [3], was 46,XY.arr[GRCh37]  
47  
48 16q24.1(86220144\_86988149)x3. This duplication, considered pathogenic, was inherited  
49  
50  
51 from the mother.  
52  
53  
54  
55  
56  
57  
58  
59  
60  
61  
62  
63  
64  
65

1 The child was born at 39 weeks' gestation with normal birth parameters: weight 3075g (25th  
2 percentile), length 50cm (52th p), head circumference 35,3cm (66th p). The meconium passed  
3  
4 within 24 hours after birth. He was exclusively breastfed. Abdominal ultrasonography at day  
5  
6 five suspected an intestinal malrotation as mesenteric artery was on the right of mesenteric  
7  
8 vein without any sign of volvulus, and found left kidney nephromegaly with pyelic  
9  
10 duplication and multiple bilateral cysts. CSBS was suspected because of diarrhea, familial  
11  
12 history and genetic findings. At two months old, height was 57cm, weight 4kg, and  
13  
14 laparotomy confirmed incomplete 180° rotation and CSBS with normal ileocecal valve. A  
15  
16 Ladd band was resected. Repositioning of the intestine and mesentery, and an appendectomy  
17  
18 were performed. Small bowel length (SBL) was 85 cm, 41% of the mean estimated SBL for  
19  
20 height and age, as a length superior to 165cm was expected (mean estimated SBL: 207 cm;  
21  
22 95% CI: [165 – 250])[4]. Prolonged PN was provided via central venous catheter. At two  
23  
24 years old, height and weight development were normal with partial home PN maintained.  
25  
26  
27  
28  
29  
30  
31  
32  
33  
34  
35  
36  
37  
38  
39  
40  
41  
42  
43  
44  
45  
46  
47  
48  
49  
50  
51  
52  
53  
54  
55  
56  
57  
58  
59  
60  
61  
62  
63  
64  
65

His older brother (III-1) has no digestive symptoms and was not tested. A maternal uncle (II-3) without digestive or renal symptoms was found to be negative for the duplication. The younger brother III-3 was tested after birth, he doesn't carry the familial duplication, he has no digestive symptoms at six months old. The maternal uncle (II-4) had diarrhea and malabsorption with long term PN during his first year and chronic abdominal pain afterwards. He had a unilateral nephrectomy due to kidney damage associated with recurrent pyelonephritis and renal dysplasia. Unfortunately he could not be informed of the genetic disease to be tested.

The familial duplication was also confirmed in the symptomatic maternal grandmother (I-4); she was diagnosed with intestinal malrotation at age 62, during a pancreatitis surgery. She

1 probably had CSBS, as she suffered from chronic diarrhea with malabsorption and failure to  
2 thrive in infancy. She had multiple episodes of pyelonephritis and developed chronic  
3  
4 interstitial nephropathy by renal dysplasia, and had undergone a renal transplantation at the  
5  
6 age of 31. After the age of 50, she had recurrent episodes of acute pancreatitis, with six  
7  
8 hospitalisations and no etiology was found even though extensive tests were performed.  
9  
10

11  
12 The dorsal mesentery is important in generating the left–right asymmetry that allows rotation  
13  
14 of the midgut during embryological development to take place[5]. Point mutations and  
15  
16 genomic deletions of *FOXF1*, a key gene in the establishment of the dorsal mesentery, are  
17  
18 associated with intestinal malrotation and CSBS has been reported in one case[6]. These  
19  
20 patients have a severe developmental lung abnormality, alveolar capillary dysplasia with  
21  
22 misalignment of pulmonary veins (ACD/MPV) causing early death.  
23  
24  
25  
26  
27

28 16q24.1 duplications of different sizes encompassing *FOXF1* have been described in four  
29  
30 unrelated families[7] without pulmonary problems. Interestingly in one family, with  
31  
32 duplication similar in size and genomic location to the one we have identified, the daughter,  
33  
34 mother and maternal grandfather presented with malrotation; the daughter also had short  
35  
36 bowel. In the other families with larger duplications, the patients had developmental delay but  
37  
38 no significant gastrointestinal problems or malrotation are specified. A 1.5 Mb de novo  
39  
40 duplication on 16q24 involving *FOXF1* has been described more recently in one patient  
41  
42 presenting with intestinal malrotation, mild intellectual disability, short stature and pulmonary  
43  
44 artery stenosis[8].  
45  
46  
47  
48  
49  
50

51 Pathogenicity of genomic duplications is often not explained by changes in gene dosage, but  
52  
53 can be linked to the formation of new chromatin domains[9] with changes in the structure and  
54  
55 function of topologically associated domains (TADs). TADs are chromosomal regions with  
56  
57 an elevated frequency of internal chromatin interactions, such as interactions between genes  
58  
59  
60  
61  
62  
63  
64  
65



1 and their distal regulatory elements. For example, duplications within TADs can increase  
2 interactions between (duplicated) regulatory elements and their target genes, which can cause  
3  
4 changes in gene expression and consequently disease.  
5  
6

7 Reinterpretation of the familial history combined with the genetic findings during the  
8 pregnancy led to close surveillance of the proband after birth. It also allowed for the parents to  
9  
10 be informed of the increased risk of volvulus and CSBS in their child. Parenteral nutrition was  
11  
12 started before the laparoscopic CSBS confirmation, so it permitted early care and avoided  
13  
14 diagnostic delay of this rare condition. The mother also agreed to resume medical nutrition  
15  
16 follow-up, her digestive symptoms improved and she had no renal lithiasis since  
17  
18  
19  
20  
21  
22  
23  
24  
25  
26  
27  
28  
29  
30  
31  
32  
33  
34  
35  
36  
37  
38  
39  
40  
41  
42  
43  
44  
45  
46  
47  
48  
49  
50  
51  
52  
53  
54  
55  
56  
57  
58  
59  
60  
61  
62  
63  
64  
65

These findings allowed for appropriate genetic counseling to be provided to the family; as  
prior to the diagnosis during the second pregnancy, the parents were not aware of the 50%  
risk of recurrence of the 16q24.1 duplication and CSBS transmission. The parents did not ask  
for prenatal diagnosis for the third pregnancy, but the child (III-3) was tested shortly after  
birth, he doesn't carry the familial duplication and has no digestive symptoms.

Array-CGH could be recommended for all patients with CSBS, as the prevalence of this  
condition is unknown.

## References:



- [1] Hamilton JR, Reilly BJ, Morecki R. Short small intestine associated with malrotation: a newly described congenital cause of intestinal malabsorption. *Gastroenterology* 1969;56:124–36.
- [2] van der Werf CS, Halim D, Verheij JBG, Alves MM, Hofstra RMW. Congenital Short Bowel Syndrome: from clinical and genetic diagnosis to the molecular mechanisms involved in intestinal elongation. *Biochim Biophys Acta BBA - Mol Basis Dis* 2015;1852:2352–61. <https://doi.org/10.1016/j.bbadis.2015.08.007>.
- [3] International Standing Committee on Human Cytogenomic Nomenclature, McGowan-Jordan J, Simons A, Schmid M, editors. *ISCN: an international system for human cytogenomic nomenclature* (2016). Basel ; New York: Karger; 2016.
- [4] Struijs M-C, Diamond IR, de Silva N, Wales PW. Establishing norms for intestinal length in children. *J Pediatr Surg* 2009;44:933–8. <https://doi.org/10.1016/j.jpedsurg.2009.01.031>.
- [5] Martin V, Shaw-Smith C. Review of genetic factors in intestinal malrotation. *Pediatr Surg Int* 2010;26:769–81. <https://doi.org/10.1007/s00383-010-2622-5>.
- [6] Stankiewicz P, Sen P, Bhatt SS, Storer M, Xia Z, Bejjani BA, et al. Genomic and Genic Deletions of the FOX Gene Cluster on 16q24.1 and Inactivating Mutations of FOXF1 Cause Alveolar Capillary Dysplasia and Other Malformations. *Am J Hum Genet* 2009;84:780–91. <https://doi.org/10.1016/j.ajhg.2009.05.005>.
- [7] Dharmadhikari AV, Gambin T, Szafranski P, Cao W, Probst FJ, Jin W, et al. Molecular and clinical analyses of 16q24.1 duplications involving FOXF1 identify an evolutionarily unstable large minisatellite. *BMC Med Genet* 2014;15:128. <https://doi.org/10.1186/s12881-014-0128-z>.
- [8] Salehi Karlslätt K, Pettersson M, Jäntti N, Szafranski P, Wester T, Husberg B, et al. Rare copy number variants contribute pathogenic alleles in patients with intestinal malrotation. *Mol Genet Genomic Med* 2019;7:e549. <https://doi.org/10.1002/mgg3.549>.
- [9] Franke M, Ibrahim DM, Andrey G, Schwarzer W, Heinrich V, Schöpflin R, et al. Formation of new chromatin domains determines pathogenicity of genomic duplications. *Nature* 2016;538:265–9. <https://doi.org/10.1038/nature19800>.

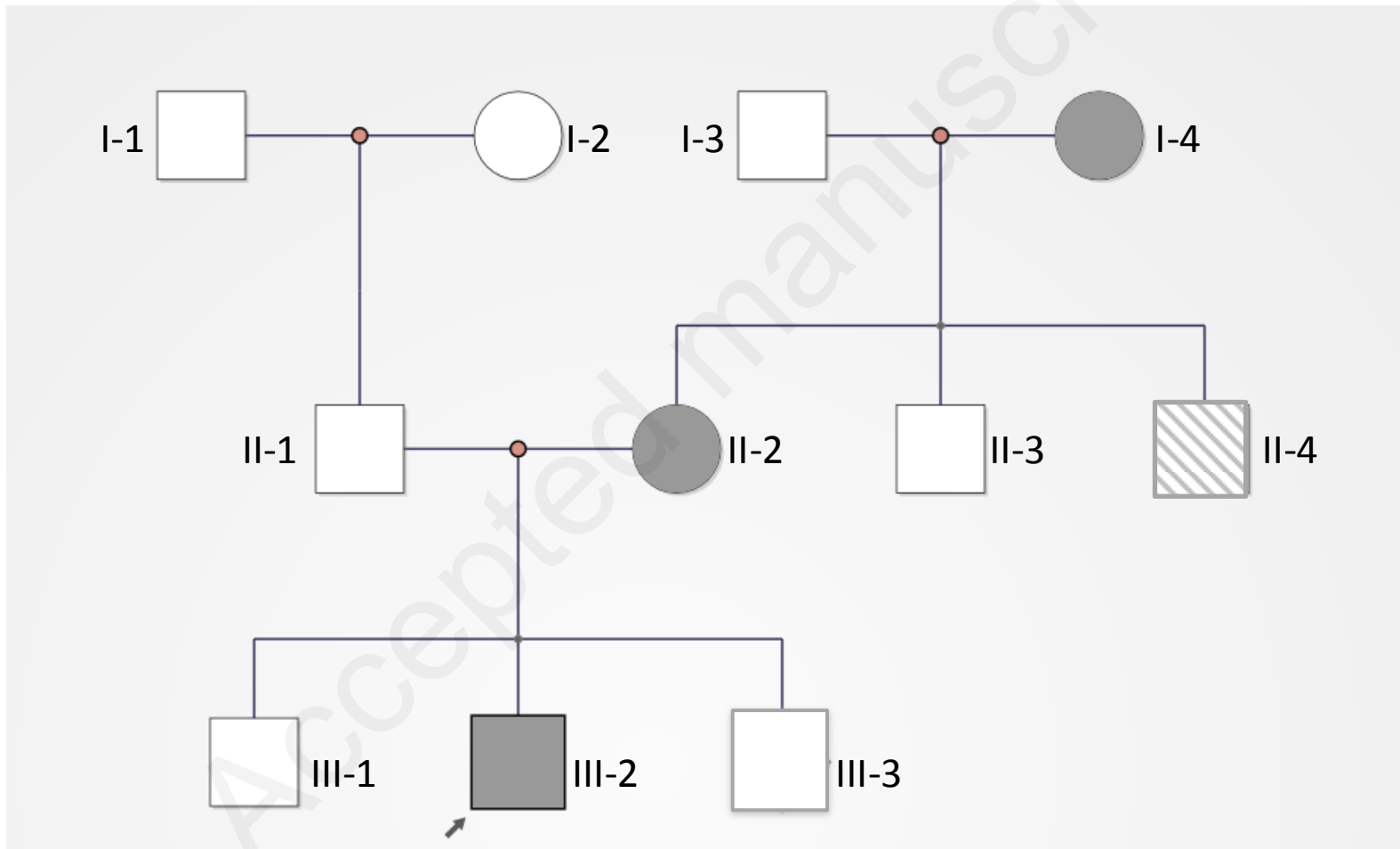
## Legend

### Figure 1: Family tree

Autosomal dominant familial pathology with congenital short bowel, malrotation and renal abnormalities, affected patients (I-4, II-2, III-2) with CSBS and 16q24.1 duplication. II-3 and III-3 are asymptomatic and tested negative for the duplication. II-4 had malabsorption with long term PN, he refused to be tested. III-1 has no digestive symptoms and was not tested.

Figure 1

-  Symptomatic patient with unknown genetic status
-  Symptomatic patients who have the 16q24.1 duplication



**Declaration of interests**

The authors declare that they have no known competing financial interests or personal relationships that could have appeared to influence the work reported in this paper.

The authors declare the following financial interests/personal relationships which may be considered as potential competing interests:

Accepted manuscript