



HAL
open science

Awake Craniotomy and Memory Induction Through Electrical Stimulation: Why Are Penfield's Findings Not Replicated in the Modern Era?

Jonathan Curot, Franck-Emmanuel Roux, Jean-Christophe Sol, Luc Valton,
Jérémie Pariente, Emmanuel J. Barbeau

► To cite this version:

Jonathan Curot, Franck-Emmanuel Roux, Jean-Christophe Sol, Luc Valton, Jérémie Pariente, et al.. Awake Craniotomy and Memory Induction Through Electrical Stimulation: Why Are Penfield's Findings Not Replicated in the Modern Era?. *Neurosurgery*, 2020, 87 (2), pp.E130-E137. <10.1093/neuros/nyz553>. <hal-03015327>

HAL Id: hal-03015327

<https://hal.science/hal-03015327v1>

Submitted on 7 Dec 2020

HAL is a multi-disciplinary open access archive for the deposit and dissemination of scientific research documents, whether they are published or not. The documents may come from teaching and research institutions in France or abroad, or from public or private research centers.

L'archive ouverte pluridisciplinaire **HAL**, est destinée au dépôt et à la diffusion de documents scientifiques de niveau recherche, publiés ou non, émanant des établissements d'enseignement et de recherche français ou étrangers, des laboratoires publics ou privés.



HAL Authorization

PRE-PRINT PUBLICATION

Awake craniotomy and memory induction through electrical stimulation: Why are Penfield's findings not replicated in the modern era?

Jonathan CUROT^{a,b,c} (MD, PhD), Franck-Emmanuel ROUX^{b,c,d} (MD, PhD), Jean-Christophe SOL^{d,f} (MD, PhD), Luc VALTON^{a,b,c} (MD), Jérémie PARIENTE^{e,f} (MD, PhD), Emmanuel J. BARBEAU^{b,c} (PhD)

Affiliations:

a - Toulouse University Hospital, Department of Neurophysiological Explorations, Toulouse, FR 31059, France

b - Centre de Recherche Cerveau et Cognition CerCo, CNRS, UMR5549, Toulouse, FR 31052, France

c - Centre de Recherche Cerveau et Cognition, Université de Toulouse, Université Paul Sabatier Toulouse, Toulouse, F-31330, France

d - Toulouse University Hospital, Department of Neurosurgery, Toulouse, FR 31059, France

e - Toulouse University Hospital, Department of Cognitive Neurology, Toulouse, FR 31059, France

f - INSERM, U1214, TONIC, Toulouse Mind and Brain Institute, FR 31024, France

Corresponding author:

Jonathan CUROT

CerCo CNRS UMR 5549, Université Toulouse III, CHU Purpan, Pavillon Baudot

BP 25202, 31052 Toulouse Cedex – France

Telephone: 33561775598

Corresponding author's e-mail:

jonathan.curot@cnrs.fr

Conflict of Interest: None.

Disclosure of Funding: None.

Running title: Modern awake craniotomy and memory induction

Key words: awake craniotomy, memory, electrical brain stimulation, reminiscences, epilepsy, déjà-vu.

Abstract

From the 1930s through the early 1960s, Wilder Penfield collected a large number of memories induced by electrical brain stimulation (EBS) during awake craniotomy. As a result, he was a major contributor to several neuroscientific and neuropsychological concepts of long-term memory. His 1963 paper, which recorded all the cases of memories he induced in his operating room, remains a substantial point of reference in neuroscience in 2019, although some of his interpretations are now debatable.

However, it is highly surprising that since Penfield's reports there has been no other surgical publication on memories induced during awake surgery. In this review, we explore this phenomenon and analyze some of the reasons that might explain it. We hypothesize that the main reasons for lack of subsequent reports are related to changes in operative procedures (i.e., use of anesthetics, time constraints, insufficient debriefings) and changes in EBS parameters, rather than to the sites that are stimulated, the pathology treated, or the tasks used. If reminiscences are still induced, they should be reported in detail to add valuable contributions to the understanding of long-term memory networks, especially memories that are difficult to reproduce in the laboratory, such as autobiographical memories.

Chronic direct electrical brain stimulation (EBS) is regularly used in the form of deep brain stimulation (DBS) for the treatment of Parkinson's disease¹ and is being actively developed for the treatment of psychiatric disorders,² epilepsy,³ and cluster headache.⁴ Its use is also being explored in neuroprosthetic applications for individuals who are blind or paralyzed.⁵ We also now live in an era when the use of EBS for the chronic modulation of memory is conceivable. Multiple recent findings indeed support the idea that EBS could potentially be used to improve human memory performance,⁶⁻⁹ increase hippocampal neurogenesis,¹⁰ or even slow down atrophy in Alzheimer's disease.¹¹

During the period from the 1930s to the early 1960s, Wilder Penfield and his colleagues became the first to induce experiential phenomena such as déjà-vu, but also the recollection of memories by EBS applied to the neocortex of patients during awake craniotomy.¹² They deeply influenced scientists' conceptions of long-term declarative memory.¹³ EBS induces a wide variety of memories, covering all aspects of declarative memory, although in different proportions (see Table 1 and online database DOI: [10.6084/m9.figshare.4733026](https://doi.org/10.6084/m9.figshare.4733026)). The "tape-recorder" hypothesis advocated by Penfield suggests that memory may be highly stable as time passes and it could be his most iconic contribution to the field of memory.¹² Although this concept is debatable nowadays, it is still a widely held belief.¹³

Table 1: *Examples of the main different types of reminiscences induced by EBS during awake craniotomy, SEEG and electrocorticography (subdural grids). More reminiscences are*

available on the web. We provide a permalink to an online database, which is a census of all reminiscences induced by EBS ever published (DOI: [10.6084/m9.figshare.4733026](https://doi.org/10.6084/m9.figshare.4733026)).

| Memory types | Examples in Penfield's reports ¹² | Examples obtained in reports after Penfield |
|---|---|---|
| Episodic memory (vivid unique events, detailed emotional content, highly contextualized in time and space) | Patient R.W. (Right superior temporal gyrus EBS, awake craniotomy). "My mother is telling my brother he has got his coat on backwards. I can just hear them." When asked if he remembered it, he said, "Oh yes, just before I came here." When asked if he thought these things were like dreams, he said, "No." " | Chapman et al. (1967). ³⁷ (Left amygdala EBS, SEEG). "He reported he was re-experiencing an epoch from his own past. [...] It concerned his entering a hospital in a small city where he had lived seven or eight years previously. [...] He stated that he could see the people and the places vividly and recall their names. The episode concerned entering the hospital and greeting a nurse. [...] The visual aspect dominated his spontaneous recall but other features such as sounds smells and emotions were said to be present. On re-stimulation on the sites the same experience was induced. [...] The interviewer asked for details and the patient replied that he would be able to furnish details if the stimulus was repeated again. When the stimulus began again, he directed his attention to the details, sought and was able to describe them. [...] The patient said that the hospital and his contacts with doctor and nurse were extremely important events in his life, but that the specific epoch re-experienced did not stand out as particularly meaningful. [...] He had completely forgotten the specific episode." |
| Personal semantics (autobiographical knowledge, without any sense of recollection or low contextualization) | Patient C.M. (Left middle temporal gyrus EBS, awake craniotomy). "She said, "I am having another one. I can't remember it. It seems like I was in my house." When asked where, she said "In the hallway, going towards my bedroom." " | Curot et al. (2017). ¹³ Patient CGT2 (Right perirhinal cortex EBS, SEEG). "As if I had lived something. I don't know why but it brought me back to work. [...] As if it was something I had lived earlier [...] the feeling of having already lived that at work. I saw myself in the hall." |
| Semantic memory (general knowledge about the world, culturally-shared) | Patient S. Be. (Right superior temporal gyrus EBS). "He observed, while the electrode was being held in place, "Again, 'Oh Marie, Oh Marie'." He explained that he had heard this before. "It is a theme song," he said, "on a radio program. The program is called the 'Life of Luigi' ". The patient then discussed the identity of the song with Dr. Sears and he ended by singing the well-known refrain, "Oh Marie, Oh Marie." All in the operating room recognized the song." | Morris et al. (1984). ⁵⁷ (Left superior temporal gyrus EBS, subdural grids). "At electrode C7, the patient recognized a familiar song he had not heard in many years. The singer was male with a British accent, and the verse went "Girl for making the morning brighter, girl for making the nighttime nicer". The patient could not remember the name of the song." |
| Familiarity (item recognition, devoid of a sense of recollection and devoid of context) | Patient A. Bra. (Right superior temporal gyrus EBS, awake craniotomy). "Yes, I have heard it before. A man's voice talking." | Bartolomei et al. (2004). ⁵⁸ Patient P3 (Left perirhinal cortex EBS, SEEG). "Patient P3 described the prow of a steamer on the sea associated with a transient feeling of familiarity." |

In the ensuing decades, induction of memories was replicated under conditions other than awake craniotomy - mostly by medial temporal lobe (MTL) intracranial EBS in patients with epilepsy¹³⁻¹⁶ but also by fornix EBS in non-epileptic patients.^{17,18} Regardless of the EBS

technique, these reminiscences became a valuable tool to explore long-term memory mechanisms.^{13,19,20} They should be considered as rare exploitable “snapshots” of the brief fleeting reinstatement of a past event.²¹

By suggesting that memory retrieval relies on the widespread synchronization of nodes beyond the MTL¹⁹, reminiscences induced by EBS also paved the way to the neuromodulation of these networks. In addition to many neuropsychological, electrophysiological and functional MRI memory experiments, EBS studies contributed to identify the rhinal cortex,^{6,7} the hippocampus,^{6,8,22} the amygdala,²³ the lateral temporal cortex,^{22,24} and the fornix,²⁵ as potential targets to modulate memory using chronic EBS. For example, Andres Lozano’s team unexpectedly induced personal semantic memories in an overweight patient following DBS targeting the hypothalamus.¹⁷ The electrodes were in fact positioned very close to the fornix, one of the major white tracts involved in declarative memory. Subsequently, the same team led a large prospective trial to test DBS of the fornix in patients with Alzheimer’s disease with the aim to limit memory impairment and even restore memory capacities.²⁵

However, memories induced by EBS are very rare phenomena. Overall, 0.19% of stimulations induced reminiscences in our most recent analysis of patients undergoing stereo-electroencephalography (SEEG),¹³ which demonstrates that unfortunately, the optimal combination of parameters required to induce and then improve memory remains unknown. Electrical parameters and electrode types vary across studies.²⁶ The best electrical parameters have rarely been compared in humans.⁸ Prospective trials that contrast the efficiency of a panel of EBS frequencies and intensities are needed.

Even the optimal brain structures that should be the target of EBS to improve memory are to a great extent unknown. In fact, stimulating the same structure can lead to contradictory results^{6,22} and, when effective, to only small improvement in cognitive scores.^{8,27} Nonetheless, we

previously demonstrated that the rhinal cortex was the main gateway to memory following EBS.¹³ In contrast, EBS of some other structures presumably involved in memory, such as the posterior cingulate cortex,^{13,28} never induce memory retrieval or can even impair memory recall during free recall memory tasks.²⁹ The choice of EBS locations would be all the more strategic since the EBS location influences the nature (e.g., episodic or semantic) of the memories that are recalled.¹³ Such an influence of the EBS location suggests that EBS can activate memory networks in a predictable manner.

In this context, studies reporting memories induced by EBS are a valuable basis for clinical trials aimed at modulating human memory networks to improve encoding or retrieval performance.²⁶ Therefore, it would appear that awake craniotomy, according to Penfield's seminal studies, should be able to make a specific contribution to this endeavor. By adding data to the pool of extra-operative EBS, awake craniotomy could help to identify the optimal location(s) and electrical parameters for neuromodulation, while empiricism is currently the rule.

Paradoxically however, reports of memories induced by EBS during awake craniotomy have completely stopped since Penfield. In an extensive review of the literature on EBS, we found no report of electrically induced memories during awake craniotomy after Penfield.¹³ We did find a description of a patient who reported dream-like experiences after EBS of the posterior cingulate cortex, but these experiences were not clearly related to memory.³⁰

It is particularly intriguing to note that Penfield's results have not been replicated, given that fundamentally, the goals and indications of awake craniotomy have not changed. Operating on awake patients is essential to delineate tumor resections, arteriovenous malformations, or seizure onset-zones in patients with drug-refractory epilepsy.^{31,32} Awake craniotomy is also

performed for functional mapping of motor and/or sensory functions,³² language,³³ visual functions,³⁴ and verbal or visuospatial memory.^{35,36}

Several possibilities can be considered to explain why no memory induced by EBS during awake craniotomy has been reported these past five decades.

1- **Changes in the indications for intra-operative mapping?** One could argue that nowadays most indications for awake craniotomy do not include epilepsy, as in Penfield's reports, but rather tumors. This could explain the lack of induced reminiscences, as some authors have argued that prior "sensitization" by seizure activity is necessary for the induction of memories by EBS (see Theodore Rasmussen's comment in the *Discussion* at the end of the 1966 paper by Chapman et al.³⁷). However, reminiscences following EBS sometimes occur in patients undergoing tumor resection (even in Penfield's series, e.g., Patient J.T.¹²). Recent reports of reminiscences induced by EBS (in settings other than awake craniotomy) are not limited to the epileptic population¹³ or to pathology with a direct impact on memory functions (e.g., obesity¹⁷). Glial tumors are also often associated with epilepsy and a significant proportion of patients who benefit from awake craniotomy for glioma are probably epileptic, although this is not always mentioned in available studies.

2- **An influence of the task and of baseline state of the brain at the moment of EBS?** One possibility could be that reminiscences are induced only when patients perform specific tasks and/or when EBS is applied during specific brain states. However, Penfield's patients performed no memory task during EBS sessions. In contrast, Ojemann's team, which used memory tasks (such as the presentation of words or visual items), to our knowledge never reported any recollection of memories induced by EBS.³⁵ More complex tasks involving higher demands on memory networks might be more efficient to trigger conscious retrieval,²⁰ for example answering questions related to specific periods of life.

3- **Insufficient patient interviewing?** Patients may not report what they experience if they are not specifically asked. Operating room conditions clearly do not favor the spontaneous verbalization of memories if the patient is not specifically questioned. Although the majority of patients do not experience major discomfort during current surgical procedures, which are well tolerated in the majority of cases,³⁸ it is nonetheless possible that Penfield was more committed to questioning patients because of his personal interest in these phenomena. The modern focus on efficiency could also be a factor. Penfield might have taken more time to talk to his patients during the surgical procedure, and in current practice operating time might be considered too limited (or too costly) to allow for the kind of interview that might elicit descriptions of EBS-induced reminiscences.

4- **A role of afterdischarges (ADs)?** The influence of ADs (transient EEG changes after EBS, corresponding to bursts of epileptiform activity) is a historical debate as some authors have posited that they are necessary for reminiscences to occur (inhibition of MTL resulting in the “liberation” of neocortical structures),¹⁶ while others have suggested that they may have an inhibitory effect that prevents the occurrence of reminiscence after EBS.¹⁵ Notwithstanding, it is difficult to interpret the effect of activation or inhibition of such a propagated and self-perpetuating epileptiform discharge. Moreover, most awake craniotomy procedures do not include concomitant electrocorticography to verify the occurrence of ADs. Early studies that reported EBS-induced reminiscences used stimulation parameters intense enough to induce an AD.¹² Penfield used to increase intensity to get ADs during awake craniotomy. However, besides the necessity to limit the risk of seizures during awake craniotomy,³⁹ in previous work, we demonstrated that nearly one-half of reminiscences were devoid of any AD visible on EEG.¹³ Therefore, ADs do not appear to be necessary for reminiscences.

5- **Subtle changes in the locations of EBS?** One might wonder if the reason is not a progressive transition over the past decades towards a more focused mapping of areas highly

eloquent for language. A combination of the improvement in preoperative functional MRI mapping and a better knowledge of neuropsychological outcomes after surgery would explain why less time is spent to stimulate areas in which resection does not usually lead to permanent language impairment (such as anterior and ventral temporal areas). However, Penfield obtained memories mostly by lateral temporal EBS. Furthermore, lateral temporal EBS during electrocorticography also induces reminiscences.⁴⁰ The targets of EBS during contemporary awake craniotomy are still primarily the same locations (Fig. 1). Therefore, the key is not in the location alone.

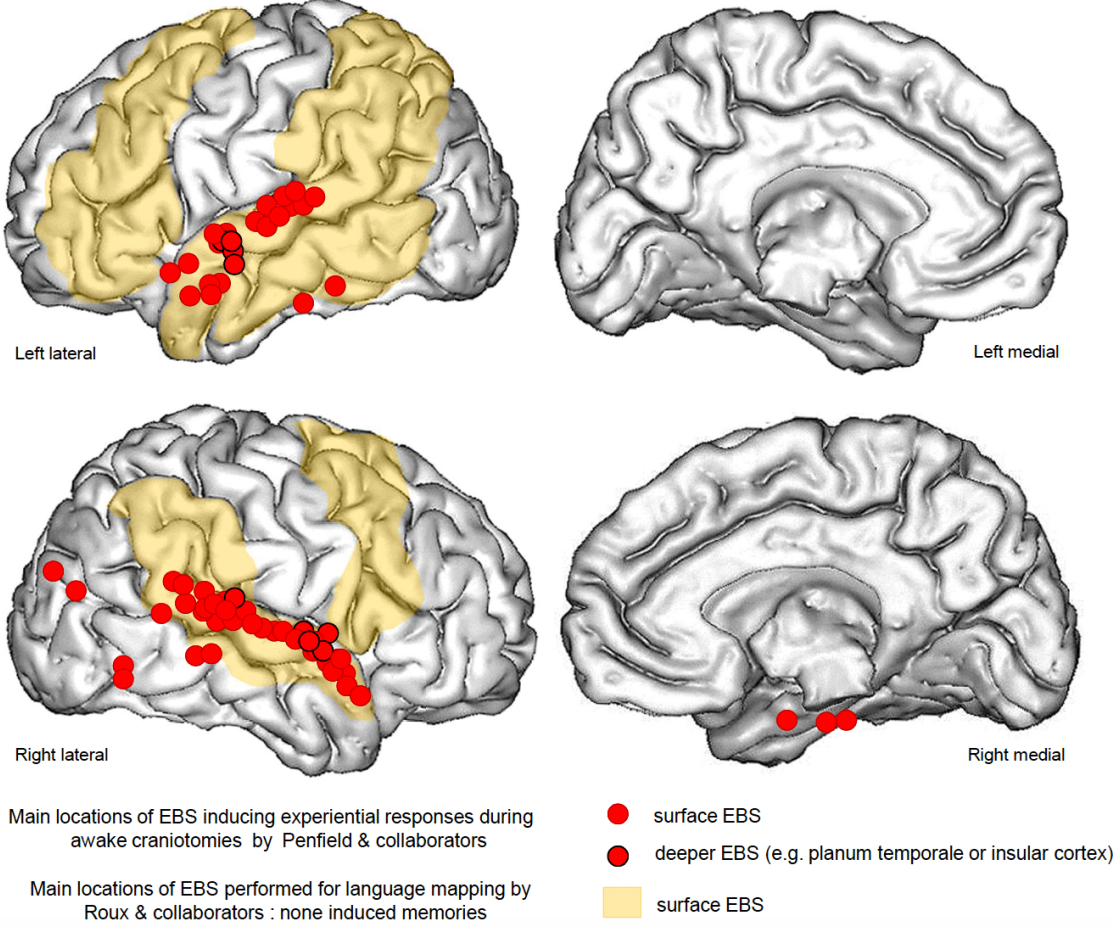


Fig. 1: Comparison of EBS locations that induced experiential responses (including memories) in Penfield’s era (red circles) and locations stimulated during awake craniotomy in the modern era (yellow areas). The red circles show the main locations at which Penfield

and his collaborators found that stimulation induced experiential responses during AC. The images represent results obtained in 40 patients (out of a pool of 1,132). This figure was created on the basis of Penfield's results.¹² The areas in yellow present the data from the Toulouse awake craniotomy database. However, no reminiscence was reported by any patient in the Toulouse cases. More details about the exact locations among a total of 2,574 stimulations that were performed for functional mapping during awake craniotomy in 90 patients are available in the 2015 study by Roux et al.³⁶

6- **Differences in electrical parameters?** There have been significant changes in the electrical parameters used for EBS (pulse type, pulse width, frequency of stimulation, intensity and duration) since Penfield's work. Variations in these parameters may influence the amount of current delivered by EBS, its extension, and its direction.⁴¹ Penfield used different types of EBS, bipolar and monopolar (a monopolar silver ball electrode for surface exploration and a multiple-contact needle electrode for depth stimulation), and he applied the stimulation for longer periods of time than nowadays.¹² The amount of current delivered is difficult to quantify, but it is likely that it was higher than the amount that would be delivered with intracranial electrodes or even by EBS during awake craniotomy in the present era. However, parameters limiting current spread (bipolar EBS, low intensity) and high-frequency EBS are in fact more likely to induce memories during SEEG^{13,26} (Fig. 2). One hypothesis is that a specific combination of electrical parameters for a specific location may be required to induce the recall of memories. The fact that the amount of current required to induce a clinical sign or an AD depends on the lobe stimulated⁴² and varies from point to point⁴³ supports this hypothesis. Electrical parameters, especially intensity, should be individualized at each location.⁴⁴ Overall, it is possible that modern parameters for EBS during awake craniotomy are inadequate to induce memory recall following neocortical EBS.

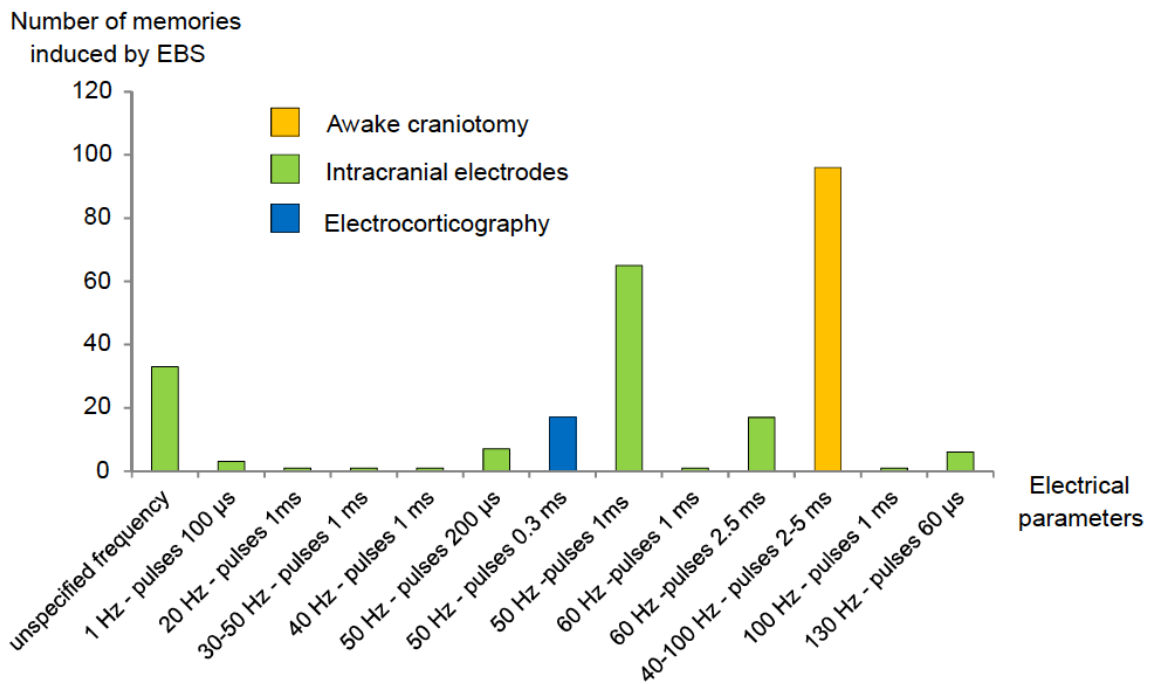


Fig. 2: Electrical parameters for all types of EBS that induce memories: results from a review of the literature and collection of all memories induced by EBS in a French SEEG database. Parameters limiting current spread (bipolar EBS, low intensity 0.5–2 mA) and high frequency (50 Hz) EBS are more likely to induce memories. All details (about parameters and references) are available in a previous publication.¹³ A majority of high frequency EBS was used (40–100 Hz, 67.8%) compared to lower frequency EBS (1-20 Hz, 4.8%). Wilder Penfield (who did not specify exact parameters for each reminiscence – neither charge density, amplitude nor frequency) used 40–100 Hz EBS (amplitude in the range 1-5V, square wave pulses of 2-5 msec, frequency of 40-100 cycles per second, 1 to 5 volts, provided by a square wave generator, resistance of the surface electrode of about 10,000-20,000 ohms and stimulus current varied between 50 and 500 micro-amperes) and could deliver monopolar cortical EBS. Monopolar cortical EBS produces higher current densities and stimulates a larger amount of tissue when compared to bipolar EBS. Nowadays, the most widely applied technique for mapping motor and cognitive functions during awake craniotomy uses the

*following parameters: 50 or 60 Hz bipolar EBS, with a current amplitude progressively increased by 1 mA (final amplitude 1.5–12 mA) and 3–4 seconds duration.*³³

7- **Changes in operating procedures?** Penfield only used local anesthesia for the beginning of the surgical procedure and sedation only after testing.⁴⁵ Nowadays, the most frequently reported anesthetic techniques are the asleep-awake-asleep technique and monitored anesthesia care.⁴⁶ Sedation with short-acting drugs such as propofol (used since the 1990s) and remifentanyl or midazolam,⁴⁶ allow the anesthesiologist to closely control the patient's level of analgesia and sedation, whereas patients undergoing postoperative SEEG and electrocorticography are free of anesthetic agents during the immediate postoperative period and during postoperative monitoring. Propofol and midazolam are known to have amnesic effects.⁴⁷ Although they are short-acting drugs, remnant effects cannot be prevented during the awake period. Since the advent of propofol, it has been reported that 8% to 37% of patients have no recollection of being awake and tested despite being awake and cooperative during the awake craniotomy procedure.³⁸ Therefore, we cannot exclude the possibility that conscious sedation with propofol may transiently alter the activation of memory-related structures (such as the hippocampus) and prevent the recall of memories after EBS.

8- **The need for intra-procedure intracranial EEG recordings?** Anesthetic agents could also influence brain state, including the frequency and the phase of oscillations, at the moment stimulation is applied. This parameter is difficult to control and assess, but certainly important. Spectral composition and the dynamics of brain oscillations in local field potentials just prior to stimulation and at the location of stimulation influence the effect of EBS.⁴⁸ Dynamics in the theta band may especially influence memory induction, since theta synchrony between MTL and neocortex mediates recollection.^{19,49} However, mimicking theta oscillatory patterns by the use of theta burst stimulation in the lateral neocortex⁵⁰ and in the entorhinal cortex⁷ led to

contradictory results, respectively a reduction and an improvement in memory performances. These uncertainties reinforce the need for more knowledge concerning EBS effects and changes in baseline brain state. Such studies would require EEG recordings in the operation room, which could be a constraint.

9- **Lack of interest or a publication bias?** A simple explanation could be that memories are still induced by EBS during awake craniotomy but are not reported in publications because of a lack of interest in experiential phenomena. It is possible that in this era neurosurgeons are only focused on issues of language and not of memory. But this argument does not seem valid, as there is still an interest in spontaneous phenomena caused by EBS during awake craniotomy. Different kinds of unexpected psychic phenomena such as out of body experiences,⁵¹ a strong desire to move a limb,⁵² and fear⁵³ are still reported. One possibility is a publication bias related to difficulties publishing single cases or the tendency to avoid publishing results that have already been reported.

Conclusions

Although historically they are major contributors to the understanding of long-term memory mechanisms, reminiscences induced by EBS have not been reported in the awake craniotomy literature of the past five decades. We are not able to give the exact reasons for this phenomenon. However, following our brief analysis above, we can hypothesize that the main reasons are more likely to be related to changes in operative procedures (use of anesthetic drugs, time constraints, and insufficient interviews) and in EBS parameters rather than to the current locations of EBS, pathology, or tasks.

If reminiscences are still induced during awake craniotomy, they should be reported in detail in order to add to the understanding of long-term memory networks, especially memories that are difficult to reproduce in a laboratory, such as autobiographical memories.^{13,19,20} Such

reminiscences are a complementary tool to rare experiments using naturalistic memory scenarios based on video-clips, movies or wearable cameras.^{54–56} Most available memory paradigms (cued words, targeted questions, presentation of visual items, spatial navigation tasks) are indeed insufficient to transcribe the rich experience and the ecological aspects of our autobiographical memories.

Therefore, here are our recommendations:

(1) Neurosurgeons should not hesitate to publish any case-report on experiential phenomena induced during awake craniotomy. A public repository would help to decrease publication biases. Each case provides further clues to determine the best EBS parameters for activating memory networks.

(2) A neurologist or psychologist in the operating room could help the patients to verbalize their subjective experience using appropriate and specific questions, especially when the temporal lobes are explored. Extensive reports should also be favored as they are the key to understanding the type of memory that was activated and the type of parameter that was used.¹³

(3) Awake mapping should be done as rigorously as possible within the limits of the operating constraints. In this context, setting a baseline state of patients' propensity to report subjective feelings during an operation would be helpful. This could be achieved through sham EBS applied randomly.

(4) Prospective trials comparing various EBS parameters in lateral versus MTL regions, coupled with intraoperative electrocorticography to track EEG oscillatory changes, should be designed.

We hope this review article will help neurosurgeons to share their experience.

References

1. Benabid AL, Chabardès S, Mitrofanis J, Pollak P. Deep brain stimulation of the subthalamic nucleus for the treatment of Parkinson's disease. *Acta Neurochir (Wien)*. 2009;8:67-81. doi:10.1007/s00701-009-0293-6
2. Holtzheimer PE, Mayberg HS. Deep Brain Stimulation for Psychiatric Disorders. *Annu Rev Neurosci*. 2011;34(1):289-307. doi:10.1146/annurev-neuro-061010-113638
3. Li MCH, Cook MJ. Deep brain stimulation for drug-resistant epilepsy. *Epilepsia*. 2017;(November). doi:10.1111/epi.13964
4. Chabardès S, Carron R, Seigneuret E, et al. Endoventricular Deep Brain Stimulation of the Third Ventricle: Proof of Concept and Application to Cluster Headache. *Neurosurgery*. 2016;79(6):806-814. doi:10.1227/NEU.0000000000001260
5. Collinger JL, Wodlinger B, Downey JE, et al. High-performance neuroprosthetic control by an individual with tetraplegia. *Lancet*. 2013;381(9866):557-564. doi:10.1016/S0140-6736(12)61816-9
6. Suthana N, Haneef Z, Stern J, et al. Memory Enhancement and Deep-Brain Stimulation of the Entorhinal Area. *N Engl J Med*. 2012;366(6):502-510. doi:10.1056/NEJMoa1107212
7. Titiz AS, Hill MRH, Mankin EA, et al. Theta-burst microstimulation in the human entorhinal area improves memory specificity. *Elife*. 2017;6:1-18. doi:10.7554/eLife.29515
8. Fell J, Staresina BP, Do Lam AT a, et al. Memory modulation by weak synchronous deep brain stimulation: A pilot study. *Brain Stimul*. 2013;6(3):270-273. doi:10.1016/j.brs.2012.08.001

9. Ezzyat Y, Kragel JE, Burke JF, et al. Direct Brain Stimulation Modulates Encoding States and Memory Performance in Humans. *Curr Biol.* 2016;27(9):1251-1258.
doi:10.1016/j.cub.2017.03.028
10. Stone SSD, Teixeira CM, DeVito LM, et al. Stimulation of Entorhinal Cortex Promotes Adult Neurogenesis and Facilitates Spatial Memory. *J Neurosci.* 2011;31(38):13469-13484. doi:10.1523/JNEUROSCI.3100-11.2011
11. Sankar T, Chakravarty MM, Bescos A, et al. Deep brain stimulation influences brain structure in Alzheimer's disease. *Brain Stimul.* 2015;8(3):645-654.
doi:10.1016/j.brs.2014.11.020
12. Penfield W, Perot P. Vol. 86, part 4. The brain's record of auditory and visual experience 1. *Brain.* 1963;86(December).
13. Curot J, Busigny T, Valton L, et al. Memory scrutinized through electrical brain stimulation: A review of 80 years of experiential phenomena. *Neurosci Biobehav Rev.* 2017;78(April):161-177. doi:10.1016/j.neubiorev.2017.04.018
14. Gloor P. Experiential Phenomena of Temporal Lobe Epilepsy. *Brain.* 1990;113(6):1673-1694. doi:10.1093/brain/113.6.1673
15. Vignal J-P, Maillard L, McGonigal A, Chauvel P. The dreamy state: hallucinations of autobiographic memory evoked by temporal lobe stimulations and seizures. *Brain.* 2007;130(Pt 1):88-99. doi:10.1093/brain/awl329
16. Halgren E, Walter RD, Cherlow DG, Crandall PH. Mental phenomena evoked by electrical stimulation of the human hippocampal formation and amygdala. *Brain.* 1978;101(1):83-117. <http://www.ncbi.nlm.nih.gov/pubmed/638728>.

17. Hamani C, McAndrews MP, Cohn M, et al. Memory enhancement induced by hypothalamic/fornix deep brain stimulation. *Ann Neurol.* 2008;63(1):119-123.
doi:10.1002/ana.21295
18. Deeb W, Salvato B, Almeida L, et al. Fornix-Region Deep Brain Stimulation–Induced Memory Flashbacks in Alzheimer’s Disease. *N Engl J Med.* 2019;381(8):783-785.
doi:10.1056/NEJMc1905240
19. Barbeau E, Wendling F, Régis J, et al. Recollection of vivid memories after perirhinal region stimulations: synchronization in the theta range of spatially distributed brain areas. *Neuropsychologia.* 2005;43(9):1329-1337. doi:10.1016/j.neuropsychologia.2004.11.025
20. Jacobs J, Lega B, Anderson C. Explaining how brain stimulation can evoke memories. *J Cogn Neurosci.* 2012;24(3):553-563. doi:10.1162/jocn_a_00170
21. Tulving E, Voi MEL, Routh DA, Loftus E. Ecphoric Processes in Episodic Memory [and Discussion]. *Philos Trans R Soc B Biol Sci.* 1983;302(1110):361-371.
doi:10.1098/rstb.1983.0060
22. Jacobs J, Miller J, Lee SA, et al. Direct electrical stimulation of human entorhinal region and hippocampus impairs memory. *Neuron.* 2016;92(5):983-990.
doi.org/10.1016/j.neuron.2016.10.062
23. Inman CS, Manns JR, Bijanki KR, et al. Direct electrical stimulation of the amygdala enhances declarative memory in humans. *Proc Natl Acad Sci.* 2018;115(1):98-103.
doi:10.1073/pnas.1714058114
24. Ezzyat Y, Wanda PA, Levy DF, et al. Closed-loop stimulation of temporal cortex rescues functional networks and improves memory. *Nat Commun.* 2018;9(1).
doi:10.1038/s41467-017-02753-0

25. Laxton AW, Tang-Wai DF, McAndrews MP, et al. A phase I trial of deep brain stimulation of memory circuits in Alzheimer's disease. *Ann Neurol*. 2010;68(4):521-534. doi:10.1002/ana.22089
26. Lee H, Fell J, Axmacher N. Electrical engram: How deep brain stimulation affects memory. *Trends Cogn Sci*. 2013;17(11):574-584. doi:10.1016/j.tics.2013.09.002
27. Koubeissi MZ, Kahrman E, Syed TU, Miller J, Durand DM. Low-frequency electrical stimulation of a fiber tract in temporal lobe epilepsy. *Ann Neurol*. 2013;74(2):223-231. doi:10.1002/ana.23915
28. Foster BL, Parvizi J. Direct cortical stimulation of human posteromedial cortex. *Neurology*. 2017;88(7):685-691. doi:10.1212/WNL.0000000000003607
29. Natu VS, Lin JJ, Burks A, et al. Stimulation of the posterior cingulate cortex impairs episodic memory encoding. *J Neurosci*. 2019;39(36):7173-7182. doi.org/10.1523/JNEUROSCI.0698-19.2019
30. Herbet G, Lafargue G, de Champfleury NM, et al. Disrupting posterior cingulate connectivity disconnects consciousness from the external environment. *Neuropsychologia*. 2014;56(1):239-244. doi:10.1016/j.neuropsychologia.2014.01.020
31. Gopinath S, Roy AG, Vinayan KP, et al. Seizure outcome following primary motor cortex-sparing resective surgery for perirolandic focal cortical dysplasia. *Int J Surg*. 2016;36:466-476. doi:10.1016/j.ijssu.2015.10.036
32. Kim SS, McCutcheon IE, Suki D, et al. Awake craniotomy for brain tumors near eloquent cortex: Correlation of intraoperative cortical mapping with neurological outcomes in 309 consecutive patients. *Neurosurgery*. 2009;64(5):836-845. doi:10.1227/01.NEU.0000342405.80881.81

33. Roux FE, Miskin K, Durand JB, et al. Electrostimulation mapping of comprehension of auditory and visual words. *Cortex*. 2015;71:398-408. doi:10.1016/j.cortex.2015.07.001
34. Wolfson R, Soni N, Shah A, Sastry A, Hosein K, Bregy A. The role of awake craniotomy in reducing intraoperative visual field deficits during tumor surgery. *Asian J Neurosurg*. 2015;10(3):139. doi:10.4103/1793-5482.161189
35. Ojemann GA, Dodrill C. Verbal memory deficits after left temporal lobectomy for epilepsy. Mechanism and intraoperative prediction. *J Neurosurg*. 1985;62(1):101-107. doi:10.3171/jns.1985.62.1.0101
36. Holmes MD, Ojemann GA, Lettich E. Neuronal activity in human right lateral temporal cortex related to visuospatial memory and perception. *Brain Res*. 1996;711(1-2):44-49. doi:10.1016/0006-8993(95)01351-2
37. Chapman LF, Walter RD, Markham CH, Rand RW, Crandall PH. Memory changes induced by stimulation of hippocampus or amygdala in epilepsy patients with implanted electrodes. *Trans Am Neurol Assoc*. 1966; 92:50–56.
38. Whittle IR, Midgley S, Georges H, Pringle a-M, Taylor R. Patient perceptions of “awake” brain tumour surgery. *Acta Neurochir (Wien)*. 2005;147(3):275-277; discussion 277. doi:10.1007/s00701-004-0445-7
39. Nossek E, Matot I, Shahar T, et al. Intraoperative seizures during awake craniotomy: Incidence and consequences: Analysis of 477 patients. *Neurosurgery*. 2013;73(1):135-140. doi:10.1227/01.neu.0000429847.91707.97
40. Moriarity JL, Boatman D, Krauss GL, Storm PB, Lenz F a. Human “memories” can be evoked by stimulation of the lateral temporal cortex after ipsilateral medial temporal lobe resection. *J Neurol Neurosurg Psychiatry*. 2001;71(4):549-551.

<http://www.pubmedcentral.nih.gov/articlerender.fcgi?artid=1763507&tool=pmcentrez&rendertype=abstract>.

41. Nathan SS, Sinha SR, Gordon B, Lesser RP, Thakor N V. Determination of current density distributions generated by electrical stimulation of the human cerebral cortex. *Electroencephalogr Clin Neurophysiol*. 1993;86(3):183-192. doi:10.1016/0013-4694(93)90006-H
42. Pouratian N, Cannestra AF, Bookheimer SY, Martin NA, Toga AW. Variability of intraoperative electrocortical stimulation mapping parameters across and within individuals. *J Neurosurg*. 2004;101(3):458-466. doi:10.3171/jns.2004.101.3.0458
43. Lesser RP, Lüders H, Klem G, Dinner DS, Morris HH, Hahn J. Cortical Afterdischarge and Functional Response Thresholds: Results of Extraoperative Testing. *Epilepsia*. 1984;25(5):615-621. doi:10.1111/j.1528-1157.1984.tb03471.x
44. Roux FE, Durand JB, Djidjeli I, Moyse E, Giussani C. Variability of intraoperative electrostimulation parameters in conscious individuals: language cortex. *J Neurosurg*. 2016;126(5):1641-1652. doi:10.3171/2016.4.JNS152434.
45. Bulsara KR, Johnson J, Villavicencio AT. Improvements in brain tumor surgery: the modern history of awake craniotomies. *Neurosurg Focus*. 2005;18(4):e5. doi:10.3171/foc.2005.18.4.6
46. Stevanovic A, Rossaint R, Veldeman M, Bilotta F, Coburn M. Anaesthesia management for awake craniotomy: Systematic review and meta-analysis. *PLoS One*. 2016;11(5):12-23. doi:10.1371/journal.pone.0156448
47. Veselis RA, Pryor KO, Reinsel RA, Li Y, Mehta M, Johnson R. Propofol and midazolam inhibit conscious memory processes very soon after encoding: An event-related

- potential study of familiarity and recollection in volunteers. *Anesthesiology*. 2009;110(2):295-312. doi:10.1097/ALN.0b013e3181942ef0
48. Lesser RP, Lee HW, Webber WRS, Prince B, Crone NE, Miglioretti DL. Short-term variations in response distribution to cortical stimulation. *Brain*. 2008;131(6):1528-1539. doi:10.1093/brain/awn044
49. Fuentemilla L, Barnes GR, Düzel E, Levine B. Theta oscillations orchestrate medial temporal lobe and neocortex in remembering autobiographical memories. *Neuroimage*. 2014;85:730-737. doi:10.1016/j.neuroimage.2013.08.029
50. Kim K, Schedlbauer A, Rollo M, Karunakaran S, Ekstrom AD, Tandon N. Network-based brain stimulation selectively impairs spatial retrieval. *Brain Stimul*. 2018;11(1):213-221. doi:10.1016/j.brs.2017.09.016
51. Bos EM, Spoor JKH, Smits M, Schouten JW, Vincent AJPE. Out-of-body experience during awake craniotomy. *World Neurosurg*. 2016;1-5. doi:10.1016/j.wneu.2016.05.002
52. Desmurget M, Reilly KT, Richard N, Szathmari a, Mottolese C, Sirigu a. Movement intention after parietal cortex stimulation in humans. *Science*. 2009;324(5928):811-813. doi:10.1126/science.1169896
53. Nowacki A, Seidel K, Schucht P, et al. Induction of Fear by Intraoperative Stimulation during Awake Craniotomy: Case Presentation and Systematic Review of the Literature. *World Neurosurg*. 2015;84(2):470-474. doi:10.1016/j.wneu.2015.03.056
54. Baldassano C, Chen J, Zadbood A, Pillow JW, Hasson U, Norman KA. Discovering Event Structure in Continuous Narrative Perception and Memory. *Neuron*. 2017;95(3):709-721.e5. doi:10.1016/j.neuron.2017.06.041

55. Chen J, Leong YC, Honey CJ, Yong CH, Norman KA, Hasson U. Shared memories reveal shared structure in neural activity across individuals. *Nat Neurosci.* 2017;20(1):115-125. doi:10.1038/nn.4450
56. Bird CM, Keidel JL, Ing LP, Horner AJ, Burgess N. Consolidation of Complex Events via Reinstatement in Posterior Cingulate Cortex. *J Neurosci.* 2015;35(43):14426-14434. doi:10.1523/JNEUROSCI.1774-15.2015
57. Morris HH, Luders H, Lesser RP, Dinner DS, Hahn J. Transient neuropsychological abnormalities (including Gerstmann's syndrome) during cortical stimulation. *Neurology.* 1984;34(7):877-877.
58. Bartolomei F, Barbeau E, Gavaret M, et al. Cortical stimulation study of the role of rhinal cortex in déjà vu and reminiscence of memories. *Neurology.* 2004;63(5):858-864. doi:10.1212/01.WNL.0000137037.56916.3F