



HAL
open science

Diffuse leptomeningeal glioneuronal tumor: a double misnomer? A report of two cases

Romain Appay, Mélanie Pages, Carole Colin, David Jones, Pascale Varlet,
Dominique Figarella-branger

► To cite this version:

Romain Appay, Mélanie Pages, Carole Colin, David Jones, Pascale Varlet, et al.. Diffuse leptomeningeal glioneuronal tumor: a double misnomer? A report of two cases. *Acta Neuropathologica Communications*, 2020, 8 (1), pp.95. 10.1186/s40478-020-00978-7 . hal-03009811

HAL Id: hal-03009811

<https://hal.science/hal-03009811v1>

Submitted on 18 Jun 2024

HAL is a multi-disciplinary open access archive for the deposit and dissemination of scientific research documents, whether they are published or not. The documents may come from teaching and research institutions in France or abroad, or from public or private research centers.

L'archive ouverte pluridisciplinaire **HAL**, est destinée au dépôt et à la diffusion de documents scientifiques de niveau recherche, publiés ou non, émanant des établissements d'enseignement et de recherche français ou étrangers, des laboratoires publics ou privés.



Distributed under a Creative Commons Attribution 4.0 International License

CASE REPORT

Open Access

Diffuse leptomeningeal glioneuronal tumor: a double misnomer? A report of two cases



Romain Appay^{1,2}, Mélanie Pages^{3,4,5,6,7}, Carole Colin², David T. W. Jones^{8,9}, Pascale Varlet^{3,4,10} and Dominique Figarella-Branger^{1,2*} 

Abstract

Diffuse leptomeningeal glioneuronal tumor (DLGNT) was introduced, for the first time, as a provisional entity in the 2016 WHO classification of central nervous system tumors. DLGNT mainly occur in children and characterized by a widespread leptomeningeal growth occasionally associated with intraspinal tumor nodules, an oligodendroglial-like cytology, glioneuronal differentiation and MAP-Kinase activation associated with either solitary 1p deletion or 1p/19q codeletion in the absence of *IDH* mutation.

We report here two unexpected DLGNTs adult cases, characterized by a unique supratentorial circumscribed intraparenchymal tumor without leptomeningeal involvement in spite of long follow-up. In both cases, the diagnosis of DLGNT was made after DNA-methylation profiling which demonstrated that one case belonged to the DLGNT class whereas the other remained not classifiable but showed on CNV the characteristic genetic findings recorded in DLGNT. Both cases harbored 1p/19q codeletion associated with *KIAA1549:BRAF* fusion in one case and with *BRAF V600E* and *PIK3CA E545A* mutations, in the other.

Our study enlarges the clinical and molecular spectrum of DLGNTs, and points out that the terminology of DLGNTs is not fully appropriate since some cases could have neither diffuse growth nor leptomeningeal dissemination. This suggests that DLGNTs encompass a wide spectrum of tumors that has yet to be fully clarified.

Keywords: DLGNT, Adult, Supratentorial, *BRAFV600E* mutation, DNA-methylation profiling

Introduction

Diffuse leptomeningeal glioneuronal tumor (DLGNT) was introduced as a provisional entity in the 2016 WHO classification of tumors of the central nervous system (CNS) [1]. It was defined as « *a rare glioneuronal neoplasm characterized by predominant and widespread leptomeningeal growth, an oligodendroglial-like cytology, evidence of neuronal differentiation in a subset of cases, and a high rate of concurrent KIAA1549:BRAF gene fusions and either solitary 1p deletion or 1p/19q codeletion in the absence of IDH mutation* ». DLGNT has not yet

been assigned a WHO grade, due to the limited number of reported cases, the often incomplete clinical follow-up, and the variability of outcome. DLGNT mainly occur in children and young adults. In addition to the leptomeningeal growth, more circumscribed, intraparenchymal, small cystic or solid tumor nodules may be observed. These tumor nodules are usually intraspinal but could be intracerebral in rare cases [2–5]. However, recent studies have reported DLGNT cases without diffuse growth nor leptomeningeal dissemination, at diagnosis and during long follow-up, suggesting that DLGNTs do not necessarily present with leptomeningeal dissemination on MRI [6–8]. Accordingly, DLGNTs were defined in the sixth cIMPACT-NOW update as “A glioneuronal neoplasm composed of oligodendrocyte-like cells; chromosome arm 1p deletion and a mitogen-activated protein kinase (MAP-

* Correspondence: dominiquefrance.figarella@ap-hm.fr

¹APHM, CHU Timone, Service d'Anatomie Pathologique et de Neuropathologie, Marseille, France

²Aix-Marseille Univ, CNRS, INP, Inst Neurophysiopathol, Marseille, France
Full list of author information is available at the end of the article



© The Author(s). 2020 **Open Access** This article is licensed under a Creative Commons Attribution 4.0 International License, which permits use, sharing, adaptation, distribution and reproduction in any medium or format, as long as you give appropriate credit to the original author(s) and the source, provide a link to the Creative Commons licence, and indicate if changes were made. The images or other third party material in this article are included in the article's Creative Commons licence, unless indicated otherwise in a credit line to the material. If material is not included in the article's Creative Commons licence and your intended use is not permitted by statutory regulation or exceeds the permitted use, you will need to obtain permission directly from the copyright holder. To view a copy of this licence, visit <http://creativecommons.org/licenses/by/4.0/>. The Creative Commons Public Domain Dedication waiver (<http://creativecommons.org/publicdomain/zero/1.0/>) applies to the data made available in this article, unless otherwise stated in a credit line to the data.

Kinase) pathway gene alteration, *KIAA1549:BRAF* fusion being most frequent; without *IDH* mutation; and commonly with diffuse leptomeningeal tumor spread" [9]. Because the pathological features of DLGNT are not specific, and with a large panel of differential diagnoses including pilocytic astrocytoma, ganglioglioma or extraventricular neurocytoma, the diagnosis might be particularly challenging in the cases lacking leptomeningeal dissemination. In a recent paper, Deng et al. [4] have reported the usefulness of DNA-methylation profiling for the diagnosis of DLGNTs. Copy-number profiles derived from the methylation arrays revealed unifying characteristics, including loss of chromosomal arm 1p in all cases. Furthermore, the authors showed that the molecular DLGNT class can be subdivided into two subgroups with distinct molecular alterations and clinical course. According to these findings, the c-IMPACT-NOW consortium suggested that DLGNT should be considered as a distinct tumor type with two distinct subtypes recognized on DNA-methylation profiling [9].

We report here two very unusual cases of DLGNT occurring in young adults and both presenting as a unique intracerebral mass without leptomeningeal involvement in spite of long follow-up.

Case presentation

Case 1

A 35-year-old woman was admitted to La Timone Hospital for epileptic seizures. She had history of a left parietal mass that was resected and diagnosed in Armenia as "diffuse astrocytoma grade II" when she was 14, without postoperative treatment. Unfortunately, we could not retrieve the tumor sample in order to review the initial diagnosis. MRI revealed an enhanced nodule after gadolinium injection, arising within the previous resection cavity (Fig. 1, a) without leptomeningeal involvement. Karnofsky index was 90 and no neurological deficit was recorded although her verbal fluency was decreased. After 2 years of MRI and clinical follow-up, a slight increase in the nodule size was observed, which, in spite of normal FDG-PET uptake, motivated a surgical excision and a gross total resection was achieved.

Pathological examination showed a highly cellular neoplasm composed of relatively monomorphic oligodendrocyte-like cells associated with an endocri-
noïd vasculature. Microvascular proliferation was observed without necrosis (Fig. 1, b). Mitotic activity was high with up to 6 mitotic figures per 2.4 mm². KI67 labeling index was around 10% (Fig. 1, c). Tumor cells strongly expressed OLIG2 and to a lesser extent synaptophysin but not GFAP nor CD34 (Fig. 1, d-e). *IDH1R132H* was negative and *ATRX* expression was retained in nuclei. *BRAF V600E* expression (VE1 antibody) was strong in all tumor cells (Fig. 1, f).

Targeted NGS analysis confirmed the *BRAF V600E* mutation and revealed a co-occurrence of the hotspot mutation *PIK3CA E545A*. No *IDH*, *H3F3A/HIST1H3B* nor *TERT* promoter mutation were observed. FISH analysis showed a 1p/19q codeletion. Diagnosis was "unusual glioneuronal tumor with histological features of anaplasia". Central review was performed under the framework of the national RENOCIP-LOC network and DNA-methylation profiling was performed using an EPIC array (Integragen, Evry, France) as previously described [10]. The raw IDAT files were uploaded to <https://www.moleculareuropathology.org> for supervised analysis using the Random Forest methylation class prediction algorithm, and copy number profiles were obtained as previously described [11]. The methylation class was DLGNT (calibrated score 0.99) and CNV analysis confirmed 1p/19q codeletion and showed additional gains of chromosomes 3 and 7 (Fig. 1, g). Comparison with the DLGNT reference series indicated that this tumor belongs to DLGNT – molecular class 1. Final diagnosis was recurrent "localized form of DLGNT associated with 1p/19q codeletion and *BRAF V600E* mutation". It was decided to closely follow the patient without adjuvant treatment.

Case 2

A 31-year-old woman was admitted to La Timone Hospital in March 2012 for epileptic seizures. MRI revealed a parietal cystic tumor with a mural nodule enhanced after gadolinium injection (Fig. 2, a-b). A gross total resection was performed. Pathological examination showed a proliferation of oligodendrocyte-like cells associated with a rich and branched vasculature (Fig. 2, c). Desmoplasia was observed. The tumor was well limited from the adjacent cortex (Fig. 2, d). Granular bodies were evident as well as inflammatory exudates. Ganglionic neurons were lacking. The tumor strongly expressed OLIG2 and synaptophysin but not neurofilament nor chromogranin A (Fig. 2, e-f). No extravascular CD34 expression was observed. KI67 labeling index was 3%. No *BRAF V600E* mutation was recorded by direct sequencing. The diagnosis was "benign glioneuronal tumor compatible with ganglioglioma grade I". In 2018, this case was included in the series of cases of gangliogliomas lacking *BRAF V600E* mutation in order to search for *EWSR1-PATZ1* mutation and to perform methylation profiling [12]. Methylation profile did not yield a high-confidence score based on the <https://www.moleculareuropathology.org> classification algorithm, possibly due to a moderate proportion of normal cells / immune infiltration in the tissue sample used for molecular profiling. The copy number profile indicated 1p/19q codeletion and *KIAA1549:BRAF* fusion, as commonly observed in DLGNT (Fig. 2, g). FISH analysis confirmed 1p/19q codeletion, and droplet digital

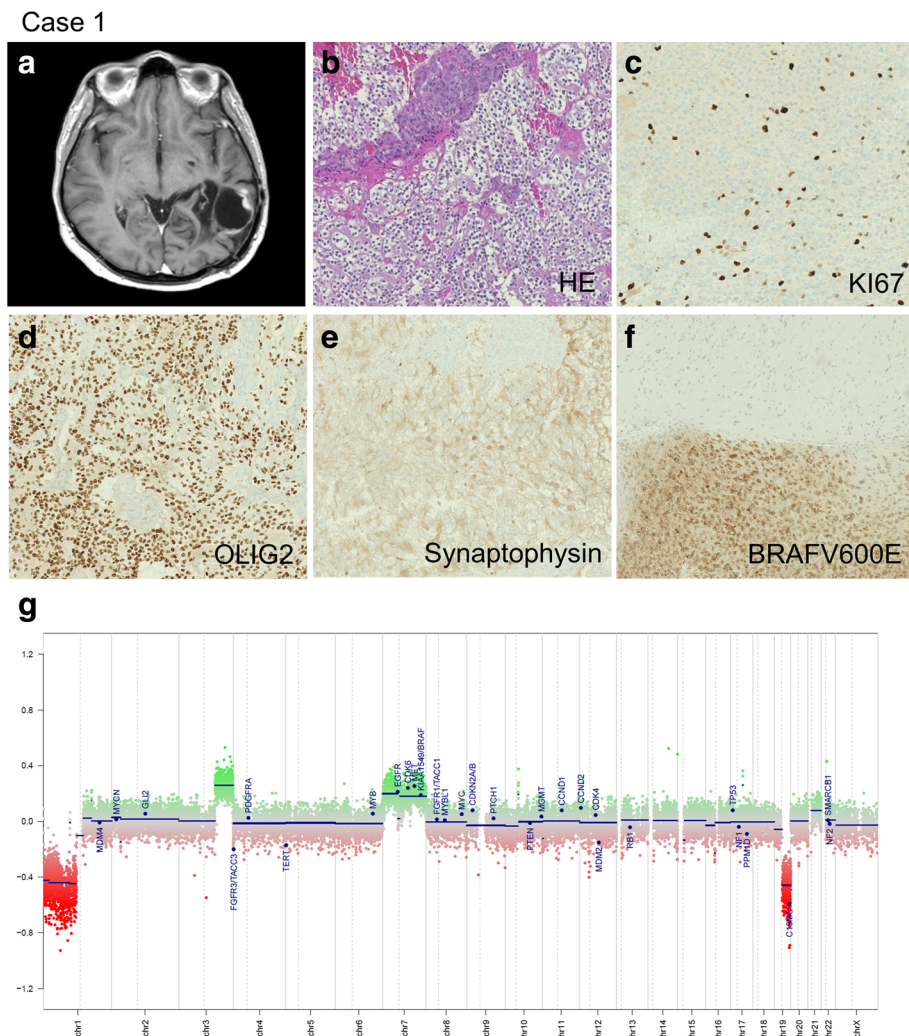


Fig. 1 **a** MRI disclosed a nodule enhanced after gadolinium injection, located within the intraoperative cavity. **b** High cellularity neoplasm composed of relatively monomorphic oligodendrocyte-like cells associated with endocrinoïd vasculature. **c** KI67 labeling index was around 10%. **d, e, f** Tumor cells strongly expressed OLIG2 and synaptophysin and BRAFV600E. **g** Copy-number profile derived from DNA-methylation arrays revealed 1p/19q codeletion with additional gains of chromosomes 3 and 7

PCR analysis confirmed the *KIAA1549:BRAF* fusion as previously described [13]. The patient did not undergo any adjuvant treatment and after 10 years follow-up, she is still alive with no evidence of relapse nor leptomeningeal spread.

Discussion and conclusions

In this study we report two cases that fully meet the diagnostic criteria of DLGNTs as proposed by the sixth cIMPACT-NOW update [9], although neither of them presented diffuse growth nor leptomeningeal involvement in spite of a long follow-up. Indeed, both were glioneuronal neoplasm composed of oligodendrocyte-like cells; chromosome arm 1p deletion and a mitogen-activated protein kinase (MAP-Kinase) pathway gene alteration.

In the first case, diagnosis was made on the late relapse, 20 years later, of a tumor initially diagnosed as “diffuse astrocytoma grade II”. In the second case, initial pathological diagnosis was “ganglioglioma grade I” and this tumor was reclassified as DLGNT 8 years later after evidence for both 1p/19q codeletion and *KIAA1549:BRAF* fusion. A t-SNE analysis (t-distributed stochastic neighbor embedding) was performed (Fig. 3) including the following glioma reference classes: ganglioglioma (GG, 21 cases), anaplastic astrocytoma with piloid features (AAP, 20 cases), DLGNT (26 cases), LGM6-GBM (Ceccarelli et al., 2016, 13 cases) [14], PA-like low grade gliomas (PA-like, Ceccarelli et al., 2016, 26 cases), pilocytic astrocytoma (PA_INF, 28 cases), polymorphous low-grade neuroepithelial tumor of the young (PLNTY, 10 cases) and normal hemisphere (Norm_Hemi, 12 cases). Our first case clustered with the DLGNT

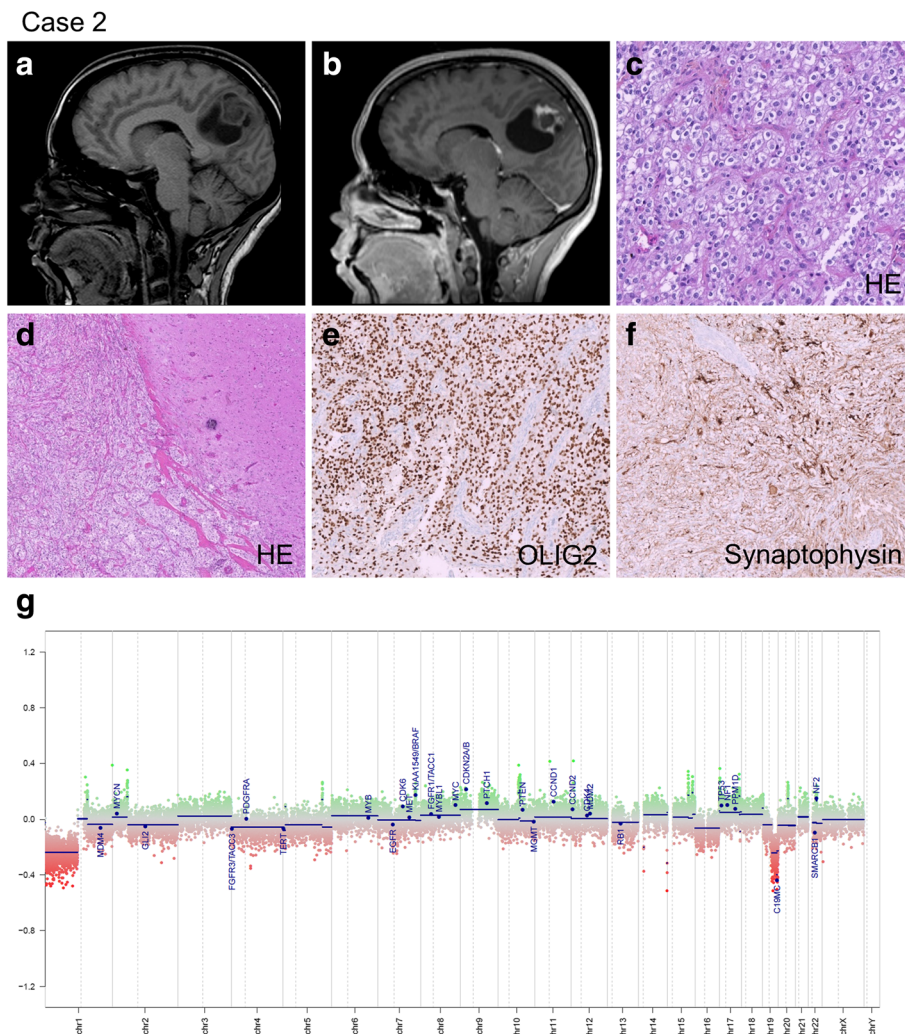


Fig. 2 **a, b** MRI showed a cystic tumor with a mural nodule enhanced after gadolinium injection. **c** A proliferation of oligodendrocyte-like cells associated with a rich and branched vasculature. **d** Well demarcation of the tumor from the adjacent cortex. **e, f** The tumor cells strongly expressed OLIG2 and synaptophysin. **g** Copy-number profile derived from DNA methylation arrays revealed 1p/19q codeletion and *KIAA1549:BRAF* fusion

tumor group, highly supporting its diagnosis. As expected, our second case, which did not demonstrated a significant confidence score on the classification algorithm, possibly due to a moderate proportion of normal cells / immune infiltration in the tissue sample, did not segregated in a clear methylation group. It showed similarity to AAP but was detached from the main cluster of this group. However, in contrast with AAP, this case did not demonstrated features of anaplasia, piloid cytology, *ATRX* loss nor *CDKN2A/B* homozygous deletion. In addition, clinical course was favorable in contrast with the reported evolution of AAP. It was a case of difficult diagnosis, for which pathological and molecular features fully met the diagnostic criteria of DLGNT with no argument towards a differential diagnosis. These two cases point out that the DLGNTs can occur in the absence of leptomeningeal

dissemination and in the adult setting, in contrast to initial reports [5]. In such circumstances it is particularly challenging to think of this diagnosis since the pathological features remain non-specific and could mimic pilocytic astrocytoma, ganglioglioma, oligodendroglioma *IDH*-mutant and 1p/19q codeleted, extraventricular neurocytoma, as well as recently reported polymorphous low-grade neuroepithelial tumors of the young (PLNTYs) [15] and tumors possibly related to the last reported as *BRAF* V600E mutant oligodendroglioma-like tumors with chromosomal instability (*BRAF*-OLT) [16]. All these tumors have in common a focal oligodendrocyte-like proliferation (i.e. pilocytic astrocytoma, ganglioglioma) or a more diffuse pattern (oligodendroglioma *IDH*-mutant and 1p/19q codeleted, extraventricular neurocytoma and PLNTYs/*BRAF*-OLT). Some pathological criteria, when present,

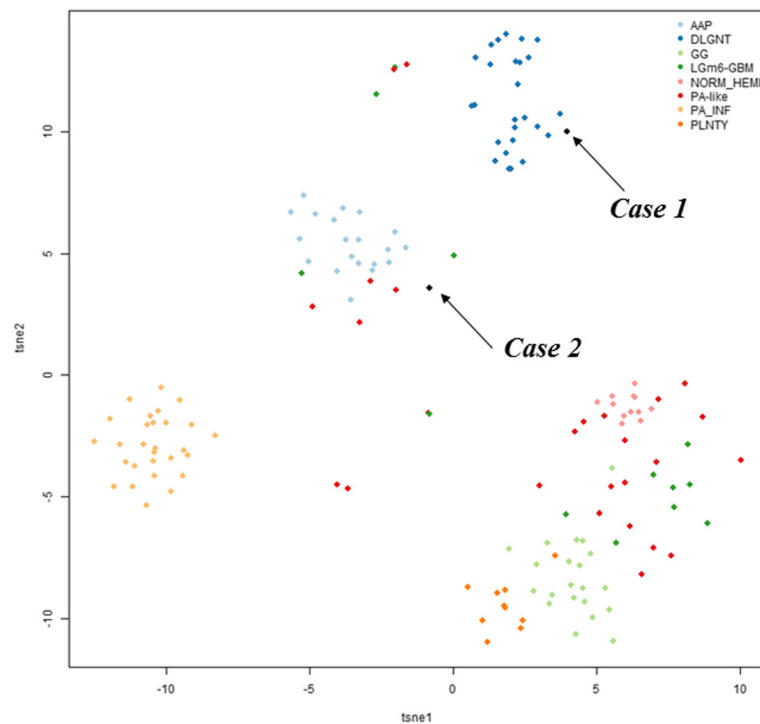


Fig. 3 t-SNE plot of the 2 reported cases associated with 156 reference gliomas. Reference classes: AAP, anaplastic astrocytoma with piloid features; DLGNT, diffuse leptomeningeal glioneuronal tumor; GG, ganglioglioma; LGm6-GBM [14]; NORM_HEMI, normal hemisphere; PA-Like [14]; PA_INF, posterior fossa pilocytic astrocytoma and PLNTY, polymorphous low-grade neuroepithelial tumor of the young

might be more characteristic of one entity than others: Rosenthal fibers in pilocytic astrocytoma, lymphocytic cuffing, and eosinophilic granular bodies in ganglioglioma. Ganglion cells, a common feature of ganglioglioma might also be observed in DLGNT and in extraventricular neurocytoma [5, 17]. Extraventricular neurocytoma and oligodendroglioma *IDH*-mutant and 1p/19q codeleted often display a dense branched vasculature. Moreover pilocytic astrocytoma, ganglioglioma, oligodendroglioma *IDH*-mutant and 1p/19q codeleted or extraventricular neurocytoma share with DLGNT the OLIG2 and synaptophysin protein expression whereas PLNTYs are OLIG2-positive but most commonly lack synaptophysin expression [15]. In addition, ganglioglioma and PLNTYs/BRAF-OLTs frequently demonstrate CD34-immunopositivity. Furthermore, as observed in our cases, GFAP expression is commonly lacking in DLGNT whereas it is positive in the differential diagnosis mentioned above [5, 6]. The two cases reported here demonstrated oligodendrocyte-like proliferations of cells co-expressing OLIG2 and synaptophysin associated with a dense, often branched vasculature. Although rare, pathological features of anaplasia such as those observed in our first case (microvascular proliferation, high mitotic count and proliferation index) might occur in DLGNTs. Genetic findings help to distinguish DLGNTs from their main differential diagnoses.

DLGNTs share MAP-Kinase alteration with pilocytic astrocytoma, ganglioglioma or PLNTYs/BRAF-OLTs. However, 1p deletion is not a common feature of pilocytic astrocytoma, when present it is usually subclonal [10], and 1p/19q codeletion does not occur. Furthermore, the 1p/19q codeletion is not encountered in ganglioglioma nor in PLNTYs/BRAF-OLTs, but by definition, is the hallmark of oligodendroglioma *IDH*-mutant and 1p/19q codeleted. The diagnosis of our second case was particularly challenging because it was supratentorial, occurring in an adult, and the pathological examination was suggestive of anaplastic oligodendroglioma. However, in spite of a 1p/19q codeletion, *IDH* mutation was lacking and *KIAA1549:BRAF* fusion was present. It is to note that, Badiali et al. [18] previously reported rare cases of gliomas *IDH*-mutant and 1p/19q-codeleted with co-occurrence of *KIAA1549:BRAF* fusion. Therefore, in adults, an oligodendrocyte-like tumor demonstrating 1p/19q codeletion, in the absence of *IDH* mutation should point towards DLGNT and the search for an associated MAP-Kinase alteration should be done by appropriate testing even if the tumor is supratentorial without leptomeningeal dissemination. The first case was also very unusual by the association of 1p/19q codeletion, *PIK3CA* mutation and *BRAF V600E* mutation. As far as we know *PIK3CA* mutation has never been reported. Although MAP-Kinase alteration is always recorded in DLGNT, the

most frequent MAP-Kinase alteration reported in DLGNT is the *KIAA1549:BRAF* fusion although *NTRK1/2/3* and *TRIM33:RAF1* fusions might also occur [4]. The *BRAF* V600E mutation seems very infrequent in DLGNT. We could identify only one previously reported case of low-grade glioneuronal tumor with oligodendroglial features and *BRAF* V600E mutation that presented as an isolated temporal lesion that later disseminated. However, 1p data was not available for this case and thus whether it corresponded to a DLGNT remains questionable [19]. Two subtypes of DLGNT have been described by DNA-methylation profiling: DLGNT-MC-1 and DLGNT-MC-2 by Deng et al. [4]. Compared to DLGNT-MC-2, the age at diagnosis was lower in the DLGNT-MC-1 group, (median 5 vs 14 years, $p < 0.01$) and the clinical course less aggressive (5-year OS 100% vs 43% in DLGNT-MC-2). DLGNT-MC-2 is enriched for superimposed 1q gain whereas codeletion of 1p/19q was more frequently observed in DLGNT-MC-1. Our two cases demonstrating 1p/19q codeletion and excellent outcome likely belong to the DLGNT-MC-1 subtype (confirmed in one case, and assumed based on absence of 1q gain in the second).

To conclude, the terminology of “diffuse leptomeningeal glioneuronal tumor” appears unsuitable in our cases which had neither diffuse growth nor leptomeningeal dissemination suggesting that DLGNTs comprises a spectrum of tumors that has yet to be fully clarified. These tumors would be further classified in the large group of “gliomas and glioneuronal tumors driven by MAP-Kinase pathway alterations” in the fifth edition of the WHO classification of CNS tumors.

Abbreviations

AAP: Anaplastic astrocytoma with piloid features; BRAF-OLT: BRAF V600E mutant oligodendroglioma-like tumor; c-IMPACT-NOW: Consortium to inform molecular and practical approaches to CNS Tumor taxonomy – not official WHO; CNS: Central nervous system; CNV: Copy number variation; ddPCR: Droplet digital PCR; DLGNT: Diffuse leptomeningeal glioneuronal tumor; FDG-PET: Positron emission tomography with 2-deoxy-2-fluoro- D-glucose; FISH: Fluorescence in situ hybridization; GG: Ganglioglioma; IDAT files: Intensity data files; LGG: Low grade glioma; MAP-Kinase: Mitogen-activated protein kinases; MRI: *Magnetic resonance imaging*; NGS: *Next-generation sequencing*; PA: Pilocytic astrocytoma; PA-like: PA-like low grade glioma; PLNTY: Polymorphous low-grade neuroepithelial tumor of the young; RENOCLIP-LOC: *Réseau national de neuro-oncologie clinicoPathologique pour les cancers rares du système nerveux central*; t-SNE: t-distributed Stochastic neighbor embedding; WHO: World health organization

Acknowledgements

We thank the pathologists of the RENOCLIP-LOC network: Dr. Guillaume Gauthot, Pr Catherine Godfraind, Pr Claude-Alain Maurage, Dr. David Meyronet, Dr. Karima Mokhtari, Dr. Audrey Rousseau and Pr Emmanuelle Uro-Coste. We thank Karen Silva and Chantal Campello. We thank the Cancéropôle PACA.

Authors' contributions

DFB and PV identified and diagnosed the reported cases; DJ and MP performed methylation profile analysis; DJ performed the t-SNE plot; RA, CC & DFB: wrote the manuscript with input from all authors. All authors read and approved the final manuscript.

Funding

This work was conducted thanks to the RENOCLIP-LOC network (*Réseau national de neuro-oncologie clinicoPathologique pour les cancers rares du système nerveux central*), funded by the French Institut National du Cancer (INCa) grant (Decision n°2019–29). It was also funded by grants from patient's associations; we thank the *Association Cassandra*, *Imagine for Margo*, the *ARTC-Sud (Association pour la recherche sur les Tumeurs Cérébrales – Sud)* and the *SFCE (Société Française de lutte contre les Cancers et les leucémies de l'Enfant et de l'Adolescent)*.

Availability of data and materials

Not applicable.

Ethics approval and consent to participate

Written consent for clinical data collection and genetic analysis according to national and RENOCLIP network policies was obtained for both patients.

Consent for publication

Not applicable.

Competing interests

The authors declare that they have no competing interests.

Author details

¹APHM, CHU Timone, Service d'Anatomie Pathologique et de Neuropathologie, Marseille, France. ²Aix-Marseille Univ, CNRS, INP, Inst Neuropsychiopathol, Marseille, France. ³Université Paris Descartes, Sorbonne Paris Cité, Paris, France. ⁴Service de Neuropathologie, GHU Paris – Hôpital Sainte-Anne, Paris, France. ⁵Equipe SiRIC RTOP Recherche Translationnelle en Oncologie Pédiatrique, Institut Curie, Paris, France. ⁶INSERM U830, Laboratoire de Génétique et Biologie des Cancers, Institut Curie, Paris, France. ⁷SiREDO: Care, Innovation and Research for Children, Adolescents and Young Adults with Cancer, Institut Curie, Paris, France. ⁸Hopp Children's Cancer Center Heidelberg (KiTZ), 69120 Heidelberg, Germany. ⁹Pediatric Glioma Research Group, German Cancer Research Center (DKFZ), Im Neuenheimer Feld 280, 69120 Heidelberg, Germany. ¹⁰INSERM UMR 1266, IMA-Brain, Institut de Psychiatrie et de Neurosciences de Paris, Paris, France.

Received: 7 May 2020 Accepted: 22 June 2020

Published online: 30 June 2020

References

- Louis DN, Perry A, Reifenberger G, von Deimling A, Figarella-Branger D, Cavenee WK, Ohgaki H, Wiestler OD, Kleihues P, Ellison DW (2016) World Health Organization classification of tumors of the central nervous system: a summary. *Acta Neuropathol* 126(1):1–103. <https://doi.org/10.1007/s00401-016-1545-1>
- Gardiman MP, Fassin M, Orvieto E, D'Avella D, Denaro L, Calderone M, Severino M, Scarsello G, Viscardi E, Perilongo G (2010) Diffuse leptomeningeal glioneuronal tumors: a new entity? *Brain Pathol* 20:361–366. <https://doi.org/10.1111/j.1750-3639.2009.00285.x>
- Agamanolis DP, Katsetos CD, Klonk CJ, Bartkowski HM, Ganapathy S, Staugaitis SM, Kuerbitz SJ, Patton DF, Talaizadeh A, Cohen BH (2012) An unusual form of superficially disseminated glioma in children: report of 3 cases. *J Child Neurol* 27:727–733. <https://doi.org/10.1177/0883073811426500>
- Deng MY, Sill M, Chiang J, Schittenhelm J, Ebinger M, Schuhmann MU, Monoranu CM, Milde T, Wittmann A, Hartmann C et al (2018) Molecularly defined diffuse leptomeningeal glioneuronal tumor (DLGNT) comprises two subgroups with distinct clinical and genetic features. *Acta Neuropathol* 136: 239–253. <https://doi.org/10.1007/s00401-018-1865-4>
- Rodriguez FJ, Perry A, Rosenblum MK, Krawitz S, Cohen KJ, Lin D, Mosier S, Lin MT, Eberhart CG, Burger PC (2012) Disseminated oligodendroglial-like leptomeningeal tumor of childhood: a distinctive clinicopathologic entity. *Acta Neuropathol* 124:627–641. <https://doi.org/10.1007/s00401-012-1037-x>
- Chiang JCH, Harrelld JH, Orr BA, Sharma S, Ismail A, Segura AD, Ellison DW (2017) Low-grade spinal glioneuronal tumors with BRAF gene fusion and 1p deletion but without leptomeningeal dissemination. *Acta Neuropathol* 134: 159–162. <https://doi.org/10.1007/s00401-017-1728-4>
- Tiwari N, Tamrazi B, Robison N, Krieger M, Ji J, Tian D (2019) Unusual radiological and histological presentation of a diffuse leptomeningeal

- glioneuronal tumor (DLGNT) in a 13-year-old girl. *Childs Nerv Syst* 35:1609–1614. <https://doi.org/10.1007/s00381-019-04074-7>
8. Kang JH, Buckley AF, Nagpal S, Fischbein N, Peters KB (2018) A diffuse Leptomeningeal Glioneuronal tumor without diffuse Leptomeningeal involvement: detailed molecular and clinical characterization. *J Neuropathol Exp Neurol* 77:751–756. <https://doi.org/10.1093/jnen/nly053>
 9. Louis DN, Wesseling P, Aldape K, Brat DJ, Capper D, Cree IA, Eberhart C, Figarella-Branger D, Fouladi M, Fuller GN et al (2020) cIMPACT-NOW update 6: new entity and diagnostic principle recommendations of the cIMPACT-Utrecht meeting on future CNS tumor classification and grading. *Brain Pathol.* <https://doi.org/10.1111/bpa.12832>
 10. Gareton A, Tauziède-Espariat A, Dangouloff-Ros V, Roux A, Saffroy R, Castel D, Kergrohen T, Fina F, Figarella-Branger D, Pages M et al (2020) The histomolecular criteria established for adult anaplastic pilocytic astrocytoma are not applicable to the pediatric population. *Acta Neuropathol* 139:287–303. <https://doi.org/10.1007/s00401-019-02088-8>
 11. Capper D, Jones DTW, Sill M, Hovestadt V, Schrimpf D, Sturm D, Koelsche C, Sahm F, Chavez L, Reuss DE et al (2018) DNA methylation-based classification of central nervous system tumours. *Nature* 555:469–474. <https://doi.org/10.1038/nature26000>
 12. Siegfried A, Rousseau A, Maurage CA, Pericart S, Nicaise Y, Escudie F, Grand D, Delrieu A, Gomez-Brouchet A, Le Guellec S et al (2019) EWSR1-PATZ1 gene fusion may define a new glioneuronal tumor entity. *Brain Pathol* 29: 53–62. <https://doi.org/10.1111/bpa.12619>
 13. Appay R, Fina F, Macagno N, Padovani L, Colin C, Baretts D, Ordioni J, Scavarda D, Giangaspero F, Badiali M et al (2018) Duplications of KIAA1549 and BRAF screening by droplet digital PCR from formalin-fixed paraffin-embedded DNA is an accurate alternative for KIAA1549-BRAF fusion detection in pilocytic astrocytomas. *Mod Pathol* 31:1490–1501. <https://doi.org/10.1038/s41379-018-0050-6>
 14. Ceccarelli M, Barthel FP, Malta TM, Sabedot TS, Salama SR, Murray BA, Morozova O, Newton Y, Radenbaugh A, Pagnotta SM et al (2016) Molecular profiling reveals biologically discrete subsets and pathways of progression in diffuse Glioma. *Cell* 164:550–563. <https://doi.org/10.1016/j.cell.2015.12.028>
 15. Huse JT, Snuderl M, Jones DT, Brathwaite CD, Altman N, Lavi E, Saffery R, Sexton-Oates A, Blumcke I, Capper D et al (2017) Polymorphous low-grade neuroepithelial tumor of the young (PLNTY): an epileptogenic neoplasm with oligodendroglioma-like components, aberrant CD34 expression, and genetic alterations involving the MAP kinase pathway. *Acta Neuropathol* 133:417–429. <https://doi.org/10.1007/s00401-016-1639-9>
 16. Fukuoka K, Mamatjan Y, Ryall S, Komosa M, Bennett J, Zapotocky M, Keith J, Myrehaug S, Hazrati LN, Aldape K et al (2020) BRAF V600E mutant oligodendroglioma-like tumors with chromosomal instability in adolescents and young adults. *Brain Pathol* 30:515–523. <https://doi.org/10.1111/bpa.12799>
 17. Sievers P, Stichel D, Schrimpf D, Sahm F, Koelsche C, Reuss DE, Wefers AK, Reinhardt A, Huang K, Ebrahimi A et al (2018) FGFR1:TACC1 fusion is a frequent event in molecularly defined extraventricular neurocytoma. *Acta Neuropathol* 136:293–302. <https://doi.org/10.1007/s00401-018-1882-3>
 18. Badiali M, Gleize V, Paris S, Moi L, Elhouadani S, Arcella A, Morace R, Antonelli M, Buttarelli FR, Figarella-Branger D et al (2012) KIAA1549-BRAF fusions and IDH mutations can coexist in diffuse gliomas of adults. *Brain Pathol* 22:841–847. <https://doi.org/10.1111/j.1750-3639.2012.00603.x>
 19. Dodgshun AJ, SantaCruz N, Hwang J, Ramkissoon SH, Malkin H, Bergthold G, Manley P, Chi S, MacGregor D, Goumnerova L et al (2016) Disseminated glioneuronal tumors occurring in childhood: treatment outcomes and BRAF alterations including V600E mutation. *J Neuro-Oncol* 128:293–302. <https://doi.org/10.1007/s11060-016-2109-x>

Publisher's Note

Springer Nature remains neutral with regard to jurisdictional claims in published maps and institutional affiliations.

Ready to submit your research? Choose BMC and benefit from:

- fast, convenient online submission
- thorough peer review by experienced researchers in your field
- rapid publication on acceptance
- support for research data, including large and complex data types
- gold Open Access which fosters wider collaboration and increased citations
- maximum visibility for your research: over 100M website views per year

At BMC, research is always in progress.

Learn more biomedcentral.com/submissions

