



HAL
open science

Bálint's syndrome

Laure Pisella, Audrey Vialatte, Aarlenne Zein, Yves Rossetti

► **To cite this version:**

Laure Pisella, Audrey Vialatte, Aarlenne Zein, Yves Rossetti. Bálint's syndrome. Handbook of Clinical Neurology 3 rd Series, In press. hal-03007997


HAL Id: hal-03007997

<https://hal.science/hal-03007997>

Submitted on 16 Nov 2020

HAL is a multi-disciplinary open access archive for the deposit and dissemination of scientific research documents, whether they are published or not. The documents may come from teaching and research institutions in France or abroad, or from public or private research centers.

L'archive ouverte pluridisciplinaire **HAL**, est destinée au dépôt et à la diffusion de documents scientifiques de niveau recherche, publiés ou non, émanant des établissements d'enseignement et de recherche français ou étrangers, des laboratoires publics ou privés.



Handbook of Clinical Neurology 3rd Series

Bálint's syndrome

Laure Pisella, Audrey Vialatte, Aarlenne Zein Khan & Yves Rossetti

laure.pisella@inserm.fr

Lyon Neuroscience Research Center, Lyon, France
Phone number: (+33) 4 72 91 34 00

Abstract:

We start by review the evolution of Bálint syndrome, covering the various interpretations of it over time. We then develop a novel integrative view in which we propose that the various symptoms, historically reported and labelled by various authors, result from a core mislocalization deficit. This idea is in accordance with our previous proposal that the core deficit of Bálint syndrome is attentional (Pisella et al. 2009, 2013, 2017) since covert attention improves spatial resolution in visual periphery (Yeshurun and Carrasco 1998); a deficit of covert attention would thus increase spatial uncertainty and thereby impair both visual object identification and visuo-motor accuracy. In peripheral vision, we perceive the intrinsic characteristics of the perceptual elements surrounding us, but not their precise localization (Rosenholtz et al. 2012a,b), such that without covert attention we cannot organize them to their respective and recognizable objects; this explains why perceptual symptoms (simultanagnosia, neglect) could result from visual mislocalisation. The visuo-motor symptoms (optic ataxia) can be accounted for by both visual and proprioceptive mislocalisations in an oculocentric reference frame, leading to field and hand effects, respectively.

This new pathophysiological account is presented along with a model of posterior parietal cortex organisation in which the superior part is devoted to covert attention while the right inferior part is involved in visual remapping. When the right inferior parietal cortex is damaged, additional representational mislocalisations across saccades worsen the clinical picture of peripheral mislocalisations due to an impairment of covert attention.

Key words: Bálint-Holmes, posterior parietal cortex, optic ataxia, simultanagnosia, spatial neglect, covert attention, visual remapping, spatial cognition

The syndrome described by Reszo Bálint in 1909 and later, in other terms, by Gordon Holmes in 1918 is a clinical entity which combines a set of complex spatial behaviour disorders following bilateral posterior parietal damage (dorsal stream). This chapter highlights the long-standing difficulties in describing and comprehending this rare and devastating syndrome. This is particularly true for the ocular behaviour of these patients. Both the diversity of terminology used in literature and biases in clinical descriptions reflect the dual views of the posterior parietal cortex (PPC): involved either in spatial cognition (Ungerleider and Mishkin 1982, Ettlinger 1990) and attention (Colby and Goldberg, 1999), or in motor control (Andersen and Buneo 2002). In the context of the perception–action dissociation model of the two visual streams (Goodale & Milner 1992, Milner & Goodale 1995, 2006), the study of patients with unilateral and more focal lesions has led researchers to consider that every symptom of Bálint triad could be seen in isolation. In other words, the syndrome may not be a single clinical entity but rather a combination of independent visuo-motor and perceptual symptoms. However, this popular idea of a dissociation between perception and action has been thoroughly revisited over the recent years (e.g. Pisella et al., 2009; Rossetti et al. 2003; 2010; 2017). We propose a novel integrative pathophysiological account of the Bálint-Holmes syndrome based on recent patient cases studies and on a modernized model of the anatomo-functional organisation of the PPC in the right hemisphere.

1- Initial observations:

Initially, Bálint (1909) described in a patient with bilateral dorso-lateral parietal damage (Figure 1) as a syndrome composed of a triad:

- ‘optische Ataxie’, an impairment manifested when performing visually-guided actions, especially with the patient’s right hand. The deficit was apparent in central vision but it was greatly exacerbated in peripheral vision. As this ataxia could be compensated by a somatosensory/haptic exploration of the object like a blind person, it was described as specifically ‘optic’;

- ‘seelenlähmung des Schauens’, described as ‘an extreme restriction of visual attention, such that only one object is seen at a time’ is often ascribed to “simultanagnosia” (Wolpert, 1924) or “disorder of simultaneous perception” (Luria,

1959). By labelling this set of symptoms “psychic” paralysis of gaze, Bálint highlighted that the patient exhibited no visual field defect and no oculomotor paralysis, but presented difficulty finding a peripheral visual target with his eyes and disengaging from fixated items;

- ‘räumliche Störung der Aufmerksamkeit’, described as a lateralised ‘spatial attention disorder’: attention in the extrapersonal space is spontaneously oriented to the right of the body midline and stimuli lying to the left of fixation are neglected (see De Renzi et al., 1989). This description corresponds to what is now called “unilateral spatial neglect”.

A few years later, Holmes (1918) described a related visual inattention disorder, after describing cutaneous inattention (Head and Holmes, 1911). He reported in detail a ‘disturbance of visual orientation’ syndrome in soldier patients with bilateral parietal lesions, highlighting a particular eye movement disorganisation: a wandering of gaze accompanied by a deficit for visually guided reach-to-grasp movements, together with disorders of fixation, convergence and depth perception. Holmes and Horrax (1919) provided evidence from post-mortem examination in two cases that this high level visual dysfunction was due to bilateral lesions of the angular and supramarginal gyri and their contiguous areas. This clinical description was later considered as an oculomotor disorder and labelled gaze ataxia or gaze apraxia (review: Vallar, 2007).

The three elements of Bálint’s triad have been historically subjected to numerous types of interpretation, such that, most current textbooks define Bálint syndrome as a triad of symptoms that actually does not correspond to Bálint’s initial description: 1) optic ataxia, 2) simultanagnosia and 3) ocular apraxia (e.g. Kirshner and Lavin, 2006; Denburg and Tranel, 2009; Kaufman et al., 2017). In this incongruous description, unilateral neglect has been excluded from the triad and perceptual and ocular deficits have been dissociated. This shift in the very definition of the syndrome may be attributed to the debate between Bálint and Holmes, reactivated later by Goldberg and Andersen. Whether there is a deficit of oculo-motor processes per se after parietal lesion is central to the debate between attentional (spatial coding or “where”, Colby and Goldberg, 1999) and intentional (motor planning or “how”, Andersen and Buneo, 2002) interpretations of the function of the posterior parietal cortex even in the non-human primate literature. The theory of a dissociation between perception and action substrates (Milner and Goodale, 1995, 2006) within the visual system has

certainly also pushed toward highlighting intrinsic visuo-manual guidance and oculomotor deficits, that would be dissociated from perceptual deficits that are lateralised or not in space (neglect and simultanagnosia, respectively). We will review the evolution of this terminology and underlying concepts below, highlighting unsatisfactorily aspects to the current classifications.

2-Historical reports and interpretation of visuo-motor clumsiness:

After Bálint and Holmes reports of patients suffering from bilateral damage, a few other case reports described “visual disorientation” or “optic ataxia” restricted to one hemifield. Riddoch (1935) described two cases with a left parietal lesion. Although these patients were not impaired in everyday life, visual pointing was altered in peripheral vision and this disorder increased with target eccentricity. In addition, these patients produced errors in estimating distance and absolute position. Brain (1941) described three patients with visuo-motor clumsiness. At least one of these patients can be considered to have exhibited “optic ataxia”: he showed hypometry when each of the two hands reached in peripheral vision on the right side.

Following the “renaissance” of the “Bálint syndrome” by Hécaen and De Ajuriaguerra (1954), the “rediscovery” of optic ataxia in Paris was initiated by Garcin et al. (1967). Their case report was highlighted as the first description of an “isolated optic ataxia”, i.e. presenting with only one element of the Bálint triad. The patient’s prehension deficit manifested itself when she looked straight ahead and was asked to reach in the left visual field. The deficit partially improved when she was allowed to fixate the object to be grasped. She also exhibited a tactile extinction on the left, constructional apraxia and minor oculomotor symptoms to the left. Interestingly, during the patient’s recovery from stroke, optic ataxia became restricted to peripheral vision from the 26th day and totally resolved from day 42nd.

Castaigne et al. (1971) described a case of optic ataxia with the two hands in the left visual hemifield, which manifested itself only in peripheral vision. They later described a patient with upper limb and lower limb ataxia in the left visual hemifield, which disappeared when gaze was free (Castaigne et al. 1975). As for most patients, Rondot et al.’s (1977) series of patients with ‘visuo-motor ataxia’ presented with a variety of associated deficits and no pure optic ataxia seemed to emerge from their series. However, several of these cases exhibit reaching problems “only in lateral vision” or “more errors were shown ... the further away the object was in the visual

field”. They also repeatedly described that after a first reaching movement the patient’s hand appeared to wander in space like that of a blind person.

The first analysis of the gesture in patients with optic ataxia was provided by Tzavaras et al. (1974): their patient exhibited optic ataxia with the right hand in the right visual field in peripheral vision. Tzavaras et al. (1974) clearly described that this patient underestimated eccentricity and overestimated depth, a pattern that was confirmed by numerous recent quantitative studies using proper motion analysis (Milner et al., 1999; Rossetti et al.; 2005; Coello et al.; 2007; Bartolo et al.; 2017). Tzavaras et al. (1974) went on to distinguish proximal and distal components of arm movements and proposed to distinguish, with analogies to apraxia (Osiurak et al., 2008; Mäki-Marttunen et al., 2014; Buxbaum et al., 2018), between left optic ataxia, where spatial errors would predominate, and right optic ataxia, where the distal finger movements would be impaired (Tzavaras and Hecaen, 1975; Tzavaras and Masure, 1976). However, most recent accounts have led to the notion that this was rather due to the intra-parietal dissociation between anterior and posterior regions (Binkofski et al. 1998).

In Jeannerod’s laboratory in Lyon, following the “Paris wave of optic ataxia” (Rossetti and Pisella 2018), Alain Vighetto’s doctoral studies (1980) used the Prablanc’s pioneering paradigm (1979) to specifically explore the oculomotor and manual behavior of three patients with optic ataxia. Prablanc’s paradigm allowed one to distinguish between static and dynamic visual information used to guide visual pointing by providing specific visual access to the static hand prior to movement, compared with dynamic visual feedback. This paradigm also focused on the effect of visual eccentricity by presenting peripheral targets while controlling for visual fixation. Vighetto’s studies showed that patients with optic ataxia exhibit only minor oculomotor impairments, but severe alterations of reaching by the hand contralateral to the side of the lesion (contralesional), in the contralesional peripheral visual hemifield (Figure 2A), and target localization errors increased with target eccentricity in the periphery of the contralesional visual field (Figure 2B). This study led to the conclusion that patients with optic ataxia produced gross errors when reaching in their contralesional visual hemifield, and exhibited more slightly impaired saccades towards the contralesional side. Yet, these patients performed accurate reaching movements in central vision (Vighetto and Perenin 1981). Some of this dedicated series of experiments was

extended and published later (Jeannerod et al. 1986, Perenin and Vighetto 1988). In an influential paper that has remained the landmark publication on optic ataxia because of the number of patients included and the broadness of the explorations described (Perenin and Vighetto 1988), clinical and psychophysical investigations of ten patients with optic ataxia are described. Optic ataxia is described as the difficulty in performing gestures toward the contralesional visual field (field effect), and/or with the contralesional hand (hand effect), in the absence of primary visual, proprioceptive or motor disorders. Performance was video-recorded (Figure 3) and rated on flight, and at the reaching end, such that ‘corrected’ (observed only in-flight) and ‘non-corrected’ (observed both in-flight and upon movement termination) errors could be distinguished. The key findings from this paper are that: 1) the largest number of errors are observed when the patient directs a movement with the contralesional ataxic hand towards the contralesional “ataxic” visual hemifield; 2) errors of intermediate severity are observed when the patient directs the healthy hand towards the contralesional “ataxic” visual hemifield, and the ataxic contralesional hand towards the healthy visual hemifield; and, 3) movements performed with the healthy hand towards the healthy visual hemifield are normal. Another aspect of Perenin and Vighetto’s (1988) article is that they examined visually-guided hand movements in several conditions, including central, peripheral and foveal vision. Central viewing corresponded to trials when the target was presented in the central zone of the visual field, albeit not in foveal vision while foveal vision corresponded to free gaze condition. As shown on their famous figure (reproduced here in Figure 4), patients produced large errors in their contralesional peripheral visual hemifields and this deficit tended to be larger when they used the contralesional hand. Except for patient 3, who presented with a very extensive left cortical and subcortical lesion and a number of associated deficits (hypokinesia, loss of right hand preference, ideomotor, ideational and constructional apraxia, body schema alteration, autotopoagnosia, abnormal limb posture at rest, and unilateral neglect), all patients exhibited only corrected errors in the central part of their visual hemifield, i.e. their potentially inaccurate initial trajectory was fully corrected before the end of the reach. The performance obtained for foveal vision was not plotted in the initial paper but quantitative data tables were provided. These results are shown as additional data in figure 4 (circles): no significant error was produced when the target was fixated. In addition, perceptual performance of the patients was also described, although not plotted as a figure, which might explain why this crucial information has

long been neglected (for example in Goodale and Milner 1992, Milner and Goodale 1995). As a matter of fact, patients exhibited severe perceptual impairments in peripheral vision. However, the main message that was (mis)taken from these studies was that the core deficit would specifically involve the visuomotor interface (e.g. Goodale and Milner 1992, Jeannerod and Rossetti 1993; Milner and Goodale 1995; Rossetti 1998). In the context of the dual stream theory of the visual brain (Milner and Goodale, 1995), research on optic ataxia has focused primarily on visuo-motor functions (“How”) and has largely ignored visuo-spatial functions (“Where”). Various aspects of the visuo-motor deficits have been studied in laboratory conditions, which have led to questioning and revisiting optic ataxia. Specifically, investigators have put forward the ideas that optic ataxia is observed 1) in temporal constraint, i.e. more with immediate than with delayed actions (Milner et al., 1999; Rossetti et al., 2005; Revol et al., 2003); 2) in spatial constraint, i.e. when the action has to be guided with the target location and/or the hand in peripheral visual space since it occurs preferentially in an oculo-centric reference frame (Khan et al., 2005, 2007; Dijkerman et al., 2006; Blangero et al; 2007, 2010a; Granek et al., 2012, 2013); and, 3) in response to target jumps triggered at movement onset (hand “automatic pilot”, see Pisella et al., 2000; Gréa et al., 2002; Blangero et al., 2008, McIntosh et al., 2011), a condition combining these temporal and spatial constraints.

These investigations have highlighted the perceptual deficits that contribute to optic ataxia (e.g. Rossetti et al., 2005, 2010). With the “rise and fall” of the dual stream theory (Rossetti, Pisella, McIntosh 2017), the possibility of a functional relationship between the visuo-motor deficits of patients with optic ataxia and their perceptual deficits has been put forward (Pisella et al. 2007, 2009) and specifically tested (Striemer et al., 2009; McIntosh et al. 2011; Medina et al., 2020). For example, Medina et al. (2020) described a patient who presented with visually-guided misreaching for targets left of fixation but not to the right of fixation. The authors also presented two small circles in succession in either the same location or offset at varying distances, and asked whether the two circles were presented in the same or different position. The patient was significantly more impaired in judging these stimuli when presented to the left of fixation compared with the right, providing evidence for a perceptual localization deficit after a dorsal stream lesion. In the contralesional visual field, saccade and reaching movements distinguish less between targets locations as target eccentricity increases (Gaveau et al. 2008; Blangero et al., 2010a; Vindras et al., 2016), as if spatial

resolution was pathologically decreasing, causing an apparent “compression” of space. It is thus tempting to recast optic ataxia as a disorder of visual attention (Pisella et al., 2007, 2009). Indeed, since attention enhances spatial resolution (Yeshurun and Carrasco 1998), visual attention impairment could explain the difficulty of patients with optic ataxia to report the occurrence of target changes in location, size and orientation in peripheral vision (Pisella et al., 2009; Medina et al., 2020). It has also been shown that attention increases contrast sensitivity (Carrasco et al., 2000), which could explain the slower detection of a visual target in the contralesional visual field (e.g. prior entry of ipsilesional visual information) in the Posner’s (1980) covert attention paradigm (Striemer et al. 2007). Furthermore, by boosting the spatial resolution, the strength and the quality of neural signals evoked by an object, attention may effectively provide a more fine-grained sample of the object’s features. Accordingly, impaired selective attention in the contralesional visual field may also explain the perceptual deficit of optic ataxia patients in a cued letter discrimination task (Khan et al., 2009, Blangero et al., 2010b).

3- Visuo-motor clumsiness: a deficit of simultaneous location processing?

Optic ataxia has been used over the last 20 years to argue in favour of dissociable functions within the dorsal (“How”) and ventral (“What”) streams of visual information processing and visuo-manual guidance (Jeannerod and Rossetti, 1993; Milner and Goodale, 1995; Rossetti and Pisella, 2002). The interaction between a field effect and a hand effect in patients with unilateral lesions was considered a key argument for the dorsal visual stream specialization for “vision for action” (Goodale and Milner, 1992; Jeannerod and Rossetti, 1993; Jeannerod 1994; Milner and Goodale, 1995). For example, similar to Bálint’s patient who presented a misreaching deficit mainly visible in the left visual field with the left hand, the misreaching of the patient described by Jackson et al. (2005) was confined to movements directed to nonfoveal targets executed using his right limb. Such observations led the authors to consider that explanations of optic ataxia based upon either only perceptual or only motor deficits could be ruled out and thus that the deficit of optic ataxia lies at the visuo-motor interface.

We instead consider that field and hand effects could be additive, and optic ataxia can therefore be explained by a combination of dissociable perceptual *and* motor components (Pisella et al., 2006). More precisely, the perceptual component corresponds to the field effect and explains the mislocalisation of the target, visual or

from another sensory modality, represented in eye-centered coordinates. The “motor” component corresponds to the hand effect and arises from a mislocalisation of the hand from an eye-centred proprioceptive-spatial transformation. Both components involve multimodal eye-centred spatial representation and may therefore result from a unique core deficit. However, we reported that a patient exhibited an isolated hand effect (Pisella et al., 2006) leading to misreaching errors only when monitoring his hand movement in absence of direct vision of his hand, e.g. in the dark or through a mirror (“mirror ataxia” Binkofski et al. 1999). Moreover, Blangero et al. (2009) have shown that patients exhibiting larger field effect had more posterior lesions and patients exhibiting more hand effect had more anterior lesions.

We therefore propose to replace the idea of a deficit of visuo-motor transformation (“How”) by a combination of at least two eye-centred mislocalisations deficits (“Where”):

1) In the contralesional visual field, targets are mislocalised toward the gaze position with a reliable hypometric error which increases non-linearly with target visual eccentricity (Blangero et al., 2010a; Vindras et al., 2016). These errors observed in the contralesional oculocentric hemispace can be modeled by mathematical equations modelling central magnification in visual maps of the superior colliculus or of the primary visual cortex (Vindras et al., 2016). We therefore suggest that the parietal cortex, in which such central magnification is not observed, and which is damaged in optic ataxia, is crucially involved in the re-magnification of compressed representation of contralateral peripheral space. The oculocentric location occupied in external space by a given hand is computed from proprioceptive signals in the left parietal cortex when the hand lies in the right oculocentric space and vice-versa. In case of parietal damage, this oculocentric proprioceptive-spatial representation becomes similarly hypometric and directed toward gaze position.

2) In addition, the oculocentric location occupied in external space by the contralesional hand is largely miscomputed irrespective of where the contralesional hand acts. Indeed, Blangero et al. (2007) have shown in two unilateral optic ataxia patients that the ipsilesional hand is mislocated when it lies in the contralesional space, but the contralesional hand is more largely mislocated wherever it lies (with errors still modulated by the oculocentric space where it lies).

Based on electrophysiological recordings in monkeys, Battaglia-Mayer and Caminiti (2002) proposed that optic ataxia arises from the breakdown in the tuning

fields of parietal neurons integrating spatially congruent retinal, eye, and hand position signals for coordinated eye and hand movements. However, the classical observation in the acute phase of optic ataxia is magnetic misreaching: patients systematically reach where they look instead of reaching to their peripheral goal (Carey et al., 1997; Jackson et al., 2005). Note that when the patient starts to recover, or when this magnetic misreaching is prevented by requiring bimanual reaching of two simultaneous objects while looking at one as in Jackson et al. (2005), the misreaching turns into a classical optic ataxia pattern, i.e. the reach ends between the object location and the gaze position. Jackson et al (2005) therefore argued that this behaviour is actually a coordinated eye-hand movement and that the underlying cause of optic ataxia is failure to simultaneously represent spatially incongruent retinal, eye and hand positions signals to produce non-standard visuo-motor transformations (uncoordinated eye-hand coordination). Starting a hand movement toward a visual goal selected from peripheral vision before initiating a saccade to it is a classical non-standard visuo-motor transformation of everyday life that patients with chronic optic ataxia tend to spontaneously avoid (Gaveau et al., 2008). Other non-standard visuo-motor transformations similar to using a computer mouse have been specifically studied by Granek et al. (2012) and optic ataxia patients use multiple saccades between the hand and the visual target in these specific conditions, while control individuals stabilise their gaze on the visual target and monitor their hand movements using peripheral visual and proprioceptive feedback.

In an fMRI task, Beurze et al. (2010) required their subjects to perform a reaching task while systematically varying hand starting position, target location and/or gaze direction on a trial-by-trial basis. They were able to distinguish activity indifferent regions of the parietal and posterior frontal cortices depending on whether the representation of target and hand locations was relative to gaze or to the body (Figure 5). The results suggest that, in the posterior parietal cortex, spatially contiguous neuronal populations encode target and hand locations in different frames of reference, with a dominance of gaze-centred representations.

Jackson et al. (2018) further investigated this ability to directly compare multiple and dissociated simultaneous spatial information so as to compute the difference between them. They investigated how individuals presenting with optic ataxia performed on a bimanual haptic matching task. Unlike neurologically healthy controls who perform the task with high levels of accuracy, patients with optic ataxia

were unable to perform the task, whether the bar to be matched was presented haptically or visually.

To sum up, we have reviewed here evidence that visuo-motor clumsiness may arise in specific conditions in which multiple locations (eye, hand and/or target not aligned) have to be simultaneously represented and integrated.

4- Historical descriptions and interpretation of ocular and perceptual/attentional deficits

Bálint clearly interpreted ocular symptoms as attentional deficits; his description of ‘Seelenlähmung des Schauens’ included both his patient’s difficulty to find visual targets with his eyes (wandering of gaze) and of visual capture by the target once fixated (spasm of fixation). As emphasised by de Renzi (1989), Holmes (1918) added an oculo-motor deficit per se to his description of patients with parietal lesions, which had been excluded by Bálint for his patient. This oculo-motor disorder described by Holmes (1918) and later labelled ocular motor apraxia (Cogan and Adams, 1953) has often been incorporated into the description of Bálint’s syndrome, and confounded with the ‘Seelenlähmung des Schauens’ most often translated in English as a ‘psychic paralysis of gaze’. Hence the attentional disorders that were initially associated with this element of the triad have been grouped together with the lateralised attentional deficits described by Bálint (1909) which has been easily ascribed to unilateral neglect (e.g. Hecaen and De Ajuriaguerra, 1954). As de Renzi (1989) rightly pointed out long ago, ‘psychic paralysis of gaze’ appears to be an erroneous translation of Bálint’s description. The alternative translation proposed by Hecaen and De Ajuriaguerra (1954) - psychic paralysis of visual fixation, also known as spasm of fixation – provides an alternative emphasis of this symptom, and suggests that it can be clearly dissociated from intrinsic oculo-motor disorders, as already argued by Bálint. Husain and Stein’s translation (1988) of Bálint’s description for the psychic paralysis of gaze corresponds to a restriction of the patient’s “field of view, or we can call it the psychic field of vision”. This latter version also emphasised a visual-attentional rather than an oculomotor deficit. Altogether these apparent subtleties have given rise to several systematisation of the oculo-motor, perceptual and attentional aspects of the syndrome. For example, Hecaen and De Ajuriaguerra (1954) distinguished the “psychic paralysis of fixation” (or inability to look towards a peripheral target) from the disturbance of attention. However, these authors further differentiated between two types of attention disorders. First, they outlined a general impairment of attention that corresponded to a

selective perception of foveal stimuli. But they also emphasised the presence of a lateralised component of the attention deficit which can now be described as unilateral neglect. Alternatively, de Renzi (1989) distinguished two types of visual disorders in Bálint's description. One of these corresponds to the lateralised deficit known as unilateral neglect, and the other to a non-lateralised restriction of visual attention, which can be partly interpreted as simultanagnosia. His interpretation of the "Bálint –Holmes syndrome" excluded the presence of intrinsic visuo-oculo-motor deficits. Rizzo and Vecera (2002) and Rizzo (1993) on their side, focused their analysis on a "spatial disorder of attention", corresponding to simultanagnosia (Wolpert, 1924), and on the "psychic paralysis of gaze", which they distinguished from oculomotor deficits and assimilated to 'spasm of fixation' or 'ocular apraxia'. To these symptoms these authors associated two additional attentional disorders: unilateral neglect and concentric restriction of the attentive field (simultanagnosia).

Gaze apraxia is characterized by severe abnormalities of eye movement generation in response to visual targets in space, in the absence of ocular motor palsy, ascertained by full reflexive eye movements. Eye movement recordings usually show several abnormalities, such as prolonged latency, fragmentation and hypometry of saccades, fixation drift, and absence of smooth pursuit (Michel et al., 1963; Girotti et al., 1982). Both the accuracy of fixation and saccadic localisation are impaired, and spatio-temporal organisation of eye displacements does not fit with the spatial configuration of the scene to be analysed (Tyler, 1968). However, it is important to note that this abnormal saccadic behaviour is observed in rich (natural) environment scenes, which require continuous selection between concurrent stimuli. In a simpler context, for example when the task is to direct the eyes to a peripheral LED in the dark, saccades may be normal (Guard et al., 1984). Interestingly this saccadic behaviour is also observed after inactivation of lateral intraparietal area (LIP) in monkeys (Li et al., 1999; Wardak et al., 2002).

In our view, two main oculo-motor disorders emerge from the clinical descriptions: one in time and one in space. First, the more consistent observation in these patients is -in cases of unilateral lesions- an increase in latency for saccades in the contralesional direction or -in cases of bilateral lesions- a poverty of eye movements, that may culminate in a condition often referred to as "spasm of fixation", or "visual grasp reflex". Patients stare open-eyed, with the gaze being locked to the detail that they are fixating. Second, patients are usually able to move their eyes on verbal

command, while they are impaired in performing visually-guided saccades. The more the eye movement relies on attention and complex visual processing, the less likely it is to be triggered. Along these lines, visual search behaviour is particularly vulnerable. Hence, when patients are asked to move their eyes to a target suddenly appearing in the peripheral field, they may generate no movement, or initiate wandering eye movements, that consist of erratic, and usually hypometric displacements of the eyes in space, ending with incidental acquisition of the target.

A spatial disorder of attention (Bálint, 1909), a restriction (De Renzi, 1989), a shrinkage of the attentional field (Michel and Henaff, 2004), or a disorder of simultaneous perception (Luria, 1959) are equivalent terms labelling a complex symptom, which can be viewed as a symmetrical or asymmetrical limitation of visual-spatial attentional resources. Patients do not seem to perceive visual targets located away from a small area, despite preserved visual fields. For example, we have observed that patients with bilateral lesions looking at their palm may not perceive their fingertips. They exhibit a reduction of “useful field of vision”, operationally defined as the field of space that can be attended to while maintaining central fixation (Rizzo and Vecera 2002). Shrinkage of the attention field reduces detection of multiple objects and may restrict patients’ perception to one item at a time, literally: simultanagnosia. Bálint’s patient himself was not able to perceive the light of a match while focusing on a cigarette until he felt a burning sensation. This limited capacity of attentive vision for only one object attracting the focus of attention at a time does not depend upon the size of the object. As a general consequence, patients fail at any time to perceive the totality of the items forming a visual scene. Performance for counting objects is altered accordingly. The shrinking of the attentional field can be either concentric in the case of bilateral posterior parietal damage (simultanagnosia) or with a contralesional bias in the case of unilateral posterior parietal damage (unilateral spatial neglect). Nevertheless, as in Bálint’s initial case, bilateral damage can be asymmetric and produce both a reduced attentional field (simultanagnosia) and a unilateral bias of attention orientation that can be rightward as well as leftward (Pisella et al., 2015). As an illustration, Figure 6 shows ocular recording of two patients with neurodegenerative bilateral posterior parietal damage during a task consisting of counting the number of dots presented on the screen. The first patient keeps the eyes only on the right dots, while the second keeps his eyes on the left dots. This distinct behaviour may correspond to distinct lateralisation of their degeneration. Description or copy of complex figures

is also laborious and slow, patients focusing serially on details, apprehending portions of the pictures with a piecemeal approach, but failing to switch attention from local details to global structures. Again, this reduction of attentional field can be associated or not with a unilateral orienting bias. Figure 7 shows the figure copy of patients with non-lateralized Bálint's syndrome to be compared with the same figure copied by a clinical neglect patient with additional rightward orienting bias leading him to mislocalise elements more toward the right side of the copy.

In Posner's paradigm, patients with posterior parietal lesion exhibit defects in shifting spatial attention (Verfaellie et al., 1990), or in disengaging attention from fixated objects (Rizzo and Vecera, 2002), a difficulty which may be central for the visual grasp reflex to occur. Michel and Hénaff (2004) have provided a comprehensive examination of a patient (AT) with bilateral PPC lesion whose initial Bálint's syndrome had been reduced 20 years post onset to bilateral optic ataxia and a variety of attentional deficits that can be interpreted as a concentric shrinking of the attentional field. An experimental demonstration of this reduced functional visual field was provided in another case study where patient IG, who had bilateral lesions of the superior parietal lobule (SPL-IPS network), was just as slow to find the O among Qs when she performed the visual search with or without a gaze-contingent visible window of 20° diameter (Khan et al. 2016). In contrast, the presence of the window dramatically reduced control participants' search times, demonstrating that the window restricted their normally wider attentional window.

In summary, there is a wealth of converging evidence inviting us to view both the visual grasp reflex and the wandering of gaze as direct consequences of this shrinking of the attentional field; if one does not perceive any visual target in the periphery, one will not perform a saccade to it. Hence gaze will remain anchored on a target once acquired (visual grasp reflex). If one is forced to find a specific target in the visual scene, then one would have to make 'blind' exploratory movements as it is the case in tunnel vision, explaining the wandering of gaze. This shrinking of the attentional field also logically reduces the size of exploratory saccades thus increasing the number necessary to find a target (Figure 8a). Since an attentional deficit can explain the large variety of ocular disorders (spasm of fixation, wandering of gaze, hypometry and increased latency of saccades), we therefore propose to consider them as multiple behavioural manifestations of an underlying attentional disorder.

5-Simultanagnosia/Extinction : a deficit of simultaneous location processing?

Khan et al. (2016) reported that patient IG with bilateral lesions of the SPL-IPS network performed slower than controls only in visual search tasks involving symbols made by a spatial combination of several lines (Figure 9). For example, she was slow to detect the presence of an item “O” among multiple items “Q”. In contrast, she was as fast as controls to find a red disk among red squares and green disks (colour-shape conjunction search). In peripheral vision, we perceive the perceptual elements surrounding us, but not their precise localization (Balas et al. 2009; Pelli & Tillman, 2008; Rosenholtz et al., 2012 a,b). A disk or a plain square are items made up of a single element. In contrast, a symbol “Q” is made by a circle and a line, such that without covert attention we cannot organize these multiple elements into respective and recognizable objects. Khan et al. (2016) concluded that shrinking of the functional field of attention in patients with bilateral SPL-IPS lesions, only occurs in visual search conditions requiring spatial binding of separable elements, i.e. conditions of spatial uncertainty. This shrinking could be mimicked by a gaze-contingent display producing a reduced visible window and thus a limitation of the number of elements that the patient could process simultaneously. In order to determine the number of elements that patient IG could process simultaneously in one single fixation, the Global Report task was also tested: strings of 5 letters were presented for 200 ms in central fixation (Valdois et al., 2019). Note that acuity, binocular vision, single letter identification, temporal threshold, and multi-letter sequential report were reported to be fully normal in patient IG, ruling out the possibility of a general slowing of visual perception and of a reduced visual short-term memory capacity following bilateral SPL lesion (Valdois et al., 2019). In the Global Report task, patient IG could report only a restricted number of letters within the string (reduced visuo-attentional span). This visuo-attentional span deficit in IG was similar to the one observed in developmental dyslexia which is specific to symbols and disappears when dyslexics are required to report the colour of five dots in a row (Valdois et al., 2012).

Vialatte et al. (submitted) further explored IG’s visual processing of plain objects (colored disks) versus objects consisting of separable lines (letters), presented in isolation (single object) versus simultaneous presentation (a triplet of objects). In peripheral vision, identification of the isolated object was normal, but dropped to chance level when it was surrounded by distracters, irrespective of eccentricity and

spacing. It was then tested whether this poor performance in identification of the central object of a triplet could reflect a deficit in processing objects' relative location within the triplet (for colored disks), aggravated by a deficit in processing the relative location of each separable line (for letters). Performance improved when IG only had to detect the presence of a specific coloured disk within the triplets rather than to identify the colour of the central one, but no improvement was observed for letters. These results can be interpreted in the framework of our hypothesis. Indeed, each color disk is composed of 1 element, and therefore a deficit of spatial localization affects detection performance only when the task requires perceiving the spatial relationships between objects. However, letters are composed of a spatial configuration of several separable elements, so the identification of each letter by itself already requires understanding such spatial relations. When the stimulus contains only a single letter, the uncertainty about the spatial relations is relatively small and patient IG manages to perform optimally (likely relying more than controls on prior knowledge). However, when there is more than a single letter, there are many more elements and possible spatial relations, and therefore uncertainty considerably increases and accordingly detection performance remains considerably reduced. Additionally, the inability to identify the target was alleviated when the distracters were identical letters "X", thereby reducing the number of possible lines binding. We concluded that a bilateral SPL sparing is necessary to process the spatial relations between multiple separable elements presented simultaneously, both between and within objects. In other words, a localization deficit for simultaneous visual elements potentially explains the deficit of perception (simultanagnosia) consecutive to bilateral SPL damage (Figure 10).

Another experiment adds weight to the idea that SPL damage causes a deficit of relative mislocalisation of visual elements. Pisella et al. (2013) report a clinically asymptomatic patient with a focal, unilateral SPL lesion. When tested with grey dots flashed simultaneously bilaterally or unilaterally in the left or the right visual field (classical visual extinction assessment), the patient was able to detect the presence of dots presented unilaterally in both visual fields but failed to detect the presence of the left dot in a condition of attentional competition between the two hemifields. However, when the visual complexity of the stimulus was increased by using letters, the patient began to fail to detect the unilateral letter presented in the left visual field. Moreover, when the difficulty of the task was increased by requiring both detection and identification of the letters, the patient no longer exhibited a visual extinction pattern

but a full spatial neglect pattern, i.e. he systematically failed to report the identity of the unilateral letters presented in his left visual field. In sum, presenting multiple simultaneous elements instead of plain dots, and requiring subjects to bind these elements spatially can lead to a full lack of report of left-sided unilateral stimuli in patients with apparent visual extinction (Figure 11).

Note that patients with lesion acquired at adulthood are nevertheless able to read long well-known words, even presented briefly in peripheral vision. This ability is explained by the use of their acquired visual lexicon developed at the level of the visual word form area of their (spared) ventral visual stream. However, a posterior parietal cortex dysfunction from the infancy would prevent to constitute such a visual lexicon and would cause developmental dyslexia (Valdois et al. 2019).

7-A renewed model of PPC organisation

The standard view of the PPC and Bálint's syndrome in the predominant model of Milner & Goodale (1995) is that the most superior part of the dorsal stream is devoted to action, as illustrated by optic ataxia (This view has been challenged by numerous authors e.g. Rossetti et al. 2015; 2017). In this context, the most inferior part of the PPC is more intermediate between "vision for action" and "vision for perception", with unilateral neglect as an example. Converging evidence now tends to distinguish the lateralised and non-lateralised components of unilateral neglect both behaviourally and anatomically, linking the well-known lateralised bias of neglect to the dysfunction of the superior parieto-frontal network and the newly defined non-lateralised deficits to the inferior parieto-frontal network and temporo-parietal junction. Indeed, the consequences of PPC lesions in humans suggest that symmetrical and asymmetrical (right-hemispheric dominant) parietal visuo-spatial maps co-exist. Transcranial magnetic stimulation applied unilaterally to the superior parietal lobule (SPL) symmetrically causes 'contralesional visual extinction' (Pascual-Leone et al., 1994; Hilgetag et al. 2001): in bilateral crossed-hemifield visual presentation of two simultaneous objects, only the ipsilesional object is reported. The spatial representations of the SPL-IPS network, whose damage potentially induces contralesional optic ataxia and contralesional visual extinction, are mainly fine-grained egocentric (eye-centred) maps of the contralesional visual field (Blangero et al. 2010a) and are fairly symmetrical (Blangero et al. 2010a; Pascual-Leone et al. 1994, Hilgetag et al. 2001). In contrast, the 'landmark' tests involve allocentric localization processes

specific to the right hemisphere. Patients with severe and chronic neglect usually have right unilateral lesions and demonstrate a rightward bias during midline judgement. Accordingly, brain imaging (Fink et al 2000) and TMS (Fierro et al. 2000) studies have revealed a specialized and lateralized network involving the right IPL and left cerebellum when performing the perceptual line bisection task. The right IPL (IPL is used here to distinguish it from SPL and comprises a large functional region in the right hemisphere including also the superior temporal gyrus and the temporo-parietal junction) is also specifically involved in processes such as sustaining and reorienting attention to spatial locations across the entire visual field, useful in visual search tasks (Ashbridge et al. 1997; Corbetta et al., 2000, 2005; Ellison et al., 2004, Mannan et al. 2005; Shulman et al., 2007; Muggleton et al., 2008; Malhotra et al., 2009). Since by definition patients with neglect: 1) have a deficit of attention for contralesional space; and, 2) are impaired in visual scanning tasks of line bisection and cancellation, then the syndrome can be interpreted as a combination of left visual extinction (produced by damage of the right SPL) and visual synthesis deficits in the entire visual field caused by damage to the right IPL (Pisella and Mattingley, 2004).

One may further speculate that bilateral lesions of the SPL in humans may cause Bálint's symmetrical shrinkage of attention, 'Seelenlähmung des Schauens', later called "simultanagnosia" (Wolpert, 1924, Luria, 1959), in which the patient reports only one object among two or more in a symmetrical manner, i.e. not systematically the right or the left one. Accordingly, the symptoms of simultanagnosia may simply appear as a non-spatial extinction restricting visual perception to seeing only one object a time, even though another overlapping object may occupy the same location in space (Luria, 1959; Humphreys et al., 1994, Husain, 2008), i.e. bilateral visual extinction without more severe spatial disorganisation. This might explain the differential severity observed between patients with bilateral SPL lesions following stroke, in which they exhibit bilateral optic ataxia and subclinical simultanagnosia manifest as a shrinking of visual attention (e.g. patient AT: Michel and Henaff, 2004; patient IG, Khan et al., 2016). In severe posterior cortical atrophy, simultanagnosia might be worsened by damage extending into the right IPL, thereby affecting the maps in which the whole of extra-personal space is represented and on which the remapping mechanisms may specifically operate in order to integrate visual information collected via multiple snapshots into a visual gestalt.

To sum up the model (figure 12) as this stage, damage to the left and/or right SPL-IPS network impairs covert attention to the contralesional hemifield hence affecting spatial resolution, with consequences for movement accuracy and perceptual identification. Damage to the right IPL-STG network leads to mislocalisations of another nature, allocentric, across time and saccades (visual synthesis).

The observation of a young patient with an extremely focal lesion of the right inferior parietal lobule (IPL) caused by a steel nut penetrating his brain during an explosion (case 1 in Patterson and Zangwill 1944) provides one additional important piece of information about the anatomico-functional organisation of the right PPC. The right IPL (supramarginal and angular gyri) is the region the most commonly associated with clinical neglect (Vallar and Perani 1986; Mort et al., 2003). The patient of Patterson and Zangwill (1944) exhibited left-sided extinction and ‘a complex disorder affecting perception, appreciation and reproduction of spatial relationships in the central visual field of vision’ (Patterson and Zangwill 1944, p. 337). This ‘piecemeal approach’ was associated to a lack of ‘any real grasp of the object as a whole’ (p. 342) that ‘could be defined as a fragmentation of the visual contents with deficient synthesis’ (p. 356). This defect of visual synthesis in central vision was qualitatively similar to the consequences of bilateral lesions of the PPC that cause simultanagnosia. It is striking that the behavioural impact of this focal, restricted unilateral lesion was almost equivalent to a full Bálint’s syndrome with ipsilesional biases, an extreme restriction of attention and a deficit of establishing spatial relationships and integration of visual snapshots as a whole (that has been related to spatial working memory or visual remapping impairments in the whole visual field: Husain et al., 2001; Driver and Husain, 2002; Pisella et al., 2004; Pisella and Mattingley, 2004). In accordance with this neuropsychological observation of Patterson and Zangwill (1944), Corbetta et al. (2005) developed a model based on the notion that right inferior parietal-frontal network is activated by unpredicted visual events throughout the whole visual field and that superior parietal-frontal eye field network of attention influences the top-down stimulus-response selection in the contralesional visual space. In their model, the lesion of the right inferior parietal-frontal network, via a “circuit-breaking signal”, decreases activity in the ipsilateral superior parietal-frontal eye field network and consequently biases the activity in the occipital visual cortex toward the ipsilesional visual field. In other words, this model predicts that the lesion of the right IPL would indirectly

decrease functional activity in the right SPL and thereby causing rightward attentional bias (arrow from the right IPL to the right SPL on the model of Figure 12).

According to previous results (Khan et al. 2009, Blangero et al. 2010b), visual extinction tests using letter identification (multiple elements) may be sensitive enough to uncover an ipsilesional attentional bias (which is the lateralised component of neglect) in patients with unilateral SPL-IPS dysfunction caused directly by a lesion of the SPL or indirectly by a lesion of the right IPL inducing an imbalance between the right and the left SPL (Corbetta et al., 2005). It seems that prism adaptation, and most other treatments of neglect (Rossetti et al. 2015; Rode et al. 2017), improve the lateralised component common to neglect and extinction patients, probably by acting on this imbalance (Pisella et al., 2006b; Luauté et al., 2006, Martin-Arevalo et al. 2016, 2019). An attentional orienting bias caused by parietal imbalance would also explain the paradoxical improvement of neglect (following right-hemisphere damage) by subsequent damage of the left hemisphere (Sprague effect, see Weddell, 2004 for a recent reference). The other (non-lateralised) components of neglect rely on the right IPL and its general function of visuo-spatial synthesis and might be more resistant to treatments (but see Rode et al., 2006; Schindler et al., 2009).

8-Hemineglect: included or not included in the syndrome?

Given the rightward attentional bias included in the initial description of Bálint's (1909) patient but the exclusion of this lateralised aspect in many recent definitions of the syndrome (e.g. Kirshner and Lavin, 2006; Denburg and Tranel, 2009; Kaufman et al., 2017), should we consider that hemineglect falls within Bálint's syndrome or not?

In terms of eye movements, patients with classical unilateral neglect have also been reported to exhibit late and hypometric leftward saccades (e.g. Girotti et al., 1983; Walker and Findlay, 1996), while their saccadic accuracy is reported normal elsewhere (Behrmann et al., 1997). Niemeier and Karnath (2000) have shown that hypometry can be observed only for reflexive saccades triggered in response to left (affected side) peripheral target presentation and that self-generated leftward and rightward saccades are equivalent in amplitude in a condition of free ocular exploration of visual scenes. By contrast, the strategy of exploration is clearly impaired in patients with unilateral neglect (e.g. Ishiai, 2002). Altogether, no available data seems to rule out that these

saccadic deficits in neglect patients result from a deficient allocation of attention to visual targets in the left periphery.

At the anatomical level, there is no clear consensus about the causative location for spatial neglect (e.g. Vallar & Perani 1986, Karnath et al. 2001, Mort et al. 2003, Karnath & Rorden 2012, Lunven & Bartolomeo 2017). Lesions of the SPL-IPS network produce a visual saliency deficit for stimuli in the contralesional visual field that can be either symmetrical or asymmetrical. In the symmetrical case, bilateral lesions induce a concentric reduction of the attentional field and in the asymmetrical case bilateral or unilateral lesions produce an attentional bias lateralised in space (Figure 12). The rightward bias of attention is therefore not the one component of unilateral neglect that can be differentiated from Bálint's syndrome. Rather the non-attentional symptoms, non-lateralised in space, such as "revisiting behaviour", described in patients with unilateral neglect who repeatedly visit items in an array (Wojciulik et al., 2001; Husain et al. 2001). Revisiting ocular behaviour has therefore been ascribed to an impairment of short-term memory for spatial location of items already explored (Driver and Husain 2002) or a visual remapping impairment leading to mislocalisations and/or lack of visual consciousness (Pisella and Mattingley, 2004), associated with right-sided damage to the IPL–STG network (Pisella et al. 2004, review in Pisella et al., 2011). As mentioned above, visual neglect is often excluded from the triad of Bálint's syndrome and separately attributed to damage to the inferior parietal lobule or superior temporal gyrus. This parietal component, non-lateralised in space (see Pisella et al. 2004), appears a crucial one to observe clinical symptoms of hemineglect in everyday life (eating, dressing, cooking, reading...). However, it is not specific to spatial neglect, since it can also worsen simultanagnosia (Pisella et al., 2015) by preventing patients with a reduced attentional field from guiding their ocular exploration of space in a coherent manner when tasked with visual search (as in Figure 8B, contrasting with Figure 8A). Such patients appear to lack memory of the locations that they have already applied the gaze/attention to (spatial working memory) and also the spatio-temporal integration of the various visual snapshots collected (visual remapping), they fail to explore space efficiently and to apprehend the environment around them. Patients with severe neglect or severe simultanagnosia may have in common not only the exploration of space in a serial fashion (because of a truncated attentional field) but also have to focus several times on the same object because they are lost in space. This spatial disorganisation (due to impaired spatial working memory

or visual remapping) worsens the functional consequences of their (concentric or contralesional, respectively) attentional restriction. Such “revisiting behaviour” has been observed in patients with bilateral posterior cortical atrophy, leading them for example to count more dots than presented, while others (not exhibiting any revisiting behaviour) tend to count fewer dots than presented (Pisella et al. 2015).

Russell et al. (2010) have proposed that the clinical condition of pure spatial disorganisation is “constructional apraxia”, revealed by disorganised reproductions of complex figures in 2D (drawing tests) or 3D (blocks tests). This label is rarely mentioned in the context of Bálint’s syndrome (see however Michel & Hénaff’s (2004) clinical description of patient AT) but it appears logically related to the piecemeal approach and the disturbance of visual orientation often described in these patients. Constructional apraxia patients were identified by Russell et al. (2010) as patients with right hemisphere stroke whose unilateral neglect symptoms have resolved but who have an inability to accurately copy drawings or three-dimensional constructions. Russell et al. (2010) demonstrated that these patients have recovered spontaneously from the first component of unilateral neglect (attentional bias) but the second component (spatial disorganisation) persists as an impairment of spatial memory across saccades. There is converging evidence that the anatomical substrate of spatial disorganisation corresponds to the right inferior parietal lobule. This region of the right hemisphere is crucial for complex visuo-spatial tasks involving a “visual synthesis” of detailed snapshots (Malhotra et al., 2009), such as the “landmark” tests which require the space between two objects to be mentally represented in order to judge whether a landmark object is closer to the right or to the left object (Ungerleider and Mishkin 1982, Bisiach et al., 1998; Fink et al., 2000; Fierro et al., 2000). Neglect patients with right IPL damage (Vallar and Perani, 1986; Mort et al., 2003) exhibit deficits of “visual synthesis” (visual space exploration and integration) that are not restricted to the contralesional hemifield (Wojciulik et al., 2001; Husain et al., 2001; Husain and Rorden, 2003; Pisella et al., 2004; Kennard et al., 2005; Husain, 2008). Indeed, the right IPL is conceived to be able to remap - and establish relationships between- locations throughout the whole visual field. Pisella and Mattingley (2004) have postulated that the human IPL may contain a whole-space map where oculo-centric remapping processes operate thereby allowing coherent “visual synthesis”. Human studies have implicated the right parietal lobe in visual remapping (Heide et al., 1995; Medendorp et al., 2003; Morris et al., 2007; Heide and Kömpf, 1998; Heide et al., 2001; Kennard

et al., 2005; Mannan et al., 2005, Van Koningsbruggen et al., 2010; Malhotra et al., 2009; Pisella et al., 2011). The lateralised remapping impairments reported in patients with visual neglect or after TMS applied to the right parietal cortex (review in Pisella et al., 2011) may result from the combination of the right IPL's specialisation for space and the ipsilesional bias of attention which additionally may alter the representation of contralesional visual stimuli. In contrast, remapping impairments may be expressed as a deficiency of visual synthesis and re-visiting behaviour without lateralised spatial bias in constructional apraxia (Russell et al., 2010) or in patients with severe simultanagnosia (Pisella et al. 2015).

In sum, the attentional and non-attentional components of visual neglect correspond to the two components of Bálint's syndrome resumed in Figure 12, and attributed to the SPL-IPS network and the right IPL-STG network, respectively.

Conclusion

We have argued that the full clinical picture of Bálint's syndrome (simultanagnosia, neglect and optic ataxia) can be accounted for by an impaired ability to accurately represent simultaneous localisations following asymmetrical, bilateral SPL-IPS damage. We have observed that the lateralised attentional bias (neglect) depends on the asymmetry of the bilateral lesions and tends to recover spontaneously leaving the patient with only two of the initial symptom triad.

If right parietal damage also includes the IPL, additional representational mislocalisations across time and saccades (spatial working memory and visual remapping impairments) increase the severity of the triad and probably reduce the ability to recover or compensate for them.

When only the right IPL is damaged, a syndrome of clinical neglect comprising both spatial disorganisation and left visual extinction is observed in the acute phase (as in Patterson & Zangwill's 1944 patient). The attentional bias is due to the temporary "virtual lesion" of the right SPL-IPS (Corbetta et al. 2005) and recovers to leave the patient with chronic constructional apraxia (Russell et al. 2010).

Figures legends :

Figure 1: Bálint depicted the lesion of his patient in schematic diagrams showing the lateral surface of the hemispheres.

Figure 2: A: Additive misreaching errors exhibited by patient with right optic ataxia when the pen is presented in his contralesional (right) visual field (**field effect**) and when he is required to grasp it with the contralesional (right) hand (**hand effect**). B: Effect of visual target eccentricity (distance relative to gaze fixation) on the signed amplitude of reaching errors (hypometric errors are negative: when visual targets are presented on the horizontal axis of gaze in the contralesional visual field, movements are hypometric when the patient do not reach far enough) in optic ataxia.

Figure 3: Images of a reaching movement made by patient presenting with right optic ataxia. Time is indicated in msec. Note that the patient is fixating straight-ahead (the camera) and reaching in peripheral vision. A full movement (including finger closure) is made to an erroneous location in-between the target and where he is fixating (hypometric movement). Then surprisingly the patient's wanders in space as if blind and then gives up. (From Vighetto 1980)

Figure 4: Percentage of reaching errors produced with the contralesional hand toward the left, central and right visual field (LVF, CVF, RVF) in 10 patients with unilateral PPC lesions (3 in the right and 7 in the left hemisphere). The mean (and standard deviation) percentage of errors of 5 control subjects (C) is presented for comparison. The participants were asked to reach an object presented by a experimenter standing in front of them while keeping the eyes fixed (histograms) or after foveating the object (circles). The dashed histograms correspond to uncorrected errors (i.e. the object was finally not acquired) whereas the blank bars correspond to the percentage of errors corrected during the execution. (Redrawn from Vighetto 1980 and Perenin and Vighetto 1988).

Figure 5: Relative contributions of gaze- and body- reference frames for target and hand position coding in the SPL-IPS network (anterior part of the intraparietal sulcus (aIPS), caudal part of the intraparietal sulcus (cIPS) and parieto-occipital sulcus (POJ)), and dorsal premotor regions (superior and inferior part) represented on an inflated brain surface. Stars indicate a significant difference between the peripheral and central reaching conditions. (Adapted from Beurze et al. 2010)

Figure 6: Schematic illustration of the oculomotor behaviour (saccades and drifts in blue and ocular fixations marked by red circles whose diameter increases with fixation duration) observed in two patients with posterior cortical atrophy during a task requiring them to count the number of dots (black disks) presented on a computer screen. In the top panel, four dots are presented with unlimited duration to the first patient. The patient is searching more dots on the right and seems to ignore the left one. The patient counts four dots due to ocular revisiting behaviour. In the bottom panel, three dots are presented with unlimited duration to the second patient. The patient is searching more dots on the left and seems to ignore the two most rightward ones. The patient counts three dots due to ocular revisiting behaviour. (Redrawn from Pisella et al. 2015)

Figure 7: Examples of copies of a Rey figure drawn by a patient with full Bálint's syndrome, a patient with constructional apraxia and a patient with clinical neglect.

Figure 8: Wandering of gaze with (bottom panel) or without (top panel) revisiting behaviour. Ocular traces (green) recorded during a visual search task consisting of finding the red disk among the red squares (the target usually pops out) in two patients with posterior cortical atrophy of different clinical severity. (Redrawn from Pisella et al. 2015)

Figure 9: Search times (reaction times to press the button) to find the odd target among 12, 24 and 48 distractors in four visual search tasks (A-D) recorded for a patient with simultanagnosia, bilateral optic ataxia and quadrantanopia in the right lower visual field (IG, green line) and for age-matched controls performing the tasks with (grey line) and without

(black line) a gaze-contingent quadrantanopic mask. Patient IG was significantly slower than controls with artificial quadrantanopia to find the target in the two balloon tasks (C,D) while she performed well in the two filled balloon tasks (A,B). (Redrawn from Khan et al. 2016)

Figure 10: Response accuracy to report the middle letter of the triplet (F, T or N, chance level =33%) in conditions of differential (plain lines) or identical (dotted lines) flankers in patient IG (simultanagnosia and bilateral optic ataxia following bilateral SPL-IPS network). The results are displayed for a middle target presented at 3° (blue), 7° (red) and 10°(green) of visual eccentricity, and varying spacing among letters within the triplet. As illustrated, the accuracy remained at chance level irrespective of visual eccentricity and spacing, except when the identical flankers drastically reduced the spatial uncertainty of the task.(from Vialatte et al. Cerebral Cortex 2021, accepted)

Figure 11: Response accuracy for left, bilateral and right brief target presentation observed in a patient with left extinction when he had to report the presence of a stimulus (dot or letter, in target detection and letter detection tasks, respectively) or to report the identity of the presented letters (letter identification). (Redrawn from Pisella et al. 2013)

Figure 12: Anatomico-functional model of the PPC organisation. The SPL-IPS network (blue) is symmetrically involved in covert attention and localisation in the contralateral hemifield. The IPL-STG network (yellow) is involved in the right hemisphere in visual synthesis (spatial working memory and visual remapping). A shadow represents a lesion. A black dot represents a functional hypoactivation (a virtual lesion, Corbetta et al. 2005). The upper part of the model concerns the effect of bilateral lesions, while the lower part displays the effect of unilateral lesions.

References:

- Andersen RA, Buneo CA (2002). Intentional maps in posterior parietal cortex. *Annu Rev Neurosci* 25 : 189-220.
- Ashbridge E, Walsh V, Cowey A (1997). Temporal aspects of visual search studied by transcranial magnetic stimulation. *Neuropsychologia* 35: 1121-1131.
- Balas, B., Nakano, L., & Rosenholtz, R. (2009). A summary-statistic representation in peripheral vision explains visual crowding. *Journal of Vision*, 9(12), 13.
- Bálint R (1909). Seelenlähmung des “Schauens”: Optische Ataxie, räumliche Störung der Aufmerksamkeit. *Monatszeitschrift Für Psychiatrie Und Neurologie* 25: 51–181.
- Bartolo A, Rossetti Y, Revol P, et al. (2017). Reachability judgement in optic ataxia: Effect of peripheral vision on hand and target perception in depth. *Cortex* 98: 102-113.
- Battaglia-Mayer A, Caminiti R (2002). Optic ataxia as a result of the breakdown of the global tuning fields of parietal neurones. *Brain* 125: 225-237.
- Behrmann M, Watt S, Black SE, et al. (1997). Impaired visual search in patients with unilateral neglect: an oculographic analysis. *Neuropsychologia* 35: 1445–1458.
- Beurze SM, Toni I, Pisella L, Medendorp WP (2010) Reference Frames for Reach Planning in Human Parietofrontal Cortex *J Neurophysiol* 104(3):1736-45.
- Binkofski F, Dohle C, Posse S, et al. (1998). Human anterior intraparietal area subserves prehension: a combined lesion and functional MRI activation study. *Neurology* 50(5):1253-9.
- Binkofski F, Buccino G, Dohle C, Seitz RJ, Freund HJ. Mirror agnosia and mirror ataxia constitute different parietal lobe disorders. *Ann Neurol*. 1999 Jul;46(1):51-61.
- Bisiach E, Ricci R, Lualdi M, et al. (1998). Perceptual and response bias in unilateral neglect: two modified versions of the milner landmark task. *Brain Cogn* 37: 369-386.
- Blangero A, Ota H, Delporte L, et al. (2007). Optic ataxia is not only 'optic': impaired spatial integration of proprioceptive information. *Neuroimage* 36 Suppl 2: 61-68.

- Blangero A, Gaveau V, Luauté J, et al. (2008). A hand and a field effect in on-line motor control in unilateral optic ataxia. *Cortex* 44: 560-568.
- Blangero A, Menz MM, McNamara A, et al. (2009). Parietal modules for reaching. *Neuropsychologia* 47: 1500-1507.
- Blangero A, Ota H, Rossetti Y, et al. (2010a). Systematic retinotopic reaching error vectors in unilateral optic ataxia. *Cortex* 46 (1): 77-93.
- Blangero A, Khan AZ, Salemme R, et al. (2010b). Pre-saccadic perceptual facilitation can occur without covert orienting of attention. *Cortex* 46(9):1132-7.
- Boller F, Cole M, Kim Y, et al. (1975). Optic ataxia: clinical-radiological correlations with the EMIScan. *J Neurol Neurosurg Psychiatry* 38: 954-958.
- Brain WR (1941). A form of visual disorientation resulting from lesions of the right cerebral hemisphere: (Section of Neurology). *Proc R Soc Med* 34: 771-776.
- Buxbaum L, Laurel J, Randerath J 2018. Limb apraxia and the left parietal lobe. In: Vallar, G, ed., Coslett H. B, ed.. *The Parietal Lobe. Handbook of Clinical neurology* Amsterdam:Elsevier, pp. 349-363
- Carey DP, Coleman RJ, Della Sala S (1997). Magnetic misreaching. *Cortex* 33: 639-652.
- Carrasco M, Penpeci-Talgar C, Eckstein M (2000). Spatial covert attention increases contrast sensitivity across the CSF: support for signal enhancement. *Vision Res* 40: 1203-1215.
- Castaigne P, Pertuiset B, Rondot P, et al. (1971). Ataxie optique dans les deux hémichamps visuels homonymes gauches après exérèse chirurgicale d'un anévrysme artériel de la paroi du ventricule latéral [Optic ataxia in the two left homonymous visual half-fields after surgical removal of an arterial aneurysm of the wall of the lateral ventricle]. *Rev Neurol (Paris)* 124: 261–268.
- Castaigne P, Rondot P, Dumas JL, et al. (1975). Ataxie optique localisée au coté gauche dans les deux hémichamps visuels homonymes gauches [Optic ataxia localised in the left side of both 2 left homonymous visual hemifields]. *Rev Neurol (Paris)* 131: 23-28.

- Coello Y, Danckert J, Blangero A, et al. (2007). Do visual illusions probe the visual brain? Illusions in action without a dorsal visual stream. *Neuropsychologia* 45: 1849-1858.
- Cogan DG, Adams RD (1953). A type of paralysis of conjugate Gaze (ocular motor apraxia). *AMA Arch Ophthalmol* 50 : 434-42.
- Colby CL, Goldberg ME (1999). Space and attention in parietal cortex. *Annu Rev Neurosci* 22: 319-49.
- Corbetta M, Kincade JM, Ollinger JM, et al. (2000). Voluntary orienting is dissociated from target detection in human posterior parietal cortex. *Nat Neurosci* 3: 292-297.
- Corbetta M, Kincade MJ, Lewis C, Snyder AZ, Sapir A (2005). [Neural basis and recovery of spatial attention deficits in spatial neglect.](#) *Nat Neurosci.* 8(11):1603-10.
- De Renzi E, Gentilini M, Faglioni P, et al. (1989). Attentional shift towards the rightmost stimuli in patients with left visual neglect. *Cortex* 25: 231-7
- Denburg NL, Tranel D (2009). Bálint Syndrome. *Encyclopedia of Neuroscience*: 37-39.
- Dijkerman HC, McIntosh RD, Anema HA, et al. (2006). Reaching errors in optic ataxia are linked to eye position rather than head or body position. *Neuropsychologia* 44: 2766-2773.
- Driver J, Husain M (2002). The role of spatial working memory deficits in pathological search by neglect patients . In H. O. Karnath , A. D. Milner , & G. Vallar (Eds.), *The cognitive and neural bases of spatial neglect* (pp. 351 –364). Oxford, UK : Oxford University Press .
- Ellison A, Schindler I, Pattison LL, (2004). An exploration of the role of the superior temporal gyrus in visual search and spatial perception using TMS. *Brain* 127: 2307-2315.
- Ettlinger G. (1990). ""Object vision" and "spatial vision": the neuropsychological evidence for the distinction". *Cortex.* 26 (3): 319–41.
- Fierro B, Brighina F, Oliveri M, et al. (2000). Contralateral neglect induced by right posterior parietal rTMS in healthy subjects. *Neuroreport* 11: 1519-1521.

- Fink GR, Marshall JC, Shah NJ, et al. (2000). Line bisection judgments implicate right parietal cortex and cerebellum as assessed by fMRI. *Neurology* 54: 1324-1331.
- Garcin R, Rondot P, de Recondo J (1967). Ataxie optique localisée aux deux hémichamps visuels homonymes gauches (étude clinique avec présentation d'un film) [Optic ataxia localized in 2 left homonymous visual hemifields (clinical study with film presentation)]. *Rev Neurol (Paris)* 116: 707-714.
- Gaveau V, Pélisson D, Blangero A, et al. (2008). Saccade control and eye-hand coordination in optic ataxia. *Neuropsychologia* 46: 475-486.
- Girotti F, Milanese C, Casazza M, et al. (1982). Oculomotor disturbances in Bálint's syndrome: anatomoclinical findings and electrooculographic analysis in a case. *Cortex* 18: 603-614.
- Goodale MA, Milner AD (1992). Separate visual pathways for perception and action. *Trends Neurosci* 15: 20-25.
- Girotti F, Casazza M, Musicco M, et al. (1983). Oculomotor disorders in cortical lesions in man: the role of unilateral neglect. *Neuropsychologia* 21: 543-553.
- Granek JA, Pisella L, Blangero A, et al. (2012). The role of the caudal superior parietal lobule in updating hand location in peripheral vision: further evidence from optic ataxia. *PLoS One* 7: e46619.
- Granek JA, Pisella L, Stemberger J, et al. (2013). Decoupled visually-guided reaching in optic ataxia: differences in motor control between canonical and non-canonical orientations in space. *PLoS One* 8: e86138.
- Gréa H, Pisella L, Rossetti Y, et al. (2002). A lesion of the posterior parietal cortex disrupts on-line adjustments during aiming movements. *Neuropsychologia* 40: 2471-2480.
- Guard O, Perenin MT, Vighetto A, et al. (1984). Syndrome pariétal bilatéral proche d'un syndrome de Bálint [Bilateral parietal syndrome approximating a Bálint syndrome]. *Rev Neurol (Paris)* 140: 358-367.
- Hecaen H, De Ajuriaguerra J (1954). Bálint's syndrome (psychic paralysis of visual fixation) and its minor forms. *Brain* 77 : 373-400.
- Heide W, Blankenburg M, Zimmermann E, et al. (1995). Cortical control of double-step saccades: implications for spatial orientation. *Ann Neurol* 38: 739-748.

- Heide W, Kömpf D (1998). Combined deficits of saccades and visuo-spatial orientation after cortical lesions. *Exp Brain Res* 123: 164-171.
- Heide W, Binkofski F, Seitz RJ, et al. (2001). Activation of frontoparietal cortices during memorized triple-step sequences of saccadic eye movements: an fMRI study. *Eur J Neurosci* 13: 1177-1189.
- Hilgetag CC, Théoret H, Pascual-Leone A (1994). Enhanced visual spatial attention ipsilateral to rTMS-induced 'virtual lesions' of human parietal cortex. *Nat Neurosci* 4: 953-957.
- Holmes G (1918). Disturbances of visual orientation. *Br J Ophthalmol* 2: 449–468.
- Holmes G, Horrax G. Disturbances of spatial orientation and visual attention with loss of stereoscopic vision, *Arch Neurol Psychiatry*, 1919, vol.1 (pg.385-407)
- Humphreys GW, Romani C, Olson A, et al. (1994) Non-spatial extinction following lesions of the parietal lobe in humans. *Nature* 372: 357-359.
- Husain M, Stein J (1988). Rezső Bálint and his most celebrated case. *Arch Neurol* 45 : 89-93.
- Husain M, Mannan S, Hodgson T, et al. (2001). Impaired spatial working memory across saccades contributes to abnormal search in parietal neglect. *Brain* 124: 941-952.
- Husain M, Rorden C (2003). Non-spatially lateralized mechanisms in hemispatial neglect. *Nat Rev Neurosci* 4: 26-36.
- Husain M (2008). Hemispatial neglect. *Handb Clin Neurol* 88: 359-372.
- Ishiai S (2002). Perceptual and motor interaction in unilateral spatial neglect. *The cognitive and neural bases of spatial neglect*. Oxford: Oxford University Press. p. 181-193.
- Jackson SR, Newport R, Mort D, et al. (2005). Where the eye looks, the hand follows; limb-dependent magnetic misreaching in optic ataxia. *Curr Biol* 15: 42-46.
- Jackson SR, Condon LA, Newport RW, et al. (2018). Optic ataxia and the dorsal visual stream re-visited: Impairment in bimanual haptic matching performed without vision. *Cortex* 98: 60-72.

Jeannerod M, Rossetti Y (1993). Visuomotor coordination as a dissociable visual function: experimental and clinical evidence. *Baillieres Clin Neurol* 2: 439-460.

Jeannerod M (1994). The hand and the object: the role of posterior parietal cortex in forming motor representations. *Can J Physiol Pharmacol* 72: 535-541.

Karnath HO, Rorden C (2012). The anatomy of spatial neglect. *Neuropsychologia* 50(6):1010-7.

Karnath HO, Ferber S, Himmelbach M (2001). Spatial awareness is a function of the temporal not the posterior parietal lobe. *Nature* 21;411(6840):950-3.

Kaufman DM, Geyer HL, Milstein MJ (2017). Chapter 12: Visual disturbances. *Kaufman's Clinical Neurology for Psychiatrists (Eighth Edition)*: 257-280.

Kennard C, Mannan SK, Nachev P, et al. (2005). Cognitive processes in saccade generation. *Ann N Y Acad Sci* 1039: 176-183.

Khan AZ, Pisella L, Rossetti Y, et al. (2005). Impairment of gaze-centered updating of reach targets in bilateral parietal-occipital damaged patients. *Cereb Cortex* 15: 1547-1560.

Khan AZ, Crawford JD, Blohm G et al. (2007). Influence of initial hand and target position on reach errors in optic ataxic and normal subjects. *J Vis.* 17;7(5):8.1-16.

Khan AZ, Blangero A, Rossetti Y, et al. (2009). Parietal damage dissociates saccade planning from presaccadic perceptual facilitation. *Cereb Cortex* 19(2):383-7.

Khan AZ, Prost-Lefebvre M, Salemm R, et al. (2016). The Attentional fields of visual search in simultanagnosia and healthy individuals: how object and space attention interact. *Cereb Cortex* 26: 1242-1254.

Kirshner HS and Lavin PJM (2006). Posterior cortical atrophy: a brief review. *Curr Neurol Neurosci Rep* 6: 477-80.

Lunven M, Bartolomeo P (2017). Attention and spatial cognition: Neural and anatomical substrates of visual neglect. *Ann Phys Rehabil Med.* 60(3):124-129.

Li CS, Mazzone P, Andersen RA (1999). Effect of reversible inactivation of macaque lateral intraparietal area on visual and memory saccades. *J Neurophysiol* 81: 1827–1838.

- Luauté J, Michel C, Rode G, et al. Functional anatomy of the therapeutic effects of prism adaptation on left neglect. *Neurology* 66: 1859-1867.
- Luria AR (1959). Disorders of "Simultaneous Perception" in a case of bilateral occipito-parietal brain injury. *Brain* 82 : 437-49.
- Mäki-Marttunen V, Villarreal M, Leiguarda RC (2014). Lateralization of brain activity during motor planning of proximal and distal gestures. *Behav Brain Res* 272: 226–237.
- Malhotra P, Coulthard EJ, Husain M (2009). Role of right posterior parietal cortex in maintaining attention to spatial locations over time. *Brain* 132: 645-660.
- Mannan SK, Mort DJ, Hodgson TL, et al. (2005). Revisiting previously searched locations in visual neglect: role of right parietal and frontal lesions in misjudging old locations as new [published correction appears in *J Cogn Neurosci* 17(10):table of contents]. *J Cogn Neurosci* 17: 340-354.
- Martín-Arévalo E, Schintu S, Farnè A, Pisella L, Reilly KT. Adaptation to Leftward Shifting Prisms Alters Motor Interhemispheric Inhibition. *Cereb Cortex*. 2018 Feb 1;28(2):528-537.
- Martín-Arévalo E, Laube I, Koun E, Farnè A, Reilly KT, Pisella L. Prism Adaptation Alters Electrophysiological Markers of Attentional Processes in the Healthy Brain. *J Neurosci*. 2016 Jan 20;36(3):1019-30.
- McIntosh RD, Mulroue A, Blangero A, et al. (2011). Correlated deficits of perception and action in optic ataxia. *Neuropsychologia* 49: 131-137.
- Medendorp WP, Goltz HC, Vilis T, et al. (2003). Gaze-centered updating of visual space in human parietal cortex. *J Neurosci* 23: 6209-6214.
- Medina J, Jax SA, Coslett HB. (2019). Impairments in action and perception after right intraparietal damage. *Cortex* 122: 288-299.
- Michel F, Jeannerod M, Devic M (1963). A case of visual orientation disorder in the 3 dimensions of space (apropos of Bálint's syndrome and the syndrome described by G. Holmes). *Revue Neurologique* 108: 983-984.
- Michel F, Henaff MA (2004). Seeing without the occipito-parietal cortex: Simultagnosia as a shrinkage of the attentional visual field. *Behav Neurol* 15: 3-13.

- Milner AD, Goodale MA (1995). *The Visual Brain in Action*. Oxford University Press, Oxford.
- Milner AD, Paulignan Y, Dijkerman HC, et al. (1999). A paradoxical improvement of misreaching in optic ataxia: new evidence for two separate neural systems for visual localization. *Proc Biol Sci* 266: 2225-2229.
- Milner AD, Goodale MA (2006). *The Visual Brain in Action* (2nd edition). Oxford University Press, Oxford.
- Montero J, Peña J, Genis D, et al. (1982). Bálint's syndrome. Report of four cases with watershed parieto-occipital lesions from vertebrobasilar ischemia or systemic hypotension. *Acta Neurol Belg* 82: 270-280.
- Morris AP, Chambers CD, Mattingley JB (2007). Parietal stimulation destabilizes spatial updating across saccadic eye movements. *Proc Natl Acad Sci U S A* 104: 9069-9074.
- Mort DJ, Malhotra P, Mannan SK, et al. (2003). The anatomy of visual neglect. *Brain* 126: 1986-1997.
- Muggleton NG, Cowey A, Walsh V (2008). The role of the angular gyrus in visual conjunction search investigated using signal detection analysis and transcranial magnetic stimulation. *Neuropsychologia* 46: 2198-2202.
- Niemeier M, Karnath HO (2000). Exploratory saccades show no direction-specific deficit in neglect. *Neurology* 54: 515-518.
- Osiurak F, Aubin G, Allain P, et al. (2008). Different constraints on grip selection in brain-damaged patients: object use versus object transport. *Neuropsychologia* 46: 2431-2434.
- Pascual-Leone A, Gomez-Tortosa E, Grafman J, et al. (1994). Induction of visual extinction by rapid-rate transcranial magnetic stimulation of parietal lobe. *Neurology* 44: 494-498.
- Paterson A., Zangwill OL (1944). Disorders of visual space perception associated with lesions of the right cerebral hemisphere. *Brain: A Journal of Neurology*, 67, 331–358
- Pelli, D. G., & Tillman, K. A. (2008, October). The uncrowded window of object recognition. *Nature Neurosc* 11: 1129–1135.

- Perenin MT, Vighetto A (1988). Optic ataxia: a specific disruption in visuomotor mechanisms. I. Different aspects of the deficit in reaching for objects. *Brain* 111: 643-674.
- Perez FM, Tunkel RS, Lachmann EA, et al. (1996). Bálint's syndrome arising from bilateral posterior cortical atrophy or infarction: rehabilitation strategies and their limitation. *Disabil Rehabil* 18: 300-304.
- Pisella L, Gréa H, Tilikete C, et al. (2000). An 'automatic pilot' for the hand in human posterior parietal cortex: toward reinterpreting optic ataxia. *Nat Neurosci* 3: 729-736.
- Pisella L, Berberovic N, Mattingley JB (2004). Impaired working memory for location but not for colour or shape in visual neglect: a comparison of parietal and non-parietal lesions. *Cortex* 40: 379-390.
- Pisella L, Mattingley JB (2004). The contribution of spatial remapping impairments to unilateral visual neglect. *Neurosci Biobehav Rev* 28: 181-200.
- Pisella L, Binkofski F, Lasek K, et al. (2006a). No double-dissociation between optic ataxia and visual agnosia: multiple sub-streams for multiple visuo-manual integrations. *Neuropsychologia* 44: 2734-2748.
- Pisella L, Rode G, Farnè A, et al. (2006b). Prism adaptation in the rehabilitation of patients with visuo-spatial cognitive disorders. *Curr Opin Neurol* 19: 534-542.
- Pisella L, Striemer C, Blangero A, et al. (2007). Perceptual deficits in optic ataxia? In book: *Sensorimotor foundations of higher cognition: Attention and Performance XXII*, Chapter: 3, Publisher: Oxford University Press, pp.47-72.
- Pisella L, Sergio L, Blangero A, et al. (2009). Optic ataxia and the function of the dorsal stream: contributions to perception and action [published correction appears in *Neuropsychologia*. 2010 48:2786]. *Neuropsychologia* 47: 3033-3044.
- Pisella L, Alahyane N, Blangero A, et al. (2011). Right-hemispheric dominance for visual remapping in humans. *Philos Trans R Soc Lond B Biol Sci* 366 :572-585.
- Pisella L, Biotti D, Vighetto A (2015). Combination of attentional and spatial working memory deficits in Bálint-Holmes syndrome. *Ann N Y Acad Sci* 1339: 165-175.
- Posner MI (1980). Orienting of attention. *Q J Exp Psychol* 32 :3-25.

- Prablanc C, Echallier JE, Jeannerod M, et al. (1979). Optimal response of eye and hand motor systems in pointing at a visual target. II. Static and dynamic visual cues in the control of hand movement. *Biol Cybern* 35: 183-187.
- Revol P, Rossetti Y, Vighetto A, et al. (2003). Pointing errors in immediate and delayed conditions in unilateral optic ataxia. *Spat Vis* 16: 347-364.
- Riddoch G (1935). Visual disorientation in homonymous half fields. *Brain* 58 : 376-382.
- Rizzo M (1993). 'Bálint's syndrome' and associated visuospatial disorders. *Baillieres Clin Neurol* 2 : 415-37.
- Rizzo M and Vecera SP (2002). Psychoanatomical substrates of Bálint's syndrome. *J Neurol Neurosurg Psychiatry* 72: 162-178.
- Rode G, Klos T, Courtois-Jacquín S, et al. (2006). Neglect and prism adaptation: a new therapeutic tool for spatial cognition disorders. *Restor Neurol Neurosci* 24: 347-356.
- Rondot P, De Recondo J, Dumas JL (1977). Visuomotor ataxia. *Brain* 100: 355-376.
- Rosenholtz, R., Huang, J., Raj, A., Balas, B. J., Ilie, L. (2012). A summary statistic representation in peripheral vision explains visual search. *J Vision*, 12(4), 14.
- Rosenholtz R, Huang J, Ehinger KA. (2012). Rethinking the role of top-down attention in vision: effects attributable to a lossy representation in peripheral vision. *Front Psychology*, 3, 13.
- Rossetti Y, Pisella L (2002). Several "vision for action" systems: a guide to dissociating and integrating dorsal and ventral functions (Tutorial). *Common Mechanisms in Perception and action Attention and Performance*. 110: 62-119.
- Rossetti Y, Revol P, McIntosh RD, et al. (2005). Visually guided reaching: bilateral posterior parietal lesions cause a switch from fast visuomotor to slow cognitive control. *Neuropsychologia* 43: 162-177.
- Rossetti Y, Pisella L (2018). Optic ataxia: beyond the dorsal stream cliché. In *Handb Clin Neurol*. 151 :225-247
- Russell C, Deidda C, Malhotra P, et al. (2010). A deficit of spatial remapping in constructional apraxia after right-hemisphere stroke. *Brain* 133: 1239-1251.

- Schindler I, McIntosh RD, Cassidy TP, et al. The disengage deficit in hemispatial neglect is restricted to between-object shifts and is abolished by prism adaptation. *Exp Brain Res* 192: 499-510.
- Schott B, Michel D, Eyssette M (1972). Spatial structuration disorders and visuomotor recording. *Rev Otoneuroophthalmol* 44: 165-175.
- Shulman GL, Astafiev SV, McAvoy MP, d'Avossa G, Corbetta M (2007). Right TPJ deactivation during visual search: functional significance and support for a filter hypothesis. *Cereb Cortex* 17(11):2625-33.
- Smith S and Holmes G (1916). A case of bilateral motor apraxia with disturbance of visual orientation. *Br Med J* 1: 437-41.
- Striemer C, Blangero A, Rossetti Y, et al. (2007). Deficits in peripheral visual attention in patients with optic ataxia. *Neuroreport* 18: 1171-1175.
- Striemer C, Blangero A, Rossetti Y, et al. (2009). Bilateral parietal lesions disrupt the beneficial effects of prism adaptation: evidence from a patient with optic ataxia. *Exp Brain Res* 187: 295-302.
- Striemer C, Locklin J, Blangero A, et al. (2009). Attention for action? Examining the link between attention and visuomotor control deficits in a patient with optic ataxia. *Neuropsychologia* 47: 1491-1499.
- Tyler HR (1968). Normal and abnormal patterns of visual search. *Trans Am Neurol Assoc* 93: 290-291.
- Tzavaras A, Ozonias G, Chodkiewicz JP (1974). Apraxie idéomotrice à prédominance unilatérale gauche avec ataxie optique lors d'une lésion pariétale gauche. In: *Les syndromes de Disconnexion Callosale chez l'Homme*: 265-285.
- Tzavaras A, Hecaen H (1975). Relations of optic ataxia and unilateral ideomotor apraxia. *Exp Brain Res suppl* 23 : 202.
- Tzavaras A, Masure MC (1976). Aspects différents de l'ataxie optique selon la latéralisation hémisphérique lésionnelle. *Lyon Med* 236 : 673-683.
- Ungerleider LG, Mishkin M. Two cortical visual systems. In: Ingle D.J., Goodale M.A., Mansfield R.J.W., editors. *Analysis of Visual Behavior*. MIT press; Cambridge, MA: 1982. pp. 549–586.

- Valdois S, Lassus-Sangosse D, Lobier M (2012). Impaired letter-string processing in developmental dyslexia: what visual-to-phonology code mapping disorder? *Dyslexia* 18: 77-93.
- Valdois S, Lassus-Sangosse D, Lallier M, et al. (2019). What bilateral damage of the superior parietal lobes tells us about visual attention disorders in developmental dyslexia. *Neuropsychologia* 130: 78-91.
- Vallar G, Perani D (1986). The anatomy of unilateral neglect after right-hemisphere stroke lesions. A clinical/CT-scan correlation study in man. *Neuropsychologia* 24: 609-622.
- Vallar G (2007). Spatial neglect, Bálint-Homes' and Gerstmann's Syndrome, and other spatial disorders. *CNS Spectr* 12: 527-36.
- Van Koningsbruggen MG, Gabay S, Sapir A, et al. (2010). Hemispheric asymmetry in the remapping and maintenance of visual saliency maps: a TMS study. *J Cogn Neurosci*. 22: 1730-1738.
- Verfaellie M, Rapcsak SZ, Heilman KM (1990). Impaired shifting of attention in Bálint's syndrome. *Brain Cogn* 12: 195-204.
- Vialatte A, Yeshurun Y, Khan AZ, et al. (submitted). Superior parietal lobule: a role in relative localization of multiple different elements.
- Vighetto A (1980) Etude neuropsychologique et psychophysique de l'ataxie optique. Thesis Université Claude Bernard Lyon I.
- Vighetto A, Perenin MT (1981). Ataxie optique: analyse des réponses oculaires et manuelles dans une tâche de pointage vers une cible visuelle [Optic ataxia: analysis of eye and hand responses in pointing at visual targets (author's transl)]. *Rev Neurol (Paris)* 137: 357-372.
- Vindras P, Blangero A, Ota H, et al. (2016). The Pointing Errors in Optic Ataxia Reveal the Role of "Peripheral Magnification" of the PPC. *Front Integr Neurosci* 10: 27.
- Vuilleumier P, Schwartz S, Clarke K, et al. (2002). Testing memory for unseen visual stimuli in patients with extinction and spatial neglect. *J Cogn Neurosci* 14: 875-886.
- Walker R, Findlay JM (1996). Saccadic eye movement programming in unilateral neglect. *Neuropsychologia* 34: 493-508.

Wardak C, Olivier E, Duhamel JR (2002). Saccadic target selection deficits after lateral intraparietal area inactivation in monkeys. *J Neurosci* 22: 9877–9884.

Weddell RA (2004). Subcortical modulation of spatial attention including evidence that the Sprague effect extends to man. *Brain Cogn* 55: 497-506.

Wojciulik E, Husain M, Clarke K, et al. (2001). Spatial working memory deficit in unilateral neglect. *Neuropsychologia* 39: 390-396.

Wolpert I (1924). Die simultagnosie: storung der gesamtauffassung. *Zeitschrift fur Gesamte Neurologie und Psychiatrie* 93: 397–415.

Yeshurun Y, Carrasco M (1998). Attention improves or impairs visual performance by enhancing spatial resolution. *Nature* 396: 72-75.

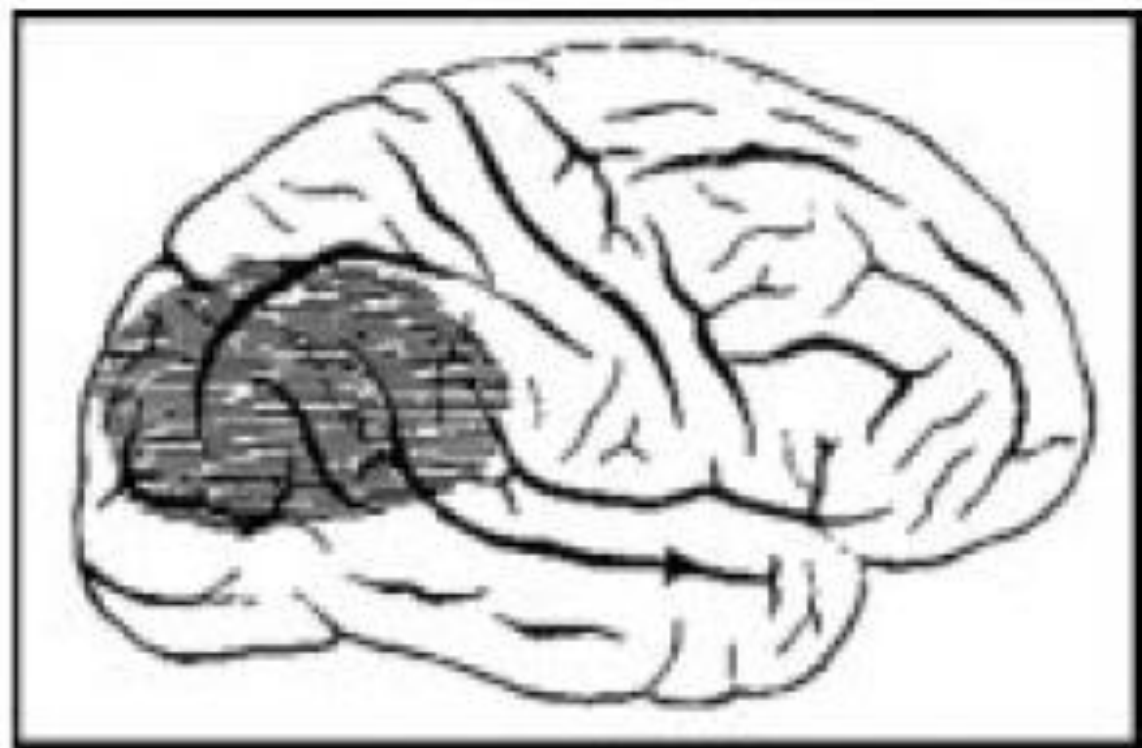
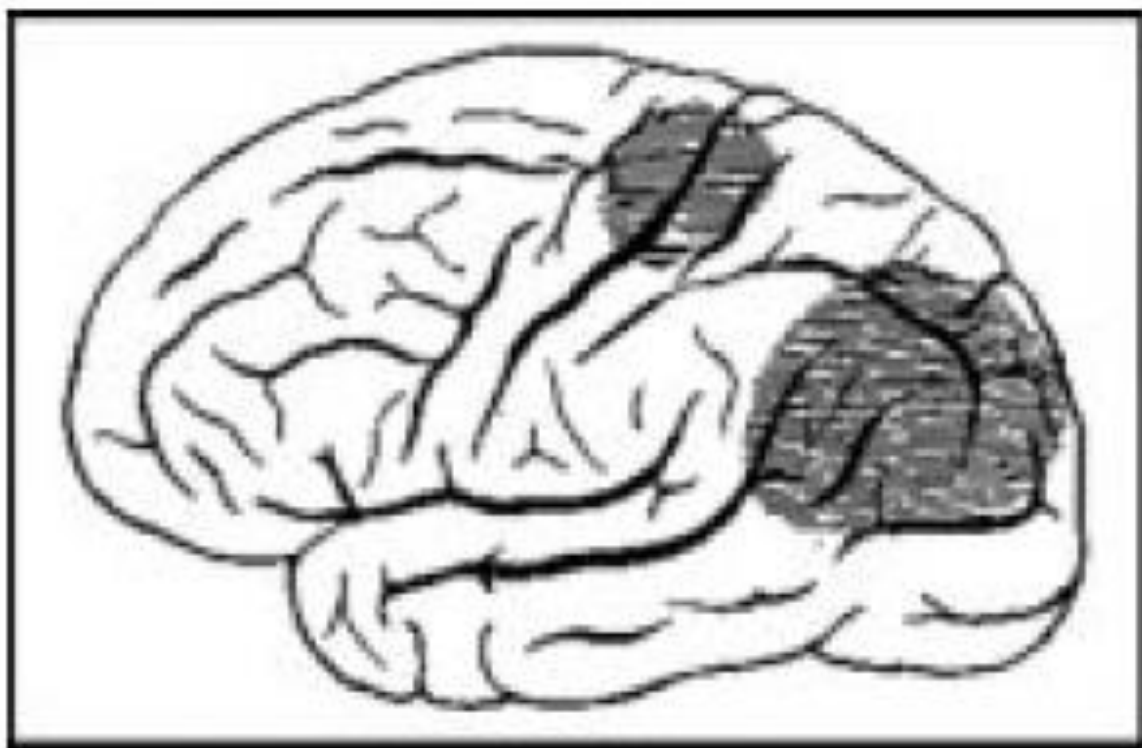


Figure 1


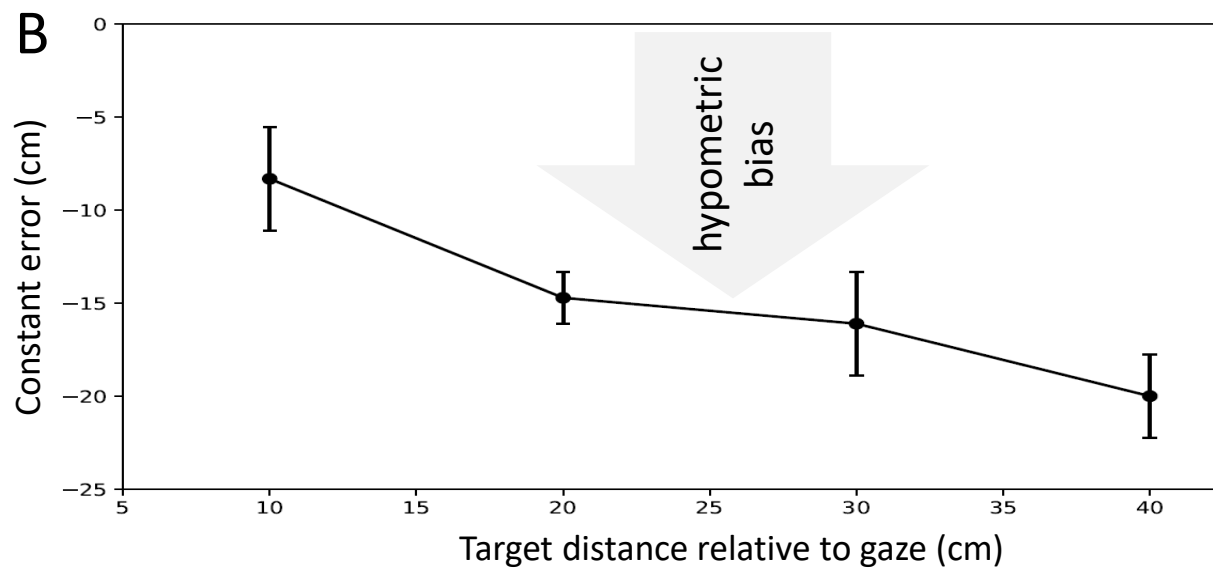


Figure 2



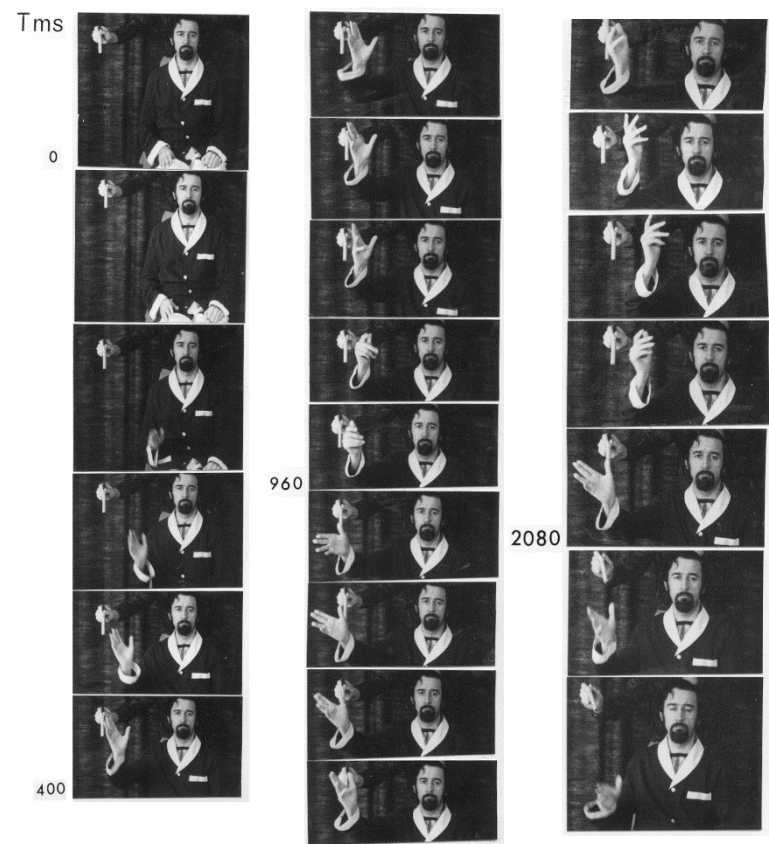
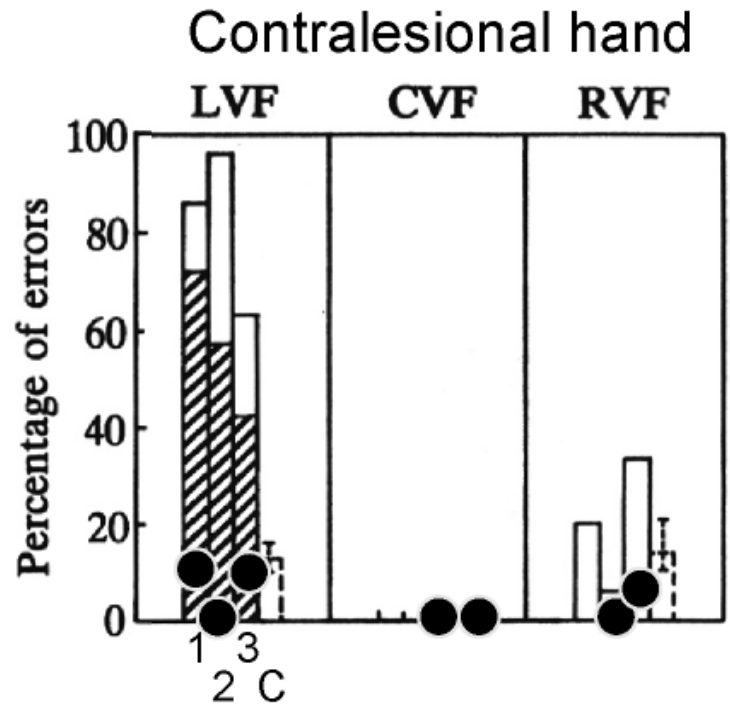


Figure 3

Right hemisphere lesion patients



● While looking at the target

Left hemisphere lesion patients

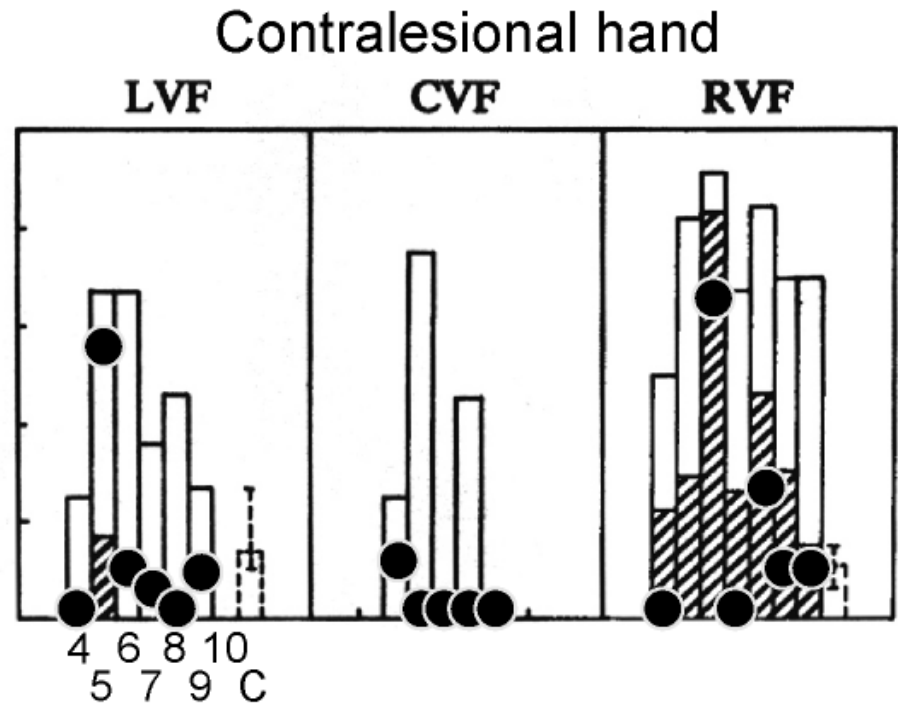
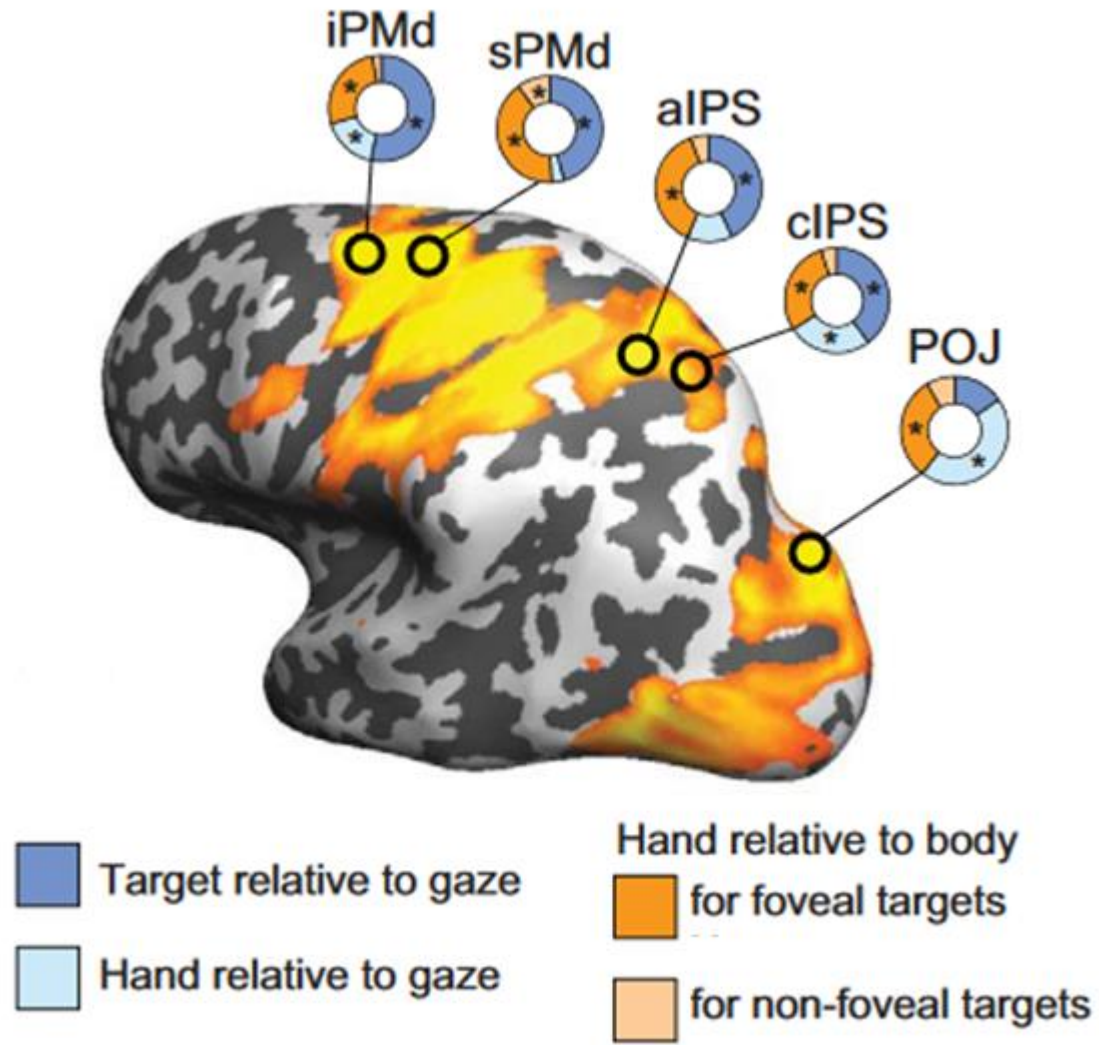


Figure 4

Figure 5



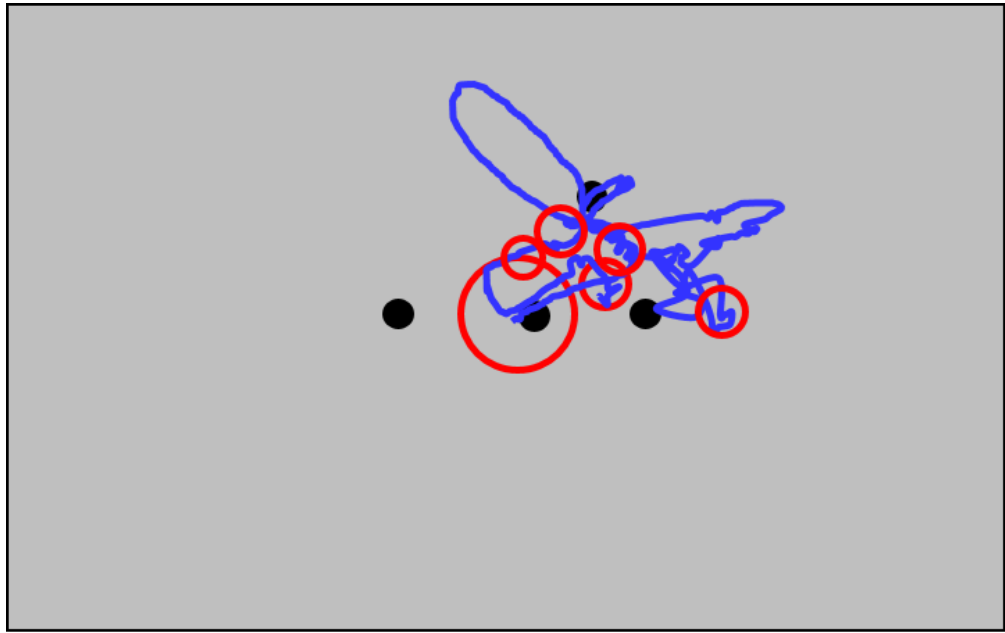
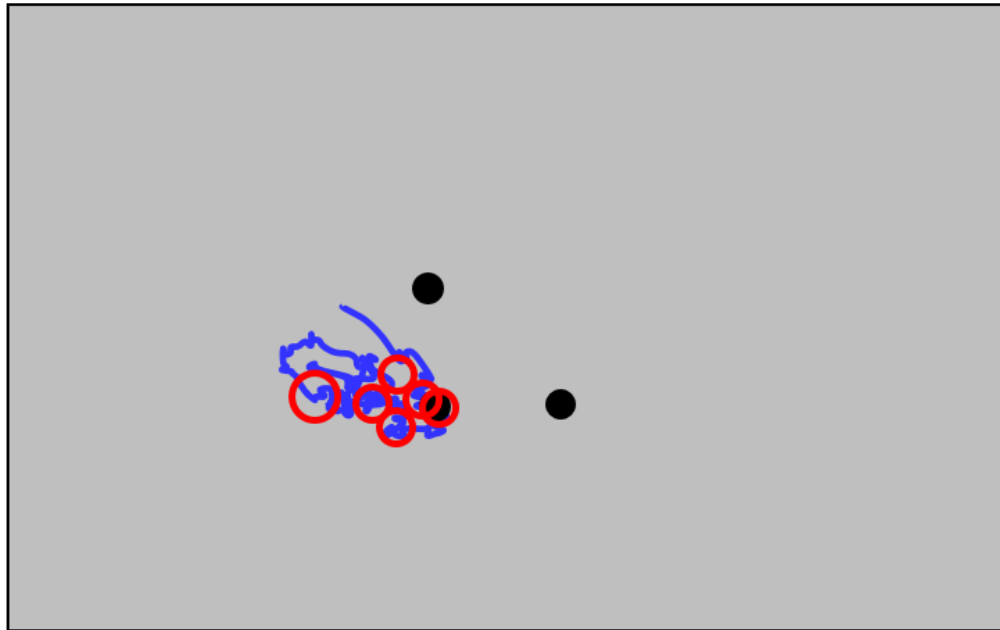


Figure 6



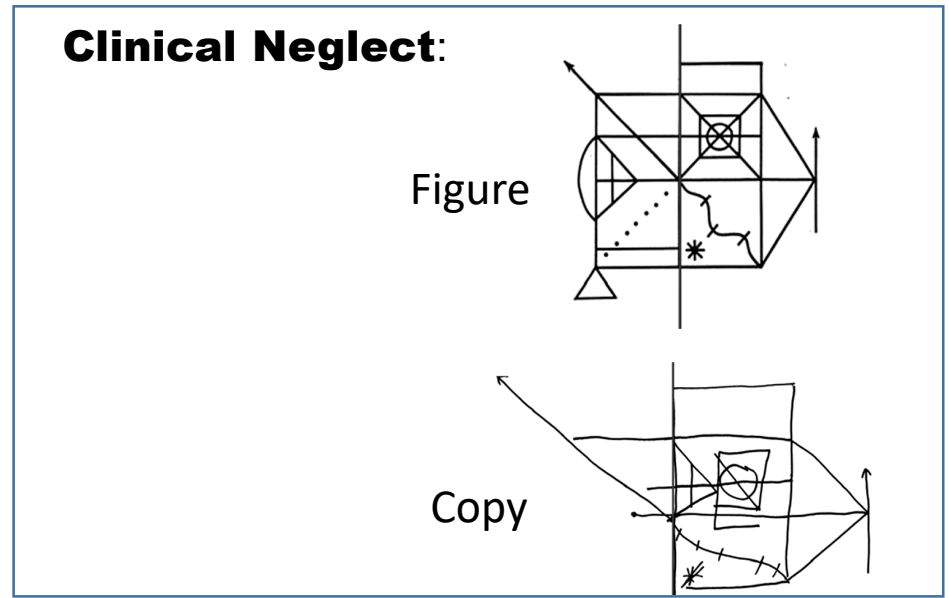
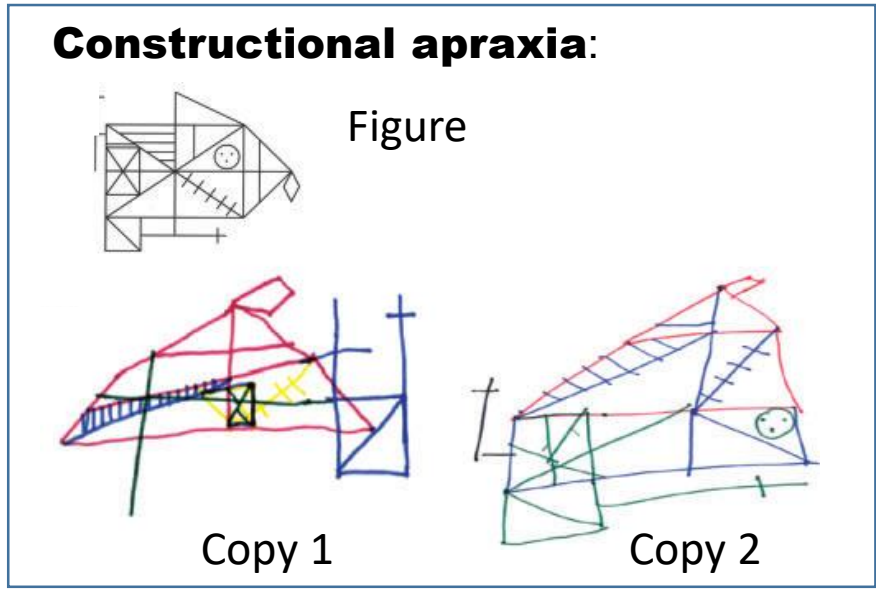



FIGURE 7

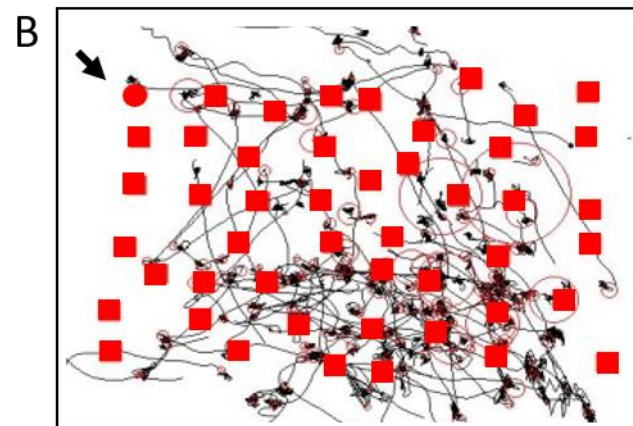
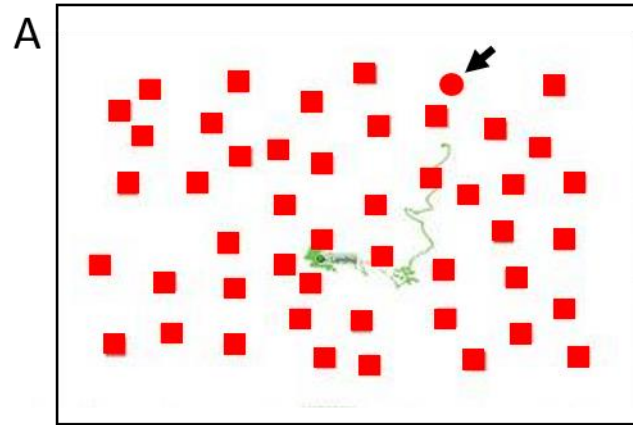
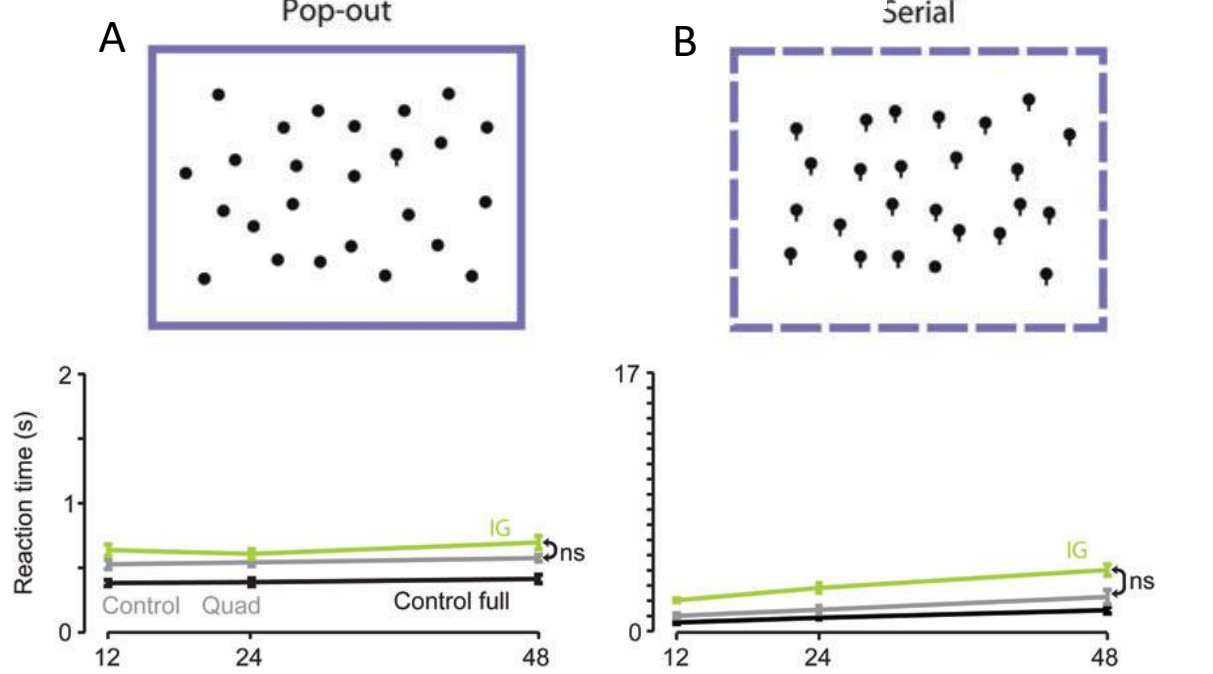


Figure 8

Filled Balloon task



Balloon task

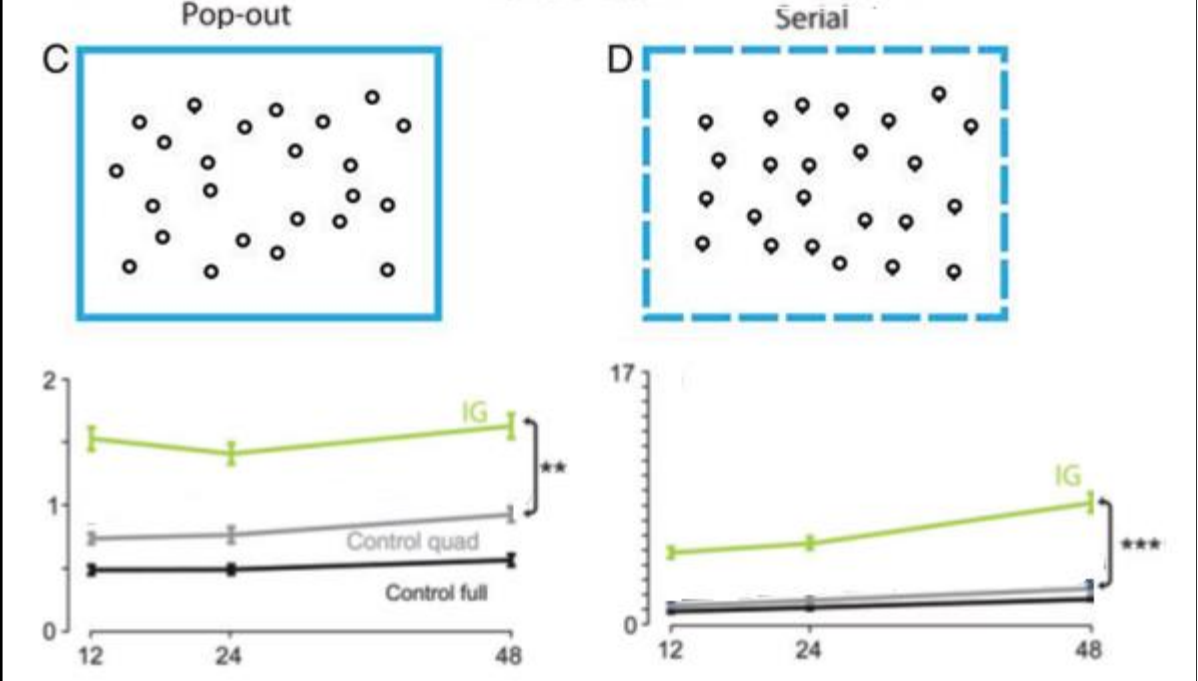


Figure 9

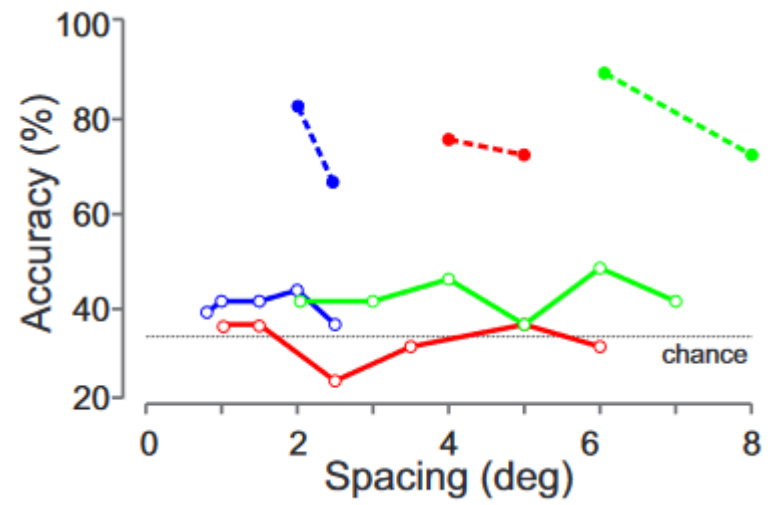
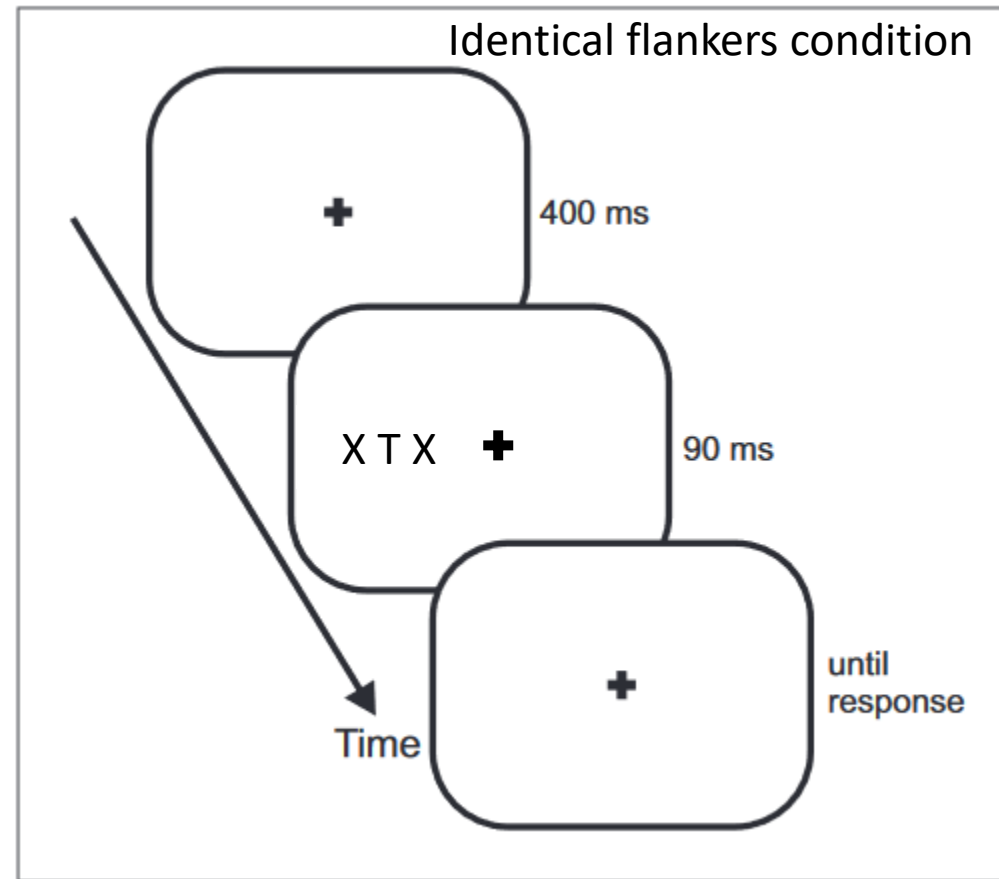
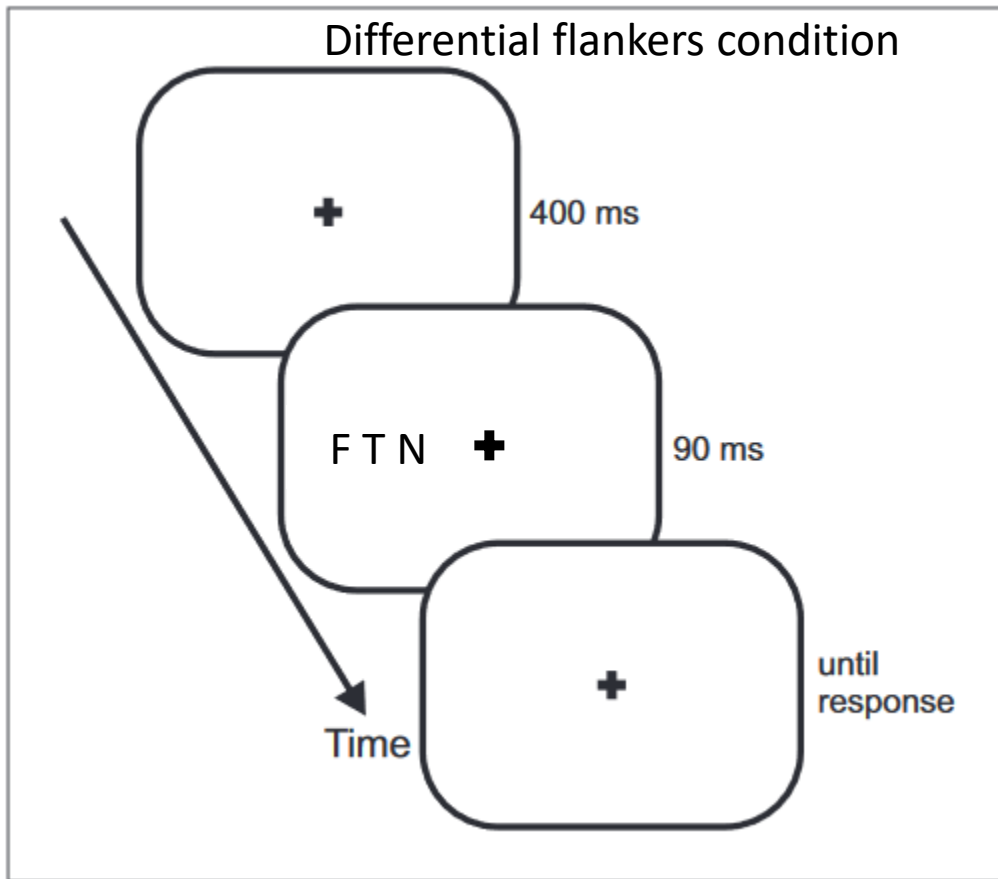

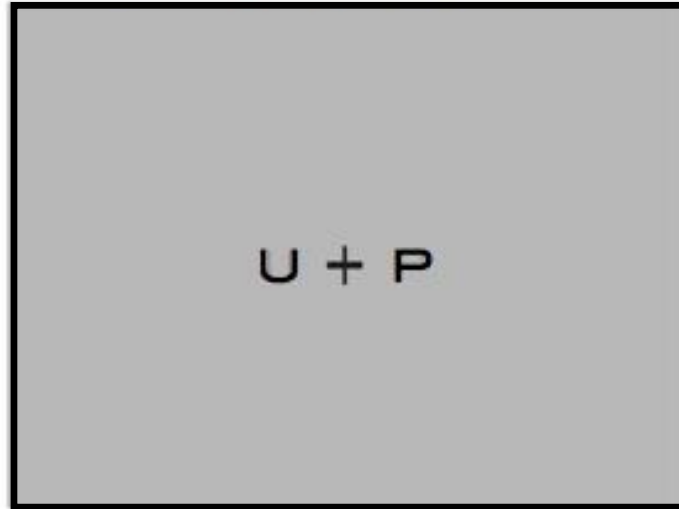


Figure 10

Target Detection



Letter Detection



Letter Identification

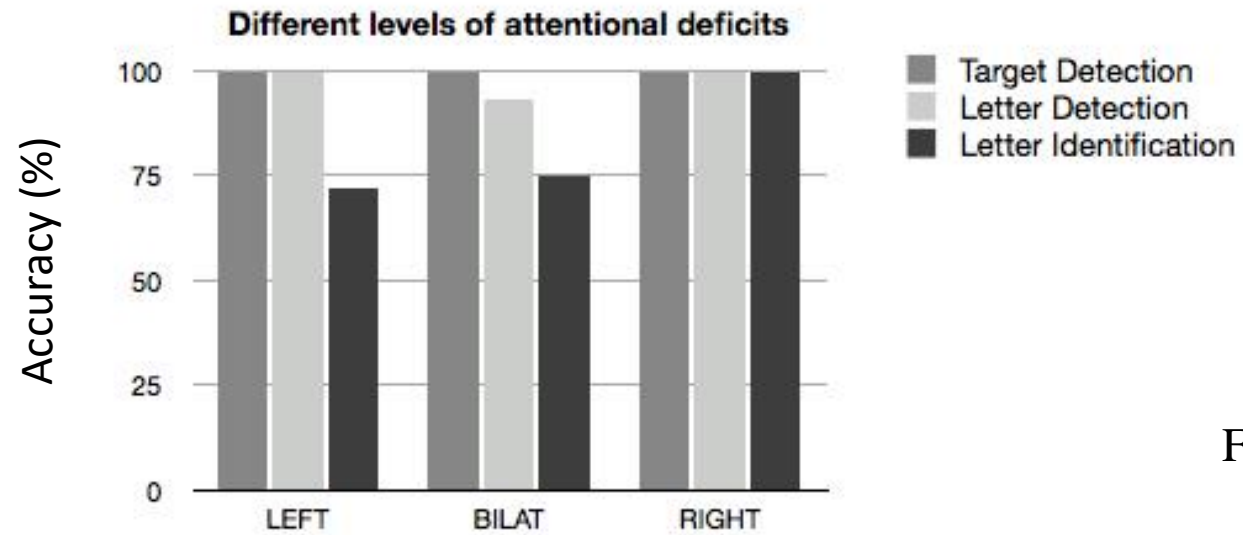
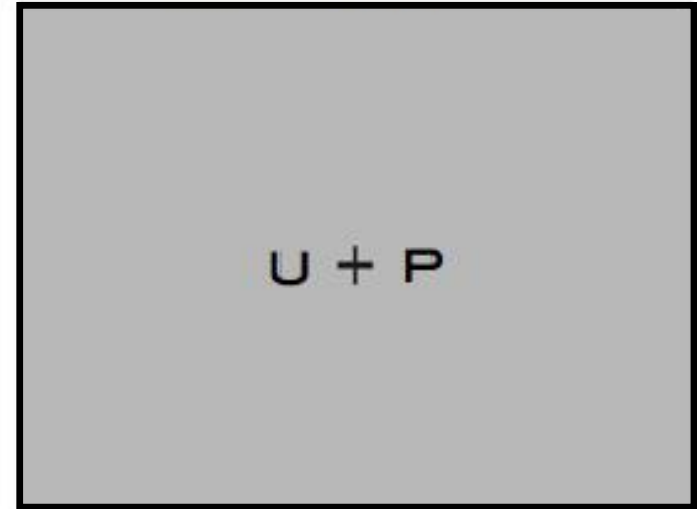
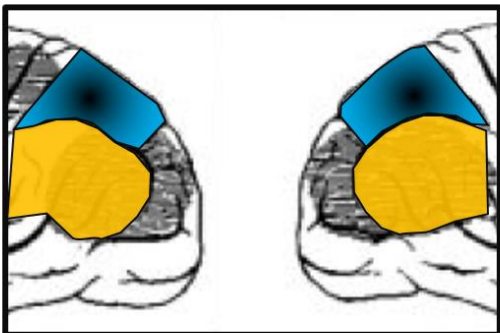

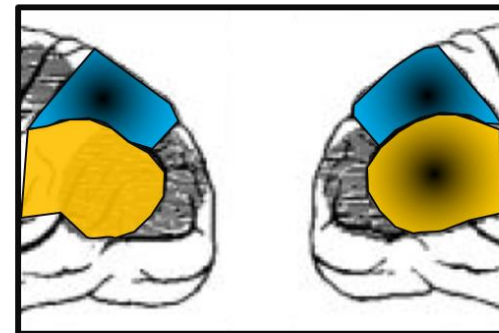Figure 11

Figure 12

BILATERAL LESION

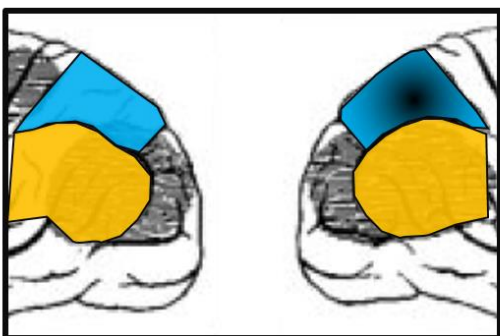


Simultanagnosia/bilateral optic ataxia

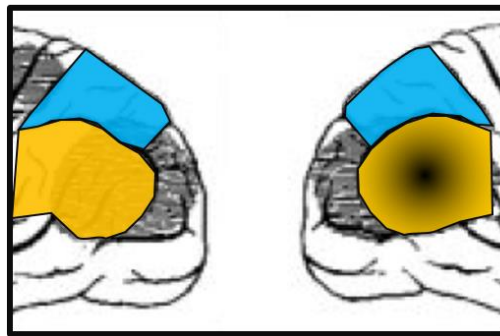


Full Balint's syndrome

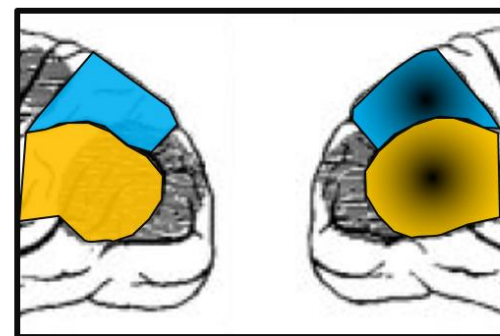
UNILATERAL LESION



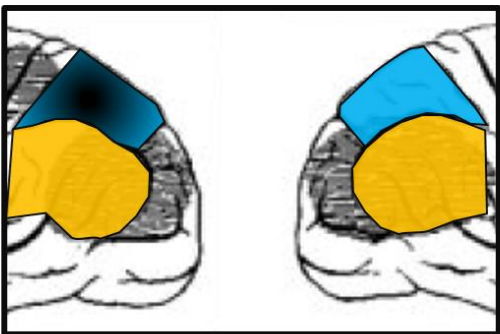Extinction / Optic ataxia



Constructional apraxia



Clinical neglect



SPL-IPS:

Attention/ Localisation

Right IPL-STG:

Visual synthesis

SPL+ right IPL:

