



**HAL**  
open science

## La Ferrassie 1 Neandertal

Antoine Balzeau, Asier Gómez-Olivencia

► **To cite this version:**

Antoine Balzeau, Asier Gómez-Olivencia. La Ferrassie 1 Neandertal. Encyclopedia of Life Sciences, 2020, pp.1-11. 10.1002/9780470015902.a0028493 . hal-03006449

**HAL Id: hal-03006449**

**<https://hal.science/hal-03006449v1>**

Submitted on 15 Nov 2020

**HAL** is a multi-disciplinary open access archive for the deposit and dissemination of scientific research documents, whether they are published or not. The documents may come from teaching and research institutions in France or abroad, or from public or private research centers.

L'archive ouverte pluridisciplinaire **HAL**, est destinée au dépôt et à la diffusion de documents scientifiques de niveau recherche, publiés ou non, émanant des établissements d'enseignement et de recherche français ou étrangers, des laboratoires publics ou privés.



Distributed under a Creative Commons Attribution - NonCommercial - ShareAlike 4.0 International License

1 **eLS**

2 The La Ferrassie 1 Neandertal

3 **A28493**

4 **Antoine Balzeau<sup>a,b</sup>, Asier Gómez-Olivencia<sup>c,d,e</sup>**

5 <sup>a</sup>Paleofed, CNRS, UMR 7194, Département Homme et Environnement, Muséum national  
6 d'Histoire naturelle, Musée de l'Homme, Paris, France.

7 <sup>b</sup>Department of African Zoology, Royal Museum for Central Africa, Tervuren, Belgium.

8 <sup>c</sup>Dept. Estratigrafía y Paleontología, Facultad de Ciencia y Tecnología, Universidad del  
9 País Vasco-Euskal Herriko Unibertsitatea (UPV/EHU). Barrio Sarriena s/n, 48940 Bilbao,  
10 Spain.

11 <sup>d</sup>Sociedad de Ciencias Aranzadi, Zorroagaina 11, 20014 Donostia-San Sebastian,  
12 Spain.

13 <sup>e</sup>Centro UCM-ISCI III de Investigación sobre Evolución y Comportamiento Humanos, Avda.  
14 Monforte de Lemos 5 (Pabellón 14), 28029 Madrid, Spain.

15 **Abstract:**

16 The La Ferrassie 1 (LF1) skeleton, discovered over a century ago, is one of the most  
17 important Neandertal individuals in both paleobiological and historical terms. It is indeed  
18 among the most complete specimens ever found and it has played an important role in  
19 the interpretation of Neandertal anatomy and lifeways. LF1 was found in 1909, and has  
20 been described as an adult male, of around 172 cm of stature and a body mass of 85 kg.  
21 He was found in what was considered a funerary tip in a level with a chronological range  
22 between 40 and 54 thousand years. This individual has been the subject of scientific  
23 studies for more than 100 years, and the most recent ones, using cutting-edge imaging  
24 technologies have provided additional important paleobiological and taphonomic  
25 information. LF1 shows different pathological lesions, including fractures of the clavicle  
26 and the femoral trochanter, degenerative pathologies in the spine and evidence of a  
27 pulmonary disease (thoracic infection and/or carcinoma) which could have been the  
28 cause of death.

29 **Key words:**

30 Human evolution, paleopathology, bone fracture, imaging methodologies, *Homo*  
31 *neanderthalensis*.

32 **Key Concepts:**

- 33
- 34 • La Ferrassie 1 (LF1) was found in 1909 and was paramount at the beginning of  
the 20<sup>th</sup> century to understand the adult Neandertal anatomy.
  - 35 • LF1 was an old individual that survived to different traumas and lesions and was  
36 finally interred by his group.

- 1       • A pulmonary disease (thoracic infection and/or carcinoma) could have been the  
2       cause of death.
- 3       • Despite having been the object of monographs in the past, recent studies have  
4       described new fossils and new data on this individual.

## 5   **Introduction**

6   The La Ferrassie site complex, in Dordogne, is one of the best places for the study of  
7   prehistoric humans. La Ferrassie is located near a limestone hill in the town of Savignac  
8   de Miremont, five kilometers north of Le Bugue, in Dordogne, France. It includes three  
9   sites: a small shelter, a cave and, the most famous, the big shelter (*grand abri* in  
10   French). The *grand abri* is particularly significant for our knowledge of Neandertals and  
11   their behaviour. The site preserves an important sequence that includes Mousterian,  
12   Chatelperronian and Aurignacian levels (Delporte, 1984). In this last site, two fairly  
13   complete adult and four partial skeletons were discovered during excavations led by  
14   Louis Capitan and Denis Peyrony between 1896 and 1922. An additional partial  
15   immature individual was found in 1970 and excavated in 1970 and 1973, during the field  
16   work led by Henri Delporte at the site (1968-1973). The discovery of two adults, possibly  
17   representing a male and a female, and five partial immature individuals of different  
18   ages-at-death has provided the possibility to explore important paleobiological questions  
19   such as variation, ontogeny and paleopathology (Heim, 1976, 1982a and b; Fennell and  
20   Trinkaus, 1997; Balzeau and Rougier, 2013; Gómez-Olivencia, 2013; Gómez-Olivencia et  
21   al., 2013, 2015). In addition, this site has contributed ample material to the debate on  
22   Neandertal burials, as for five of the individuals it has been proposed that they were  
23   buried in intentional pits, being one individuals covered by a stone and another was  
24   associated with three stone artefacts (Capitan and Peyrony, 1909, 1910, 1911, 1920;  
25   Maureille and Van Peer, 1998). Nevertheless, the interpretation of several aspects of the  
26   burials as indicating that some Neandertals were intentionally buried is particularly  
27   difficult due to a number of limitations. Some aspects of the archaeological record have  
28   been used to recognise past acts or behaviours, including funerary activities, but their  
29   interpretation as symbolic acts often remains disputable (Heim in Delporte, 1984).

30   Finally, it is also worth noting that the *grand abri* has also yielded five isolated dental  
31   remains: three classified as Neandertals belonging to a minimum of two additional adult  
32   individuals, one belonging to a modern human and the last one for which it has not been  
33   possible to stablish its taxonomic affinities (Gambier et al., 1990; Gambier, 1992; Becam  
34   et al., 2019).

## 35   **La Ferrassie 1: the discovery**

36   On September 17, 1909, a Neandertal skeleton, probably of a male and adult individual,  
37   designated La Ferrassie 1 (LF1), was found in what Denis Peyrony, then in charge of the  
38   excavations, considered a funerary pit contemporary to level C (Maureille and Van Peer,  
39   1998). LF1 is associated with the Ferrassie facies of Mousterian. This individual was  
40   found in a geological level dated between c. 40,000 ± 2,000 and 54,000 ± 3,000,  
41   depending on the method used (Guérin et al., 2015).

42   Excavations more than a century old were carried out according to standards very  
43   different from modern research with laser recording as we do today. The first skeleton of

1 La Ferrassie was found when digging a trench several meters wide with shovel and  
2 pickaxe, when some bones which were protruding from the profile were recognized as  
3 humans. This led to the excavation of four meters of sediment above this individual in  
4 just three days. Once these four meters of sediment were removed, it took another day  
5 to clean the entire surface of the skeleton, which was done in front of the presence of all  
6 the prehistorians invited for the event (Figure 1). Finally, another day was devoted to  
7 make two large blocks of plaster surrounding the skeleton and to remove them from the  
8 site. They were then sent to the National Museum of Natural History of Paris for a more  
9 "fine" work of cleaning and excavation of the blocks (Figure 1). The excavated remains  
10 were then reconstructed, although some errors were done in both vertebrae and ribs  
11 (Gómez-Olivencia, 2013).

12 LF1 was lying on its back, with the head higher (less deep) than the pelvis and looking to  
13 the left, with the right arm flexed on his right side, left arm more or less parallel to the  
14 trunk on the left side and both legs flexed to the right (Figure 1). The publication of a  
15 letter sent in 1926 by D. Peyrony to M. Boule, in charge of the study of the skeletons,  
16 together with other impressions of the researchers who witnessed the unearthing of the  
17 LF1 provided new information regarding the stratigraphy of the place where this  
18 individual was found (Maureille and Van Peer, 1998). First, H. Breuil described LF1 as  
19 laying on an apparently natural depression (Maureille and Van Peer, 1998). Something  
20 not seen in the rest of the Mousterian levels was observed by both D. Peyrony and M.  
21 Boule: small packets of yellow sand (from the lower level) mixed with the Mousterian  
22 sediments associated with LF1 (and also LF2). The presence of this sediment coming  
23 from the underneath level has been interpreted as evidence for the intentional burial in  
24 funerary pits. Neandertals, digging the funerary pit for LF1 (and also LF2), removed  
25 sediment from the underlying level and mixed with the sediment which would afterwards  
26 fill the pit (Maureille and Van Peer, 1998). The recent taphonomic analysis of this  
27 individual confirms the absence of surface alterations (i.e., absence of cut-marks or bite-  
28 marks) on the bones in the LF1 skeleton. Moreover, the breakage pattern is that of bone  
29 that has lost collagen, which would be consistent with the intentional burial of this  
30 individual proposed by previous studies (Gómez-Olivencia et al., 2018).

### 31 **The La Ferrassie 1 Neandertal individual**

32 La Ferrassie 1 is a nearly complete skeleton that preserves all anatomical regions (Heim,  
33 1976, 1982a; Fennell and Trinkaus, 1997). The fossil remains of LF1 are housed in the  
34 collections of the Muséum national d'Histoire Naturelle (MNHN) at the Musée de  
35 l'Homme. The recent study of the micro-CTs of the cranium has revealed that even the  
36 most delicate ear ossicles from the right temporal bone (Figure 2) were preserved.

37 LF1 has been determined as a male based on greater sciatic notch morphology (Heim,  
38 1982). The age at death of LF1 has been estimated to be between 40 and 55, and thus  
39 has been classified as an old adult individual (see Heim, 1976; Trinkaus, 1995). The  
40 assessment of the pubic symphysis is consistent with Todd's (1920) age phase X (50+;  
41 White and Folkens, 2005, based on Meindl et al., 1985) in agreement with previous  
42 estimations (Gómez-Olivencia et al., 2018). LF1 was a relatively tall individual for a  
43 Neandertal with an estimated stature of 171-173.1 cm and a body mass estimation of 85  
44 kg (Ruff et al., 1997: their supplementary information; Carretero et al., 2012).

45

## 1 **The pathological lesions**

2 The pathological lesions and/or anomalies present in LF1 are related to trauma, aging  
3 effects and a severe systemic disease that could have been related to the cause of death  
4 (Figure 3). We will describe them anatomically.

5 Heim (1976) described the presence of alveolar mandibular abscesses related to a high  
6 degree of dental attrition. In the vertebral column, the atlas (C1) presents a non-clinical  
7 variant in the vertebral artery, called unilateral persistent first intersegmental artery,  
8 which has no clinical consequences (Gómez-Olivencia et al., 2018). This was previously  
9 diagnosed as an exostosis that has reduced the size of the left transverse foramen of  
10 this vertebra (Heim, 1976). Despite the absence of ossification at the insertion point  
11 (entheso-exostosis) of the anterior ligament on the ventral surfaces of the vertebral  
12 bodies, and the absence of ossification of the ligamenta flava at the cranial and caudal  
13 edges of the laminae, the amount of vertebral pathology displayed in LF1 is greater than  
14 previously reported (Gómez-Olivencia et al., 2018), which includes exostosis, the  
15 remodelling of different, articular facets and evidence of scoliosis. One rib from the left  
16 side (the 6<sup>th</sup> or 7<sup>th</sup>) also shows a bulge of unknown etiology (Gómez-Olivencia et al.,  
17 2018).

18 The left clavicles is very different from the right one, as a result of a possible greenstick  
19 fracture, with no displacement of the bone (Gómez-Olivencia et al., 2018). Heim (1982a:  
20 5) originally suggested that the slightly (~1 mm) longer right clavicle was consistent  
21 with the hypothesis that this individual was left-handed. It is difficult to assess to which  
22 extent the pathology and fracture detected on the left clavicle is responsible for its  
23 slightly shorter length. However, data on humeral asymmetry are additional shows that  
24 the right humerus is more robust than the left (Trinkaus et al., 1994), which suggests  
25 that LF1 was right-handed. Moreover, the LF1 endocast displays a morphological pattern  
26 of RF/LO fronto-occipital petalia that is more consistent with that present in right-handed  
27 modern humans (Balzeau et al., 2012a, 2012b).

28 The pathology of the greater trochanter is probably an avulsion fracture which displaced  
29 proximo-medially the detached portion prior to healing, and which also resulted in the  
30 abnormal growth of bone in the trochanteric fossa (Dastugue, 1960; Trinkaus, 1985;  
31 Fennell and Trinkaus, 1997; Gómez-Olivencia et al., 2018).

32 Finally, the skeleton shows bilateral periostitis on the distal femora and both proximal  
33 and distal ends of the tibiae, the presence on at least one fibula and the possible  
34 involvement of the right distal radius as a result of a systemic condition, likely due to  
35 hypertrophic pulmonary osteoarthropathy (HPO) due to a thoracic infection and/or  
36 carcinoma (Fennell and Trinkaus, 1997).

37 These pathologies likely did not occur all at the same time. The atlas is the only  
38 congenital condition and for the rest of them it is difficult to assess the timing of its  
39 onset. Gómez-Olivencia et al. (2018) suggest that the two traumatic lesions (left clavicle  
40 and right femur) are due to one or two events that occurred long before death, and  
41 maybe early in life. On the other hand, the scoliotic and degenerative processes present  
42 on the spine as well as the abscesses, likely occurred later and could have been the result  
43 of ongoing degenerative and aging processes in which the femoral lesion could have  
44 aided due to postural asymmetry. Finally, according to Fennell and Trinkaus (1997), LF1

1 suffered the early stages of an acute form of HPO, which likely began 2-14 months  
2 before death.

### 3 **The end of the life of La Ferrassie 1**

4 The lesions of LF1 would have likely affected his posture and appearance. The traumatic  
5 lesion on the shoulder likely would have resulted in an asymmetrical external  
6 appearance of the shoulders. The presence of scoliosis and osteoarthritis (based on the  
7 osteophytes) suggests that the trunk of LF1 was not straight. In summary, it is likely  
8 that LF1 showed differences in the physical appearance and posture reflective of an old  
9 man that suffered various healed lesions plus ongoing problems resulting from  
10 respiratory issues.

11 Maureille et al. (2008) proposed that due to his physical condition, LF1 was helped by his  
12 group: "Son état physique implique qu'il fût pris en charge par son groupe". Most of the  
13 articles dealing with the presence of pathological lesions in fossil hominins discuss the  
14 possibility of compassion being a component of the survival of these individuals, due to  
15 altruistic help/tolerance offered by other members of the group (e.g., Lebel et al., 2001;  
16 Lordkipanidze et al., 2005; Maureille et al., 2008). Inherent in these discussions  
17 generally lies the concept that at certain point in human evolution, hominins acquired  
18 social/solidarity skills similar to modern *Homo sapiens* that is, some behavioural  
19 boundary was crossed that marks the starting point of humanity. This idea is also reliant  
20 on the notion that some level of behaviour "fossilizes" and can be inferred from the  
21 archaeopaleontological record. Dettwyler (1991) argued that the study of pathological  
22 individuals is inductive and based on too many assumptions for the archaeological record  
23 to answer, which does not mean that they are incorrect *per se*. DeGusta (2002) states  
24 that the lack of comparative studies has led to proposals that are speculative. However,  
25 the study of paleopathology in human evolution is still able to provide important hints on  
26 human paleobiology, as long as its inherent limitations regarding group behaviour are  
27 recognized.

### 28 **La Ferrassie 1 in the Neandertal context**

29 A few hundred sites have yielded Neandertal remains of along their c. 300,000 years of  
30 life as a species. Among these fossils, about fifty cases correspond to quite complete  
31 individuals, in about twenty sites. In Shanidar, (Iraqi Kurdistan), nine bodies have been  
32 discovered, seven in La Ferrassie, three in La Palomas, Spain, two in Spy (Belgium), in  
33 Kebara and Amud (in the Mediterranean Levant), in Le Moustier (France), in Kiik-Koba  
34 (Russia), in Dederiyeh (Syrian Kurdistan). Several additional sites have so far provided  
35 isolated skeletons. Many of these discoveries are not very well dated. The oldest come  
36 from the Mediterranean Levant and could be c. 100 thousand years old, maybe more  
37 (Tabun C1; Grün and Stringer, 2000). Intriguingly, they show a similar chronology to the  
38 oldest well dated modern human burials from Skhul and Qafzeh, also in the  
39 Mediterranean Levant. Most are located in Western Europe and are probably less than  
40 50,000 years old, although more direct datings are needed in order to proof this  
41 particular. The detailed anthropological analysis of the individuals found shows that five  
42 died around the time of birth and that there are many young children. Conversely, there  
43 are basically no adolescents among these fairly complete bodies. These data are  
44 challenging. There is indeed, starting in a particular moment of Prehistory, and in  
45 relatively short period of time, more skeletons, sometimes almost complete and in

1 anatomical connection, than for all previous periods in the human history. For most  
2 researchers, the most parsimonious explanation, also based on geological and  
3 taphonomic analysis is that the Neandertals began to bury (some of) their dead.

4 La Ferrassie 1 was an old man who suffered various healed injuries during his lifetime,  
5 probably related to his hunter-gatherer lifestyle. He was also suffering from respiratory  
6 problems when he was over 50 years old. Following his death, he was buried by other  
7 members of his group in the La Ferrassie rock-shelter, a place repeatedly used by  
8 Neandertals for millennia.

## 9 **References:**

10 *Balzeau A, Gilissen E, Grimaud-Hervé D (2012a) Shared pattern of quantified*  
11 *endocranial shape asymmetries among anatomically modern humans, great apes and*  
12 *fossil hominins. PLoS ONE 7(1): e29581.*

13 *Balzeau A, Holloway R, Grimaud-Hervé D (2012b) Variations and asymmetries in*  
14 *regional brain surface in the genus Homo. Journal of Human Evolution 62: 696-706.*

15 *Balzeau A, Rougier H (2013) New information on the modifications of the neandertal*  
16 *suprainiac fossa during growth and development and on its etiology. American Journal of*  
17 *Physical Anthropology 151: 38-48.*

18 *Becam G, Verna C, et al. (2019) Isolated teeth from La Ferrassie: Reassessment of the*  
19 *old collections, new remains, and their implications. American Journal of Physical*  
20 *Anthropology 169: 132-142.*

21 *Capitan L., Peyrony D (1909) Deux squelettes humains au milieu de foyers de l'époque*  
22 *moustérienne. La Revue de l'Ecole Anthropologie Paris 4: 402-409.*

23 *Capitan L., Peyrony D (1910) Deux squelettes humains au milieu de foyers de l'époque*  
24 *moustérienne. Bulletins et Mémoires de la Société d'Anthropologie de Paris 48-53.*

25 *Capitan L., Peyrony D (1911) Un nouveau squelette humain fossile. La Revue de l'Ecole*  
26 *Anthropologie Paris 148-150.*

27 *Capitan L., Peyrony D (1920) Nouvelles fouilles à La Ferrassie (Dordogne). 44e session*  
28 *de l'Association française pour l'avancement des sciences. Ass. française l'avancement*  
29 *sci., Strasbourg.*

30 *Carretero JM, Rodríguez L et al. (2012) Stature estimation from complete long bones in*  
31 *the Middle Pleistocene humans from the Sima de los Huesos, Sierra de Atapuerca*  
32 *(Spain). Journal of Human Evolution 62: 242e255.*

33 *Dastugue J (1960) Pathologie de quelques Néandertaliens. VIe Cong. Int. Sc. Anth.*  
34 *Ethn., Paris 576-581.*

35 *DeGusta D (2002) Comparative skeletal pathology and the case for conspecific care in*  
36 *Middle Pleistocene hominids. Journal of Archaeological Sciences 29: 1435-1438.*

37 *Delporte H. et el. (1984) Le grand abri de la Ferrassie: fouilles 1968-1973. Laboratoire*  
38 *de paléontologie humaine et de préhistoire, Paris.*

- 1 Dettwyler KA (1991) Can paleopathology provide evidence for "compassion"? American  
2 Journal of Physical anthropology **84**: 375-384.
- 3 Fennell KJ, Trinkaus E (1997) Bilateral Femoral and Tibial Periostitis in the La Ferrassie 1  
4 Neanderthal. Journal of Archaeological Sciences **24**: 985-995.
- 5 Gómez-Olivencia A (2013) The presacral spine of the La Ferrassie 1 Neandertal: a  
6 revised inventory. Bulletins et Mémoires de la Société d'Anthropologie de Paris **25**: 19-  
7 38.
- 8 Gómez-Olivencia A, Been E, et al. (2013) The Neandertal vertebral column 1: The  
9 cervical spine. Journal of Human Evolution **64**: 608-630.
- 10 Gómez-Olivencia A, Crevecoeur I, Balzeau A, (2015) La Ferrassie 8 Neandertal child  
11 reloaded: New remains and re-assessment of the original collection. Journal of Human  
12 Evolution **82**: 107e126.
- 13 Gómez Olivencia A, Quam R, et al. (2018) La Ferrassie 1: New perspectives on a  
14 "classic" Neandertal. Journal of Human Evolution **117**: 13-32.
- 15 Grün R, Stringer C, (2000) Tabun revisited: revised ESR chronology and new ESR and U-  
16 series analyses of dental material from Tabun C1. Journal of Human Evolution **39**: 601-  
17 612.
- 18 Guérin G, Frouin M, et al. (2015) A multi-method luminescence dating of the Palaeolithic  
19 sequence of La Ferrassie based on new excavations adjacent to the La Ferrassie 1 and 2  
20 skeletons. Journal of Archaeological Science **58**: 147-166.
- 21 Heim, J-L (1976) *Les Hommes fossiles de la Ferrassie. I. Le gisement. Les squelettes*  
22 *adultes (crâne et squelette du tronc)*. Masson, Paris.
- 23 Heim, J-L (1982a) *Les hommes fossiles de La Ferrassie. II. Les squelettes d'adultes:*  
24 *squelettes des membres*. Masson, Paris.
- 25 Heim, J-L (1982b) *Les enfants néandertaliens de la Ferrassie. Étude anthropologique et*  
26 *analyse ontogénique des hommes de Néandertal*. Masson, Paris.
- 27 Lebel S, Trinkaus E (2002) A Carious Neandertal Molar from the Bau de l'Aubesier,  
28 Vaucluse, France. Journal of Archaeological Sciences **29**: 555-557.
- 29 Lebel S, Trinkaus E, et al. (2001) Comparative morphology and paleobiology of Middle  
30 Pleistocene human remains from the Bau de l'Aubesier, Vaucluse, France. Proceedings of  
31 the National Academy of Sciences of the United States of America **98**: 11097-11102.
- 32 Lordkipanidze D, Vekua A, et al. (2005) The earliest toothless hominin skull. Nature  
33 **434**: 717-718.
- 34 Maureille B, Laville D, Mennecier P (2008) La Ferrassie 1. In: Vandermeersch, B., Cleyet-  
35 Merle, J.-J., Jaubert, J., Maureille, B., Turq, A. (Eds.), *Première Humanité. Gestes*  
36 *funéraires des Néandertaliens*. Musée National de Préhistoire, Les Eyzies-de-Tayac, p.  
37 100.



- 1 *Maureille B, Van Peer P (1998) Une donnée peu connue sur la sépulture du premier*  
2 *adulte de La Ferrassie (Savignac-de-Miremont, Dordogne)/A little known element*  
3 *concerning the burial of the first adult at La Ferrassie (Savignac-de-Miremont,*  
4 *Dordogne). PALEO 10: 291-301.*
- 5 *Meindl RS, Lovejoy CO, et al. (1985) A revised method of age determination using the os*  
6 *pubis, with a review and tests of accuracy of other current methods of pubic symphyseal*  
7 *aging. American Journal of Physical Anthropology 68: 29-45.*
- 8 *Ruff, C.B., Trinkaus, E., Holliday, T.W., 1997. Body mass and encephalization in*  
9 *Pleistocene Homo. Nature 387: 173-176.*
- 10 *Trinkaus, E., 1985. Pathology and the posture of the La Chapelle-aux-Saints Neandertal.*  
11 *American Journal of Physical Anthropology 67: 19-41.*
- 12 *Trinkaus E (1995) Neanderthal mortality patterns. Journal of Archaeological Sciences*  
13 *22: 121-142.*
- 14 *Trinkaus E, Churchill SE, Ruff CB (1994). Postcranial robusticity in Homo. II: humeral*  
15 *bilateral asymmetry and bone plasticity. American Journal of Physical Anthropology 93:*  
16 *1-34.*
- 17 *White TD, Folkens PA (2005) The human bone manual. Elsevier Academic Press, New*  
18 *York.*

19

## 20 **Further Reading:**

- 21 *Pettitt, P.B., 2011. The Paleolithic origins of human burial. Routledge, London.*
- 22 *Rendu W, Beauval C, et al. (2014). Evidence supporting an intentional Neandertal burial*  
23 *at La Chapelle-aux-Saints. Proceedings of the National Academy of Sciences 111:81e86.*

24

## 25 **Glossary:**

26 Ear ossicles: Inside the middle ear, three bones contribution to the transmission of the  
27 sounds. Their names are malleus, incus, and stapes (hammer, anvil, and stirrup).

28 *Homo neanderthalensis*: that is the species name of the Neandertal group. It was  
29 proposed in 1864. Long discussion about the status has led to the more frequent use of  
30 Neandertals (that should not be written with a h because of an orthographic revision of  
31 the german language, only the original species name cannot change). Despite the  
32 evidence of interbreeding with modern humans, their distinct morphology in many parts  
33 of the skeleton warrant an specific name in paleontological terms.

34 Paleopathology: the study of the pathologies of past humans. This is a difficult field of  
35 research as the patient cannot explain his health status and in the case of  
36 paleoanthropology, the only available information concerns hard tissues.

37 Virtual Anthropology: Imaging methodologies have now a huge place in  
38 paleoanthropological sciences. They allow the study of internal characteristics of fragile,

1 rare and irreplaceable patrimonial object. The MNHN in Paris has its own high-resolution  
2 imaging system dedicated to patrimonial and natural sciences, within the AST-RX  
3 platform, UMS 2700 (<http://www.ums2700.mnhn.fr/>). Information about the imaging  
4 dataset are available on <https://3dtheque.mnhn.fr/>.


## 5 **Figures**

6 Figure 1. Discovery of the La Ferrassie 1 Neandertal, view of the site (photo by M. Lucas  
7 on September the 28<sup>th</sup>, 1909) and during the cleaning of the block that contained the  
8 neck and the head (photo by J.L. Heim).

9 Figure 2: The three ossicles of La Ferrassie 1, imaged thanks to AST-RX and  
10 reconstructed in 3D at a resolution of 23.65 microns.

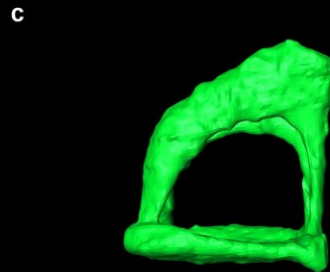
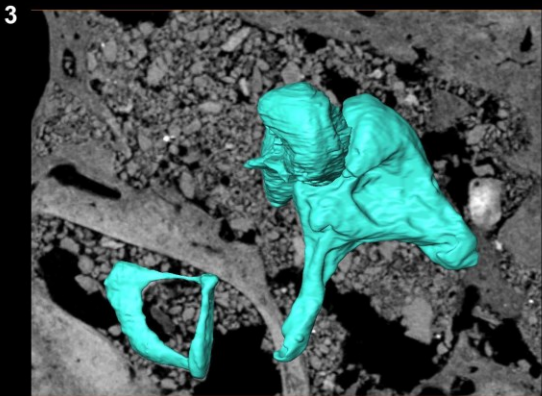
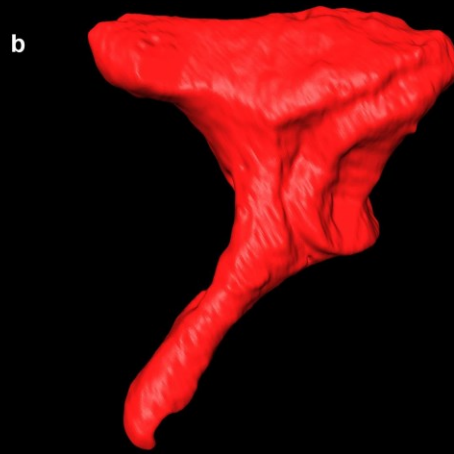
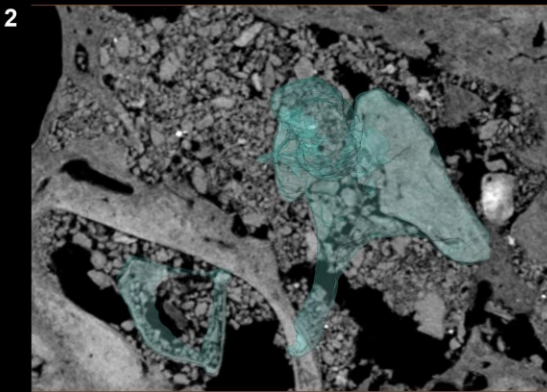
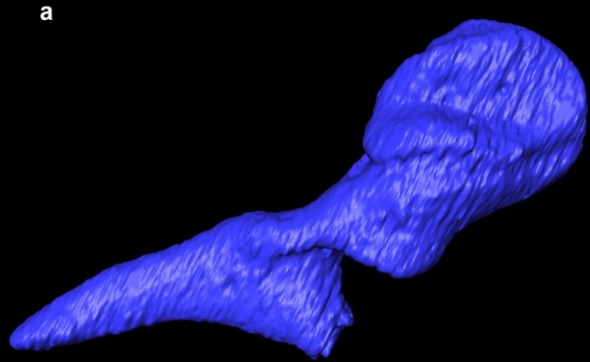
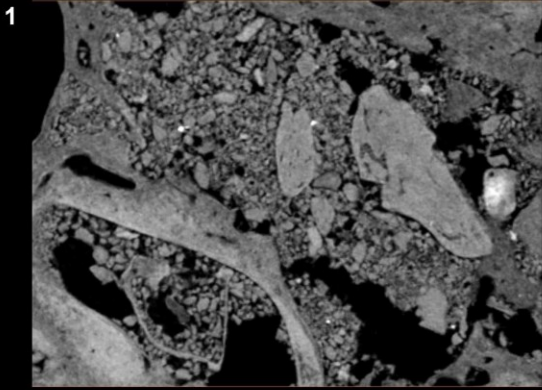
11 Figure 3: Schematic view of the skeleton of La Ferrassie 1 and the representation of the  
12 different pathologies present in this individual. On the left we have represented the  
13 traumatic lesions which consist in a fracture of the left clavicle and a fracture of the  
14 greater trochanter of the right femur. In the center, we have represented the  
15 periostitis/remodeling lesions which are, at least in the case of the limb and feet bones  
16 related to a hypertrophic pulmonary osteoarthropathy. On the right, other lesions are  
17 represented: i.e., the oral pathologies and the scoliosis of the vertebral column.

18



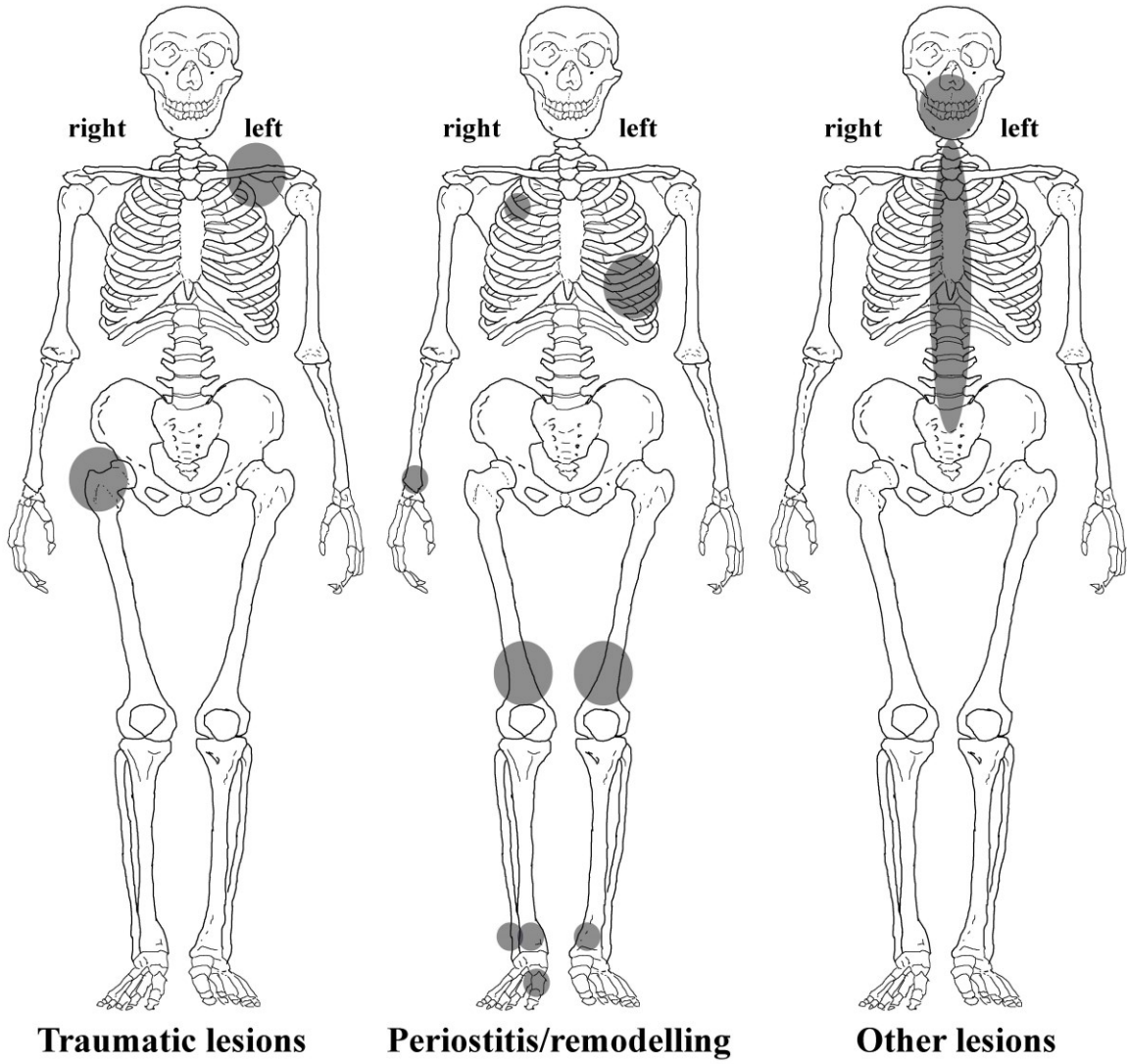
19

20



1

2



1