



**HAL**  
open science

## **Sneathia amnii, an unusual pathogen in spondylitis: A case report**

Claire Duployez, Rémi Le Guern, Emmanuel Faure, Frederic Wallet, Caroline Loïez

► **To cite this version:**

Claire Duployez, Rémi Le Guern, Emmanuel Faure, Frederic Wallet, Caroline Loïez. Sneathia amnii, an unusual pathogen in spondylitis: A case report. Anaerobe, 2020, 66, pp.102277. 10.1016/j.anaerobe.2020.102277 . hal-03002358

**HAL Id: hal-03002358**

**<https://hal.science/hal-03002358v1>**

Submitted on 12 Nov 2020

**HAL** is a multi-disciplinary open access archive for the deposit and dissemination of scientific research documents, whether they are published or not. The documents may come from teaching and research institutions in France or abroad, or from public or private research centers.

L'archive ouverte pluridisciplinaire **HAL**, est destinée au dépôt et à la diffusion de documents scientifiques de niveau recherche, publiés ou non, émanant des établissements d'enseignement et de recherche français ou étrangers, des laboratoires publics ou privés.

1 **CATEGORY:** Case report

2 **TITLE:** *Sneathia amnii*, an unusual pathogen in spondylitis : a case report

3 **AUTHORS :** Claire Duployez<sup>a,b</sup>, Rémi Le Guern<sup>a,b</sup>, Emmanuel Faure<sup>b,c</sup>, Frédéric Wallet<sup>a</sup>,  
4 Caroline Loïez<sup>a</sup>.

5 **AUTHORS AFFILIATIONS :**

6 <sup>a</sup> CHU Lille, Service de Bactériologie-Hygiène, Centre de Biologie-Pathologie, F 59000 Lille,  
7 France

8 <sup>b</sup> Faculté de Médecine de Lille, Université de Lille Nord de France, Lille, France.

9 <sup>c</sup> CHU Lille, Service des Maladies Infectieuses, Hôpital Claude Huriez, F 59000 Lille, France

10 **CORRESPONDING AUTHOR :** Claire Duployez

11 claire.duployez@chru-lille.fr

12 Laboratoire de Bactériologie - Institut de Microbiologie

13 Centre de Biologie Pathologie

14 F-59037 – Lille Cedex, France

15 Telephone number: +33-320.445.480

16 Fax number: +33-320.444.895

17

18

19 **ABSTRACT**

20 *Sneathia amnii* is an opportunistic pathogen of the female reproductive tract that has been  
21 reported to cause infections during pregnancy and in the post-partum period. Infections  
22 outside the reproductive tract have rarely been described. We report the case of a spondylitis  
23 due to *S. amnii* in a 72-year old woman, successfully treated with a course of antibiotic therapy  
24 for 7 weeks. Growth of this pathogen guided our diagnosis towards a gynecological  
25 pathology; we discovered an endometrium adenocarcinoma. This case emphasizes the need  
26 for adequate incubation of discal biopsies, both using aerobic and anaerobic enrichment broth  
27 and prolonging delay of culture of negative samples.

28

29 **KEYS WORDS :** *Sneathia amnii*; Spondylitis; Endometrium adenocarcinoma; 16S rDNA  
30 sequencing; Case report

31

32

## 33 **1. Introduction**

34 *Sneathia amnii* (formerly *Leptotrichia amnionnii*) is a fastidious anaerobic Gram-negative rod  
35 considered as an opportunistic pathogen of the female reproductive tract. *Sneathia* species  
36 have been associated with bacterial vaginosis and with various obstetric complications  
37 including spontaneous abortions, preterm labor and post-partum bacteremia [1]. Infections  
38 outside the reproductive tract have rarely been described. We report a case of *S. amnii*  
39 spondylitis linked to an endometrium adenocarcinoma and review the literature on this  
40 pathogen.

## 41 **2. Case report**

42 A 72-year old woman with a previous history of heart disease and type 2 diabetes was  
43 admitted to the emergency department for a disabling back pain evolving for one week, not  
44 controlled by morphine. She did not report deterioration of her general condition. On  
45 admission, she presented with fever (38.3°C), lower back and paravertebral pain, without  
46 sepsis nor neurological signs. Laboratory tests showed biological inflammatory syndrome (C-  
47 Reactive Protein at 142 mg/L), hyperleukocytosis (19690/mm<sup>3</sup>), anemia (9,9 g/dL).  
48 Dorsolumbar MRI showed a L3-L4 spondylitis with a small anterior abscess, infiltration of  
49 the psoas and epiduritis. Blood cultures (Bact-Alert3D; BioMérieux, Marcy l'Etoile, France)  
50 remained sterile. Discal biopsies were sampled. An inflammatory tissue with many  
51 neutrophils was described by anatomopathologic analysts. In bacteriology, a Gram-negative  
52 nonmotile bacilli grew in Wilkins-Chalgren anaerobic broth at the third day of incubation  
53 while aerobic broth remained sterile. Subculture was performed on Columbia agar with blood  
54 5% anaerobically incubated at 35°C for 6 days. On blood agar, colonies were flat, crystalline  
55  $\alpha$ -hemolytic, with a diameter of approximately 1 mm. Catalase and oxidase were negative.  
56 On the Gram stain, bacteria appeared as long and short Gram-negative rods (Figure A).  
57 Bacteria were identified as *S. amnii* using MALDI-TOF spectrometry mass (Bruker Daltonics,

58 Wissembourg, France) and 16S rDNA sequencing (377 ABI Prism; PE Applied Biosystems,  
59 Foster City, CA., USA). *In vitro* susceptibility tests performed by disk diffusion method with  
60 an inoculum of 1 McFarland on Brucella agar with vitamin K1 and blood 5%, according to  
61 the procedure and interpretation criteria proposed by the Comité de l'Antibiogramme de la  
62 Société Française de Microbiologie (CA-SFM EUCAST 2019) ([http://www.sfm-](http://www.sfm-microbiologie.org)  
63 [microbiologie.org](http://www.sfm-microbiologie.org)), showed susceptibility to amoxicillin-clavulanic acid, tetracycline,  
64 clindamycin, rifampicin, and metronidazole. New discal biopsies were sampled 4 weeks later.  
65 The same bacteria yielded in 14 days in the anaerobic broth and the subculture in 12 days  
66 more on Columbia agar with 5 % blood. Both vertebral biopsies cultures being positive with  
67 *S. amnii* alone, since gynecological entrance wound was highlighted in the patient, the  
68 contribution of other micro-organisms such as streptococcus and other anaerobic bacteria  
69 remained unclear but plausible and was considered for antimicrobial therapy. The presence of  
70 complications with abscess and epiduritis was also taken into account. Treatment was initiated  
71 with association of intravenous amoxicillin-clavulanic acid and metronidazole for 10 days to  
72 enlarge microbiological spectrum, further replaced by clindamycin plus metronidazole for 6  
73 weeks since psoas abscess and epiduritis had promptly disappeared.  
74 Because of these microbiological findings and given that *S. amnii* is part of the genital tract, a  
75 gynecological examination was performed: a large uterine fibroid was discovered, later  
76 identified as an endometrium adenocarcinoma, with a significant increase of CA125 level (86  
77 U/mL). The patient later revealed that she had metrorrhagia since one year.

78

79

### 80        3. Discussion

81    The review of the literature on *S. amnii* related various cases of infections associated with the  
82    female genital tract or delivery : upper genital tract infections, chorioamnionitis, abortion,  
83    stillbirth, postnatal sepsis and neonatal infections such as meningitis [2,3,4,5]. Only few cases  
84    of infections outside the urogenital tract have been described : an urinary tract infection in a  
85    renal transplant [6], a renal abscess occurring 5 weeks after vaginal delivery [7], an arthritis in  
86    a diabetic and hemodialysis man [8], an epidural abscess following hysteroscopy [9] and a  
87    spondylitis in a context of endometrium adenocarcinoma (our case) .

88    To our knowledge, our description is the first of a *S. amnii* spondylitis in a patient with  
89    gynecological cancer. *In vitro*, Harwich et al. pointed out *S. amnii* ability to adhere and its  
90    high cytotoxic potential for cervical epithelial cells [1]. Recent studies evocated increase of  
91    *Sneathia* sp. in vaginal flora of patients with cervical cancer [10-12]. However, these  
92    observations need to be strengthened and may not be transposable to endometrium  
93    adenocarcinoma.

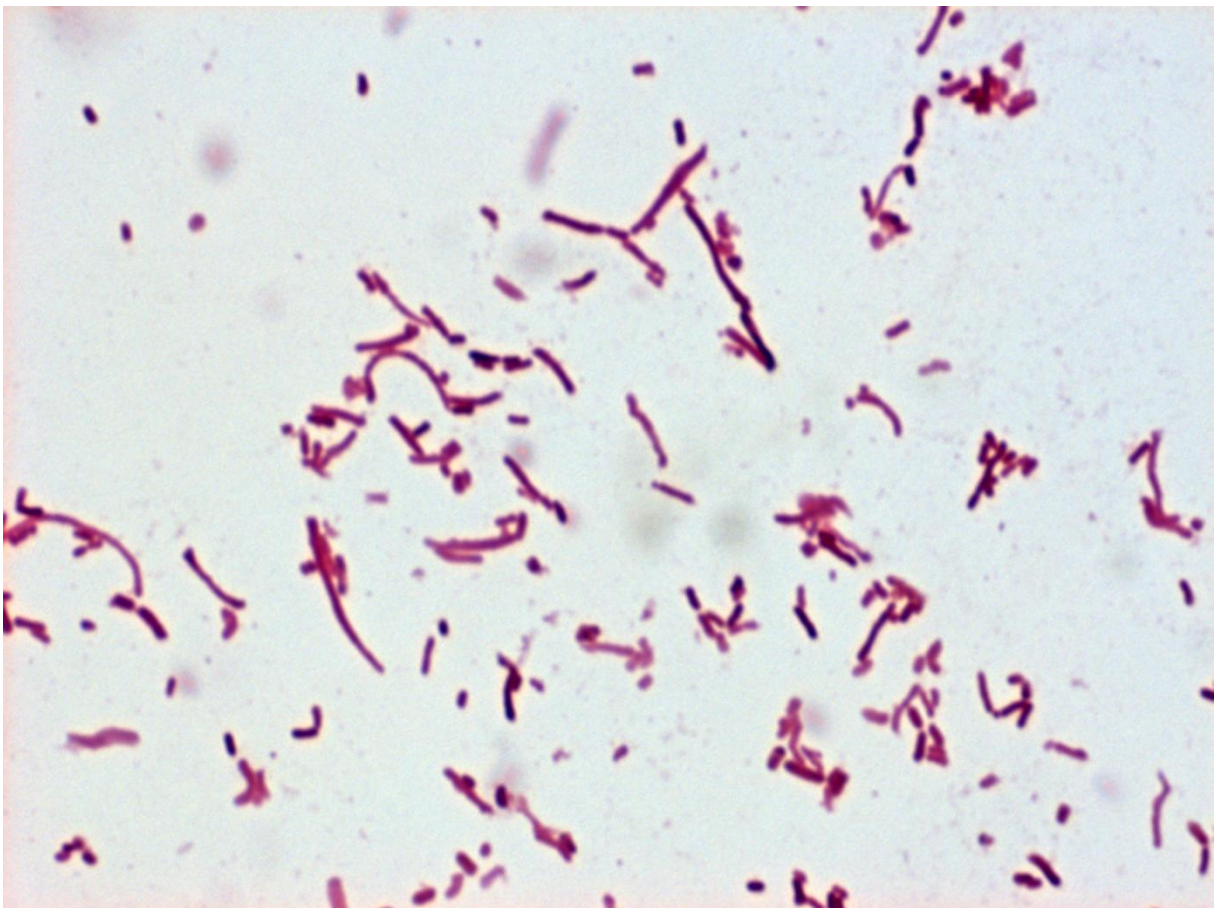
94    Anaerobes are rare causes of spondylitis since they are observed in less than 4% of cases [13,  
95    14]. Indeed, *Staphylococcus aureus* is the predominant pathogen accounting for half of non-  
96    tuberculosis spondylitis, followed by *Enterobacteriaceae*, *Pseudomonas aeruginosa*,  
97    coagulase-negative staphylococci and streptococci [13]. Blood cultures are the first way to  
98    obtain a microbiological diagnosis of spondylitis and were positive in 66.0% out of the 194  
99    documented cases in the serie by Amsilli et al. These authors recommend to perform vertebral  
100    biopsies as a second line technique since they documented 89.4% of cases without positive  
101    blood culture, and particularly, yielded all anaerobes of their serie [14]. In other studies, 39%  
102    of biopsy cultures in suspected cases of spondylitis were negative [13]. In this context,  
103    anaerobes such as *S. amnii* may be underestimated organisms since they are fastidious and  
104    slow-growing bacteria. Some authors thus consider use of broad range PCR as a valuable

105 adjunct to standard cultures for culture-negative vertebral biopsies [13]. To our view, it  
106 mostly emphasizes the need for adequate incubation of these samples, both using aerobic and  
107 anaerobic enrichment broth and prolonging delay of culture of negative samples. Indeed, in  
108 our case, culture of *S. amnii* has been essential for gynecological cancer diagnosis (since it has  
109 led us to perform a gynecological examination), more than for spondylitis treatment (since it  
110 is a very antibiotic-susceptible bacterium).

111

112

113 **FIGURE A**



114

115 **Gram stain of *Sneathia amnii*.** Gram stain from colonies on blood agar, image taken at  
116 magnification 1000x. Presence of long and short Gram-negative rods.

117 **DECLARATIONS OF INTEREST** : none

118 **FUNDING SOURCE** : This research did not receive any specific grant from funding  
119 agencies in the public, commercial, or not-for-profit sectors.

120 **ACKNOWLEDGMENTS** : We thank Antonino Bongiovanni of the BICeL Facility for  
121 access to systems and technical advice.

122 **REFERENCES:**

- 123 1. Harwich MD Jr, Serrano MG, Fettweis JM, Alves JM, Reimers MA; Vaginal  
124 Microbiome Consortium (additional members), Buck GA, Jefferson KK. Genomic  
125 sequence analysis and characterization of *Sneathia amnii* sp. nov. BMC Genomics.  
126 2012;13 Suppl 8:S4. doi: 10.1186/1471-2164-13-S8-S4.
- 127 2. Masschaele T, Steyaert S, Goethals R. *Leptotrichia Amnionii*, an emerging pathogen  
128 of postpartum endometritis. Acta Clin Belg. 2018 Oct;73(5):368-371. doi:  
129 10.1080/17843286.2017.1392090.
- 130 3. Vitorino P, Varo R, Castillo P, Hurtado JC, Fernandes F, Valente AM, Mabunda R,  
131 Mocumbi S, Gary JM, Jenkinson TG, Mandomando I, Blau DM, Breiman RF, Bassat  
132 Q. *Sneathia amnii* and Maternal Chorioamnionitis and Stillbirth, Mozambique. Emerg  
133 Infect Dis. 2019 Aug;25(8):1614-1616. doi: 10.3201/eid2508.190526.
- 134 4. Decroix V, Goudjil S, Kongolo G, Mammeri H. '*Leptotrichia amnionii*', a newly  
135 reported cause of early onset neonatal meningitis. J Med Microbiol. 2013 May;62(Pt  
136 5):785-788. doi: 10.1099/jmm.0.051870-0.
- 137 5. Shukla SK, Meier PR, Mitchell PD, Frank DN, Reed KD. *Leptotrichia amnionii* sp.  
138 nov., a novel bacterium isolated from the amniotic fluid of a woman after intrauterine  
139 fetal demise. J Clin Microbiol. 2002 Sep;40(9):3346-9.



- 140 6. Domann E, Hong G, Imirzalioglu C, Turschner S, Kühle J, Watzel C, Hain T, Hossain  
141 H, Chakraborty T. Culture-independent identification of pathogenic bacteria and  
142 polymicrobial infections in the genitourinary tract of renal transplant recipients. *J Clin*  
143 *Microbiol.* 2003 Dec;41(12):5500-10.
- 144 7. Thilesen CM, Nicolaidis M, Lökebö JE, Falsen E, Jorde AT, Müller F. *Leptotrichia*  
145 *amnionii*, an emerging pathogen of the female urogenital tract. *J Clin Microbiol.* 2007  
146 Jul;45(7):2344-7.
- 147 8. Goto M, Hitomi S, Ishii T. Bacterial arthritis caused by *Leptotrichia amnionii*. *J Clin*  
148 *Microbiol.* 2007 Jun;45(6):2082-3.
- 149 9. Rao P, Chan M. *Sneathia amnii* epidural abscess following hysteroscopy : a case  
150 report. 27<sup>th</sup> ECCMID, 25 April 2017, Vienna, Austria. Session P087 Progress in bone  
151 and joint infections. Cat 2e Skin, soft tissue, bone and joint and central nervous system  
152 infection. P1822.  
153 [https://www.escmid.org/escmid\\_publications/escmid\\_elibrary/?q=sneathia+amnii&id](https://www.escmid.org/escmid_publications/escmid_elibrary/?q=sneathia+amnii&id=2173&L=0&x=0&y=0)  
154 [=2173&L=0&x=0&y=0](https://www.escmid.org/escmid_publications/escmid_elibrary/?q=sneathia+amnii&id=2173&L=0&x=0&y=0)
- 155 10. Zhang Z, Zhang D, Xiao BB, Zhang R, Bai HH, Dong HY, Bi H, Liu ZH. Primary  
156 study on the relationship between high-risk HPV infection and vaginal cervical  
157 microbiota. *Zhonghua Fu Chan Ke Za Zhi.* 2018 Jul 25;53(7):471-480. doi:  
158 10.3760/cma.j.issn.0529-567x.2018.07.006.
- 159 11. Audirac-Chalifour A, Torres-Poveda K, Bahena-Román M, Téllez-Sosa J, Martínez-  
160 Barnetche J, Cortina-Ceballos B, López-Estrada G, Delgado-Romero K, Burguete-  
161 García AI, Cantú D, García-Carrancá A, Madrid-Marina V. Cervical Microbiome and  
162 Cytokine Profile at Various Stages of Cervical Cancer: A Pilot Study. *PLoS One.*  
163 2016 Apr 26;11(4):e0153274. doi: 10.1371/journal.pone.0153274.

- 164 12. Nawrot R, Kamieniarz K, Malinowska M, Józefiak A, Kedzia W, Kwaśniewska A,  
165 Kuźma D, Goździcka-Józefiak A. The prevalence of leptotrichia amnionii in cervical  
166 swabs of HPV positive and negative women. *Eur J Gynaecol Oncol.* 2010;31(4):425-  
167 8.
- 168 13. Gouliouris T, Aliyu SH, Brown NM. Spondylodiscitis: update on diagnosis and  
169 management. *J Antimicrob Chemother.* 2010;65 Suppl 3:iii11-iii24.  
170 doi:10.1093/jac/dkq303
- 171 14. Amsilli M, Epaulard O. How is the microbial diagnosis of bacterial vertebral  
172 osteomyelitis performed? An 11-year retrospective study. *Eur J Clin Microbiol Infect*  
173 *Dis.* 2020;10.1007/s10096-020-03929-1. doi:10.1007/s10096-020-03929-1