



**HAL**  
open science

## **Structural and functional abnormalities within sensori-motor and limbic networks underpin intermittent explosive symptoms in Tourette disorder**

Cyril Atkinson-Clement, Fuaad Sofia, Emilio Fernandez-Egea, Astrid de Liege, Benoit Beranger, Yanica Klein, Emmanuelle Deniau, Emmanuel Roze, Andreas Hartmann, Yulia Worbe

### ► To cite this version:

Cyril Atkinson-Clement, Fuaad Sofia, Emilio Fernandez-Egea, Astrid de Liege, Benoit Beranger, et al.. Structural and functional abnormalities within sensori-motor and limbic networks underpin intermittent explosive symptoms in Tourette disorder. *Journal of Psychiatric Research*, 2020, 125, pp.1-6. 10.1016/j.jpsychires.2020.02.033 . hal-02992212

**HAL Id: hal-02992212**

**<https://hal.science/hal-02992212>**

Submitted on 20 May 2022

**HAL** is a multi-disciplinary open access archive for the deposit and dissemination of scientific research documents, whether they are published or not. The documents may come from teaching and research institutions in France or abroad, or from public or private research centers.

L'archive ouverte pluridisciplinaire **HAL**, est destinée au dépôt et à la diffusion de documents scientifiques de niveau recherche, publiés ou non, émanant des établissements d'enseignement et de recherche français ou étrangers, des laboratoires publics ou privés.



Distributed under a Creative Commons Attribution - NonCommercial 4.0 International License

## **Structural and functional abnormalities within sensori-motor and limbic networks underpin intermittent explosive symptoms in Tourette disorder**

Cyril Atkinson-Clement PhD<sup>1</sup>, Fuaad Sofia MS<sup>2</sup>, Emilio Fernandez-Egea MD, PhD<sup>3</sup>, Astrid de Liege MD<sup>1,4</sup>, Benoit Beranger PhD<sup>5</sup>, Yanica Klein PhD<sup>1,4</sup>, Emmanuelle Deniau MD<sup>1,4</sup>, Emmanuel Roze<sup>1</sup>, MD, PhD, Andreas Hartmann MD<sup>1,4</sup>, Yulia Worbe MD, PhD<sup>1,4,6</sup>

**1** Sorbonne University, 75005 Paris, Inserm U1127, CNRS UMR7225, UM75, ICM, F-75013, Paris, France. Movement Investigation and Therapeutics Team, Paris, France.

**2** Department of Psychology, University of Oslo, 0373 Oslo, Norway.

**3** Department of Psychiatry and Behavioural and Clinical Neuroscience Institute, University of Cambridge, Cambridge, UK.

**4** National Reference Center for Tourette syndrome, Assistance Publique des Hôpitaux de Paris, Groupe Hospitalier Pitié-Salpêtrière, F-75013, Paris, France.

**5** Centre de NeuroImagerie de Recherche (CENIR), Sorbonne Université, UMRS975, CNRS UMR7225, ICM, F-75013, Paris, France.

**6** Department of Neurophysiology, Saint Antoine Hospital, Assistance Publique-Hôpitaux de Paris, France.

### **Corresponding author:**

Dr Yulia Worbe, MD, PhD  
Sorbonne University & Department of Neurophysiology  
Saint-Antoine Hospital, Paris, France  
Email: [yulia.worbe@aphp.fr](mailto:yulia.worbe@aphp.fr)

**Word count (excl. References):** 2,920

**Abstract word count:** 213

**Ref:** 39

**Figures & Tables:** 4

## **ABSTRACT**

**Background:** Intermittent explosive outbursts (IEO), manifesting as sudden episodes of verbal or physical aggression, are frequently present in patients with Tourette disorder (TD) and considered as one of the most disabling symptoms by patients and families. The neuronal correlates of these behaviours are poorly understood, and this was the primary objective of the present study.

**Methods:** We assessed the presence of IEO in 55 patients with TD and then compared the subgroup of the patients with IEO to those without these manifestations using a multimodal neuroimaging approach.

**Results:** 47 % of TD patients presented IEO, which was frequently associated with attention deficit hyperactivity disorder (ADHD). TD patients (without ADHD) with IEO compared to TD without IEO, showed structural changes in the right supplementary motor area as well as in the right hippocampus (increased fractional anisotropy), and in the left orbitofrontal cortex (decreased mean diffusivity). Using these three nodes as seeds for resting state functional connectivity, we showed a lower connectivity within the sensori-motor cortico-basal ganglia network, and an altered connectivity pattern among the orbito-frontal cortex, amygdala and hippocampus.

**Conclusions:** Overall, our results indicate that TD with IEO is associated with brain dysfunction related to a less efficient top-down control on action selection, and impairments related to emotional regulation, impulse control and aggressive behaviours.

**Keywords:** Tics; Aggressivity; MRI; Inhibition; Pathophysiology

## INTRODUCTION

Tourette's disorder (TD), primary characterized by motor and vocal tics, is frequently associated with psychiatric comorbidities and behavioural symptoms. Depression, anxiety, obsessive-compulsive disorder (OCD), and attentional deficit hyperactivity disorder (ADHD) are considered to be the most frequently associated with tics (Hirschtritt et al., 2015).

Intermittent explosive outbursts (IEO), also referred to "*rage attacks*", are often seen in patients with TD, mostly in those with psychiatric comorbidities. IEO are the one of the most disabling symptoms, and cause immense distress for patients, families, and caregivers (Budman et al., 2015). As defined by the Diagnostic and Statistical Manual of Mental Disorders (DSM-V; (American Psychiatric Association, 2013). IEO manifest as sudden episodes of verbal or physical aggression, which are disproportionate to the given situation and usually occur with little to no warning. Previous studies on IEO in TD found these manifestations in a large proportion of patients (from 25 to 70 %) and were frequently associated with more severe tics and the presence of ADHD or OCD comorbidities (Budman et al., 2000, 1998; Chen et al., 2013). However, some of these studies pointed to the fact that IEO could also occur in patients with typical TD without any significant associated psychopathology (Chen et al., 2013; Sambrani et al., 2016). In TD patients with IEO and without significant associated psychiatric comorbidities the prevalence decreased to 5 % (Chen et al., 2013).

TD and IEO have some common morphological and functional features raising the possibility of a partly shared pathogenesis. For instance, thinning of the orbitofrontal cortex (OFC) in patients with mild traumatic brain injury (Epstein et al., 2016) and inactivation of the ventral and lateral OFC in animal models was related to aggressive behaviours (Kuniishi et al., 2016). Other brain

regions, such as the amygdala, hippocampus, hypothalamus, and anterior and retrosplenial cingulate cortices were also related to the expression of aggressive behaviours in humans and animals (Ferris et al., 2008, p. 200; Leroy et al., 2018).

In TD, the dysfunction of the cortico-basal ganglia networks is considered to be one of the main pathophysiological mechanisms, with a particular focus on sensori-motor networks as the main generator of the tics (Rae et al., 2018). However, dysfunction of several brain regions implicated in the generation of aggressive behaviours was also found in TD. In particular the OFC, hippocampus, amygdala and anterior cingulate cortex were related to premonitory urges, control over tics, and the presence of associated psychopathology such as OCD (Martino et al., 2018; Worbe et al., 2010).

Despite the relevance and frequency of the aggressive behaviours seen in TD, the neuronal underpinnings of these behaviours are poorly understood. We hypothesized that patients with TD and aggressive outbursts would present a specific alteration within the brain regions previously linked to aggressive behaviours compared to those without IEO.

## **MATERIAL AND METHODS**

### **Patients**

We analysed available data from a larger study on impulsivity in TD. 55 adult patients with TD were included in the study from the specialized Tourette disorder clinic (Pitié-Salpêtrière hospital, Paris, France) and assessed prior to inclusion by a multidisciplinary team. All procedures comply

with the ethical standards of the relevant national and institutional committees on human experimentation and with the Helsinki Declaration of 1975, as revised in 2008.

For all patients, the exclusion criteria were an incapability or unwillingness to give consent for the study and incompatibility with MRI scanning as well as present substance addiction (excluding nicotine; recreational cannabis use was allowed), a past or present history of psychosis and a presence of neurological symptoms other than tics.

All patients were assessed for psychiatric disorders (French version of the Mini International Neuropsychiatric interview, MINI; (Sheehan et al., 1998)), impulse-control disorders (Minnesota Impulse Disorders Interview, MIDI; (Grant, 2008)), impulsivity (using the Barratt Impulsivity scale, BIS-11; (Patton et al., 1995)), and anxiety with the State-Trait Anxiety Inventory (STAI; (Hamilton, 1959)). Yale Global Tics Severity Scale (YGTSS; (Leckman et al., 1989)) was used to assess tics severity, and the presence of psychiatric comorbidities was evaluated using patient medical records and psychiatric evaluations prior to their inclusion in the study. Prior to inclusion in the protocol, patients with TD were also assessed by a multidisciplinary team for common psychiatric comorbidities (OCD and ADHD) using the DSM-V criteria (American Psychiatric Association, 2013). An IEO diagnosis was based on the MIDI as well as medical notes and a face to face interview, and was made according to the DSM-V definition (American Psychiatric Association, 2013): several episodes of inability to inhibit aggressive impulses; aggressivity out of proportion and not explained by psychosocial causes; aggressivity not explained by psychiatric or neurological disorders or substance effects.

## **Neuroimaging data**

Neuroimaging data were acquired using 3T MRI scans (Siemens Prisma, Germany) with a 64-channel head coil. Multimodal MRI protocol was used with the sequences as followed:

i) T1-weighted images (MP2RAGE; TR = 5s, TI = 700/2500ms, fov = 256, 1mm isotropic, Ipat acceleration of 3) were first denoised and pre-processed (segmentation, normalization to Montreal Neurological Institute space and smoothing at 10mm) using the Computational Anatomy Toolbox ([www.neuro.uni-jena.de/cat/](http://www.neuro.uni-jena.de/cat/)) extension from SPM12 ([www.fil.ion.ucl.ac.uk/spm/](http://www.fil.ion.ucl.ac.uk/spm/)).

ii) A multi-echo echo-planar imaging (EPI) sequence was performed for the resting states, with a multi-slice, multi-echo acquisition scheme (TR = 1.9s, TE = 17/36/56ms, Ipat acceleration factor 2, Multi-band 2, isotropic voxel size 3mm) and were processed with the MEICA toolbox ([www.github.com/ME-ICA/me-ica/](http://www.github.com/ME-ICA/me-ica/)). This toolbox implements standard pre-processing steps: slice timing correction and realignment to the first volume driven by the first echo, and coregistration to the anatomic volume. A single warp was applied to combine realignment and coregistration. Then, we performed a principal component analysis to reduce the dimensionality of the dataset by removing thermal noise, and an independent component analysis decomposition to separate BOLD (blood-oxygen-level dependent) from non-BOLD components based on the echo time dependence of the BOLD component. After the independent component analysis, we obtained a dataset where both thermal noise and physiological noise such as movements, respiration artefacts, and cardiac artefacts were removed. Finally, we normalized the dataset using the flow field generated by the T1 processing from CAT12.

iii) A multi-shell diffusion tensor imaging (DTI) acquisition was also performed (TR = 3.5s, TE = 75ms, Multi-band of 3, isotropic voxel size 1.75mm, 60 direction with  $b = 2000 \text{ s/mm}^2$ , 32 direction with  $b = 1000 \text{ s/mm}^2$  and 8 direction with  $b = 300 \text{ s/mm}^2$ , one  $b = 0$  was each 10 directions). Data pre-processing was performed using the FMRIB software library (FSL) pipeline

to extract fractional anisotropy (FA) and mean diffusivity (MD), involving correction for motion and eddy currents, removal of non-brain tissue of each volumes, tensor reconstruction, non-linear registration, alignment to the MNI space and thresholding data at 0.2.

### **Statistical analyses**

First, for both T1 and DTI metrics, we performed group whole-brain voxel-based analyses using the total intracranial volume as a nuisance variable. Second, for fMRI analysis, we used the AAL atlas to perform functional connectivity between the regions of interest (ROI) found during structural analysis to discriminate patients with and without IEO (selected bilaterally), and all the other AAL ROI, using the DPSARF toolbox implemented in SPM12 (<http://rfmri.org/DPARSEF>). Functional connectivity statistics were performed in two time involving systematical t-tests (threshold at  $p \leq 0.05$ ) following permutations adjustments ( $n = 5000$ ): i) One sample t-test to exclude connectivity between two-regions when they were not different from 0; ii) Two-sample t-tests to discriminate patients with TD with and without IEO. Regarding demographics and clinical data, we used two-sample t-tests and chi-square analyses when appropriate, as well as Bayesian analyses to compensate the weak number of participants. All statistics were performed using the statistical R software.

## **RESULTS**

### **Clinical characteristics of TD patients with and without aggressive outbursts**

Fifty-five patients with TD were included in the study. As shown in **Table.1**, 26 patients (47 %) presented IEO. In TD patients with IEO, we found higher scores of impulsivity (BIS-11), anxiety



(STAI) and ADHD comorbidity ( $p \leq 0.01$ ). There were no differences in the severity of tics (YGTSS/50) or the presence of comorbid OCD.

-----[TABLE.1]-----

After excluding all cases with an ADHD comorbidity and/or a childhood history of ADHD to avoid a confounding factor ( $n = 25$ ), the final sample included 21 patients with TD without IEO (TD<sub>[no-ADHD]</sub> group) and 9 with IEO (TD-IEO<sub>[no-ADHD]</sub> group). No significant differences between the two groups of patients were found regarding gender, demographics, or clinical data, and were confirmed by both classical and Bayesian statistics (**Table.2**). Among the TD-IEO<sub>[no-ADHD]</sub> group, one subject had past history of OCD and two had active checking behaviour, but no past or current history of obsessive or compulsive symptoms of aggressive content.

-----[TABLE.2]-----

### **Structural and functional neuronal changes in TD patients with aggressive outbursts**

Whole brain voxel-based analysis did not show any significant differences between the TD<sub>[no-ADHD]</sub> and the TD-IEO<sub>[no-ADHD]</sub> groups in grey or white matter intensity. We found an increased FA in the right SMA and hippocampus, and a decreased MD in left OFC in TD-IEO<sub>[no-ADHD]</sub> group (**Fig.1**).

-----[FIG.1]-----

### **Resting state functional connectivity analysis**

Based on structural results, we performed a functional connectivity analysis of the resting state functional MRI using the bilateral SMA, hippocampus and OFC as seed regions, and compared the connectivity maps between the two groups. As shown in **Fig.2.A**, in TD-IEO<sub>[no-ADHD]</sub> patients compared to TD<sub>[no-ADHD]</sub>, the SMA, as a seed region, showed overall decreased connectivity to the basal ganglia (putamen bilaterally and right subthalamic nucleus) and cortical areas, namely temporal (right temporal pole and left middle temporal gyrus), the superior frontal gyrus and the middle cingulate gyrus. The OFC, as a seed region, showed lower connectivity to the left amygdala and the cerebellum (part 10 bilaterally and part 9 right), and higher connectivity with the temporal cortex (right pole, left inferior and middle gyri) in TD-IEO<sub>[no-ADHD]</sub> patients (**Fig.2.B**). The hippocampus, as a seed region, (**Fig.2.C**) showed lower connectivity to the left OFC, right cerebellum (vermis 8 and part 6) and lingual gyrus.

-----[FIG.2]-----

## **DISCUSSION**

We assessed aggressive outbursts in a relatively large group of consecutive TD patients with no associated ADHD, and investigated their neuronal correlates. We found various alterations in the anatomical and functional connectivity between motor and limbic networks that may account for

the pathogenesis of these outbursts, and could be targeted by future experimental therapeutics. Our findings also indicate that some of the patients with TD are more prone to aggressive outbursts due to atypical brain functionality, which may have potential implications for legal issues.

### **Aggressive behaviours in Tourette disorder and associated psychopathology**

Overall, and in agreement with previous studies in adults (Sambrani et al., 2016) and child (Benaroya-Milshtein et al., 2019) patients with TD, our results pointed to the fact that IEO are frequent in TD (47 % in our study), and are usually associated with the presence of ADHD, as 65 % of our patients with TD and IEO also had comorbid ADHD. Moreover, and in agreement with previous studies (Sambrani et al., 2016), we found that a part of our patients (16 %) experienced IEO, which were not associated with the comorbid psychopathology, namely ADHD, suggesting an independent pathophysiological mechanism in these patients.

In contrast with previous findings (Budman et al., 2000, 1998; Chen et al., 2013), we found that our two groups of patients had similar tics severity (YGTSS/50), suggesting a weak or no association between severity of tics and the presence of IEO. However, this latter conclusion should be tempered by the fact that our sample was fairly small when restricted to TD-IEO patients.

### **Structural and functional correlates of IEO in TD**

The neuroimaging part of our study that focused on the TD-IEO group of patients pointed out the abnormal structure and functional connectivity within the sensori-motor and limbic neuronal networks as a potential marker of aggressive behaviours in this group.

### ***Sensori-motor neuronal network in TD patients with IEO***

In TD-IEO<sub>[no-ADHD]</sub> patients we found a higher FA in the SMA and lower connectivity between the SMA and the putamen and subthalamic nucleus.

Indeed, the SMA is involved in action selection (Rowe et al., 2010), suppression (Boy et al., 2010) and evaluation (Scangos et al., 2013) and is also part of a network related to tics severity in TD (Polyanska et al., 2017). It was also shown to be involved in behaviours related to anger control impairment. For example, adolescents with conduct disorder have a lower activity of the pre-SMA (Zhang et al., 2015), whereas patients with borderline personality disorder have an increased SMA gray matter volume (Yang et al., 2016).

The functional connectivity results revealed a lower interaction between the SMA and the putamen and subthalamic nucleus involved in the direct and indirect (putamen) and hyperdirect (subthalamic nucleus) cortico-basal ganglia pathways. Overall, lower connectivity within these networks suggests a less efficient mechanism of action selection and control in TD-IEO patients compared to TD. Moreover, the SMA also had a lower connectivity with temporal, prefrontal and dorsal cingulate cortices, known for their implication with anger regulation and threat appraisal (Achterberg et al., 2018; Klimecki et al., 2018). All together, these results pointed to abnormal integration within a network related to anger regulation, as well as less efficient top-down control on action selection.

These results offer a theoretical framework that suggests that TD-IEO patients could face more difficulties with anger regulation as well as appropriate action selection and action control, which could trigger seemingly uncontrollable aggressive behaviours as seen in IEO.

***Limbic neuronal network in TD patients with IEO***

Two limbic regions, the OFC and the hippocampus, showed structural abnormalities and abnormal functional connectivity in TD-IEO<sub>[no-ADHD]</sub>. Namely, these patients showed a lower MD in the OFC, suggesting a lower cellular density in this region, and a higher FA in the hippocampus, which could reflect higher axonal input or output from this structure. Grey matter reduction in the OFC was previously found in patients with IEO (Coccaro et al., 2011), but also in increased aggressivity following a focal OFC injury (Brower and Price, 2001). Interestingly, in animal models, chemical and electric activation of the hippocampus elicits aggressive behaviours (Leroy et al., 2018). Moreover, animal models of aggressive behaviours elicited by peripubertal stress, showed structural abnormality in frontal cortical areas, the hippocampus and the amygdala only in animals with a high aggressiveness (Walker et al., 2018), suggesting a specific role of this network in aggressive behaviours. The results of our functional connectivity analyses are in line with animal models findings, as they showed a lower functional connectivity between the OFC and the hippocampus, amygdala, and cerebellum.

According to the proposed neuroanatomical model of impulsive aggressive behaviours (Coccaro et al., 2011), the OFC plays a role in emotional regulation and impulse control (Rudebeck et al., 2008), while the hippocampus is involved with socio-emotional information processing as a part of decision-making networks, and in choosing between initiating or suppressing aggressive behaviours. Finally, the amygdala was suggested to be a part of the network generating the aggressive impulses. According to this model, a lower functional connectivity among these regions in patients with TD-IEO could reflect a poorer impulse and / or emotional control, and less efficient decision-making, facilitating aggressive actions.

Our results further support a role for the cerebellum in aggressive behaviours. The cerebellum has not been classically linked to aggressivity, even if some studies showed abnormal cerebellar

structure in patients with aggressive behaviours and psychosis (Widmayer et al., 2018), or the development of aggressivity after a cerebellar stroke (Tessier et al., 2015). There is also a growing evidence in the literature that the cerebellum is crucial for cognitive functioning and flexible behavioural adaptation (Miquel et al., 2019). In this study, we found a lower connectivity of the OFC with the cerebellum. Within the theoretical framework of cerebellar role in the forward model of action adaptation, it might indicate that, in patients with TD-IEO, the cerebellum is failing to adjust the OFC activity in response to external or internal stimuli and consequently to flexibly adapt the behaviour to these stimuli in favour of an aggressive response.

Finally, we also found a higher connectivity between the OFC and temporal cortices. The role of the temporal cortex in aggressive behaviours is well-documented throughout numerous reports of aggressivity in patients with temporal lobe epilepsy (Brodie et al., 2016). The temporal cortex and in particular, the temporal pole, has been linked to the processing of social cues and the integration of contextual information (Pehrs et al., 2017). In line with a previous study on the alteration of social information processing in TD (Rae et al., 2018), our results of higher connectivity between the OFC and temporal pole could suggest a higher sensitivity to social cues in TD-IEO as a potential trigger for aggressive behaviours.

Overall, our results highlighted the abnormal functional and structural connectivity of limbic and sensory motor networks that were specific for patients with TD associated with IEO. Future experimental therapeutic studies with non-invasive brain stimulation of the connection between motor and limbic network would be warranted, especially because both pharmacological (Coccaro et al., 2009) and behavioural (McCloskey et al., 2008) treatments reported interesting but weak IEO improvements. These results also raised the question of legal implication in patients suffering from these manifestations.

### ***Limitations***

The main limitation of this study is a small sample size in TD-IEO patients after the exclusion of patients with comorbid ADHD. This approach allowed us to avoid a major confounding factor and identify the cerebral regions associated with aggressive outbursts. Moreover, the obtained results are in line with other studies that addressed the cerebral correlates of aggressive outbursts in other pathological conditions. However, further studies on even larger groups of TD patients are warranted to confirm our results.

### **CONFLICTS OF INTERESTS**

None of the authors declare any conflict of interest.

### **FINANCIAL SUPPORT**

The study was supported by the National Research Agency (ANR-18-CE37-0008-01), French Tourette Syndrome Association (AFSGT) and Fondation pour la Recherche Medicale (FRM).

### **REFERENCES**

- Achterberg, M., van Duijvenvoorde, A.C.K., van der Meulen, M., Bakermans-Kranenburg, M.J., Crone, E.A., 2018. Heritability of aggression following social evaluation in middle childhood: An fMRI study. *Hum. Brain Mapp.* 39, 2828–2841. <https://doi.org/10.1002/hbm.24043>
- American Psychiatric Association (Ed.), 2013. *Diagnostic and statistical manual of mental disorders: DSM-5*, 5. ed. ed. American Psychiatric Publishing, Washington, DC.

- Benaroya-Milshtein, N., Shmuel-Baruch, S., Apter, A., Valevski, A., Fenig, S., Steinberg, T., 2019. Aggressive symptoms in children with tic disorders. *Eur. Child Adolesc. Psychiatry*. <https://doi.org/10.1007/s00787-019-01386-6>
- Boy, F., Husain, M., Singh, K.D., Sumner, P., 2010. Supplementary motor area activations in unconscious inhibition of voluntary action. *Exp. Brain Res.* 206, 441–448. <https://doi.org/10.1007/s00221-010-2417-x>
- Brodie, M.J., Besag, F., Ettinger, A.B., Mula, M., Gobbi, G., Comai, S., Aldenkamp, A.P., Steinhoff, B.J., 2016. Epilepsy, Antiepileptic Drugs, and Aggression: An Evidence-Based Review. *Pharmacol. Rev.* 68, 563–602. <https://doi.org/10.1124/pr.115.012021>
- Brower, M.C., Price, B.H., 2001. Neuropsychiatry of frontal lobe dysfunction in violent and criminal behaviour: a critical review. *J. Neurol. Neurosurg. Psychiatry* 71, 720–726. <https://doi.org/10.1136/jnnp.71.6.720>
- Budman, C.L., Bruun, R.D., Park, K.S., Lesser, M., Olson, M., 2000. Explosive outbursts in children with Tourette's disorder. *J. Am. Acad. Child Adolesc. Psychiatry* 39, 1270–1276. <https://doi.org/10.1097/00004583-200010000-00014>
- Budman, C.L., Bruun, R.D., Park, K.S., Olson, M.E., 1998. Rage attacks in children and adolescents with Tourette's disorder: a pilot study. *J. Clin. Psychiatry* 59, 576–580.
- Budman, C.L., Rosen, M., Shad, S., 2015. Fits, Tantrums, and Rages in TS and Related Disorders. *Curr. Dev. Disord. Rep.* 2, 273–284. <https://doi.org/10.1007/s40474-015-0059-1>
- Chen, K., Budman, C.L., Diego Herrera, L., Witkin, J.E., Weiss, N.T., Lowe, T.L., Freimer, N.B., Reus, V.I., Mathews, C.A., 2013. Prevalence and clinical correlates of explosive outbursts in Tourette Syndrome. *Psychiatry Res.* 205, 269–275. <https://doi.org/10.1016/j.psychres.2012.09.029>
- Coccaro, E.F., Lee, R.J., Kavoussi, R.J., 2009. A Double-Blind, Randomized, Placebo-Controlled Trial of Fluoxetine in Patients With Intermittent Explosive Disorder. *J. Clin. Psychiatry* 70, 653–662. <https://doi.org/10.4088/JCP.08m04150>
- Coccaro, E.F., Sripada, C.S., Yanowitch, R.N., Phan, K.L., 2011. Corticolimbic function in impulsive aggressive behavior. *Biol. Psychiatry* 69, 1153–1159. <https://doi.org/10.1016/j.biopsych.2011.02.032>
- Epstein, D.J., Legarreta, M., Bueler, E., King, J., McGlade, E., Yurgelun-Todd, D., 2016. Orbitofrontal cortical thinning and aggression in mild traumatic brain injury patients. *Brain Behav.* 6, e00581. <https://doi.org/10.1002/brb3.581>
- Ferris, C.F., Stolberg, T., Kulkarni, P., Murugavel, M., Blanchard, R., Blanchard, D.C., Febo, M., Brevard, M., Simon, N.G., 2008. Imaging the neural circuitry and chemical control of aggressive motivation. *BMC Neurosci.* 9, 111. <https://doi.org/10.1186/1471-2202-9-111>



- Grant, J.E., 2008. *Impulse control disorders: a clinician's guide to understanding and treating behavioral addictions*. W.W. Norton, New York.
- Hamilton, M., 1959. The assessment of anxiety states by rating. *Br. J. Med. Psychol.* 32, 50–55.
- Hirschtritt, M.E., Lee, P.C., Pauls, D.L., Dion, Y., Grados, M.A., Illmann, C., King, R.A., Sandor, P., McMahon, W.M., Lyon, G.J., Cath, D.C., Kurlan, R., Robertson, M.M., Osiecki, L., Scharf, J.M., Mathews, C.A., 2015. Lifetime Prevalence, Age of Risk, and Genetic Relationships of Comorbid Psychiatric Disorders in Tourette Syndrome. *JAMA Psychiatry* 72, 325. <https://doi.org/10.1001/jamapsychiatry.2014.2650>
- Klimecki, O.M., Sander, D., Vuilleumier, P., 2018. Distinct Brain Areas involved in Anger versus Punishment during Social Interactions. *Sci. Rep.* 8, 10556. <https://doi.org/10.1038/s41598-018-28863-3>
- Kuniishi, H., Ichisaka, S., Matsuda, S., Futora, E., Harada, R., Hata, Y., 2016. Chronic Inactivation of the Orbitofrontal Cortex Increases Anxiety-Like Behavior and Impulsive Aggression, but Decreases Depression-Like Behavior in Rats. *Front. Behav. Neurosci.* 10, 250. <https://doi.org/10.3389/fnbeh.2016.00250>
- Leckman, J.F., Riddle, M.A., Hardin, M.T., Ort, S.I., Swartz, K.L., Stevenson, J., Cohen, D.J., 1989. The Yale Global Tic Severity Scale: Initial Testing of a Clinician-Rated Scale of Tic Severity. *J. Am. Acad. Child Adolesc. Psychiatry* 28, 566–573. <https://doi.org/10.1097/00004583-198907000-00015>
- Leroy, F., Park, J., Asok, A., Brann, D.H., Meira, T., Boyle, L.M., Buss, E.W., Kandel, E.R., Siegelbaum, S.A., 2018. A circuit from hippocampal CA2 to lateral septum disinhibits social aggression. *Nature* 564, 213–218. <https://doi.org/10.1038/s41586-018-0772-0>
- Martino, D., Ganos, C., Worbe, Y., 2018. Neuroimaging Applications in Tourette's Syndrome, in: *International Review of Neurobiology*. Elsevier, pp. 65–108. <https://doi.org/10.1016/bs.irn.2018.09.008>
- McCloskey, M.S., Noblett, K.L., Deffenbacher, J.L., Gollan, J.K., Coccaro, E.F., 2008. Cognitive-behavioral therapy for intermittent explosive disorder: A pilot randomized clinical trial. *J. Consult. Clin. Psychol.* 76, 876–886. <https://doi.org/10.1037/0022-006X.76.5.876>
- Miquel, M., Nicola, S.M., Gil-Miravet, I., Guarque-Chabrera, J., Sanchez-Hernandez, A., 2019. A Working Hypothesis for the Role of the Cerebellum in Impulsivity and Compulsivity. *Front. Behav. Neurosci.* 13, 99. <https://doi.org/10.3389/fnbeh.2019.00099>
- Patton, J.H., Stanford, M.S., Barratt, E.S., 1995. Factor structure of the Barratt impulsiveness scale. *J. Clin. Psychol.* 51, 768–774.
- Pehrs, C., Zaki, J., Schlochtermeyer, L.H., Jacobs, A.M., Kuchinke, L., Koelsch, S., 2017. The Temporal Pole Top-Down Modulates the Ventral Visual Stream During Social Cognition. *Cereb. Cortex N. Y. N 1991* 27, 777–792. <https://doi.org/10.1093/cercor/bhv226>

- Polyanska, L., Critchley, H.D., Rae, C.L., 2017. Centrality of prefrontal and motor preparation cortices to Tourette Syndrome revealed by meta-analysis of task-based neuroimaging studies. *NeuroImage Clin.* 16, 257–267. <https://doi.org/10.1016/j.nicl.2017.08.004>
- Rae, C.L., Polyanska, L., Gould van Praag, C.D., Parkinson, J., Bouyagoub, S., Nagai, Y., Seth, A.K., Harrison, N.A., Garfinkel, S.N., Critchley, H.D., 2018. Face perception enhances insula and motor network reactivity in Tourette syndrome. *Brain* 141, 3249–3261. <https://doi.org/10.1093/brain/awy254>
- Rowe, J.B., Hughes, L., Nimmo-Smith, I., 2010. Action selection: A race model for selected and non-selected actions distinguishes the contribution of premotor and prefrontal areas. *NeuroImage* 51, 888–896. <https://doi.org/10.1016/j.neuroimage.2010.02.045>
- Rudebeck, P.H., Bannerman, D.M., Rushworth, M.F.S., 2008. The contribution of distinct subregions of the ventromedial frontal cortex to emotion, social behavior, and decision making. *Cogn. Affect. Behav. Neurosci.* 8, 485–497. <https://doi.org/10.3758/CABN.8.4.485>
- Sambrani, T., Jakubovski, E., Müller-Vahl, K.R., 2016. New Insights into Clinical Characteristics of Gilles de la Tourette Syndrome: Findings in 1032 Patients from a Single German Center. *Front. Neurosci.* 10, 415. <https://doi.org/10.3389/fnins.2016.00415>
- Scangos, K.W., Aronberg, R., Stuphorn, V., 2013. Performance monitoring by presupplementary and supplementary motor area during an arm movement countermanding task. *J. Neurophysiol.* 109, 1928–1939. <https://doi.org/10.1152/jn.00688.2012>
- Sheehan, D.V., Lecrubier, Y., Sheehan, K.H., Amorim, P., Janavs, J., Weiller, E., Hergueta, T., Baker, R., Dunbar, G.C., 1998. The Mini-International Neuropsychiatric Interview (M.I.N.I.): the development and validation of a structured diagnostic psychiatric interview for DSM-IV and ICD-10. *J. Clin. Psychiatry* 59 Suppl 20, 22-33;quiz 34-57.
- Tessier, A., Cosin, C., Mayo, W., Pfeuty, M., Misdrahi, D., Sibon, I., 2015. Impulsive aggressive obsessions following cerebellar strokes: a case study. *J. Neurol.* 262, 1775–1776. <https://doi.org/10.1007/s00415-015-7804-6>
- Walker, S.E., Wood, T.C., Cash, D., Mesquita, M., Williams, S.C.R., Sandi, C., 2018. Alterations in brain microstructure in rats that develop abnormal aggression following peripubertal stress. *Eur. J. Neurosci.* 48, 1818–1832. <https://doi.org/10.1111/ejn.14061>
- Widmayer, S., Sowislo, J.F., Jungfer, H.A., Borgwardt, S., Lang, U.E., Stieglitz, R.D., Huber, C.G., 2018. Structural Magnetic Resonance Imaging Correlates of Aggression in Psychosis: A Systematic Review and Effect Size Analysis. *Front. Psychiatry* 9, 217. <https://doi.org/10.3389/fpsy.2018.00217>
- Worbe, Y., Gerardin, E., Hartmann, A., Valabrégue, R., Chupin, M., Tremblay, L., Vidailhet, M., Colliot, O., Lehericy, S., 2010. Distinct structural changes underpin clinical phenotypes in patients with Gilles de la Tourette syndrome. *Brain* 133, 3649–3660. <https://doi.org/10.1093/brain/awq293>

Yang, X., Hu, L., Zeng, J., Tan, Y., Cheng, B., 2016. Default mode network and frontolimbic gray matter abnormalities in patients with borderline personality disorder: A voxel-based meta-analysis. *Sci. Rep.* 6, 34247. <https://doi.org/10.1038/srep34247>

Zhang, J., Li, B., Gao, J., Shi, H., Wang, X., Jiang, Y., Ming, Q., Gao, Y., Ma, R., Yao, S., 2015. Impaired Frontal-Basal Ganglia Connectivity in Male Adolescents with Conduct Disorder. *PloS One* 10, e0145011. <https://doi.org/10.1371/journal.pone.0145011>

## FIGURES CAPTIONS

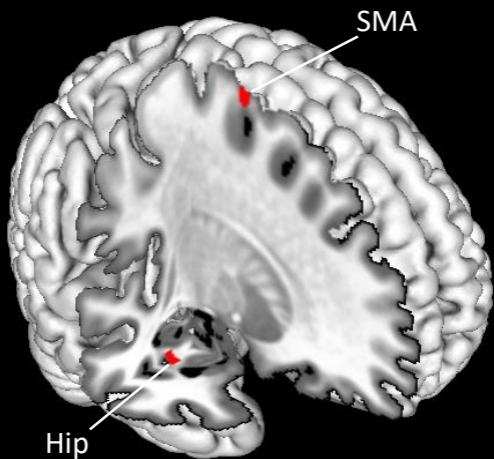
**Fig.1. Structural correlates of IEO in TD<sub>[no-ADHD]</sub>, representing (A) an increased FA and (B) a decreased MD in comparison to TD patients without IEO.**

Hip: Hippocampus; OFC: Orbitofrontal cortex; SMA: Supplementary motor area.

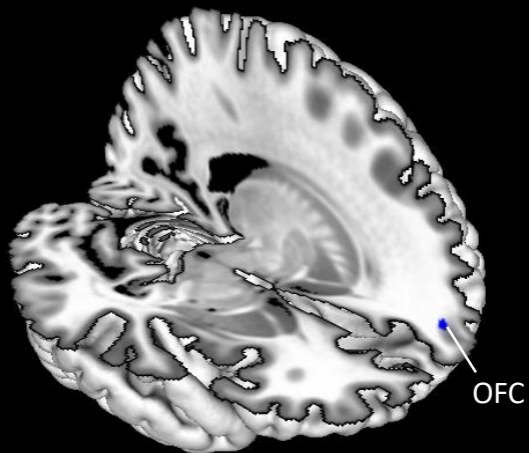
**Fig.2. Functional correlates of IEO in TD<sub>[no-ADHD]</sub>, using (A) the SMA, (B) the OFC and (C) the hippocampus as nodes in comparison to TD patients without IEO. Blue lines represent decreased connectivity and red lines represent increased connectivity in comparison to TD patients without IEO.**

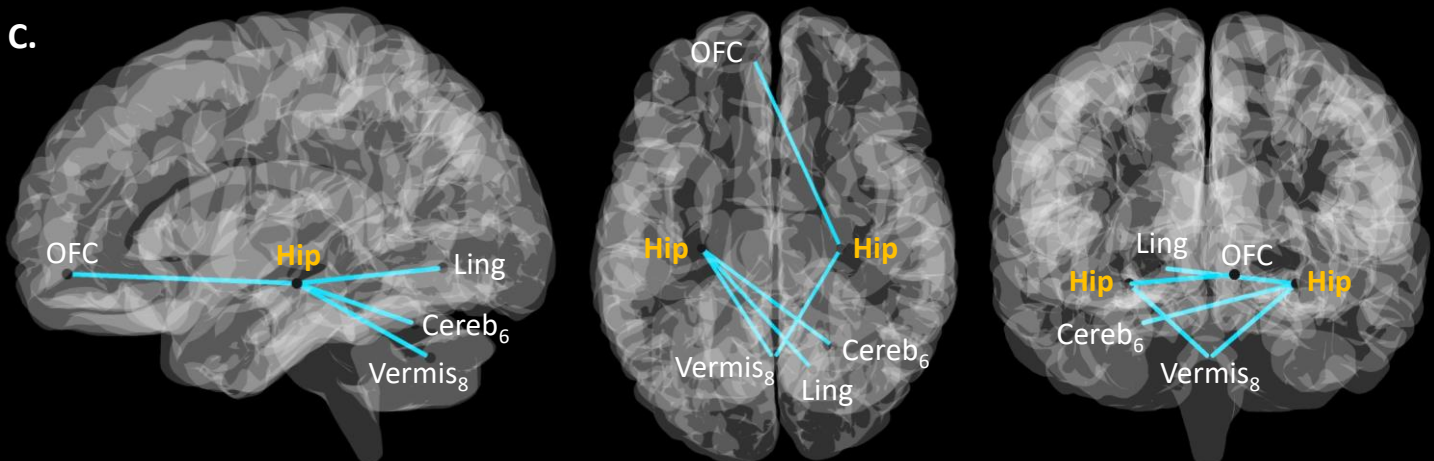
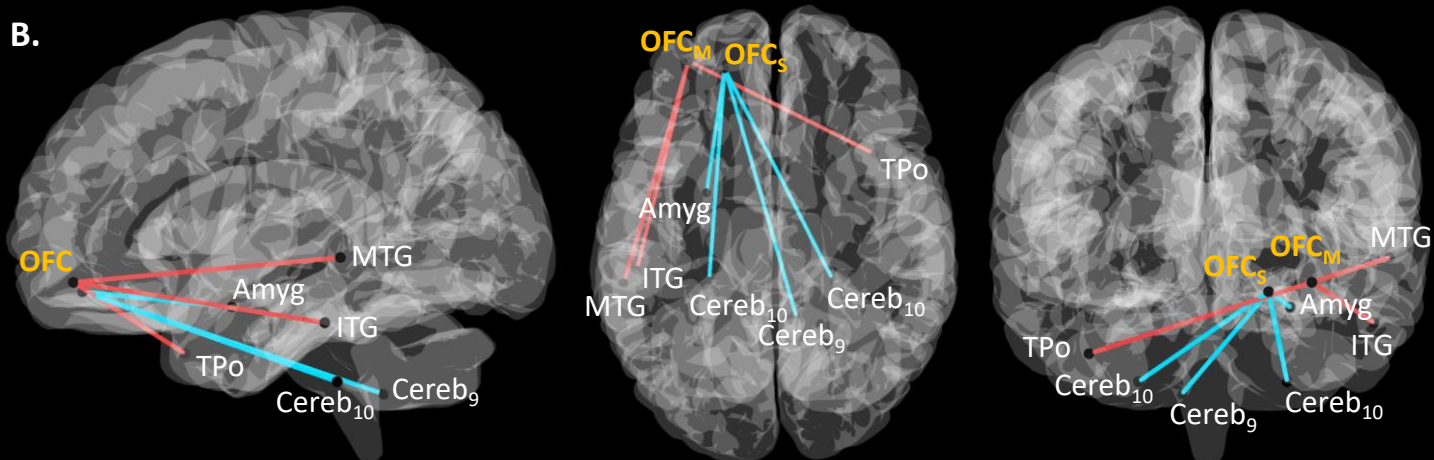
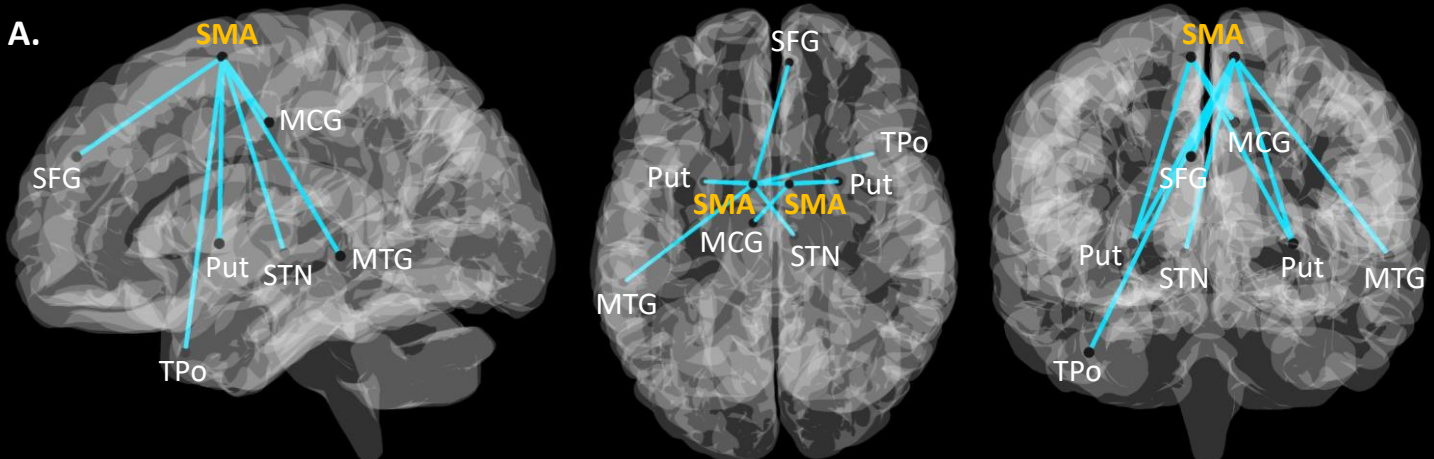
Amyg: Amygdala; Cereb: Cerebellum; Hip: Hippocampus; ITG: Inferior temporal gyrus; Lin: Lingual gyrus; MCG: Middle cingulate gyrus; MTG: Middle temporal gyrus; OFC: Orbitofrontal cortex (M: Middle; S: Superior); Put: Putamen; SFG: Superior frontal gyrus; SMA: Supplementary motor area; STN: Subthalamic nucleus; TPo: Temporal pole.

A.



B.





**Table.1. Demographics and clinical data for TD patients with and without intermittent explosive outbursts.**

	<b>TD (n = 29)</b>	<b>TD-IEO (n = 26)</b>	<b>p-value</b>	<b>bf</b>
<b>Gender (F / M)</b>	4 / 25	7 / 19	0.38	0.49 ± 0.01%
<b>Age (y)</b>	31.45 ± 11.17	31.03 ± 11.55	0.86	0.33 ± 0.01%
<b>Education duration (y)</b>	14.06 ± 2.66	13.94 ± 2.66	0.83	0.34 ± 0.01%
<b>YGTSS (/50)</b>	15.67 ± 6.36	17.03 ± 8.17	0.46	0.27 ± 0.01%
<b>MIDI*</b>	0.83 ± 1.07	1.27 ± 1.04	0.13	0.73 ± 0.02%
<b>BIS-11</b>	60.98 ± 10.34	67.21 ± 11.33	<b>0.01</b>	0.43 ± 0.01%
<b>STAI</b>	69.73 ± 18.73	84.51 ± 16.32	<b>&lt;0.001</b>	2.19 ± 0.00%
<b>Medication (%)</b>	38%	31%	0.78	0.31 ± 0.01%
<b>ADHD (%)</b>	27%	65%	<b>0.01</b>	<b>9.31 ± 0.00%</b>
<b>OCD (%)</b>	17%	27%	0.59	0.37 ± 0.01%

\*: one point was removed for TD-IEO patients due to the score of IEO itself; ADHD:

Attentional deficit hyperactivity disorder; bf: Bayesian factor; BIS-11: Barratt Impulsivity scale; MIDI: Minnesota Impulse Disorders Interview; OCD: Obsessive-compulsive disorder; STAI: State-Trait Anxiety Inventory; TD: Patients without intermittent explosive outbursts; TD-IEO: Patients with intermittent explosive outbursts; YGTSS: Yale Global Tics Severity Scale.

**Table.2. Demographics and clinical data for TD<sub>[no-ADHD]</sub> patients with and without intermittent explosive outbursts, excluding patients with comorbid ADHD.**

	<b>TD<sub>[no-ADHD]</sub> (n = 21)</b>	<b>TD-IEO<sub>[no-ADHD]</sub> (n = 9)</b>	<b>p-value</b>	<b>bf</b>
<b>Gender (F / M)</b>	3 / 18	4 / 5	0.19	1.21 ± 0.00%
<b>Age (y)</b>	32.81 ± 12.55	30 ± 7.21	0.45	0.43 ± 0.00%
<b>Education duration (y)</b>	14.05 ± 2.67	15.22 ± 3.31	0.36	0.54 ± 0.00%
<b>YGTSS (/50)</b>	16.09 ± 6.13	14.78 ± 8.73	0.69	0.39 ± 0.00%
<b>MIDI*</b>	0.62 ± 1.02	1 ± 0.87	0.31	0.52 ± 0.00%
<b>BIS-11</b>	61.28 ± 9.88	59.11 ± 7.77	0.53	0.41 ± 0.00%
<b>STAI</b>	71.76 ± 14.33	80 ± 14.47	0.17	0.77 ± 0.00%
<b>Medication (%)</b>	38%	55%	0.78	0.48 ± 0.00%
<b>OCD (%)</b>	14%	33%	0.48	0.31 ± 0.00%

\*: one point was removed for TD-IEO<sub>[no-ADHD]</sub> patients due to the score of IEO itself; ADHD: Attentional deficit hyperactivity disorder; bf: Bayesian factor; BIS-11: Barratt Impulsivity scale; MIDI: Minnesota Impulse Disorders Interview; OCD: Obsessive-compulsive disorder; STAI: State-Trait Anxiety Inventory; TD<sub>[no-ADHD]</sub>: Patients without intermittent explosive outbursts; TD-IEO<sub>[no-ADHD]</sub>: Patients with intermittent explosive outbursts; YGTSS: Yale Global Tics Severity Scale.