



HAL
open science

Towards metabolic disconnection – symptom mapping

Michel Thiebaut de Schotten, Stephanie Forkel

► **To cite this version:**

Michel Thiebaut de Schotten, Stephanie Forkel. Towards metabolic disconnection – symptom mapping. *Brain - A Journal of Neurology*, 2020, 143 (3), pp.718-721. <10.1093/brain/awaa060>. <hal-02991269>

HAL Id: hal-02991269

<https://hal.science/hal-02991269v1>

Submitted on 18 Oct 2024

HAL is a multi-disciplinary open access archive for the deposit and dissemination of scientific research documents, whether they are published or not. The documents may come from teaching and research institutions in France or abroad, or from public or private research centers.

L'archive ouverte pluridisciplinaire **HAL**, est destinée au dépôt et à la diffusion de documents scientifiques de niveau recherche, publiés ou non, émanant des établissements d'enseignement et de recherche français ou étrangers, des laboratoires publics ou privés.



HAL Authorization

Published in final edited form as:

Brain. 2020 March 01; 143(3): 718–721. doi:10.1093/brain/awaa060.

Towards metabolic disconnection – symptom mapping

Stephanie J. Forkel^{a,b,c}, Michel Thiebaut de Schotten^{a,b}

^aBrain Connectivity and Behaviour Laboratory, Sorbonne Universities, Paris, France

^bGroupe d'Imagerie Neurofonctionnelle, Institut des Maladies Neurodégénératives-UMR 5293, CNRS, CEA University of Bordeaux, Bordeaux, France

^cCentre for Neuroimaging Sciences, Department of Neuroimaging, Institute of Psychiatry, Psychology and Neuroscience, King's College London, London, UK

Structural and functional neuroimaging methods have contributed to our understanding of the anatomy of higher cognitive functions. Magnetic resonance imaging (MRI) has often been the method of choice because it allows for the simultaneous and non-invasive study of brain structure and function in health and disease. In the presence of brain pathologies, structural MRI is traditionally used for lesion delineation and provides an estimate of the lesion location, its size, and how far it extends into cortical and subcortical regions (Bates *et al.*, 2003). Several studies have demonstrated, however, that the timing of neuroimaging relative to symptom onset, as well as the particular modalities used, can influence the results obtained (Shahid *et al.*, 2017; Forkel & Catani, 2018). For instance, the extent, contrast and shape of lesions can change over time and differ between imaging modalities. These anatomical observations can be complemented by functional MRI sequences that shed light on the deterioration of brain functional networks and their reorganisation (Corbetta *et al.*, 2005)

Despite the success of neuroimaging, clinicians are accustomed to seeing patients with cognitive deficits indicative of brain lesions, and yet no visible evidence of such lesions on the MRI scan. There are a number of possible explanations for this incongruent presentation. In some patients, cognitive impairments may be caused by other underlying conditions (e.g. effects of toxins, infections); in others our conventional imaging tools may be insufficient to detect damaged tissues. It is also possible for the brain to appear structurally intact, and yet for its function to be compromised because individual regions are no longer working together effectively. Hence, the absence of a structural lesion on conventional MRI does not preclude the presence of a functional disconnection. Reliable neuroimaging methods are therefore crucial to aid diagnostics, inform treatment pathways and improve quality of life for patients. But despite our best efforts to improve methods for studying structural and functional disconnections in patients, we still lack advanced imaging tools to identify 'hidden damage' (Thiebautde Schotten and Foulon, 2018).

Correspondence to stephanie.forkel@gmail.com.

Competing interests statement: The authors report no competing interests.

The absence of visible brain lesions can have far-reaching implications. For example, patients with traumatic brain injury often present with cognitive impairment but lose medico-legal cases because of a lack of evidence of lesions. Recent studies have shown, however, that differences in perfusion imaging and tractography measures can be evident in traumatic brain injury patients despite a clinically ‘negative’ structural MRI (Metting *et al.*, 2013). Another example is non-lesional focal epilepsy, which may be confirmed by electroencephalography (EEG), but where cognitive impairments are not contingent on the presence of a visible lesion (Reyner *et al.*, 2019). In the absence of demonstrable lesions, neurosurgeons are primarily guided by the clinical symptoms exhibited by a patient and the EEG results. Thus, it is clear that new neuroimaging strategies are required to improve diagnosis, treatment and, subsequently, patients’ quality of life.

In this issue of *Brain*, Jha and co-workers introduce a novel approach to lesion-deficit mapping based on metabolic imaging (Jha *et al.*, 2020). The authors provide proof-of-principle for their approach using retrospective positron emission tomography (PET) neuroimaging data from 159 patients undergoing investigation for epilepsy but with negative structural MRI results. The advantage of metabolic-disconnection mapping over classical lesion-symptom mapping is that cerebral glucose metabolism can be extracted as graded deviations, whereas lesion maps are extracted as binary masks. The metabolic gradient includes hypofunction and hyperfunction, which may reflect deterioration and reorganisation of brain function and may thus improve clinical-anatomical correlations.

Jha *et al.* (2020) assessed cognition with a clinical neuropsychological battery that included 16 commonly used measures probing memory, verbal fluency, affect, and intelligence. The cerebral glucose metabolism scans were performed using (18)F-FDG PET/CT imaging. Evaluating these scans revealed metabolic lesions in patients with no visible lesions on standard MRI (Figure 1A). Metabolic lesions were also more uniformly distributed across the brain as compared to lesions resulting from stroke. In stroke, lesions tend to adhere to the vasculature of the brain, resulting in clusters of lesioned voxels on MRI (Mah *et al.*, 2014). The results of Jha *et al.* thus suggest that (18)F-FDG PET/CT imaging may be helpful for comprehensively mapping symptoms to the brain.

Jha *et al.* generated their metabolic-symptom maps by means of voxel-wise mass-univariate inference between the metabolic lesions and the neuropsychological assessments. Most functions were associated with both positive and negative metabolic activity across the brain (see example in Figure 1B). Unlike classical lesion-symptom mapping which points to the most critical area (Figure 1C), metabolic approaches may reveal the underlying network affected by a lesion. These networks resemble results from functional imaging in healthy controls for the same cognitive domains (Figure 1D).

In a final step, the authors tested their dataset for predictive fidelity by using verbal IQ and HADS depression measures in a Bayesian regression analysis, which yielded high predictive values for individual patient scores. These results indicate that Jha *et al.* have laid the foundations for some exciting future research applications. Given the broad clinical impact of a method that can reveal ‘hidden lesions’, the approach should be extended. Rather than relying on a radioactive tracer, it could be extended to a non-invasive sequence (e.g.

diffusion-perfusion MRI, Hillis *et al.*, 2005). Combining metabolic lesion mapping with multimodal imaging, such as tractography and EEG, will greatly enhance our understanding of the relation between structural and functional lesions. For instance, extending this line of investigation from its current focus on grey matter to also include white matter tractography could allow one to partially decipher the structural mechanisms behind the metabolic changes identified. Having a continuous measure of a lesion is a great advantage as it increases statistical power and could allow for grading of the lesion (e.g. core, penumbra, oedema). This study thus represents a significant step forward in the quest to map and understand brain function and pathology, while also having the potential to greatly improve clinical diagnosis and treatment.

Acknowledgements

We thank Henrietta Howells for discussion, Jha *et al.* for the examples presented in Figure 1A of MRI-negative and PET-positive scans of the same patient, and the generous support of the European Research Council (ERC) under the European Union's Horizon 2020 research and innovation programme (grant no. 818521).

References

- Bates E, Wilson S, Saygin AP, Dick F, Sereno M, Knight RT, Dronkers NF. Voxel-based lesion-symptom mapping. *Nature Neuroscience*. 2003; 6(5):448–450. [PubMed: 12704393]
- Corbetta M, Kincade MJ, Lewis C, Snyder AZ, Sapir A. Neural Basis and Recovery of Spatial Attention Deficits in Spatial Neglect. *Nat Neurosci*. 2005; 8(11):1603–10. [PubMed: 16234807]
- Forkel SJ, Catani M. Lesion mapping in acute stroke aphasia and its implications for recovery. *Neuropsychologia*. 2018; 115:88–100. [PubMed: 29605593]
- Hillis AE, Newhart M, Heidler J, Barker PB, Herskovits EH, Degaonkar M. Anatomy of Spatial Attention: Insights from Perfusion Imaging and Hemispatial Neglect in Acute Stroke. *Journal of Neuroscience*. 2005; 25(12):3161–3167. DOI: 10.1523/JNEUROSCI.4468-04.200 [PubMed: 15788773]
- Jha, et al. Metabolic lesion–deficit mapping of human cognition. *Brain*. 2020
- Mah YH, Husain M, Rees G, Nachev P. Human Brain Lesion-Deficit Inference Remapped. *Brain*. 2014; 137(Pt 9):2522–31. [PubMed: 24974384]
- Metting Z, Cerliani L, Rödiger LA, van der Naalt J. Pathophysiological concepts in mild traumatic brain injury: diffusion tensor imaging related to acute perfusion CT imaging. *PLoS One*. 2013; 8(5):e64461. [PubMed: 23704986]
- Rayner G, Tailby C, Jackson G, Wilson S. Looking Beyond Lesions for Causes of Neuropsychological Impairment in Epilepsy. *Neurology*. 2019; 92(7):e680–e689. [PubMed: 30635484]
- Shahid H, Sebastian R, Schnur T, Hanayik T, Wright A, Tippett D, Fridriksson J, Rorden C, Hillis AE. Important Considerations in Lesion-Symptom Mapping: Illustrations From Studies of Word Comprehension. *Hum Brain Mapp*. 2017; 38(6):2990–3000. [PubMed: 28317276]
- Thiebaut de Schotten M, Foulon C. 2018 The rise of a new associationist school for lesion-symptom mapping. *Brain*. 2018; 141(1):2–4. DOI: 10.1093/brain/awx332 [PubMed: 29325046]
- Yarkoni T, Poldrack R, Nichols TE, Van Essen D, Wager T. Large-scale automated synthesis of human functional neuroimaging data. *Nat Methods*. 2011; 8(8):665–670. [PubMed: 21706013]

Glossary

Metabolic disconnection:

Brain regions are structurally connected to each other to work together by means of co-activation, inhibition or disinhibition. If these processes are functionally impaired without a lesion being evident on conventional structural imaging, this is considered metabolic disconnection.

(18)FDG PET/CT:

A positron emission tomography (PET) scan uses a small amount of a radioactive drug, or tracer, to show differences between healthy and pathological tissue. The most commonly used tracer is FDG (fluorodeoxyglucose). In the study by Jha *et al.*, 30 minutes after the injection of 250 MBq (18)F-FDG, a computerized tomography (CT) scan was acquired for attenuation correction, and this was followed by 15 minutes of PET acquisition.

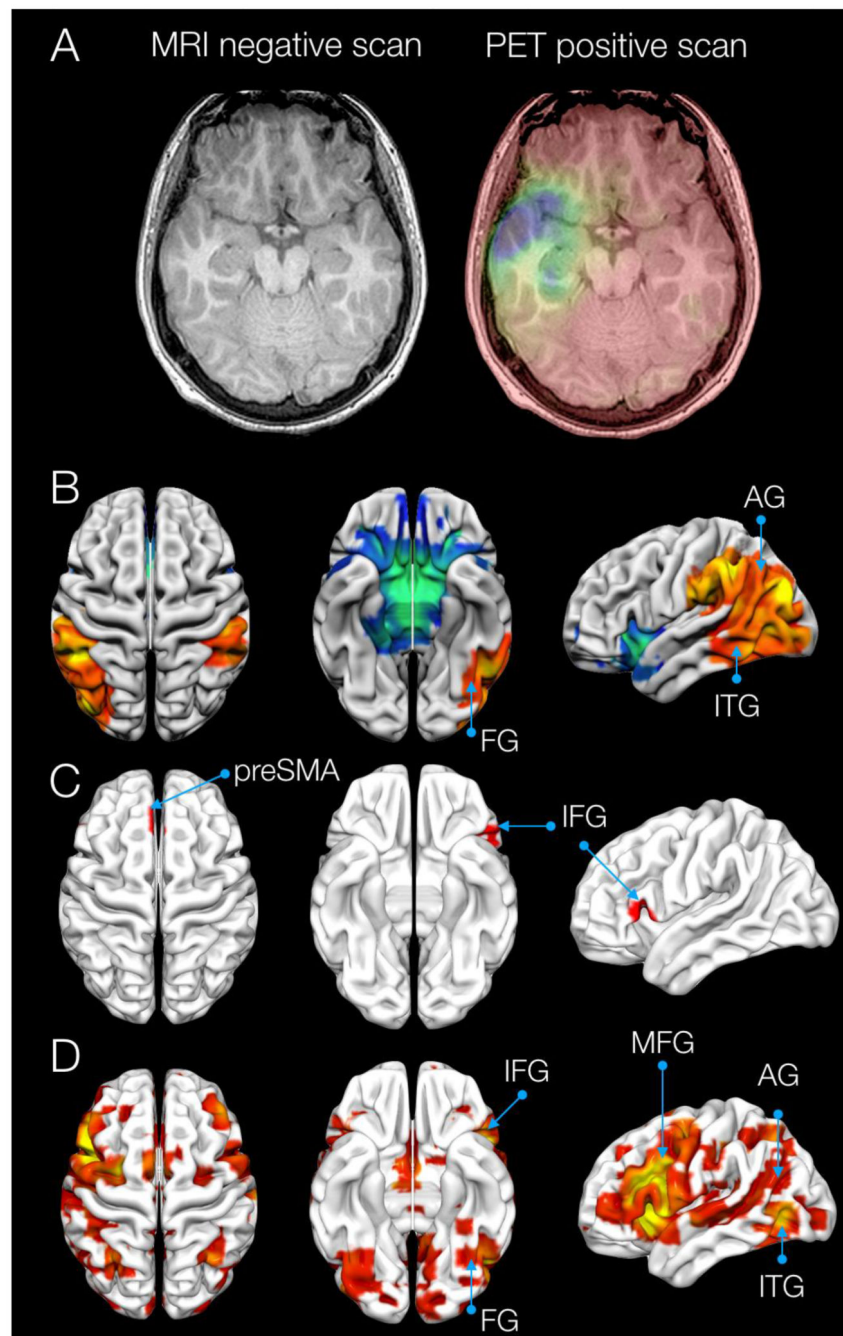


Figure. The ‘hidden lesion’.

A) MRI-negative and PET-positive scans of the same patient (images courtesy of Jha *et al.*). B) Metabolic lesion-symptom map for phonemic verbal fluency as identified by Jha *et al.* C) Example of a structural lesion-symptom map for phonemic verbal fluency as obtained from Kinkingnehun *et al.*, 2007. D) Functional activation maps from healthy controls performing a verbal fluency task in an MRI scanner. Maps derived from Neurosynth (<http://www.neurosynth.org/>, Yarkoni *et al.*, 2011).

AG, angular gyrus; FG, fusiform gyrus; IFG, inferior frontal gyrus; ITG, inferior temporal gyrus; MFG, middle frontal gyrus, preSMA, presupplementary motor area.