



**HAL**  
open science

## **DIVA, a 3D virtual reality platform, improves undergraduate craniofacial trauma education**

Jebrane Bouaoud, Mohamed El Beheiry, Eve Jablon, Thomas Schouman, Chloé Bertolus, Arnaud Picard, Jean-Baptiste Masson, Roman Khonsari

### ► To cite this version:

Jebrane Bouaoud, Mohamed El Beheiry, Eve Jablon, Thomas Schouman, Chloé Bertolus, et al.. DIVA, a 3D virtual reality platform, improves undergraduate craniofacial trauma education. *Journal of Stomatology, Oral and Maxillofacial Surgery*, 2020, 10.1016/j.jormas.2020.09.009 . hal-02974248

**HAL Id: hal-02974248**

**<https://hal.science/hal-02974248>**

Submitted on 9 Dec 2020

**HAL** is a multi-disciplinary open access archive for the deposit and dissemination of scientific research documents, whether they are published or not. The documents may come from teaching and research institutions in France or abroad, or from public or private research centers.

L'archive ouverte pluridisciplinaire **HAL**, est destinée au dépôt et à la diffusion de documents scientifiques de niveau recherche, publiés ou non, émanant des établissements d'enseignement et de recherche français ou étrangers, des laboratoires publics ou privés.

1 DIVA, a 3D virtual reality platform, improves undergraduate craniofacial trauma education

2 **Short title** VR in craniofacial trauma education

3

4 Jebrane **Bouaoud**, MD<sup>1,2,\*</sup>; Mohamed **El Beheiry**, PhD<sup>3\*</sup>; Eve **Jablon**<sup>4</sup>; Thomas **Schouman**  
5 MD PhD<sup>2</sup>; Chloé **Bertolus** MD PhD<sup>2</sup>; Arnaud **Picard** MD PhD<sup>1</sup>; Jean-Baptiste **Masson**,  
6 PhD<sup>3,†</sup>; Roman H. **Khonsari**, MD PhD<sup>1,†</sup>

7 1. Assistance Publique - Hôpitaux de Paris, Service de Chirurgie maxillo-faciale et  
8 Chirurgie plastique, Hôpital Universitaire Necker - Enfants Malades; Université Paris  
9 Descartes, Université de Paris; Paris, France.

10 2. Assistance Publique - Hôpitaux de Paris, Service de Chirurgie maxillo-faciale et  
11 Stomatologie, Hôpital Universitaire Pitié-Salpêtrière, Université Pierre et Marie Curie,  
12 Sorbonne Université; Paris, France

13 3. Decision and Bayesian Computation, Neuroscience Department UMR 3571 & USR  
14 3756 (C3BI/DBC), Institut Pasteur & CNRS, Paris, France

15 4. Université Paris Descartes, Université de Paris; Paris, France.

16  
17 \* contributed equally as first authors

18 † contributed equally as last authors

19  
20 **Corresponding author:**

21 Jebrane Bouaoud, MD

22 Service de Chirurgie maxillo-faciale et Chirurgie plastique, Hôpital Universitaire Necker -  
23 Enfants Malades, 149 rue de Sèvres, 75015 Paris, France

24 jebrane.bouaoud@gmail.com

25 Phone# +33142161049

26

1  
2 **27 Financial Disclosure Statement:**  
3

4  
5 28 We acknowledge funding from Institut Pasteur, Institut Curie, Paris Sciences Lettres and the  
6  
7 29 sponsorship of CRPCEN, Gilead-Sciences, and fondation EDF, the “programme  
8  
9 30 d’investissement d’avenir” supported by the “agence nationale de la recherche” ANR-19-  
10  
11 31 P3IA-0001 (PRAIRIE 3IA Institute), INCEPTION project (PIA/ANR- 16-CONV-0005,  
12  
13  
14 32 OG)), and TRamWAY ANR-17-CE23-0016.  
15

16  
17 33

18  
19 **34 Conflict of interest**  
20

21 35 Mohamed El Beheiry and Jean-Baptiste Masson are cofounders, shareholders and scientific  
22  
23  
24 36 advisors of Avatar Medical.

25  
26 37 Jean-Baptiste Masson is one of the scientific advisors of the Robeauté startup.  
27  
28  
29  
30  
31  
32  
33  
34  
35  
36  
37  
38  
39  
40  
41  
42  
43  
44  
45  
46  
47  
48  
49  
50  
51  
52  
53  
54  
55  
56  
57  
58  
59  
60  
61  
62  
63  
64  
65

38 **Author's role and participation on the manuscript**

39 All authors have participated to the conception and design, acquisition of data, or analysis and  
40 interpretation of data;

41 All authors have participated to the drafting the article or revising it critically for important  
42 intellectual content;

43 All authors have approved the final version to be published;

44 All authors have participated to the agreement to be accountable for all aspects of the work in  
45 ensuring that questions related to the accuracy or integrity of any part of the work are  
46 appropriately investigated and resolved

47

48 **Approval and confirming statements**

49 This study was approved by Institutional review board and performed in accordance with the  
50 Helsinki declaration. Collection of data and analysis were in accordance with guidelines of  
51 the French National Committee for the Protection of Personal Data (Commission Nationale  
52 Informatique et Libertés, CNIL, declaration number 2218907v0).

53 **Abstract**

54 Craniofacial fractures management is challenging to teach due to the complex anatomy of the  
55 head, even when using three-dimensional CT-scan images. DIVA is a software allowing the  
56 straightforward visualization of CT-scans in a user-friendly three-dimensional virtual reality  
57 environment. Here, we assess DIVA as an educational tool for craniofacial trauma for  
58 undergraduate medical students.

59 Three craniofacial trauma cases (jaw fracture, naso-orbital-ethmoid complex fracture and Le  
60 Fort 3 fracture) were submitted to 50 undergraduate medical students, who had to provide  
61 diagnoses and treatment plans. Each student then filled an 8-item questionnaire assessing  
62 satisfaction, potential benefit, ease of use and tolerance. Additionally, 4 postgraduate students  
63 were requested to explore these cases and to place 6 anatomical landmarks on both virtual  
64 reality renderings and usual slice-based three-dimensional CT-scan visualizations.

65 High degrees of satisfaction (98%) without specific tolerance issues (86%) were reported. The  
66 potential benefit in a better understanding of craniofacial trauma using virtual reality was  
67 reported by almost all students (98%). Virtual reality allowed a reliable localization of key  
68 anatomical landmarks when compared with standard three-dimensional CT-scan  
69 visualization.

70 Virtual reality interfaces such DIVA are beneficial to medical students for a better  
71 understanding of craniofacial trauma and allow a reliable rendering of craniofacial anatomy.

72 **Keywords:**

73 virtual reality; data visualization; image processing; craniofacial; traumatology; education

74 **Introduction**

75 Craniofacial trauma is difficult to teach due to the complex anatomy of the skull [1]. Three-  
76 dimensional (3D) CT-scans help in visualizing fracture lines based on exploration of the 3D  
77 objects on 2D screens. Virtual reality (VR) is a technology that uses real-world visual  
78 perception within entirely artificial computer-generated environments. VR allows users to  
79 efficiently explore 3D environments in an entirely immersive manner, providing a natural and  
80 spatially realistic experience [2].

81 The benefits of VR in craniofacial surgery have been assessed in previous studies [3]. Almost  
82 all studies reported the use of VR for pre-operative planning [4] and intra-operative assistance  
83 [5], notably in implantology, orthognathic surgery and maxillofacial reconstruction [3]. Few  
84 studies have reported the benefits of VR in surgical education. Within the educational  
85 literature, radiology [6] and implantology [7] applications have been evaluated but no study  
86 has been dedicated to craniofacial trauma to date.

87 DIVA (Data Integration and Visualization in Augmented and Virtual Environments, Pasteur  
88 Institute, Paris) is a software allowing a fast and user-friendly visualization of raw CT-scan  
89 data with immediate immersion [8,9]. DIVA allows users to intuitively navigate in a flexible  
90 3D environment with virtual handheld tools that can be used to interact with 3D images in  
91 real-time including landmarking, clipping and highlighting tools.

92 Here we assess DIVA as an educational tool for teaching craniofacial trauma using a  
93 dedicated questionnaire. We furthermore assess the anatomical precision of this tool using  
94 anatomical landmark placement.

95 **Materials and Methods**

96

97 **1. VR in craniofacial trauma education: benefits and tolerance**

98 Three craniofacial trauma cases (jaw fracture, naso-orbital-ethmoid complex fracture and Le  
99 Fort 3 fracture) were submitted to 50 fourth-year undergraduate medical students from the  
100 University of Paris, who had to provide a diagnosis and a treatment plan. For each student,  
101 pre- and post-operative CT-scans were assessed using both a freeware DICOM viewer  
102 (RadiAnt, Medixant, Poznan, Poland) and DIVA (Figure 1).

103 The DIVA interface offers two visualization tools: (1) a desktop tool for standard 3D  
104 visualization and (2) the VR environment. The desktop tool was used to reconstruct the skull  
105 in 3D based on pre-defined transfer functions. This same visualization is seamlessly switched  
106 to the VR viewing context where it can be physically interacted with (Figure 2 and  
107 Supplemental Digital Contents 1-3).

108 After using the DICOM viewer and DIVA, each undergraduate medical student filled a  
109 questionnaire based on 8 items assessing satisfaction, potential benefit, comfort of use and  
110 tolerance.

112 **2. Anatomical precision of VR**

113 4 postgraduate students were requested to explore these cases and to place 6 anatomical  
114 landmarks on two types of 3D renderings: (1) 3D reconstructions from CT-scan using Avizo  
115 (ThermoFisher Scientific, Waltham, MA, USA) and (2) 3D renderings of the same DICOM  
116 data using the DIVA VR interface.

117 The landmarks selected were: (1) anterior nasal spine, (2) posterior nasal spine, (3) distal  
118 palatal cusp of tooth 17 (right second maxillary molar), (4) distal palatal cusp of tooth 27 (left  
119 second maxillary second molar), (5) apex of the crista galli process and (6) apex of the

120 odontoid process of C2. Landmarks on both rendering were positioned 3 successive times (3  
1 trials) by the 4 subjects and 3D coordinates were extracted. Geometric morphometrics was  
2 121 performed using *MorphoJ* (Apache License, Version 2.0) [10]. After screening for outliers  
3 122 and Procrustes superimposition, canonical variate analysis on Procrustes coordinates using  
4 123 both trials and subjects as classifier variables allowed to compute Procrustes distances  
5 124 between groups (trials and subjects) [11]. Permutation test for pairwise distances with 10000  
6 125 iterations allowed obtaining p-values accounting for the significance of Procrustes distances  
7 126 between trials 1-3 and subjects 1-4.  
8  
9 128 We furthermore evaluated the variability in landmark positioning by assessing inter- and  
10 129 intra-individual error rates, defined as the variance of the position divided by N-1, with N  
11 130 being the number of points.  
12  
13  
14  
15  
16  
17  
18  
19  
20  
21  
22  
23  
24  
25  
26  
27  
28  
29  
30  
31  
32  
33  
34  
35  
36  
37  
38  
39  
40  
41  
42  
43  
44  
45  
46  
47  
48  
49  
50  
51  
52  
53  
54  
55  
56  
57  
58  
59  
60  
61  
62  
63  
64  
65



131 **Results**

132

133 **1. VR in craniofacial trauma education: benefits and tolerance**

134 Almost all undergraduate medical students (92%) reported a high degree of satisfaction  
135 (question 1, responses defined as “very satisfied” and “more than satisfied”) when using  
136 DIVA to explore and analyze craniofacial trauma cases (Table 1). The use of DIVA was  
137 deemed easy, intuitive (88%) and well tolerated (86%) (questions 2 and 3, Table 1).  
138 Furthermore, DIVA allowed students to visualize some lesions not seen on the usual 2D and  
139 3D renderings (82%), such as skull base and pterygoid process fractures (questions 4 and 5,  
140 Table 1). Almost all students strongly recommended the use of DIVA for educational  
141 purposes in traumatology (questions 6-8, Table 1).

142

143 **2. Anatomical precision of VR**

144 Geometric morphometrics analyses showed that all p-values accounting for the significance  
145 of Procrustes distances between trials 1-3 and subjects 1-4 were  $> 0.05$ : landmarking using  
146 standard 3D CT-scan visualization and landmarking using DIVA provided a similar 3D  
147 display of landmarks, without significant distortion. All mean 3D errors, exploring the  
148 variability in landmark positioning, were lower than 1 millimeter, ranging from 0.37 to 0.84  
149 millimeters (Figure 3 and Supplemental Digital Contents 4).

150 **Discussion**

1  
2 151  
3  
4 152 Craniofacial anatomy is challenging to teach to undergraduate medical students and common  
5  
6  
7 153 misunderstandings lead to pitfalls in diagnosis and treating head and neck trauma. While the  
8  
9  
10 154 teaching of traditional anatomy usually involves books and cadaveric dissection, which  
11  
12 155 requires significant amounts of time and effort, other teaching methods can be beneficial [12–  
13  
14 156 14].

15  
16  
17 157 VR has been recently re-introduced in medical schools as an easy-to-access technology due to  
18  
19 158 the availability of low-cost VR headsets. Through the integration of stereoscopy, motion  
20  
21  
22 159 tracking technologies and total 3D immersion, VR aims at providing a more natural means to  
23  
24 160 visualize 3D structures. VR headsets are bundled with 3D controllers (that act as 3D computer  
25  
26 161 mice) allowing manipulation and interaction with data within the virtual environment.  
27  
28  
29 162 Interactions with the VR controller are rather intuitive as they are performed as if the data  
30  
31 163 were physically present in front of the user.

32  
33  
34 164 DIVA is a software that automatically generates detailed 3D reconstructions of tomographic  
35  
36 165 medical images such as CT-scans. The avatar generated by DIVA based on raw DICOM CT-  
37  
38  
39 166 scan images is generated through volumetric reconstruction without pretreatment (e.g.  
40  
41 167 segmentation). DIVA is optimized to ensure high refresh rate (at least 60 Hz) and a high  
42  
43  
44 168 quality of volume rendering and thus provides a fluid experience. Users are free from latency  
45  
46 169 issues that induce negative experience within VR environments [9].

47  
48 170  
49  
50  
51 171 Here we showed that using DIVA to explore and analyze 3D CT-scans[8] improved the  
52  
53 172 understanding craniofacial trauma. Furthermore, we found a high degree of interobserver  
54  
55  
56 173 reproducibility reflecting the precision and accuracy of this tool to explore head and neck 3D  
57  
58 174 anatomy and landmarking.

175 As outlined by Alsabbagh et al., craniofacial fractures may be better interpreted using VR  
176 compare to usual CT-scan renderings[15]. We furthermore found that 82% of students  
177 reported spotting lesions using VR that they had missed on usual 3D renderings, thus  
178 confirming that VR is beneficial for exploring complex 3D objects [16].

179  
180 The value of VR in understanding fractures has recently been reported in orthopedics [17] and  
181 in pre-surgical planification of maxillofacial cases [18], as well as in dental education [19].  
182 Roessel et al. have recently reported a systematic literature review supporting the using of VR  
183 in surgical education and training [20].

184  
185 In brief, VR solutions such as DIVA can complement conventional teaching methods (2D  
186 sketches, 3D renderings, cadaveric dissections) when complex 3D structures such as the skull  
187 are involved [21–24]. High satisfaction and tolerance degrees could be obtained using VR  
188 tools such as DIVA. Beyond traumatology, similar tools may be used to explore craniofacial  
189 malformations and head and neck cancers, by combining CT-scan and MRI data.

190

191 **References**

- 1  
2 192 [1] Review: Anatomy of Head & Neck | SEER Training n.d.  
3 193 <https://training.seer.cancer.gov/head-neck/anatomy/review.html> (accessed February 16,  
4 194 2020).  
5  
6 195 [2] El Beheiry M, Doutreligne S, Caporal C, Ostertag C, Dahan M, Masson J-B. Virtual  
7 196 Reality: Beyond Visualization. *J Mol Biol* 2019;431:1315–21.  
8 197 <https://doi.org/10.1016/j.jmb.2019.01.033>.  
9  
10 198 [3] Ayoub A, Pulijala Y. The application of virtual reality and augmented reality in Oral &  
11 199 Maxillofacial Surgery. *BMC Oral Health* 2019;19:238. [https://doi.org/10.1186/s12903-](https://doi.org/10.1186/s12903-019-0937-8)  
12 200 [019-0937-8](https://doi.org/10.1186/s12903-019-0937-8).  
13 201 [4] von Sternberg N, Bartsch MS, Petersik A, Wiltfang J, Sibbersen W, Grindel T, et al.  
14 202 Learning by doing virtually. *Int J Oral Maxillofac Surg* 2007;36:386–90.  
15 203 <https://doi.org/10.1016/j.ijom.2006.12.016>.  
16 204 [5] Bosc R, Fitoussi A, Hersant B, Dao T-H, Meningaud J-P. Intraoperative augmented  
17 205 reality with heads-up displays in maxillofacial surgery: a systematic review of the  
18 206 literature and a classification of relevant technologies. *Int J Oral Maxillofac Surg*  
19 207 2019;48:132–9. <https://doi.org/10.1016/j.ijom.2018.09.010>.  
20  
21 208 [6] Soltanimehr E, Bahrapour E, Imani MM, Rahimi F, Almasi B, Moattari M. Effect of  
22 209 virtual versus traditional education on theoretical knowledge and reporting skills of  
23 210 dental students in radiographic interpretation of bony lesions of the jaw. *BMC Med Educ*  
24 211 2019;19:233. <https://doi.org/10.1186/s12909-019-1649-0>.  
25 212 [7] Durham M, Engel B, Ferrill T, Halford J, Singh TP, Gladwell M. Digitally Augmented  
26 213 Learning in Implant Dentistry. *Oral Maxillofac Surg Clin N Am* 2019;31:387–98.  
27 214 <https://doi.org/10.1016/j.coms.2019.03.003>.  
28  
29 215 [8] Jean-Baptiste Masson - Maxime Dahan† - (EN) Fabien Reyal - (EN) Bassam Hajj -  
30 216 mohamed el beheiry - DIVA — Data Integration and Visualisation in Augmented and  
31 217 Virtual Environments | Research - Institut Pasteur n.d.  
32 218 [https://research.pasteur.fr/fr/project/data-integration-and-visualisation-in-augmented-](https://research.pasteur.fr/fr/project/data-integration-and-visualisation-in-augmented-and-virtual-environments/)  
33 219 [and-virtual-environments/](https://research.pasteur.fr/fr/project/data-integration-and-visualisation-in-augmented-and-virtual-environments/) (accessed February 16, 2020).  
34 220 [9] El Beheiry M, Godard C, Caporal C, Marcon V, Ostertag C, Sliti O, et al. DIVA: Natural  
35 221 Navigation inside 3D Images Using Virtual Reality. *J Mol Biol* 2020.  
36 222 <https://doi.org/10.1016/j.jmb.2020.05.026>.  
37  
38 223 [10] Klingenberg CP. MorphoJ: an integrated software package for geometric  
39 224 morphometrics. *Mol Ecol Resour* 2011;11:353–7. [https://doi.org/10.1111/j.1755-](https://doi.org/10.1111/j.1755-0998.2010.02924.x)  
40 225 [0998.2010.02924.x](https://doi.org/10.1111/j.1755-0998.2010.02924.x).  
41 226 [11] Ten Berge JMF, J.C. Gower and G.B. Dijksterhuis. Procrustes problems. New York:  
42 227 Oxford University Press. *Psychometrika* 2005;70:799–801.  
43 228 <https://doi.org/10.1007/s11336-005-1390-y>.  
44 229 [12] McLachlan JC, Patten D. Anatomy teaching: ghosts of the past, present and future. *Med*  
45 230 *Educ* 2006;40:243–53. <https://doi.org/10.1111/j.1365-2929.2006.02401.x>.  
46 231 [13] Triepels CPR, Smeets CFA, Notten KJB, Kruitwagen RFPM, Futterer JJ, Vergeldt TFM,  
47 232 et al. Does three-dimensional anatomy improve student understanding? *Clin Anat*  
48 233 2020;33:25–33. <https://doi.org/10.1002/ca.23405>.  
49 234 [14] Mascarenhas W, Richmond D, Chiasson G. CTRead—A Revolutionary Approach to  
50 235 Training Residents in Computed Tomography Facial Bone Interpretation. *J Oral*  
51 236 *Maxillofac Surg* 2019;77:1841–6. <https://doi.org/10.1016/j.joms.2019.04.016>.  
52 237 [15] Alsabbagh AY, Watt-Smith S, Leeson R. Comparison of CT, 3D Reconstruction, and  
53 238 Virtual Reality in the Interpretation of Maxillofacial Fractures. *Br J Oral Maxillofac*  
54 239 *Surg* 2019;57:e69. <https://doi.org/10.1016/j.bjoms.2019.10.205>.  
55  
56  
57  
58  
59  
60  
61  
62  
63  
64  
65

- 240 [16] Trelease RB. Anatomical informatics: Millennial perspectives on a newer frontier. *Anat*  
1 241 *Rec* 2002;269:224–35. <https://doi.org/10.1002/ar.10177>.
- 2 242 [17] Brouwers L, Pull Ter Gunne AF, de Jongh MA, Maal TJJ, Vreeken R, van der Heijden  
3 243 FHWM, et al. What is the value of 3D virtual reality in understanding acetabular  
4 244 fractures? *Eur J Orthop Surg Traumatol Orthop Traumatol* 2020;30:109–16.  
5 245 <https://doi.org/10.1007/s00590-019-02537-w>.
- 7 246 [18] Zhang J, Li D, Liu Q, He L, Huang Y, Li P. Virtual surgical system in reduction of  
8 247 maxillary fracture. 2015 IEEE Int. Conf. Digit. Signal Process. DSP, 2015, p. 1102–5.  
9 248 <https://doi.org/10.1109/ICDSP.2015.7252050>.
- 11 249 [19] Huang T-K, Yang C-H, Hsieh Y-H, Wang J-C, Hung C-C. Augmented reality (AR) and  
12 250 virtual reality (VR) applied in dentistry. *Kaohsiung J Med Sci* 2018;34:243–8.  
13 251 <https://doi.org/10.1016/j.kjms.2018.01.009>.
- 14 252 [20] Roessel J, Knoell M, Hofmann J, Buettner R. A systematic literature review of practical  
15 253 virtual and augmented reality solutions in surgery. *COMPSAC 2020 Proc. Conf. 44th*  
16 254 *IEEE Comput. Softw. Appl. Conf. Madr. Spain, Madrid, Spain: COMPSAC 2020*  
17 255 *Proceedings*; 2020.
- 19 256 [21] Bartella AK, Kamal M, Scholl I, Schiffer S, Steegmann J, Ketelsen D, et al. Virtual  
20 257 reality in preoperative imaging in maxillofacial surgery: implementation of “the next  
21 258 level”? *Br J Oral Maxillofac Surg* 2019;57:644–8.  
22 259 <https://doi.org/10.1016/j.bjoms.2019.02.014>.
- 24 260 [22] Pulijala Y, Ma M, Ayoub A. VR Surgery: Interactive Virtual Reality Application for  
25 261 Training Oral and Maxillofacial Surgeons using Oculus Rift and Leap Motion. In: Ma  
26 262 M, Oikonomou A, editors. *Serious Games Edutainment Appl. Vol. II*, Cham: Springer  
27 263 International Publishing; 2017, p. 187–202. [https://doi.org/10.1007/978-3-319-51645-](https://doi.org/10.1007/978-3-319-51645-5_8)  
28 264 [5\\_8](https://doi.org/10.1007/978-3-319-51645-5_8).
- 30 265 [23] Estai M, Bunt S. Best teaching practices in anatomy education: A critical review. *Ann*  
31 266 *Anat - Anat Anz* 2016;208:151–7. <https://doi.org/10.1016/j.aanat.2016.02.010>.
- 32 267 [24] Pulijala Y, Ma M, Pears M, Peebles D, Ayoub A. Effectiveness of Immersive Virtual  
33 268 Reality in Surgical Training-A Randomized Control Trial. *J Oral Maxillofac Surg Off J*  
34 269 *Am Assoc Oral Maxillofac Surg* 2018;76:1065–72.  
35 270 <https://doi.org/10.1016/j.joms.2017.10.002>.
- 37 271

272 **Figures legends**

273

274 **Figure 1.** 3D renderings provided by a freeware (RadiAnt, Medixant, Poznan, Poland) (**A, B**)  
275 and DIVA (**C, D**) for the per- and post-operative aspects of a Le Fort III fracture trauma case  
276 (case №3).

277

278 **Figure 2.** Exploring a pre-operative (**A**) and post-operative (**B**) Le Fort III trauma case (case  
279 №3) using DIVA. 2D sections can be visualized on a box surrounding the 3D rendering, and  
280 the used can interact with the 3D avatar using cutting tools, in order to better understand the  
281 internal skull anatomy.

282

283 **Figure 3.** Low error values when positioning 3D landmarks using DIVA: all mean 3D errors  
284 were lower than an arbitrary threshold of 1 millimeter. mm: millimeter; 3D: tridimensional;  
285 ANS: anterior nasal spine; PNS: posterior nasal spine; Cusp\_17: distal palatal cuspid of tooth  
286 17; Cusp\_27: distal palatal cuspid of tooth 17; Apex\_C2: apex of the odontoid process of C2;  
287 Apex\_galli: apex of the *crista galli* process.

288 **Table legends**

1  
2  
3  
4  
5  
6  
7  
8  
9  
10  
11  
12  
13  
14  
15  
16  
17  
18  
19  
20  
21  
22  
23  
24  
25  
26  
27  
28  
29  
30  
31  
32  
33  
34  
35  
36  
37  
38  
39  
40  
41  
42  
43  
44  
45  
46  
47  
48  
49  
50  
51  
52  
53  
54  
55  
56  
57  
58  
59  
60  
61  
62  
63  
64  
65

289

290 **Table 1.** Assessment of the use of VR in craniofacial trauma education by 50 undergraduate  
291 medical students from the University of Paris.

292 **Supplemental Digital Contents**

1  
2  
3  
4  
5  
6  
7  
8  
9  
10  
11  
12  
13  
14  
15  
16  
17  
18  
19  
20  
21  
22  
23  
24  
25  
26  
27  
28  
29  
30  
31  
32  
33  
34  
35  
36  
37  
38  
39  
40  
41  
42  
43  
44  
45  
46  
47  
48  
49  
50  
51  
52  
53  
54  
55  
56  
57  
58  
59  
60  
61  
62  
63  
64  
65

293

294 ***Supplemental Digital Content 1.*** Pre-operative and post-operative virtual avatars (case №3)

295 on DIVA.

296

297 ***Supplemental Digital Content 2.*** Pre-operative virtual avatar (case №3) on DIVA with

298 implementation of 2D sections and the cutting tool.

299

300 ***Supplemental Digital Content 3.*** Post-operative virtual avatar (case №3) on DIVA with

301 implementation of 2D sections and the cutting tool.

302

303 ***Supplemental Digital Content 4.*** 3D distribution of anatomical landmarks placed by the 4

304 evaluators on a post-operative virtual avatar (case №3).



305 **Acknowledgments**

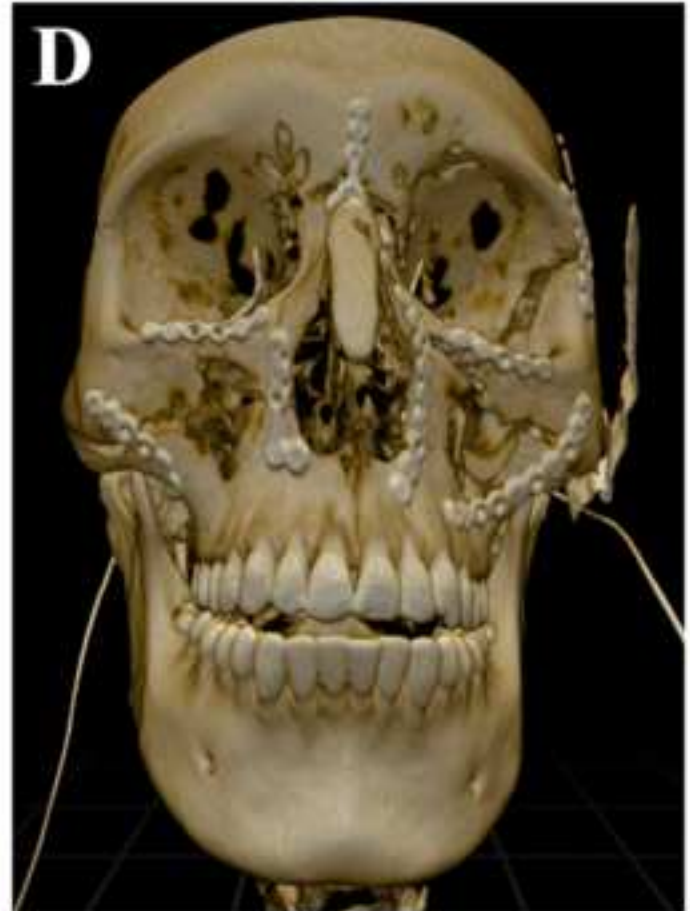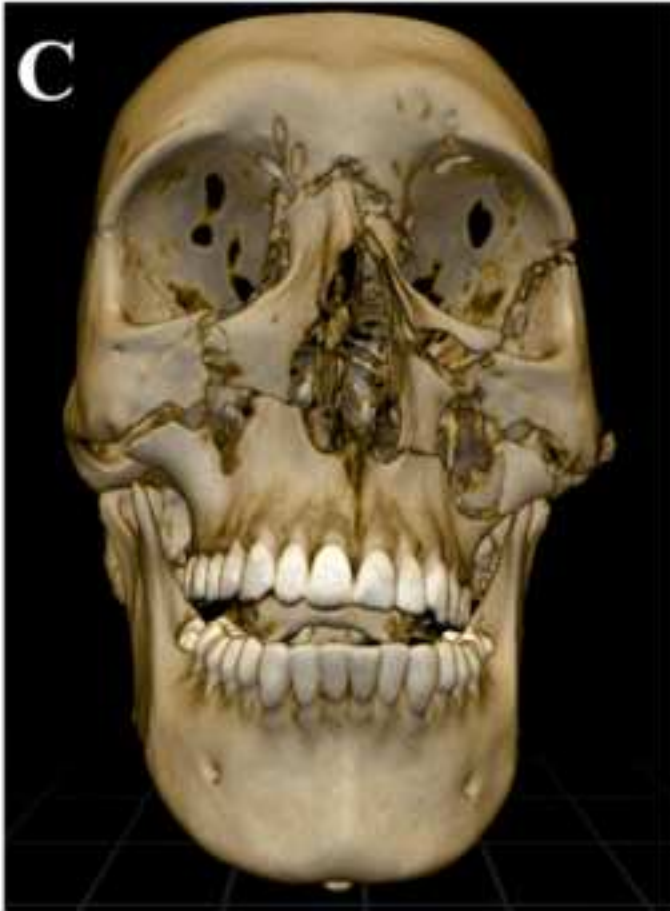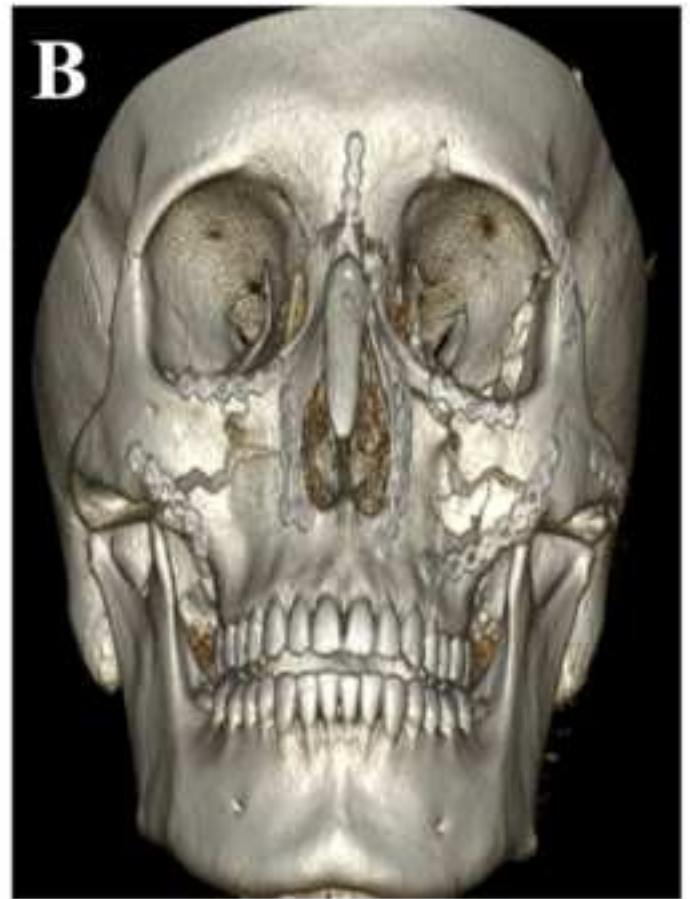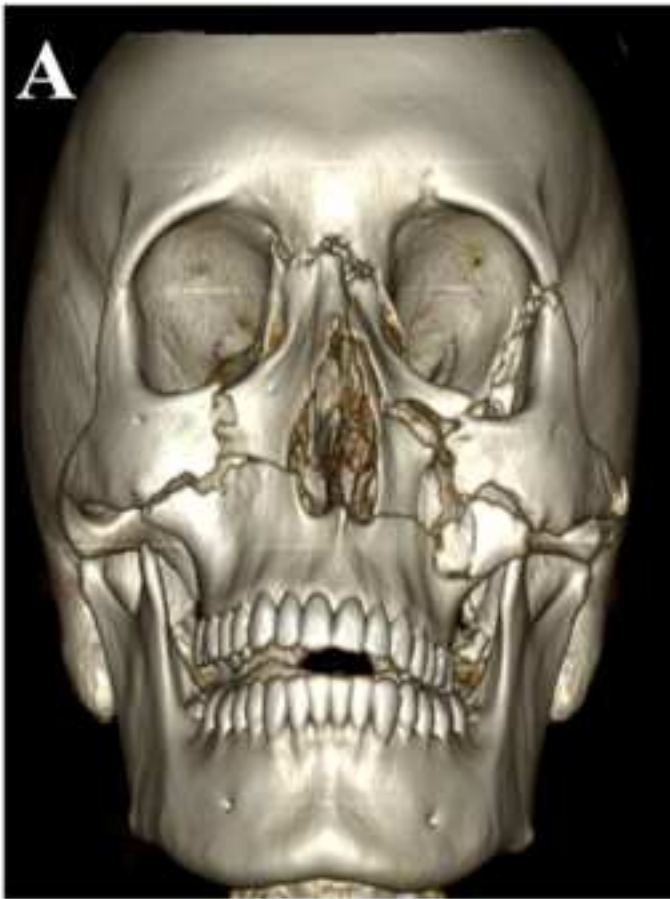1  
2 306 We acknowledge funding from Institut Pasteur, Institut Curie, Paris Sciences Lettres and the  
3  
4  
5 307 sponsorship of CRPCEN, Gilead-Sciences, and fondation EDF, the “programme  
6  
7 308 d’investissement d’avenir” supported by the “agence nationale de la recherche” ANR-19-  
8  
9 309 P3IA-0001 (PRAIRIE 3IA Institute), INCEPTION project (PIA/ANR- 16-CONV-0005,  
10  
11 310 OG)), and TRamWAY ANR-17-CE23-0016.

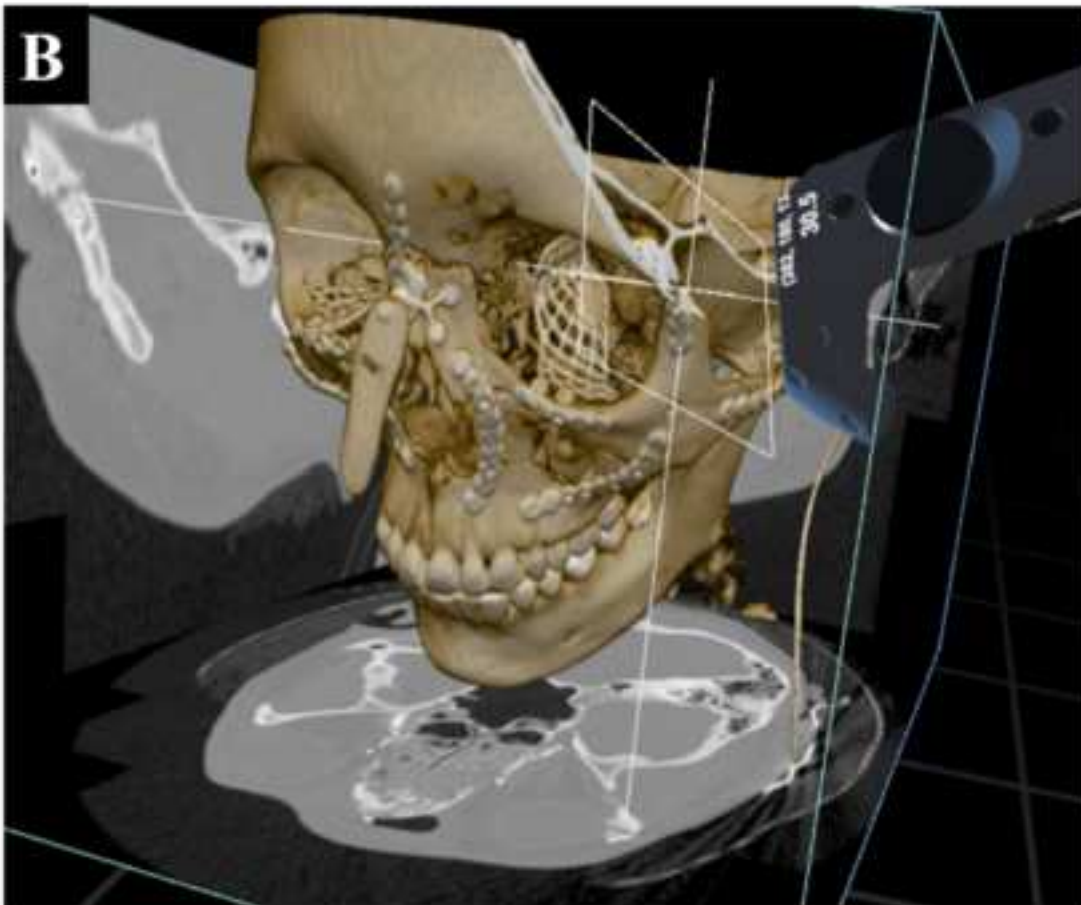
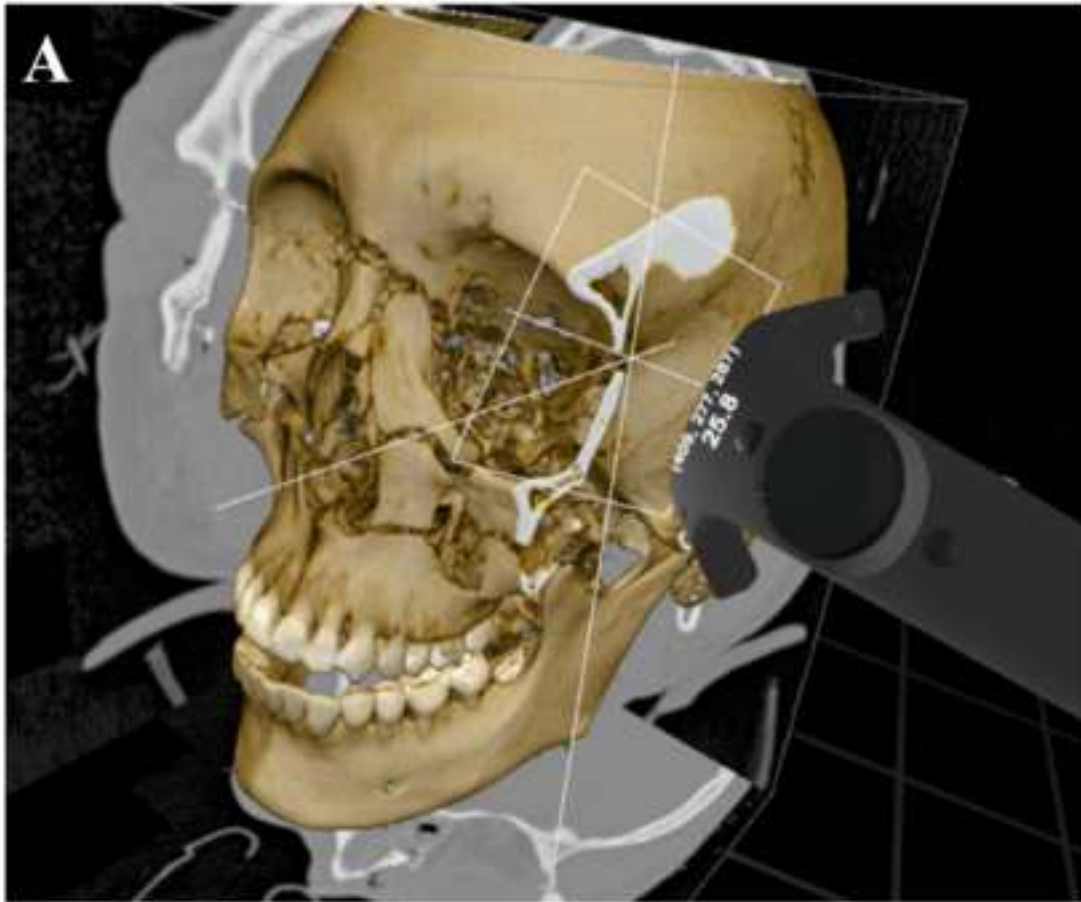
12  
13  
14 311 Special thanks to Kevin Bloch, Alexia Kany, Alice Prevost and Camille Rabot.  
15  
16  
17 312

18  
19 313 **Conflict of interest**

20  
21 314 Mohamed El Beheiry and Jean-Baptiste Masson are cofounders, shareholders and scientific  
22  
23  
24 315 advisors of Avatar Medical.

25  
26 316 Jean-Baptiste Masson is one of the scientific advisors of the Robeauté startup.  
27  
28  
29  
30  
31  
32  
33  
34  
35  
36  
37  
38  
39  
40  
41  
42  
43  
44  
45  
46  
47  
48  
49  
50  
51  
52  
53  
54  
55  
56  
57  
58  
59  
60  
61  
62  
63  
64  
65





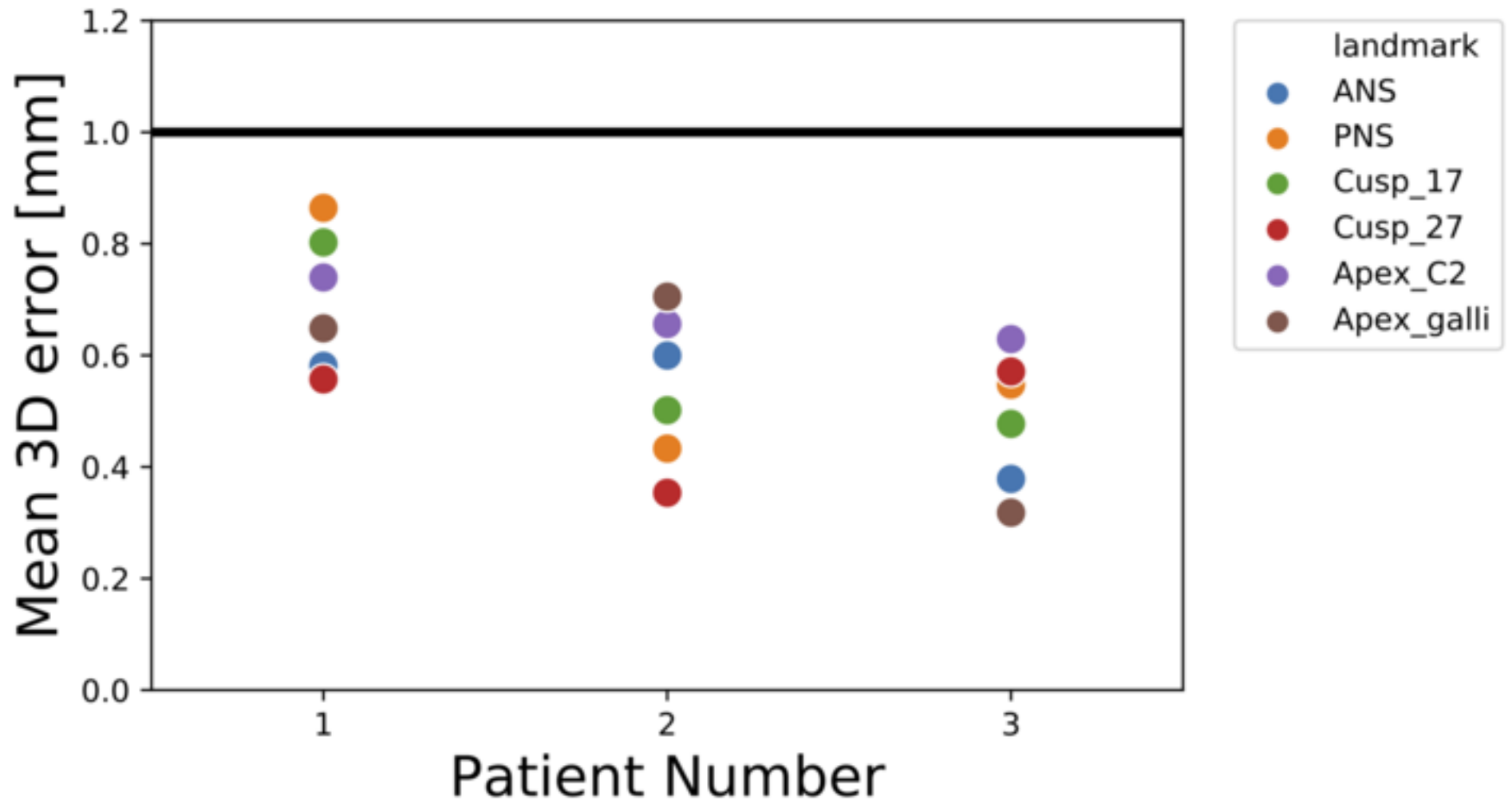


Table 1

Questions	Responses	Evaluation scale and more detailed student responses	
1. Are you satisfied of DIVA when exploring craniofacial trauma cases?	Yes n=49 No n =1	5: very satisfied 4: more than satisfied 3: satisfied 2: partly satisfied 1: not at all satisfied	5: n=27 4: n=19 3: n=4 2: n=0 1: n=0
2. Do you think that DIVA was easy and intuitive to use?	Yes n=50 No n =0	5: very easy and intuitive 4: more than easy and intuitive 3: easy and intuitive 2: partly intuitive 1: not at all intuitive	5: n=22 4: n=22 3: n=4 2: n=2 1: n=0
3. Have you experienced any difficulties in tolerating the use of DIVA?	Yes n=7 No n =43	<input type="checkbox"/> visual fatigue <input type="checkbox"/> headaches <input type="checkbox"/> dizziness <input type="checkbox"/> nausea <input type="checkbox"/> other (precise)	n=0 n=0 n=0 n=0 n=0
4. Does the use of DIVA allow you to visualize some lesions <u>not suspected</u> on usual 2D and 3D renderings?	Yes n=41 No n =9	Fracture of the pterygoid processes were especially well apprehended and visualized using DIVA.	
5. Does the use of DIVA allow you to better visualize some lesions seen on usual 2D and 3D renderings?	Yes n=49 No n =1	Fractures lines were better visualized and understood using DIVA.	
6. Do you think that DIVA was beneficial to understand maxillofacial trauma?	Yes n=50 No n =0	5: very profitable 4: more than profitable 3: profitable 2: partly profitable 1: not at all profitable	5: n=27 4: n=19 3: n=4 2: n=0 1: n=0

<p>7. Do you VR is of interest for the better understanding of maxillofacial anatomy? Please precise</p>	<p>Yes n=48 No n =1</p>	<p>It provides a better visualization of the maxillofacial anatomy, which helps the comprehension of the traumatology.</p>	
<p>8. Would you advise using DIVA as a standard educational tool in traumatology?</p>	<p>Yes n=49 No n =1</p>	<p>5: highly recommended 4: more than recommended 3: recommended 2: partly recommended 1: not at all recommended</p>	<p>5: n=25 4: n=22 3: n=2 2: n=0 1: n=1</p>