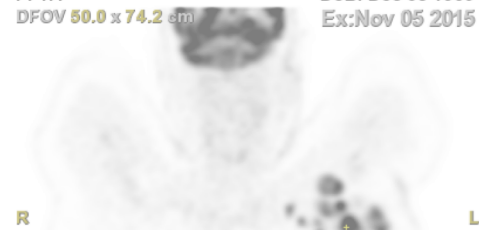
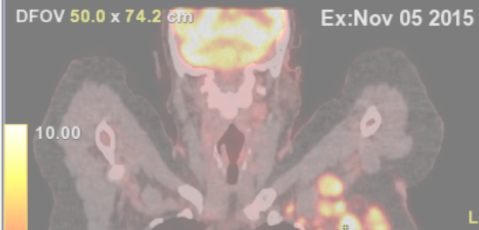




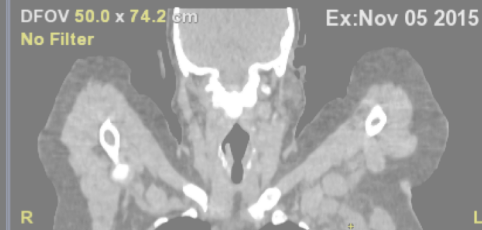Coronal PET AC TOF S 50 R24 R24
Ex: 646 Institut Jean Godinot
Se: 12 F 45 21507697
P: 1.4 DoB: Dec 08 1969
DFOV 50.0 x 74.2 cm Ex: Nov 05 2015



Coronal PET AC TOF->CT Standard R24 R24
Ex: 50% 646 / 50% 646 S 50 Institut Jean Godinot
Se: 12 / 3 F 45 21507697
P: 1.4 DoB: Dec 08 1969
DFOV 50.0 x 74.2 cm Ex: Nov 05 2015



Coronal CT Standard S 49 R24 R24
Ex: 646 Institut Jean Godinot
Se: 3 F 45 21507697
P: 1.8 DoB: Dec 08 1969
DFOV 50.0 x 74.2 cm Ex: Nov 05 2015
No Filter



Segmentation of Axillary and Supraclavicular Tumoral Lymph Nodes in PET / CT: A Hybrid CNN / Component-Tree Approach

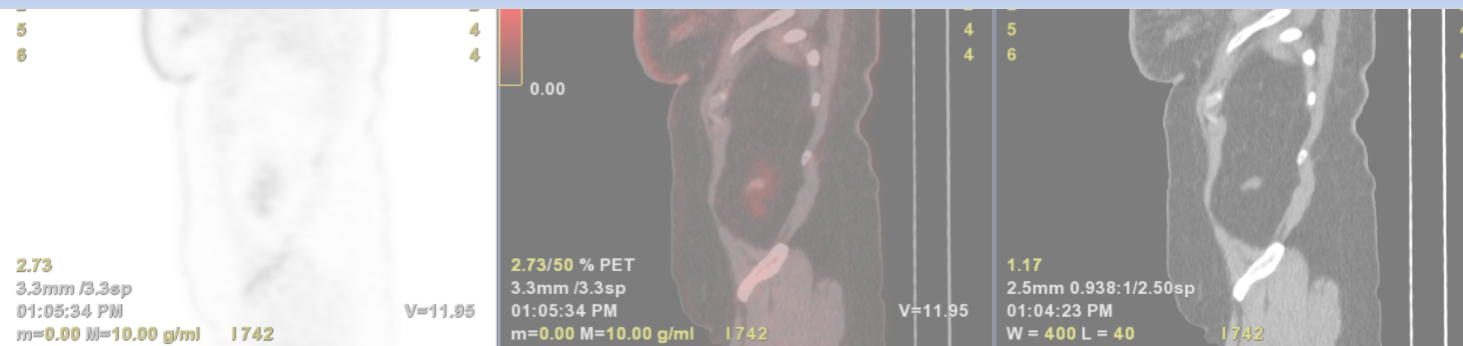
D. L. Farfan Cabrera, N. Gogin, D. Morland, B. Naegel, D. Papathanassiou, N. Passat

Université de Reims Champagne Ardenne, CReSTIC, EA 3804, 51097 Reims, France

General Electric Healthcare, Buc, France

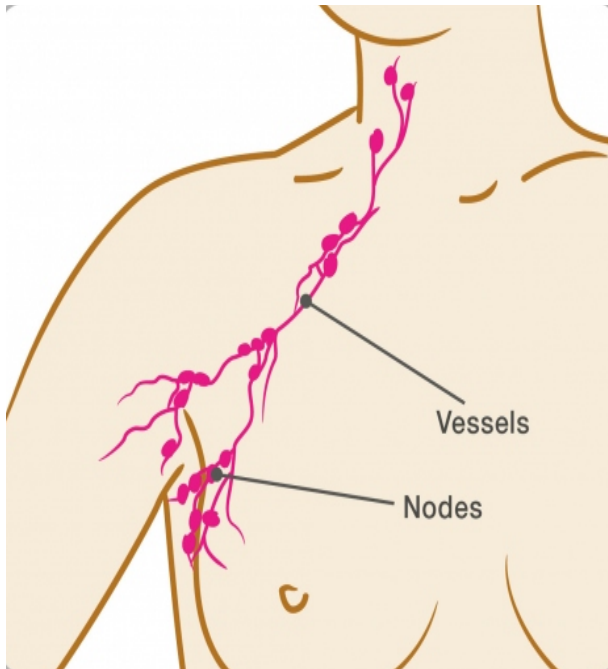
Département de Médecine Nucléaire, Institut Godinot, Reims, France

Université de Strasbourg, CNRS, ICube, Strasbourg, France

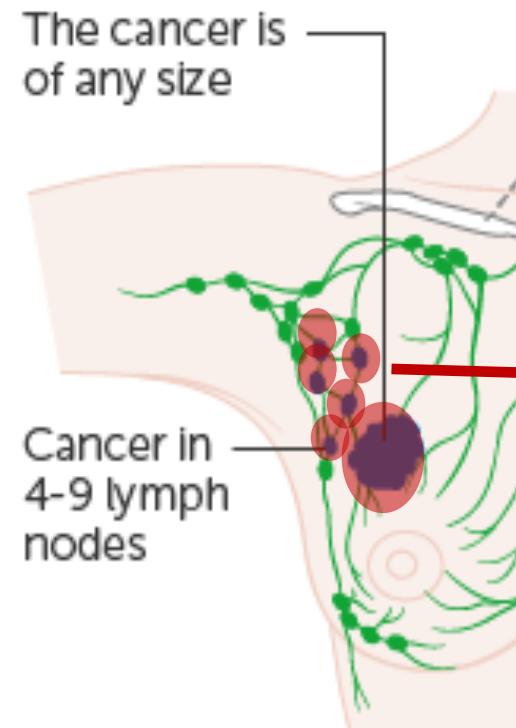


Automatic axillary lymph node tumor segmentation in PET/CT

What are lymph nodes?



Patient with no breast cancer

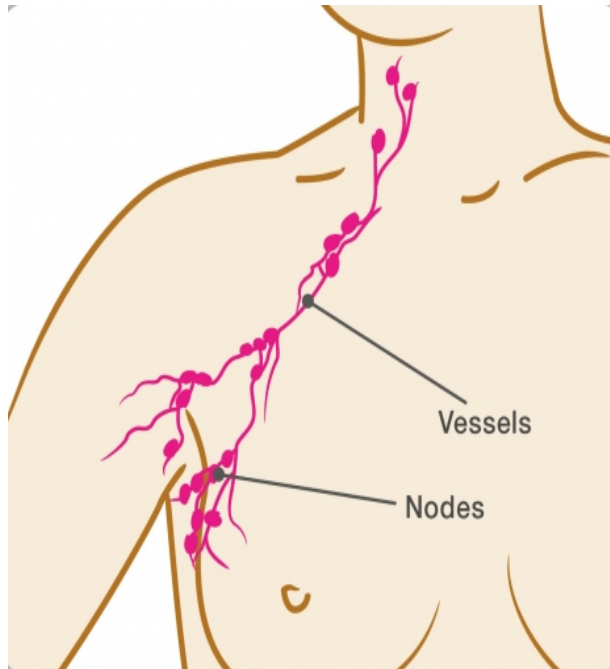


Patient with breast cancer

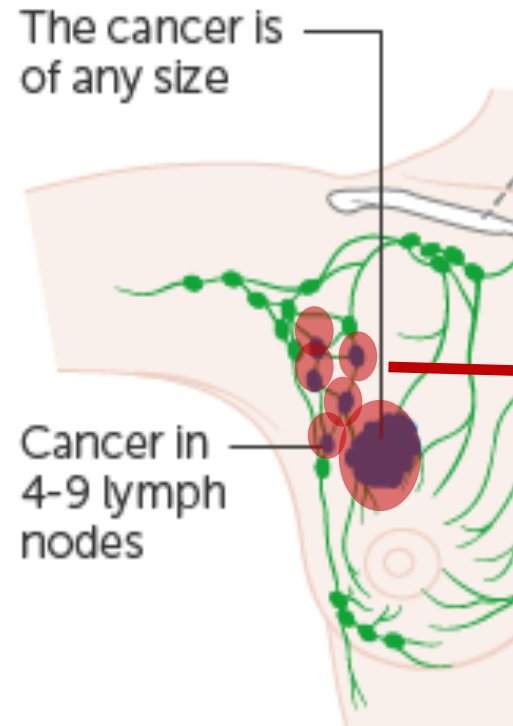
lymph nodes are the first organs reached by cancer

Automatic axillary lymph node tumor segmentation in PET/CT

What are our contributions?



Patient with no breast cancer



Patient with breast cancer

1st Contribution:

- Provide a prognostic factor for the staging of breast cancer

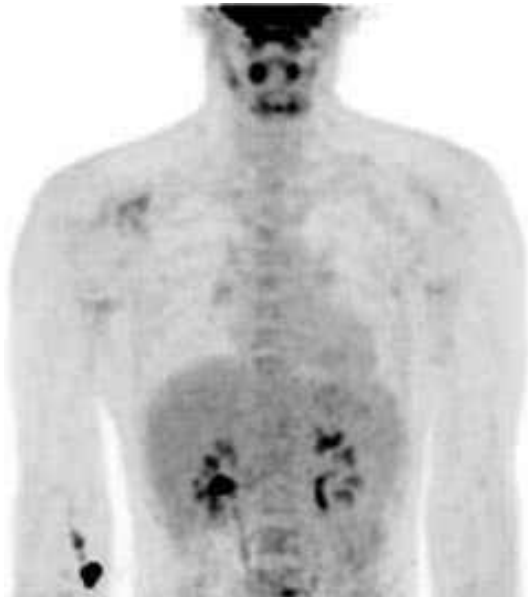lymph nodes are the first organs reached by cancer

Cancer staging is determined by:

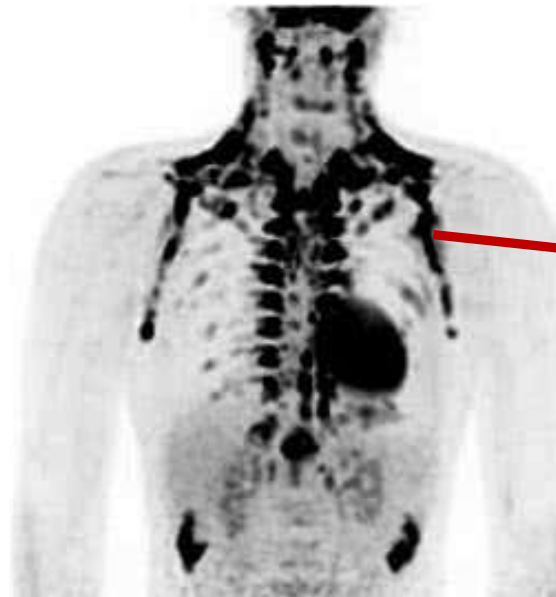
- N:** number of lymph nodes with cancer
- T:** tumor volume
- M:** metastasis state

Automatic axillary lymph node tumor segmentation in PET/CT

What are our contributions?



PET image



PET image

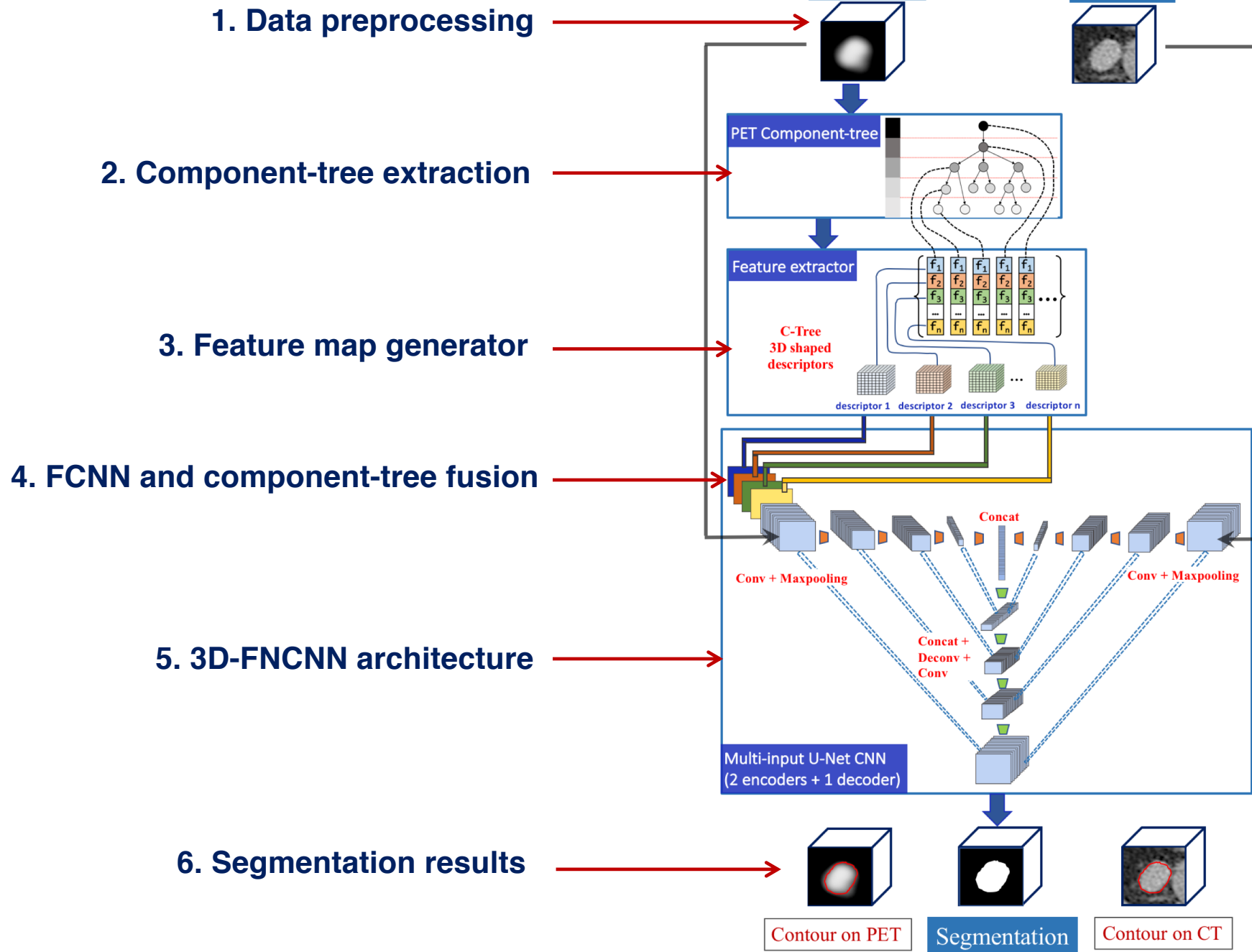
Brown fat shows up (due to exposure to cold)

2nd Contribution:

- Help doctors to identify quicker false positive coming from brown fat

brown fat

- Brown fat has the same metabolism as tumor cells
- Brown fat generates **false positives** that can be mistaken by tumors

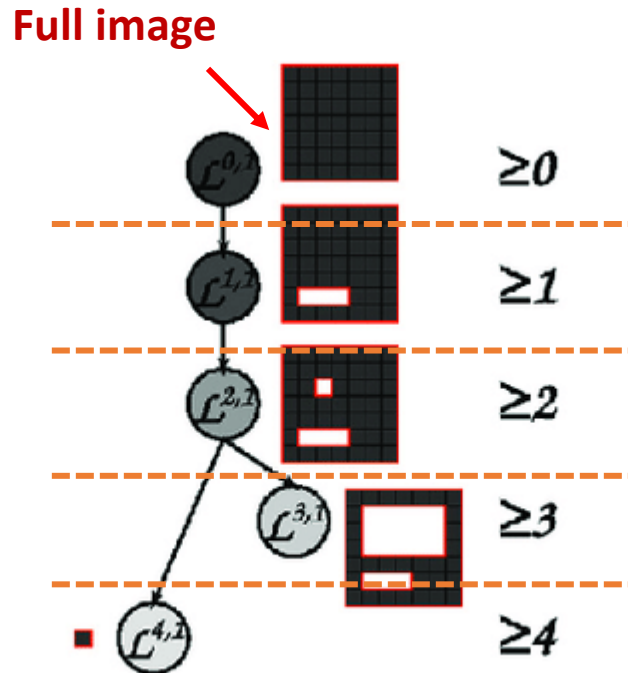


Automatic lymph node tumor segmentation in PET/CT

2. Component-tree extraction

What is a component-tree?

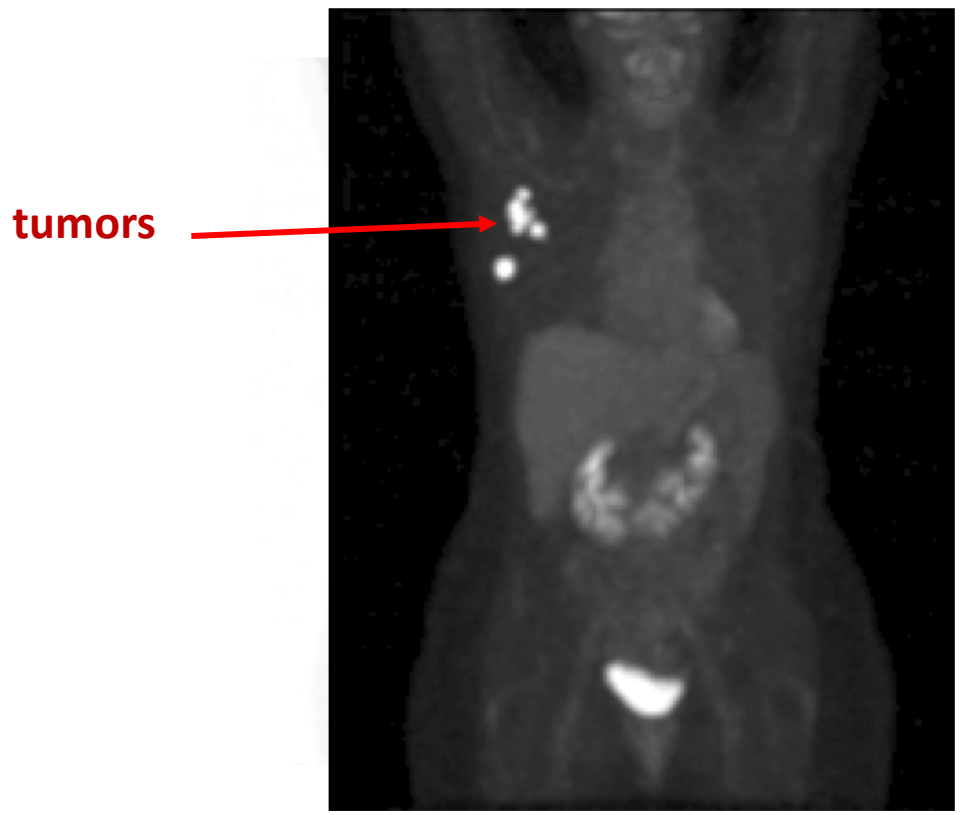
3	3	3	3	3	3	3
3	2	2	2	2	2	3
3	2	1	2	4	2	3
3	2	2	2	2	2	3
3	3	3	3	3	3	3
3	0	0	0	3	3	3
3	3	3	3	3	3	3



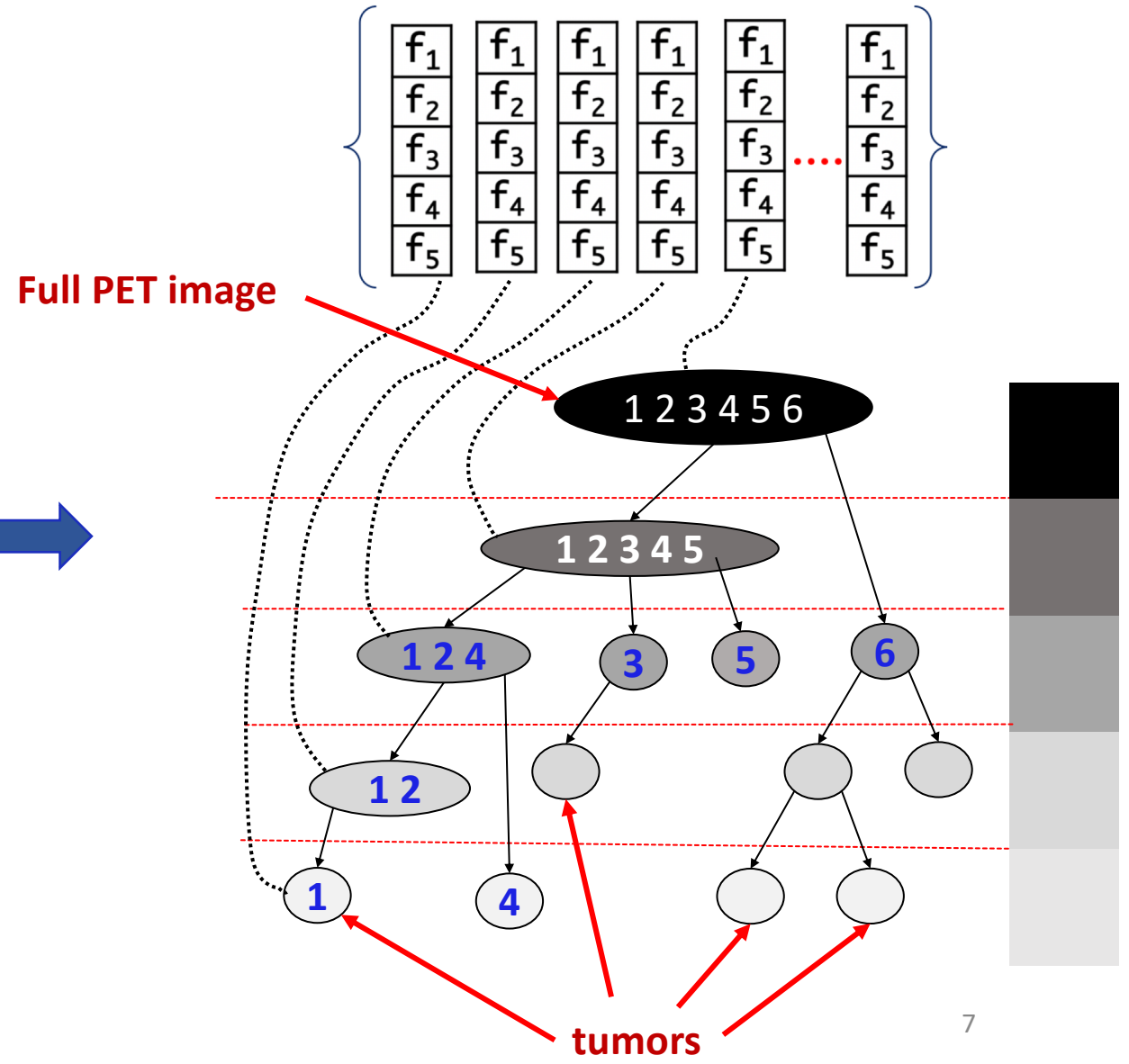
- Each node is a connected component
- Root node contains all the image
- Follows a hierarchical structure according to gray levels
- Each tree level corresponds to a gray level
- Each node belongs to its ascendants nodes

Automatic lymph node tumor segmentation in PET/CT

2. Component-tree extraction



PET image
Coronal MIP view

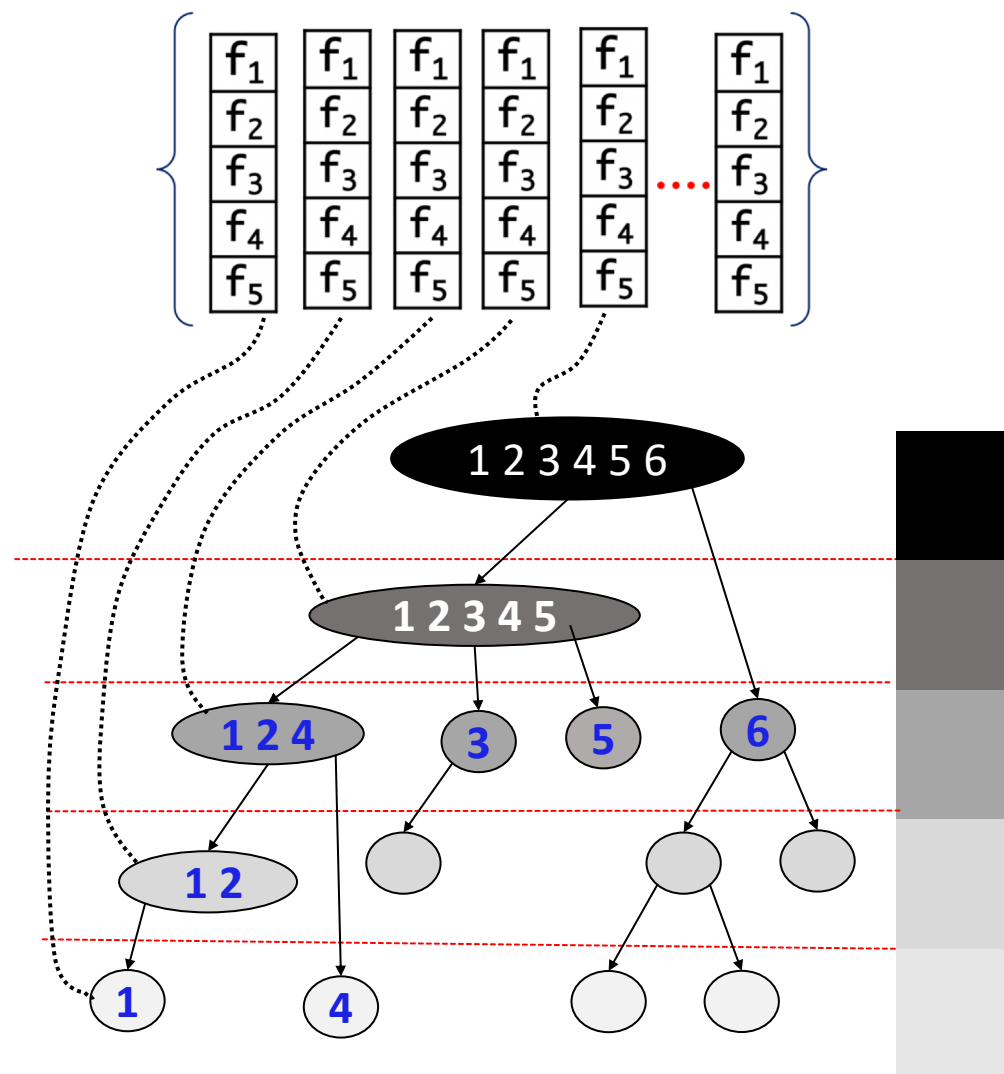


Automatic lymph node tumor segmentation in PET/CT

2. Component-tree extraction

For each node N_i , it is computed:

- $f_1 \rightarrow G(N_i)$: mean gradient of node contour in PET
- $f_2 \rightarrow H(N_i)$: mean HU value in CT
- $f_3 \rightarrow S(N_i)$: standard deviation of H
- $f_4 \rightarrow R(N_i)$: relative integral volume
- $f_5 \rightarrow L(N_i)$: position with respect to the lungs



Automatic lymph node tumor segmentation in PET/CT

2. Component-tree extraction

Goal of these descriptors?

We assign to each **node** 5 descriptors

For each node N_i , it is computed:

- $f1 \rightarrow G(N_i)$: mean gradient of node contour \rightarrow lymph node have **high** contour gradient
- $f2 \rightarrow H(N_i)$: mean HU value in CT \rightarrow lymph nodes have **positive** HU value
brown fat has **negative** HU value
- $f3 \rightarrow S(N_i)$: standard deviation of H \rightarrow lymph nodes have **low** standard deviation
- $f4 \rightarrow R(N_i)$: relative integral volume \rightarrow lymph nodes have **high** contrast with their neighbourhood
- $f5 \rightarrow L(N_i)$: position with respect to the lungs \rightarrow lymph nodes are **outside** the lungs convexhull

Automatic lymph node tumor segmentation in PET/CT

3. Feature map generator

From feature vectors to feature volumes?

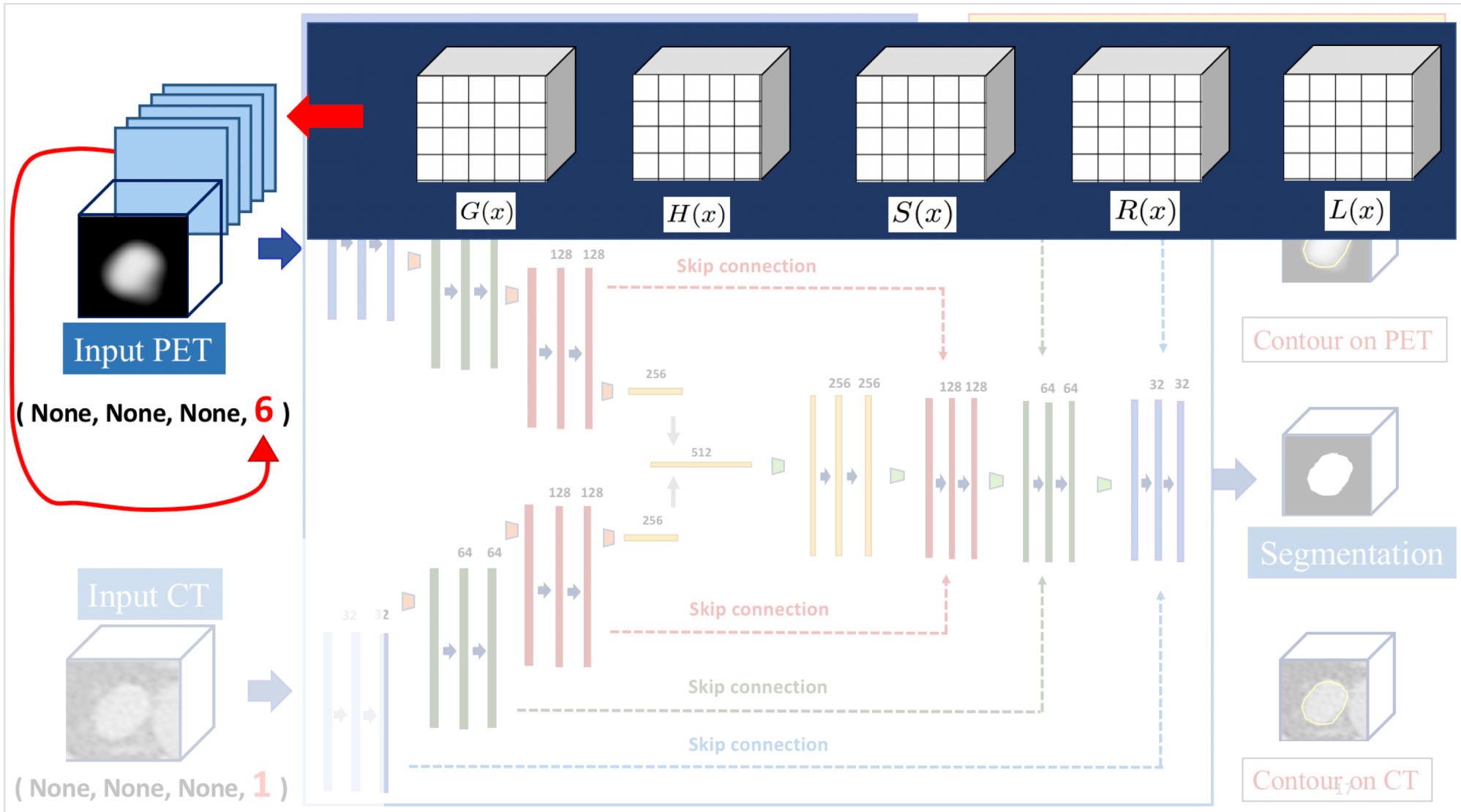
We assign to each **voxel** 5 descriptors

For each voxel x in the PET image, it is computed:

- | | | |
|-------------------------------|---|---|
| $G(x) = \max_i G(N_i)$ | → | lymph node have high contour gradient |
| $H(x) = \text{mean}_i H(N_i)$ | → | lymph nodes have positive HU value
brown fat has negative HU value |
| $S(x) = \min_i S(N_i)$ | → | lymph nodes have low standard deviation |
| $R(x) = \max_i R(N_i)$ | → | lymph nodes have high contrast with their neighbourhood |
| $L(x) = \text{or}_i L(N_i)$ | → | lymph nodes are outside the lungs convexhull |

Automatic lymph node tumor segmentation in PET/CT



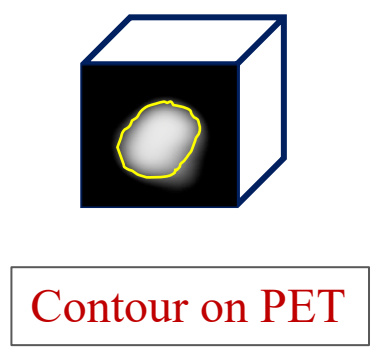
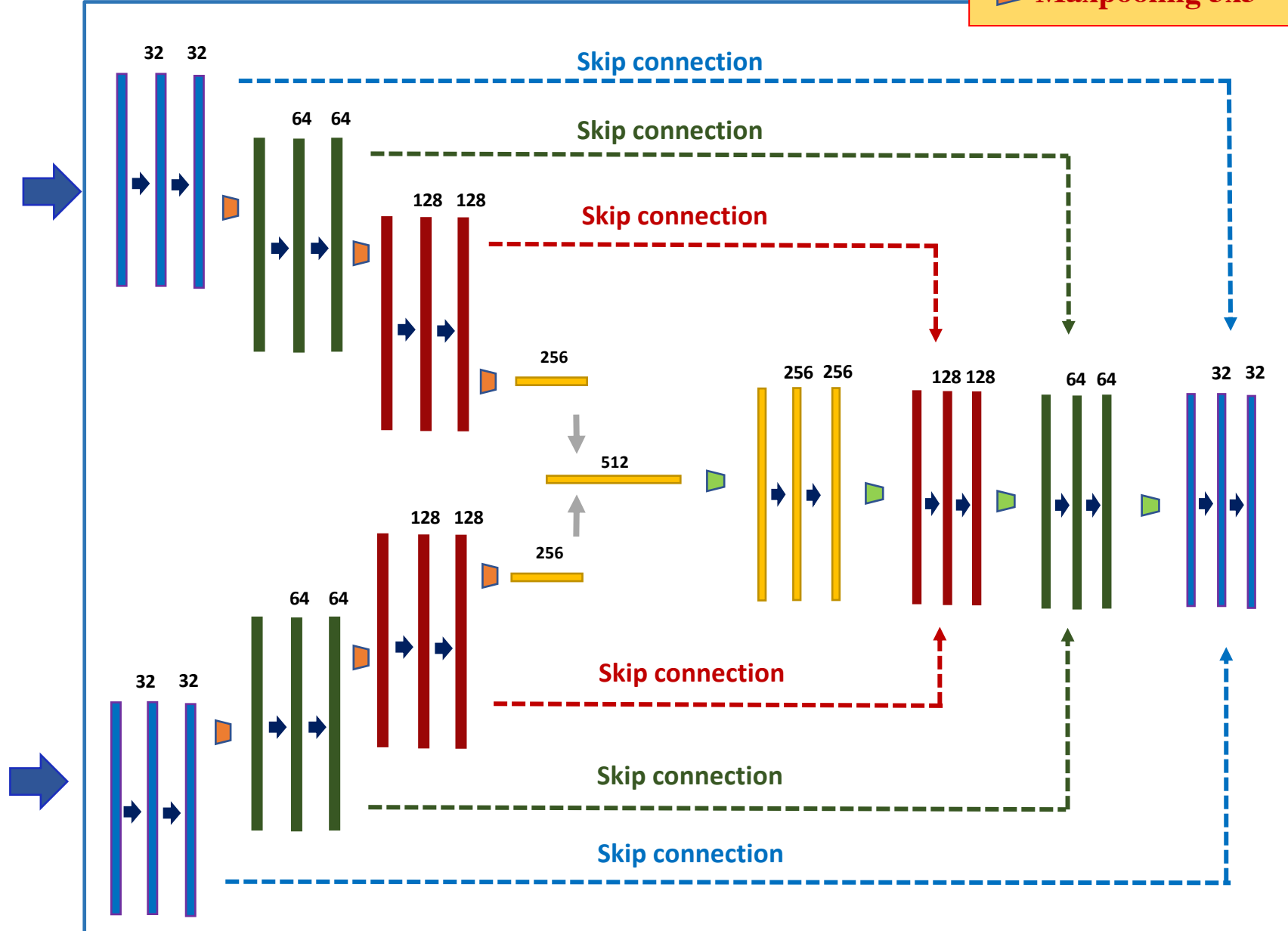
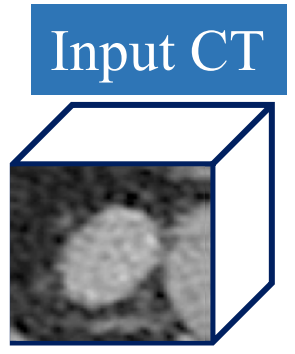

4. CNN and component-tree fusion



5. CNN

3D U-Net PET-CT for LN tumor segmentation (2 encoders + 1 decoder)

➔ **Conv 3x3 Relu** ▢ **Upconv 3x3 Relu**
▢ **Maxpooling 3x3** ↑ **Concatenation**



Automatic lymph node tumor segmentation in PET/CT

6. Results

Training: 201 tumors (42 PET/CT exams)
Validation: 56 tumors
Patches for test: 63 tumors (10 PET/CT exams)
Loss Function: 1 - Dice
Iterations: 1000

Type of CNN: U-NET
Number of layers: 3
Resolution 1.2mm³
3D Patch size: 80 mm³

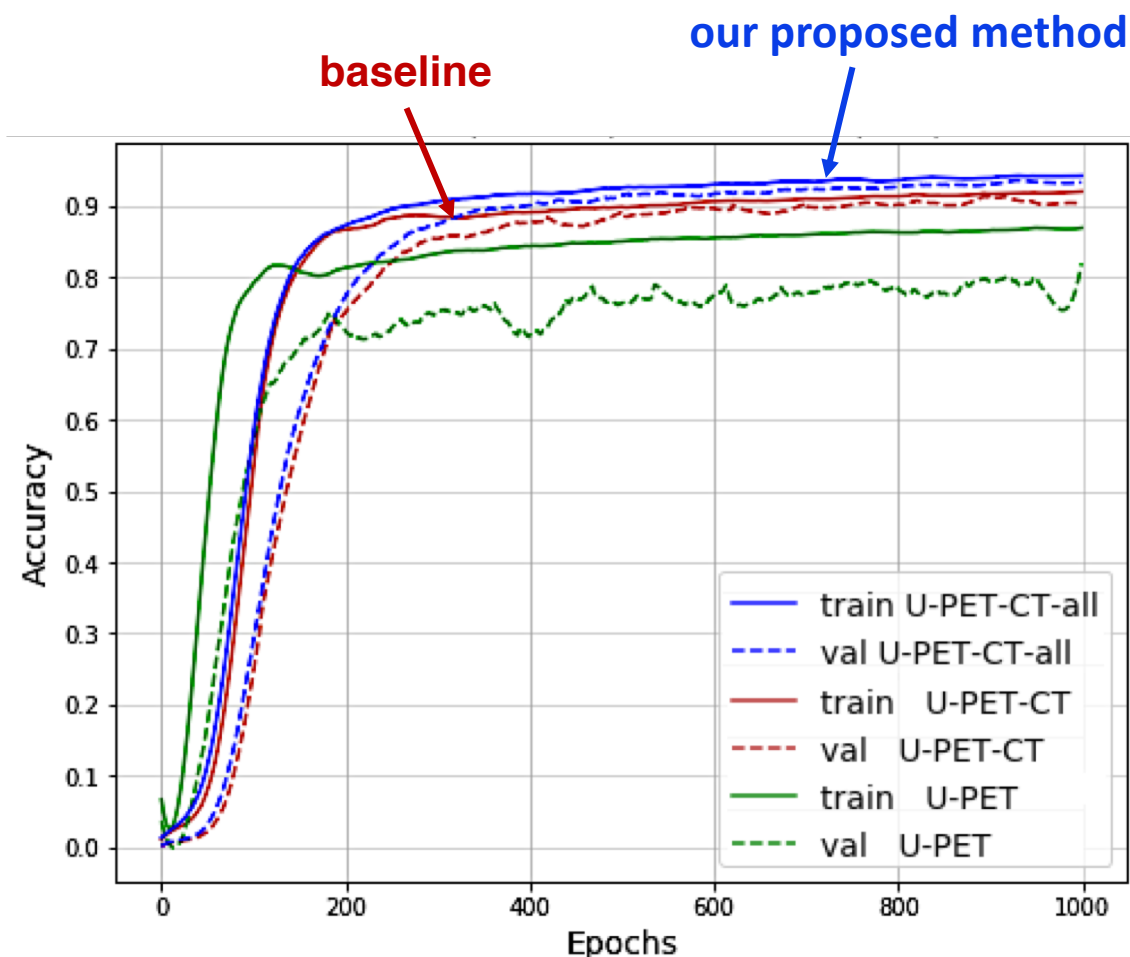
U-PET → inputs {PET}

U-PET-CT → inputs {PET, CT}

U-PET-CT-all → inputs {PET, CT, all feature maps}

baseline →

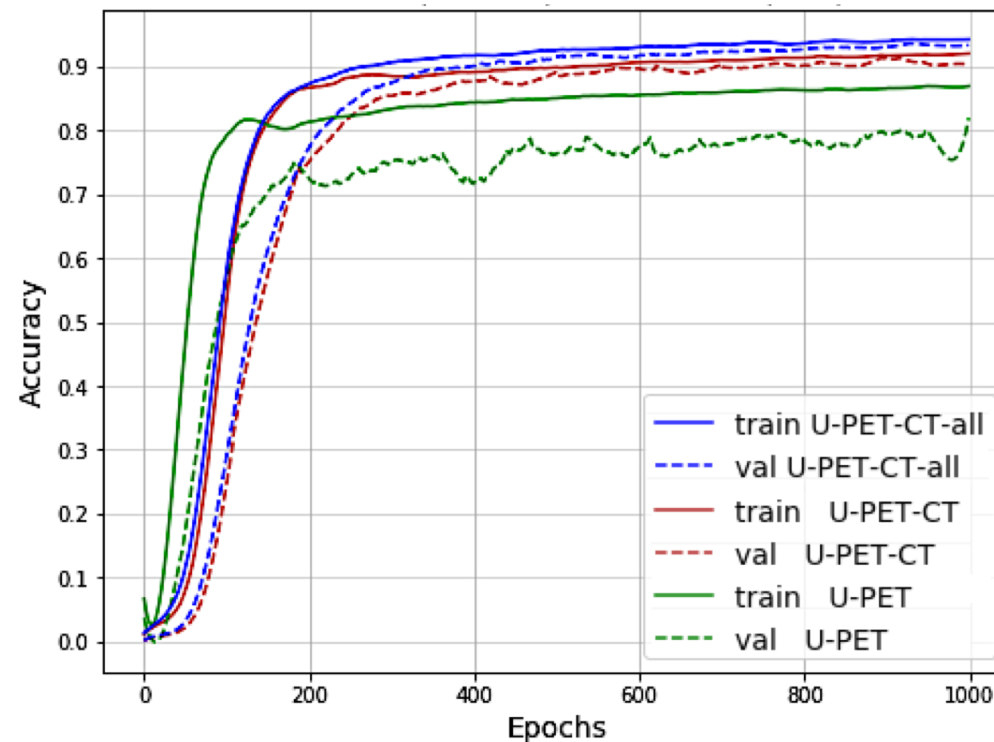
proposed method →



Automatic lymph node tumor segmentation in PET/CT

6. Results

U-PET → inputs {PET}
U-PET-CT → inputs {PET, CT}
U-PET-CT-all → inputs {PET, CT, all feature maps}



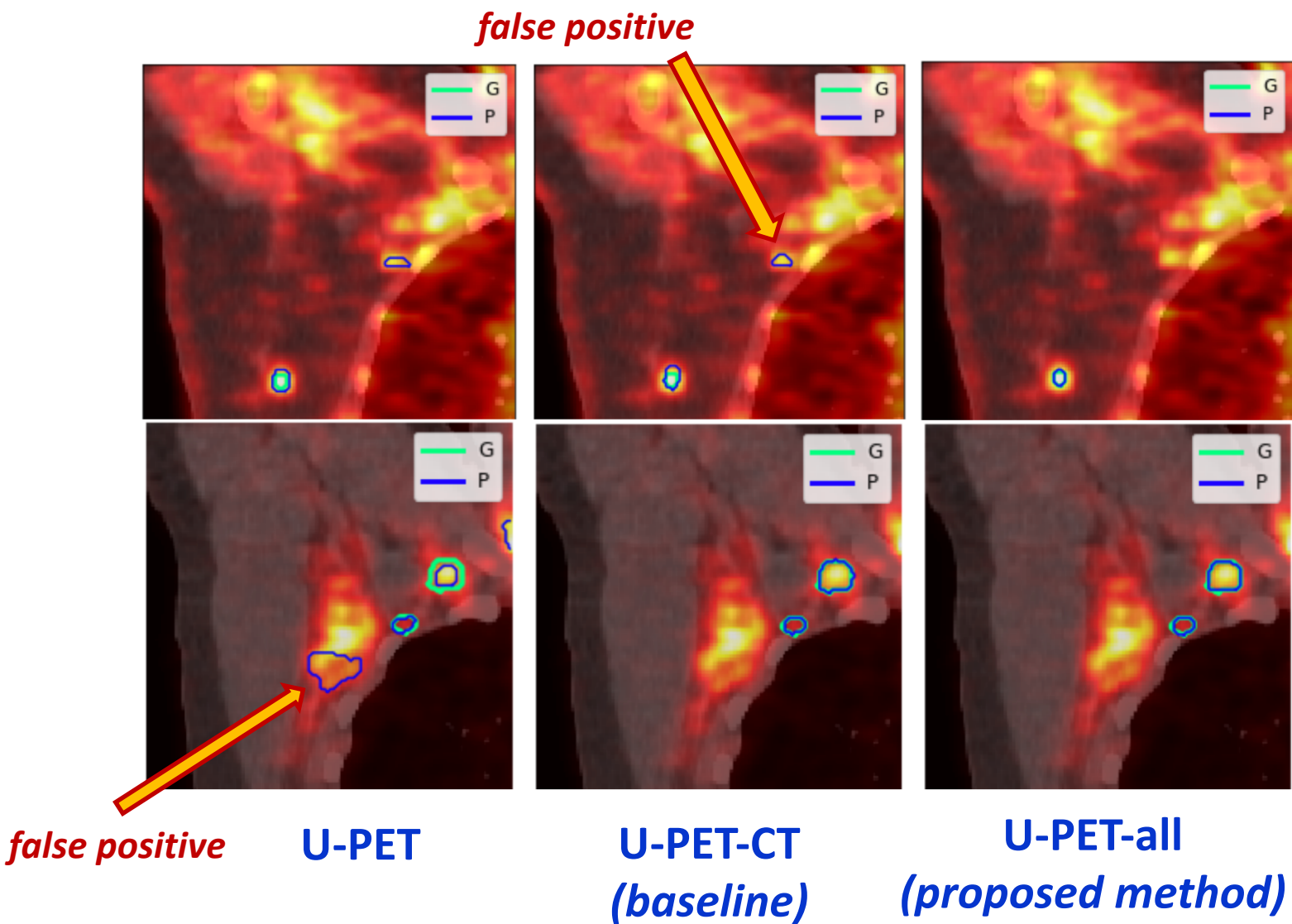
baseline →
proposed method →

3D CNN Model	Voxel-based metrics (Segmentation)			Region-based metrics (Detection)		
	DSC voxel	PPV voxel	SE voxel	DSC region	PPV region	SE region
3D U-Net (PET)	0.832703 +- 0.1327	0.827762 +- 0.1483	0.82478 +- 0.0868	0.798685 +- 0.1547	0.757925 +- 0.2206	0.890805 +- 0.0821
3D U-Net (PET-CT)	0.865896 +- 0.08	0.844429 +- 0.1034	0.886527 +- 0.0465	0.871825 +- 0.1312	0.849864 +- 0.1893	0.926111 +- 0.0628
3D U-Net (PET-CT-all)	0.867845 +- 0.1161	0.872781 +- 0.1425	0.896473 +- 0.0553	0.894624 +- 0.1431	0.851361 +- 0.1948	0.933135 +- 0.0756

6. Results

Proposed method removes false positives coming from brown fat

Results shown on the PET/CT fusion images



Automatic lymph node tumor segmentation in PET/CT

6. Results

Proposed method separates visually connected tumors

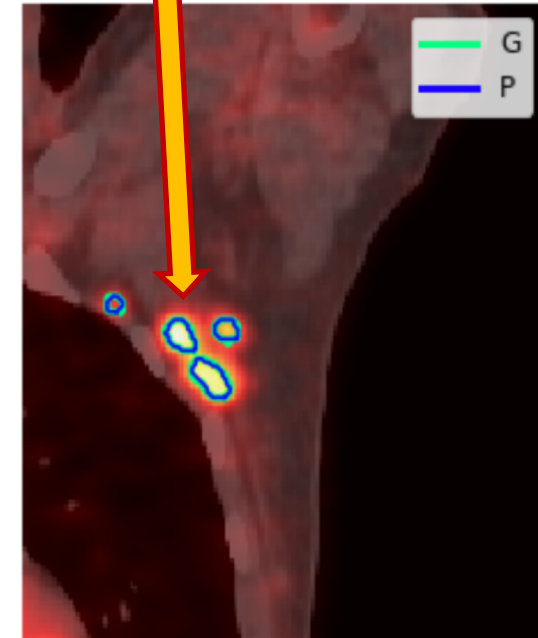
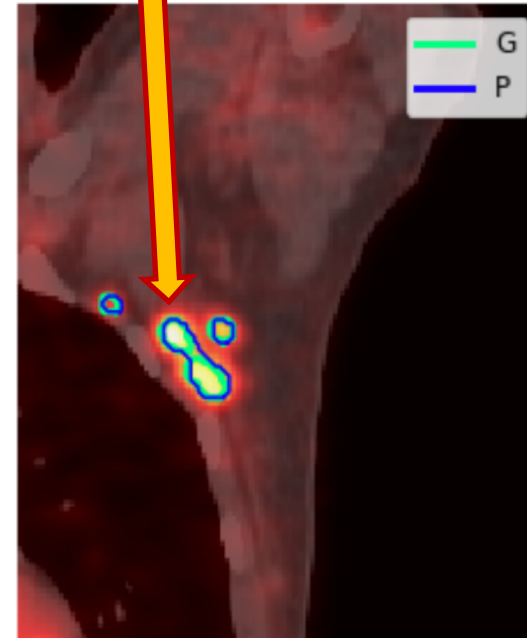
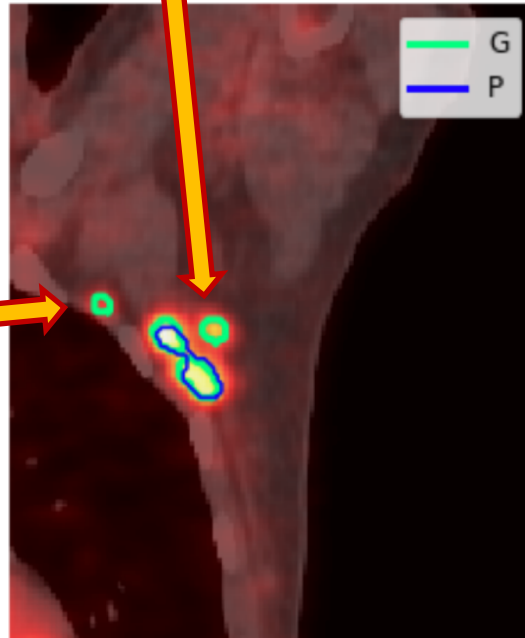
Results shown on the PET/CT fusion images

false positive

joined contours

separated contours

false positive



U-PET

**U-PET-CT
(baseline)**

**U-PET-all
(proposed method)**



Thank you for your attention

mail: diana.lucia.farfan@gmail.com

page: [linkedin.com/dianafarfan](https://www.linkedin.com/dianafarfan)