



HAL
open science

Prospective assessment of trochanteric fracture managed by intramedullary nailing with controlled and limited blade back-out

Manuela Barla, François Egrise, Bogdan Zaharia, Camille Bauer, Jauffrey Parot, Didier Mainard

► To cite this version:

Manuela Barla, François Egrise, Bogdan Zaharia, Camille Bauer, Jauffrey Parot, et al.. Prospective assessment of trochanteric fracture managed by intramedullary nailing with controlled and limited blade back-out. *Orthopaedics & Traumatology: Surgery & Research*, 2020, 106 (4), pp.613-619. 10.1016/j.otsr.2019.11.028 . hal-02961329

HAL Id: hal-02961329

<https://hal.science/hal-02961329>

Submitted on 22 Aug 2022

HAL is a multi-disciplinary open access archive for the deposit and dissemination of scientific research documents, whether they are published or not. The documents may come from teaching and research institutions in France or abroad, or from public or private research centers.

L'archive ouverte pluridisciplinaire **HAL**, est destinée au dépôt et à la diffusion de documents scientifiques de niveau recherche, publiés ou non, émanant des établissements d'enseignement et de recherche français ou étrangers, des laboratoires publics ou privés.



Distributed under a Creative Commons Attribution - NonCommercial 4.0 International License

Original article

Prospective assessment of trochanteric fracture managed by intramedullary nailing with controlled and limited blade back-out.

Manuela **Barla**, François **Egrise**, Bogdan **Zaharia**, Camille **Bauer**, Jauffrey **Parot**, Didier **Mainard**
CHRU Nancy, 54000 Nancy, France

Corresponding author: Manuela Barla,

Hôpital Central
CHRU
Orthopaedics & Traumatology
29 Avenue du Maréchal de Lattre de Tassigny
Nancy, 54000
FRANCE
manuela.barla@gmail.com

Abstract

Introduction – The main objective of the present prospective study was to assess mechanical complications associated with an original intramedullary nail with limited and controlled blade back-out in the treatment of trochanteric fracture.

Material and Method – All patients treated for trochanteric fracture in a single orthopedic/traumatologic surgery department over a 2-year period were included. Minimum follow-up was 6 months. Fracture stability was assessed on the AO criteria. The TFP® intramedullary nail has a monobloc helicoid blade. Its main feature is the controlled and limited blade back-out, optimizing fracture site compression in weight-bearing, without the drawback of excessive back-out. The main endpoint was onset of mechanical complications: cut-out, intra-articular protrusion, non-union, and pain. Baumgaertner's Tip-Apex Distance (TAD), blade centering within the femoral head and fracture reduction were also assessed.

Results – One hundred thirty-eight patients (mean age, 83 years) were operated on, and 118 followed up. There were 9 mechanical complications (7.6%): 4 cut-outs (3.4%), 3 intra-articular protrusions (2.5%), 1 non-union (0.8%) and 1 case of pain (0.8%). TAD length was not associated with complications rate. Poor reduction was significantly associated with more complications ($p = 0.02$), as was blade malpositioning. Mean back-out was 3.3 mm, affecting 22 nails (19%). There were no complications in case of back-out, versus a 9.4% rate in absence of back-out, although this difference was not significant ($p = 0.21$). There were no postoperative infections.

Conclusion – The TFP® nail is useful for fixation of trochanteric fracture, whether stable or unstable, due to its low rate of mechanical complications compared to the literature.

Key-words: trochanteric fracture; intramedullary nail; TFP nail; mechanical complications

INTRODUCTION

Proximal femoral fracture is frequent in the elderly. Incidence of 143,000 was predicted in France for 2050 [1] [2]. Almost two-thirds consist in trochanteric fracture [3] [4]. Functional impact is very severe, with significant loss of autonomy [5][6]. One-year mortality ranges between 15% and 36% [6][7].

Intramedullary nailing is widely used to fix trochanteric fracture, incurring fewer complications than Dynamic Hip Screw (DHS), especially in unstable fracture [8] [9]. The aim of nailing is to stabilize the fracture and allow early weight-bearing, to avoid confinement to bed [1] [10].

In France, the most widely used intramedullary nails are Gamma® (Howmedica – Osteonics, Rutherford, NJ, USA) and Proximal Femoral Nail Antirotation® (PFNA®, Synthes, Oberdorf, Switzerland). The main complication associated with the Gamma nail is cephalic screw cut-out, in 6-7% of cases [11] [12]. Cut-out is less frequent with PFNA, but there are risks of intra-articular protrusion [13] and excessive back-out of the cephalic blade [14] [15].

The main aim of the present single-center prospective study was to describe and assess mechanical complications with the Telegraph Femoral Proximal (TFP) nail in trochanteric fracture, and to compare results with the literature.

The secondary objective was to compare complications rates according to fracture stability.

MATERIAL & METHOD

Sample

A single-center prospective study was conducted from May 2012 to September 2014, with a minimum 6 months' follow-up. All trochanteric fractures, unless pathologic, were included; subtrochanteric and isolated greater trochanter fractures were also excluded.

Patients were seen in follow-up consultation, or else they or their family doctor was contacted (bed-ridden or deceased patients).

Fractures were classified on the AO system [16], and dichotomized as stable (A1.1, A1.2, A2.1) or unstable (A2.2, A2.3, A3): 54 unstable (46%), 64 stable (54%). Instability criteria comprised calcaneal comminution, lesser trochanter injury, absence of medial support, metaphyseal or greater trochanter comminution, and/or lateral femoral hinge fracture.

Study variables

The main endpoint was onset of mechanical complications by 6 months:

- cephalic blade cut-out,
- intra-articular protrusion,
- non-union,
- hardware-related pain.

Hardware-related pain was diagnosed by elimination of other causes: mechanical complication (cut-out, protrusion, non-union), infectious, neuropathic, scar-related.

The secondary endpoint was results in stable versus unstable fracture.

Radiologic assessment was based on preoperative, immediate postoperative and 3 and 6 months AP and lateral views, using PACS radiology software.

A single surgeon took measurements and analyzed data, to avoid inter-observer issues.

Complications were assessed with reference to Baumgaertner's Tip-Apex Distance (TAD) [17], blade centering within the femoral head, and fracture reduction. TAD is the sum of the distances between the head of the cephalic screw and the summit of the femoral head on AP and lateral views. According to Baumgaertner, TAD >25 mm is predictive of cut-out.

Blade centering within the femoral head was assessed on AP and lateral view using PACS software, gridding the femoral neck in 3 frontal and lateral areas.

Fracture reduction on immediate postoperative views was assessed in terms of diastasis and cervico-diaphyseal angle. Diastasis was counted if >5 mm. Reduction was considered good if cervico-diaphyseal angle was 130-150° on AP view and anteversion <20° on lateral view, acceptable if only 1 criterion was met and poor if neither [18].

Bone consolidation was assessed on weight-bearing view when possible (patient not bedridden) in terms of trabeculae crossing the fracture site and resolution of discontinuity. CT was performed in case of doubt.

Surgical revision was also assessed, at the usual 6 week, 3 month and 6 month follow-up.

Clinical assessment used Parker score [19], at preoperative, immediate postoperative and 3 and 6 month assessment. This clinical and functional score is based on ability to move unaided, with technical or human assistance, at home, outdoors and for shopping. A total of 9 out of 9 indicates perfect autonomy; at 0 points, the patient is confined to bed.

Infection was assessed clinically: scar aspect, fistula, effusion, local redness, persistent pain or functional impotence without mechanical or neuropathic cause, or unexplained fever. In case of negative clinical findings, biological analysis was not performed.

TFP nail

The Telegraph Femoral Proximal® (TFP) intramedullary nail (FH Orthopedics, Heimsbrunn, France) has a monobloc helical blade providing good cancellous fixation. Its main feature is to allow limited and controlled back-out up to a maximum 15 mm to optimize fracture site compression under weight-bearing (Figure 1).

Nail length is 190 mm, and diameter 17 mm in the metaphyseal region and 11 mm in the diaphyseal region for any type of fracture. Angulation is either 125° or 130°.

The proximal locking screw (Figure 2A) blocks rotation and fits into one of the grooves in the blade under weight-bearing; it controls and limits back-out to 15 mm (Figure 2B).

Distal locking can be static or dynamic. In the present study, locking was static, except for 7 nails locked dynamically.

Surgical technique

After fracture reduction by external maneuvers with the patient positioned supine on the surgery table, the skin incision was made 4 cm from the summit of the greater trochanter. After incising the fascia lata, the guide-wire and hand-auger were positioned at the summit of the greater trochanter. The nail was introduced into the shaft, and the cephalic blade was

tapped and measured and impacted in the femoral head using a hammer. The locking screw was inserted in the head of the nail and distal locking was performed after releasing traction.

Weight-bearing was systematic on the day after surgery.

Statistical analysis

Categoric variables were reported as percentages and continuous variables as mean, standard deviation, median, interquartile range and range.

The significance of mean Parker score decrease between day 0 and month 6 was assessed on 1-tailed Wilcoxon signed ranks test for matched samples. Patients with Parker score 0 at day 0 were excluded from this analysis.

The significance threshold was set at 5%.

Analyses used SAS 9.4 software (SAS Institute, Carry, NC, USA).

Ethical aspects

The study adhered to the French guidelines on clinical research in human subjects and to the 1975 Declaration of Helsinki (revised, 2000).

RESULTS

One hundred and thirty-eight patients were operated on as described above; 118 were followed up; 20 were lost to follow-up. Mean age was 83 years (range, 48-104 years). There were 88 females (75%) and 30 males (25%): sex-ratio, 3/1. At 6 months, there had been 17 deaths (14.4%) (Table 1).

Mean hospital stay was 9.4 days (range, 2-30 days). Mean surgery time was 40 minutes (range, 12-85 minutes).

There were 9 mechanical complications (7.6%; 95% CI [2.8;12.4]): 4 cut-outs (3.4%), 3 intra-articular protrusions (2.5%), 1 non-union (0.8%) and 1 case of pain (0.8%). All, except the non-union, occurred within 3 months.

Age, gender, ASA score, history, patient referral path, affected side, preoperative Parker score, hospital stay and operating time were not predictive of mechanical complications (Table 2).

After adjustment on variables differing significantly in distribution between groups (stable versus unstable fracture), there was no significant inter-group difference in mechanical complications rate ($p=0.99$).

Mean TAD was 30.7 ± 9.8 mm, with 69.5% of values > 25 mm ($n=82$). TAD >25 mm was not significantly associated with a higher complications rate ($p=0.58$) (Table 3).

Blade in superior position on AP view ($p=0.001$) or in anterior position on lateral view ($p=0.0017$) was not significantly associated with a higher complications rate.

57.6% of fractures were reduced optimally, 34.7% acceptably, and 7.6% poorly. Poor reduction was significantly associated with a higher complications rate ($p=0.02$). 33.3% of cases with mechanical complications showed poor reduction, versus only 5.5% without

(Table 3).

Mean blade back-out was 3.3mm (range, 1-10 mm), involving 22 nails (18.6%). There were no mechanical complications with back-out (0%), and 9.4% without, although the difference was not significant ($p=0.21$).

At 6 months, the fracture consolidation rate was 99%.

The surgical revision rate was 7.6%: 2 total hip replacements, due to cut-out; 4 partial hip replacements, due to 1 cut-out, 2 protrusions and 1 non-union; 2 simple nail removals, 1 for pain and 1 for protrusion; and 1 cephalic blade exchange, for protrusion.

Mean Parker score was 6.2 preoperatively, and 5.2 at 6 months, with significant decrease ($p<0.0001$).

There were no surgery-site infections. There was 1 case of urinary retention, 2 of pulmonary embolism, 3 of inhalation pneumopathy, 1 of pulmonary atelectasis, 1 of acute kidney failure, and 1 of ascitic edematous decompensation in liver failure.

DISCUSSION

The main aim of the present prospective study was to describe mechanical complications following TFP nailing. The rate of 7.6% was lower than those usually reported: 8.5-12.5% with the Gamma® nail, and 7.9-19% with PFNA [15] [17]. The present cut-out rate was 3.4%, compared to 5-19% elsewhere [1] [11] [12] [18] [20] (Table 4).

Biomechanically, the TFP nail resembles the PFNA nail, with an impacted helical blade, the main difference being the distal grooves in TFP, where the locking screw fits, allowing maximum 15 mm back-out by blocking at the end of the groove. The PFNA blade has no grooves, and back-out is thus without limit.

This limited controlled back-out avoids excessive fracture site compression, limb-length loss and severe lever arm loss, while optimizing fracture site compression under weight-bearing.

There was only 1 case of hardware-related pain (0.8%). The postoperative radiograph showed that the cephalic blade was initially too long, and that the distal end was in contact with the fascia lata.

This is one of the advantages of the TFP nail compared to other reports. There was no cephalic blade back-out causing lateral pain, whereas the PFNA nail is associated with 5-13% rates of lateral pain due to fascia lata irritation by excessive back-out [15] [21]. Lee et al. even reported back-out with complete cephalic blade expulsion following a fall in a patient who had received a PFNA nail 6 months earlier [14]. With the Gamma nail, Leung [2], Docquier [12] and Gadegone [22] reported 6-12% diffuse persistent pain (inguinal, lateral or thigh) (Table 4).

The only case of non-union in the present series was secondary to 10-mm inter-fragment diastasis associated to blade malpositioning (anterior on lateral and superior on AP view). There was no cephalic blade back-out, and hence no fracture site compression. Non-union is rare in fractures involving cancellous bone; the rate was around 1% in the present series, like in those of Nikoloski [11], Docquier [12], Simmermacher [21] and Gadegone [22]. The present series showed a significant association between poor fracture reduction and onset of mechanical complications, as confirmed elsewhere [1] [12] [21] [23].

The TFP nail is useful for trochanteric fracture fixation, as no significant difference in mechanical complications rate was found between stable and unstable fractures. The instrumentation, moreover, is easy to use. Hélin [6], using the PFNA nail, reported significantly more complications in unstable trochanteric fracture. No other studies found significant differences between stable and unstable trochanteric fractures treated by intramedullary nailing. Schipper [24] reported no difference in results for unstable trochanteric fracture between Gamma and PFNA nails.

The link between TAD and cut-out remains controversial. Baumgaertner et al. [17] reported cephalic screw cut-out in case of TAD >25 mm. Docquier [12], Geller [18] and Bruijn [13] also found that long TAD significantly increased cut-out risk with the Gamma nail. Kraus [25] and Caruso [26] showed a significant association between TAD >30 mm and mechanical complications with the PFNA nail.

The present study found no significant association between long TAD and cut-out. According to Nikoloski [11], the behavior of the cephalic blade differs from that of the screw. TAD >25 mm did not increase cut-out risk; in contrast, TAD <25 mm increased the risk of the blade being too close to the subchondral bone, and hence of protrusion. In a biomechanical cadaver study, Strauss et al. [27] found that cancellous bone subsidence and compaction around the helical blade increased implant migration resistance compared to the cephalic screw. Pu's conclusions [15] likewise differed from Baumgaertner's: the cephalic screw should be at least 10 mm away from the subchondral bone to avoid protrusion. However, Brunner et al. [28] reported 3 cases of intra-articular protrusion 6 weeks postoperatively with the PFNA nail despite all 3 fractures being well-reduced, with the blades well-positioned, more than 10 mm from the subchondral bone.

Interestingly, there were no surgical site infections in the present series whereas infection is systematic (2-10%) in the literature [5] [22] [24].

Intramedullary nailing in trochanteric fracture with rapid resumption of weight-bearing slows, without quite preventing, loss of autonomy [5] [6] [23]. The present significant deterioration in Parker score at 6 months was in line with the literature [5].

Although prospective the present study was not comparative, and the absence of a control group is its main limitation. On the other hand, loss to follow-up was average for the literature (14.5%); it is not always easy to follow up these elderly patients with severe comorbidity.

CONCLUSION

The TFP intramedullary nail proved useful for fixing trochanteric fracture, whether stable or unstable. Its helical blade and limited back-out provided a complications rate lower than found in the literature. These results need confirming in a comparative prospective study, with larger sample size and, above all, a control group. This was the first study to report results on intramedullary nailing with limited controlled blade back-out.

Disclosure of interest:

The authors have no conflicts of interest to disclose.

Funding: none

Author contributions:

M Barla: data collection, statistical analysis, article writing, re-editing

F Egrise: data collection, statistical analysis, article writing, re-editing

B Zaharia: data collection
C Bauer: data collection
J Parot: data collection
D Mainard: re-editing

References

1. Kempf I, Grosse A, Taglang G, Favreul E. Gamma nail in the treatment of closed trochanteric fractures. Results and indication of 121 cases. *Orthop Traumatol Surg Res* 2014 Feb;100(1):75-83.
2. Leung K. S., So W. S., Shen W. Y., Hui P. W. Gamma nails and dynamic hip screws for peritrochanteric fractures. A randomised prospective study in elderly patients. *J. Bone Joint Surg.*, 1992, 74-B, 345-351
3. Bejui-Hugues J. Ostéosynthèse des fractures trochantériennes. Cahiers d'enseignement de la Sofcot. Editeurs Paris : Expansion Scientifique Française ; 1994. p. 1—17.
4. M. Ehlinger, P. Adam, F. Bonnet. Fracture de l'extrémité supérieure du fémur de l'adulte. EMC - Appareil Locomoteur 2014 ;9(2):1-18.
5. Soucanye de Landevoisin E, Bertani E, Candoni P, Charpail C, Demortiere E. Proximal femoral nail antirotation (PFN-ATM) fixation of extra-capsular proximal femoral fractures in the elderly: retrospective study in 102 patients. *Orthop Traumatol Surg Res.* 2012 98,288-295.
6. Hélin M, Pelissier A, Boyer P, Delory T, Estellat C, Massin P. Does the PFNA nail limit impaction in unstable intertrochanteric femoral fracture? A 115 case-control series. *Orthop Traumatol Surg Res.* 2015 101 :45-49.
7. BY Farahmand, K Michaelsson, A Ahlbom, S Ljunghall, JA Baron. Survival after hip fracture. *Osteoporos Int* 2005 Dec;16(12):1583-90.
8. Shen L., Zhang Y., Shen Y., Cui Z. Antirotation proximal femoral nail versus dynamic hip screw for intertrochanteric fractures: a meta-analysis of randomized controlled studies. *Orthop Traumatol Surg Res.* 2013 Jun ;99(4):377-83.
9. Klinger HM, Baums MH, Eckert M, Neugebauer R. A comparative study of unstable per- and intertrochanteric femoral fractures treated with dynamic hip screw (DHS) and trochanteric buttress plate vs. proximal femoral nail (PFN). *Zentralbl Chir.* 2005 Aug;130(4):301-6.
10. Baudoin C, Fardellone P, Thelot B, Juvin R, Potard V, Bean K et al. Hip fractures in France: the magnitude and perspective of the problem. *Osteoporos Int* 1996 ; 6: 1-10.
11. Nikolski N, Osbrough AL, Yates PJ. Should the tip-apex distance (TAD) rule be modified for the proximal femoral nail antirotation (PFNA)? A retrospective study. *J Orthop Surg Res.* 2013;8: 35
12. PL. Docquier, E. Manche, JC. Autique, B. Geulette. Complications associated with Gamma Nailing. A review of 439 cases. *Acta Orthopædica Belgica*, Vol. 68 - 3 – 2002.
13. De Bruijn den Hartog D, Tuinebrejer W, Roukema G. Reliability of predictors for screw cutout in intertrochanteric hip fractures. *J Bone Joint Surg [Am]* 2012; 94:1266-72.
14. Lee SY., Niikura T., Iwakura T., Sakai Y., Kuroda R., Kurosaka M. Complete traumatic backout of the blade of proximal femoral nail antirotation: a case report. *Orthop Traumatol Surg Res.* 2014 Jun;100(4):441-3.
15. JS Pu, L Liu, GL Wang, Y Fang, TF Yang. Results of the proximal femoral nail anti-rotation (PFNA) in elderly Chinese patients. *International Orthopaedics (SICOT)* (2009) 33:1441–1444.
16. Muller ME, Nazarian S. Classification of fractures of the femur and its use in the A.O. index. *Rev Chir Orthop Reparatrice Appar Mot* 1981;67(3):297-309.
17. Baumgaertner MR, Curtin SL, Lindskog DM, Keggi JM. The value of the tip-apex distance in predicting failure of fixation of peritrochanteric fractures of the Hip. *J. Bone Joint Surg [Am]* 1995 Jul;77(7):1058-64.
18. Geller JA, Saifi C, Morrison A, Macaulay W. Tip-apex Distance of intramedullary devices as a predictor factor of cut-out failure in the treatment of peritrochanteric elderly hip fractures. *Int Orthop* 2010 34:719-722.
19. Parker MJ, Palmer CR. A new mobility score for predicting mortality after hip fracture. *J Bone Joint Surg [Br]* 1993 ;75 : 797—8.
20. A. Lobo-Escolar, E. Joven, D. Iglesias, A. Herrera. Predictive factors for cutting-out in femoral intramedullary nailing. *Injury* (2010) 41:1312-1316.
21. RK Simmermacher, J Ljungqvist J, H Bail, T Hockertz et al. The new proximal femoral nail antirotation (PFNA) in daily practice: results of a multicentre clinical study. *Injury* 2008 Aug;39(8):932-9.
22. Gadegone WM, Salphale YS. Short proximal femoral nail fixation for trochanteric fractures. *J Orthop Surg (Hong Kong)* 2010 ;18(1):39-44.
23. Waast D, Touraine D, Wessely L, Ropars M, Coipeau P, Perrier C, et al. Pertrochanteric fractures in elderly subjects aged over 75. *Rev Chir Orthop Reparatrice Appar Mot* 2007;93: 2S33—46.

24. Schipper IB, Steyerberg EW, Castelein RM, van der Heijden FHWM, den Hoed PT, Kerver AJH, van Vugt AB. Treatment of unstable trochanteric fractures. Randomised Comparison of the Gamma Nail and the Proximal Femoral Nail. *J Bone Joint Surg [Br]* 2004;86-B:86-94.
25. Kraus M, Krischak G, Wiedmann K, Riepl C, Jöckel JA, Scola A. Clinical evaluation of PFNA® and relationship between the tip-apex distance and mechanical failure. *Unfallchirurg* 2011 Jun;114(6):470-8.
26. Caruso G, Bonomo M, Valpiani G, Salvatori G, Gildone A, Lorusso V, Massari L. A six-year retrospective analysis of cut-out risk predictors in cephalomedullary nailing of pertrochanteric fractures: Can the tip-apex distance (TAD) still be considered the best parameter? *Bone Joint Res.* 2017 Aug;6(8):481-488.
27. E Strauss, J Frank, J Lee, FJ Kummer, N Tejwani. Helical blade versus sliding hip screw for treatment of unstable intertrochanteric hip fractures: A biomechanical evaluation. *Injury* 2006 Oct; 37(10):984–9.
28. Brunner A., Jöckel JA., Babst R. The PFNA proximal femur nail in treatment of unstable proximal femur fractures – 3 cases of postoperative perforation of the helical blade into the hip joint. *J Orthop Trauma.* 2008 Nov-Dec;22(10):731-6.

Tables

Table 1 – Patient data

	N	%/mean	SD	median	Q1	Q3	min	max
Age (years)	117	83.2	9.8	84.0	80.0	89.0	48.0	104.0
Age group (median)								
ND	1							
Age <= 84 years	62	53.0						
Age > 84 years	55	47.0						
Gender								
Female	88	74.6						
Male	30	25.4						
ASA class								
ND	3							
ASA 1	8	7.0						
ASA 2	50	43.5						
ASA 3/4	57	49.6						
History								
ND	2							
No	17	14.7						
Yes	99	85.3						
Cardiac/cardiovascular history								
ND	1							
No	50	42.7						
Yes	67	57.3						
History of dementia								
ND	1							
No	96	82.1						
Yes	21	17.9						
Referral from								
ND	4							
Home	76	66.7						
Old persons' home	21	18.4						
Nursing home/Institution	17	14.9						
Type of fracture								
A1-1	26	22.0						
A1-2	22	18.6						
A2-1	17	14.4						
A2-2	22	18.6						
A2-3	18	15.3						
A3	13	11.0						
Side								
Right	56	47.5						
Left	62	52.5						
Stable fracture								
No	54	45.8						
Yes	64	54.2						

Table 1 – Patient data

	N	%/mean	SD	median	Q1	Q3	min	max
Parker score, D0	118	6.2	2.7	7.0	4.0	9.0	0.0	9.0
Parker score, M6	88	5.2	2.7	6.0	3.0	7.0	0.0	9.0
Deceased at 6 months								
No	101	85.6						
Yes	17	14.4						
Hospital stay (days)	87	9.4	5.2	8.0	6.0	11.0	2.0	30.0
Operating time (min)	64	39.8	15.4	40.0	30.0	50.0	12.0	85.0

SD: standard deviation; ND: no data

Table 2 – Patient data according to complications

	Total N= 118			No complications N=109 (92.4%)			Complications N=9 (7.6%)			p**
	N	%/mean	SD	N	%/mean	SD	N	%/mean	SD	
Age (years)	117	83.2	9.8	108	83.3	9.9	9	81.6	7.7	0.2643
Gender										0.1093
Female	88	74.6		79	72.5		9	100.0		
Male	30	25.4		30	27.5		0	0.0		
ASA	115	2.5	0.7	107	2.5	0.7	8	2.3	0.7	0.3920
History										0.1256
No	17	14.7		14	13.1		3	33.3		
Yes	99	85.3		93	86.9		6	66.7		
Cardiac/cardiovascular history										0.4939
No	50	42.7		45	41.7		5	55.6		
Yes	67	57.3		63	58.3		4	44.4		
History of dementia										1.0000
No	96	82.1		88	81.5		8	88.9		
Yes	21	17.9		20	18.5		1	11.1		
Referral from										1.0000
Home	76	66.7		69	65.7		7	77.8		
Old persons' home	21	18.4		20	19.0		1	11.1		
Nursing home/Institution	17	14.9		16	15.2		1	11.1		
Type de fracture										0.6082
A1-1	26	22.0		25	22.9		1	11.1		
A1-2	22	18.6		21	19.3		1	11.1		
A2-1	17	14.4		14	12.8		3	33.3		
A2-2	22	18.6		21	19.3		1	11.1		
A2-3	18	15.3		16	14.7		2	22.2		
A3	13	11.0		12	11.0		1	11.1		
Side										0.7342
Right	56	47.5		51	46.8		5	55.6		
Left	62	52.5		58	53.2		4	44.4		
Stable fracture										1.0000
No	54	45.8		50	45.9		4	44.4		
Yes	64	54.2		59	54.1		5	55.6		
Parker score, D0	112	6.2	2.7	103	6.1	2.7	9	7.0	2.5	0.3456
Hospital stay (days)	87	9.4	5.2	82	9.4	5.0	5	10.6	8.7	0.6392
Operating time (min)	64	39.8	15.4	60	39.6	15.6	4	42.5	12.6	0.7212

SD: standard deviation

** Fisher exact test for qualitative variables, Student or Wilcoxon test for quantitative variables

Table 3 – Mechanical complications according to radiographic criteria

	Total N= 118			No complications N=109 (92.4%)			Complications N=9 (7.6%)			p**
	N	%/mean	SD	N	%/mean	SD	N	%/mean	SD	
Blade, AP										0.0014
Centered	54	45.8		52	47.7		2	22.2		
Inferior	56	47.5		53	48.6		3	33.3		
Superior	8	6.8		4	3.7		4	44.4		
Blade, AP (dichotomized)										0.0010
Superior	8	6.8		4	3.7		4	44.4		
Centered/Inferior	110	93.2		105	96.3		5	55.6		
Blade, lateral										0.0016
Centered	44	37.3		43	39.4		1	11.1		
Posterior	65	55.1		61	56.0		4	44.4		
Anterior	9	7.6		5	4.6		4	44.4		
Blade, lateral (dichotomized)										0.0017
Posterior/Centered	109	92.4		104	95.4		5	55.6		
Anterior	9	7.6		5	4.6		4	44.4		
TIP-APEX DISTANCE	118	30.7	9.8	109	30.5	9.6	9	33.1	11.7	0.2669
TAD (dichotomized)										0.7204
<=25 mm	36	30.5		34	31.2		2	22.2		
>25 mm	82	69.5		75	68.8		7	77.8		
Anteversión	118	19.1	6.4	109	18.7	6.1	9	23.2	9.0	0.1627
Diastasis (mm)	118	1.8	2.7	109	1.6	2.5	9	4.1	3.5	0.0542
AP (varus - valgus)	118	132.1	8.3	109	132.2	8.0	9	130.1	12.1	0.4750
Reduction										0.0396
Good	68	57.6		64	58.7		4	44.4		
Acceptable	41	34.7		39	35.8		2	22.2		
Poor	9	7.6		6	5.5		3	33.3		
Reduction (dichotomized)										0.0208
Good/Acceptable	109	92.4		103	94.5		6	66.7		
Poor	9	7.6		6	5.5		3	33.3		

SD: standard deviation

** Fisher exact test for qualitative variables, Student or Wilcoxon test for quantitative variables

Table 4: Complications rates in the literature

	Nail	Mechanical complications	Cut-out	Intra-articular protrusion	Pain	Non-union	Surgical revision
Present study	TFP	7.6%	3.4%	2.5%	0.8%	0.8%	7.6%
Kempf	Gamma	-	4.9%	-	-	-	-
Docquier	Gamma	19.2%	7.1%	-	6.2%	0.9%	11.5%
Gadegone	Gamma	14.6%	6%	2%	7%	1%	8.9%
Simmermacher	PFNA	14.6%	-	1.3%	0.63%	0.63%	8.9%
Nikoloski	PFNA	19%	6.2%	-	-	1.1%	-
Pu	PFNA		0%		12.6%		

Legends of Figures

Figure 1: TFP nail

Figure 2A: Proximal locking screw

Figure 2B: Cephalic blade longitudinal grooves

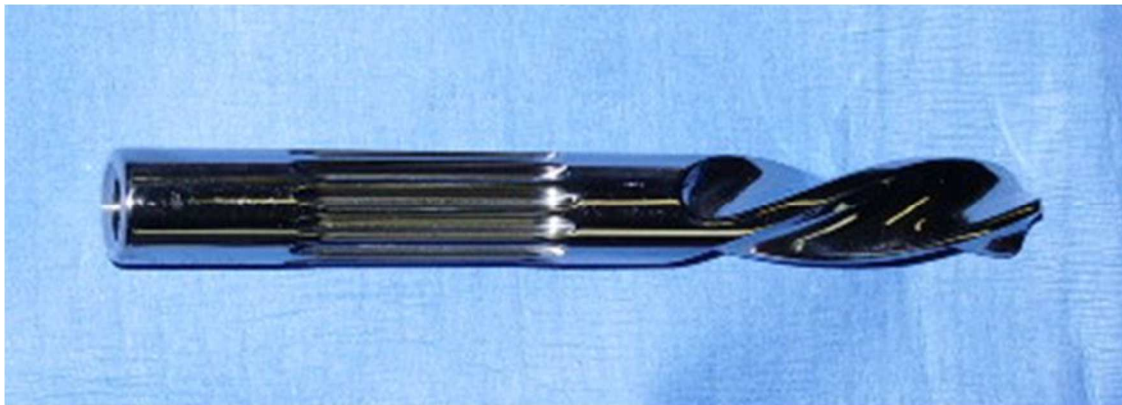
Figure 1: TFP nail

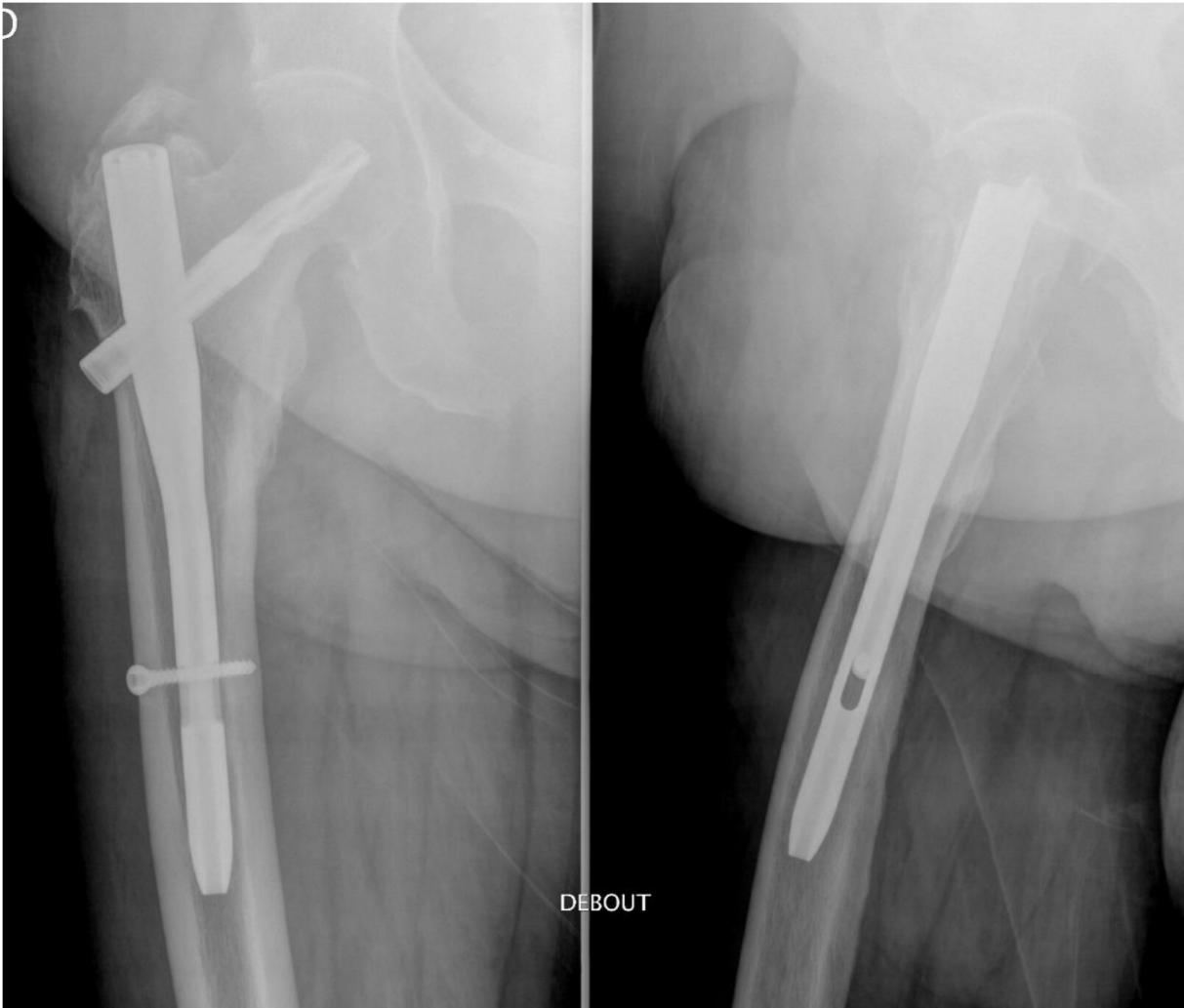

Figure 2



2A: Proximal locking screw



2B: Cephalic blade longitudinal grooves