



HAL
open science

Fusion imaging with a mobile C-arm for peripheral arterial disease

Alexandre Villena, Florent Lalys, Blandine Saudreau, Remy Pascot, Alexandre Barré, Antoine Lucas, Adrien Kaladji

► **To cite this version:**

Alexandre Villena, Florent Lalys, Blandine Saudreau, Remy Pascot, Alexandre Barré, et al.. Fusion imaging with a mobile C-arm for peripheral arterial disease. *Annals of Vascular Surgery*, 2021, 71, pp.273-279. <10.1016/j.avsg.2020.07.059>. <hal-02958977>

HAL Id: hal-02958977

<https://hal.science/hal-02958977v1>

Submitted on 9 Mar 2023

HAL is a multi-disciplinary open access archive for the deposit and dissemination of scientific research documents, whether they are published or not. The documents may come from teaching and research institutions in France or abroad, or from public or private research centers.

L'archive ouverte pluridisciplinaire **HAL**, est destinée au dépôt et à la diffusion de documents scientifiques de niveau recherche, publiés ou non, émanant des établissements d'enseignement et de recherche français ou étrangers, des laboratoires publics ou privés.



Distributed under a Creative Commons CC BY-NC 4.0 - Attribution - Non-commercial use - International License

Fusion imaging with a mobile C-arm for peripheral arterial disease

Alexandre Villena,¹ Florent Lalys,² Blandine Saudreau,¹ Rémy Pascot,¹ Alexandre Barré,¹ Antoine Lucas,^{1,3,4} Adrien Kaladji,^{1,3,4}

¹ Center of cardiothoracic and vascular surgery, Rennes University Hospital, F-35033, Rennes, France

² Therenva, F-35000, Rennes, France

³ INSERM, U1099, F-35000 Rennes, France

⁴ Signal and Image Processing Laboratory (LTSI), University of Rennes 1 F-35000 Rennes, France

Correspondence: Adrien Kaladji, Center of cardiothoracic and vascular surgery, Rennes University Hospital, F-35033 Rennes, France; E-mail: adrien.kaladji@chu-rennes.fr

ABSTRACT

Objectives: Fusion imaging makes it possible to improve endovascular procedures and is mainly used in hybrid rooms for aortic procedures. The objective of this study was to evaluate the feasibility of fusion imaging for femoro-popliteal endovascular procedures with a mobile flat plane sensor and dedicated software to assist endovascular navigation.

Material and methods: Between May and December 2017, 41 patients requiring femoro-popliteal endovascular revascularization were included. Interventions were carried out in a conventional surgical room equipped with a mobile plane sensor (Cios Alpha, Siemens). The numerical video stream was transmitted to an angionavigation station (EndoNaut (EN), Therenva). The software created an osseous and arterial panorama of the treated limb from the angiographies carried out at the beginning of procedure. After each displacement of the table, the software relocated the current image on the osseous panorama, with 2D-2D resetting, and amalgamated the mask of the arterial panorama. The success rates of creation of osseous and arterial panorama and the success of relocation were evaluated. The data concerning irradiation, the volume of contrast injected, and operative times were recorded.

Results: Osseous panoramas could be automatically generated for the 41 procedures, without manual adjustment in 33 cases (80.5%). 35 relocations based on a 2D-2D resetting could be obtained in the 41 procedures, with a success rate of 85%. The causes of failure were a change in table height or arch angulation. The average duration of intervention was 74.5 min. The irradiation parameters were: duration of fluoroscopy 17.8 ± 13.1 min, K_a 80.5 ± 68.4 mGy, DAP 2140 ± 1599 μ Gy.m². The average volume of contrast (VC) was 24.5 ± 14 mL.

Conclusions: This preliminary study showed that fusion imaging is possible in a non-hybrid room for peripheral procedures. Imagery of mobile C-arms can be improved for femoro-popliteal endovascular procedures without heavy equipment. These imagery tools bring an operative comfort and could probably reduce irradiation and the injected volume of contrast. The clinical benefit must be evaluated in more patients in a randomized comparative study with a rigorous methodology.

INTRODUCTION

Endovascular revascularization became the treatment of first intention for femoro-popliteal occlusive lesions.^{1,2} These endovascular procedures evolved considerably these last years due to the development of endovascular devices and the advances in operative imaging. New technologies appeared a few years ago to secure and improve endovascular procedures. It is the case of image fusion which is more and more used and integrated in the model of computer-assisted medico-surgical procedures (CAMSP), to bring useful information to the surgeons.³ Fusion imaging is defined as the mapping of images resulting from different techniques (MRI, CT, angiography...), with different dimensionalities (3D, 2D) and different temporalities, with a process of image computation. This process used in aortic endovascular surgery allows a permanent view of the vascular structures obtained from a preoperative angio-CT on the fluoroscopic image during the operative procedure via a 3D-2D resetting on the osseous reference marks. The vascular structures are thus visualized in real time without angiography. This technology of image fusion makes it possible to optimize and secure endovascular procedures by avoiding repeated injections of iodized contrast. Many studies reported the use of fusion imaging and showed the advantages of this technique for the patients and the operators in endovascular aortic procedures⁴⁻⁶ to reduce irradiation according to ALARA principles,⁷ and the injection of nephrotoxic products of contrast.^{8,9} At the present time, this benefit was described for aortic procedures. Preliminary studies on fusion imaging for lower extremities revascularization was reported in several studies for iliac lesions.¹⁰⁻¹² At the moment, fusion imaging is not used routinely for the treatment of femoro-popliteal lesions. Moreover, this technology was described only in hybrid rooms equipped with fixed plane sensors. However softwares were developed to optimize mobile plane sensors and to bring this technology of fusion imaging in non-hybrid rooms. This was the case of the EndoNaut Therenva® software of angionavigation assistance, for which theoretical operation, algorithms and scientific design were described by Lalys and al.¹³ The objective of this study was to evaluate the feasibility of fusion imaging for femoro-popliteal endovascular procedures using a mobile plane sensor and this software.

MATERIAL AND METHODS

Description of the study, criteria of inclusion and exclusion

Description of the study. This was a pilot, prospective and monocentric feasibility study. The aim to evaluate the capacity of the EndoNaut® (Therenva, Rennes, France) software of endovascular navigation assistance to carry out image fusion with a mobile plane sensor in femoro-popliteal endovascular procedures. This non-interventional study was approved by the ethics committee of the Rennes University Hospital and was declared to the National Commission for Data Protection and Liberties (CNIL). The protocol was recorded on the ClinicalTrials database under the number: NCT03669978 after agreement of the local ethics committee and the CNIL.

Criteria of inclusion. All the patients presenting a de novo femoro-popliteal lesion and candidates to an endovascular revascularization with angioplasty and stenting were included, at any clinical stage. The topography of the femoro-popliteal lesions was objectified by echo-Doppler or a preoperative angio-CT. The procedure was performed in a conventional OR,

equipped with a Cios-alpha mobile plane sensor (30x30 cm) (Siemens®, Munich, Germany) and the EndoNaut® angio-navigation assistance software (Therenva®, Rennes, France). The patients were included after oral and written information on the protocol and if they had not expressed opposition to take part in the study. The operator had been trained to use the software, and an engineer of the company was present in the surgical unit during the first procedures in order to guide the clinician on the use of the software.

Criteria of non-inclusion. The patients requiring another endovascular or surgical revascularization procedure in another location (iliac or limb) as well as the patients operated with an imaging system differing from the Cios α mobile plane sensor or presenting an intrastent or anastomotic restenosis were not included.

Criteria of exclusion. The patients with missing irradiation data or volume of contrast were excluded from the study as well as the patients in which another technique than angioplasty with stenting was necessary at the time of intervention to treat the femoro-popliteal lesion.

Surgical procedure and software operation

Patient's positioning. The patient was placed in a supine position on a radiolucent table. Most of the interventions were carried out under local anesthesia with sedation. The Cios-α mobile plane sensor was positioned in front of the operator and the EndoNaut station was positioned between the C-arm and the screens. This mobile station consists of a screen and a touch pad constituting the operator-software interface. It is connected to the C-arm by a numerical cable allowing to transmit in real time the numerical video stream recorded by the C-arm. The choice of an antegrade or crossover approach was left to the operator, depending on the lesions described by ultrasound or the preoperative angio-CT and his preference. When the recanalization was not possible due to a failure of reentry, the safari technique could be used.

Creation of the fluoroscopic panorama. The objective was to create a fluoroscopic osseous panorama in order to obtain a continuous fluoroscopic image of the femur and the leg bones. The method used by this software relies on the scientific principle of the overlap or assembly of images defined as “image stitching”. The principle combines multiple images to put them in continuity. The images are pasted successively with a common overlap. With this software, the originality was to create an osseous panorama of the femur and the bones of the leg by using the minimum of images i.e. by minimizing the overlap. The objective of the designers of EndoNaut was to record the 2D fluoroscopic images while limiting the overlapping and to find the best correspondence between two adjacent images. The minimal ratio of overlap between two images had been calculated and was 20%. The assembly of the images rested on an algorithm of iconic 2D-2D image matching searching for an optimal geometrical transformation between two adjacent images.¹⁴ Algorithms used as well as the mathematical and physical principles were described in the original article of Lalys et al. reporting the software operation.¹³

In practice, the operator obtained a first image centered on the femoral head, a second on the femoral diaphysis with a minimal overlap of 20% between the two images. Then, the software applied the algorithms in order to merge these two images, which allowed building a two levels osseous panorama. A third level was added with a 20% overlap, and a three level panorama was then obtained. The same procedure was applied to the following levels. Three or four levels were generally created in order to obtain an osseous panorama including the

femur, the knee joint, and the proximal part of the two bones of the leg. It was necessary to keep the same incidence of the C-arm, the same table height, the same radiological zoom level, and the same position of the limb of the patient to create the panorama. These data were kept throughout the procedure in order to avoid errors of relocation.

Creation of the angiographic panorama. During this diagnostic phase, the arterial panorama was created along with the osseous panorama. With each fluoroscopic image obtained to create the osseous panorama, an angiography was carried out by subtraction and injection of product of contrast. An angiographic image was obtained for each fluoroscopic view. There was therefore a spatial correspondence between the osseous image and the arterial image. By using the same image stitching algorithm, a complete angiographic panorama of the femoro-popliteal arterial tree was then obtained. This complete arterial roadmapping was kept in memory by the software and could thus be used during all the intervention. The real image obtained at one time during the injection of product of contrast became a virtual image when it was used a moment later. This applies the principle of increased reality where a virtual image is superimposed on a real image.

Synchronization of the current image on the panorama. During the interventional phase, the surgeon treated the lesions one after another, in general from the most distal to the most proximal, under fluoroscopic control. The current fluoroscopic image was then relocated on the fluoroscopic panorama recorded during the diagnostic phase. This relocation or synchronization was carried out with the model of mapping of the osseous images. It was thus also about 2D-2D matching putting in correspondence the osseous panorama created at the time of the diagnostic phase and the current osseous image at the time of intervention. Because of the difference in size between these two images, the process of relocation of a small image in a large one called “template matching”, used the same methods of matching as during the creation of the panorama. Once osseous matching was carried out, the arterial panorama was automatically visualized by spatial correspondence between the two panoramas.

Thus the initial arteriography was permanently posted on the current image by superposition or image fusion. Fig. 1 illustrates the various stages of software operation. A manual matching is sometimes necessary and implies a direct adjustment with the Endonaut touch pad. Buttons for translations and rotation in the plane are proposed to the user. These adjustments are necessary when matching is not visually ideal, which can occur when collimators make sound effects for the image slightly, or when the two images to be matched do not present enough similar osseous elements (insufficient overlap).

Primary and secondary outcomes

Primary outcome. The aim of this study was to evaluate the feasibility of image fusion with a mobile plane sensor for endovascular femoro-popliteal revascularization using this software. The principal criterion of judgment was the technical success of the creation of osseous fluoroscopic and angiographic panoramas. This technical success was expressed in numbers and percentage. These data were recorded by the operator during the procedure.

Secondary outcomes. The main secondary outcome was the evaluation of the capacity of the software to reproject the arterial panorama created initially after each displacement of the table, since in a conventional operating room the table and the C-arm are not linked with a data-processing system as in a hybrid room. This objective was evaluated by the technical success of relocation, expressed in numbers and percentage. Other secondary outcomes were the efficiency of the software evaluated by quantifiable parameters such as the use of fluoroscopy and the volume of contrast product injected during the procedure. The following secondary criteria of judgment were analyzed: BMI (kg/m^2), air Kerma (K_a , mGy), the Dose Area Product (DAP, $\mu\text{Gy}\cdot\text{m}^2$), the time of fluoroscopy (min), the duration of the procedure (min), and the volume of iodized contrast product injected (mL).

Statistical analysis

All the data were entered in a database as Excel[®] spreadsheet (Microsoft, Redmond, USA). Qualitative variables were expressed as percentages and quantitative variables were expressed as average and standard deviation.

RESULTS

Patients et intervention

Between May and December 2017, 41 patients (23 men, 56.1%) were included in this study. The average age of the patients was 74.5 ± 11.2 years. Their average body mass index was 25.1 ± 4.6 kg/m^2 . During this period, 51 procedures were carried out with the EndoNaut software, and ten were excluded from the study. Six of these procedures had been performed with an OEC image intensifier (GE[®]), and one procedure was excluded because tibial lesions had been treated. Three procedures were also excluded because the data regarding irradiation and/or the volume of contrast product were missing. All the patients included were operated with the same technique including a pre-dilatation followed by the implantation of a self-expandable stent and remodeling with another balloon angioplasty.

Primary outcome

The software was efficient in the 41 procedures, with the creation of a fluoroscopic osseous panorama in 100% of the cases. Thirty-three (80.5%) of these 41 osseous panoramas did not require a manual readjustment by the operator. In the 41 procedures, all the arterial angiographic panoramas were created, including 36 (87.8%) without manual readjustment.

Secondary outcomes

Among these 41 procedures, 35 (85%) procedures of relocation were successful, including 31 (75%) which did not require a manual readjustment. Among the six failures of relocation, two were due to an insufficient overlap, one to a change in the orientation of the C-arm, one to the installation of a reducing shutter which masked osseous information, and one to the modification of the table height. In one procedure, the cause of the failure was the movements of the patient during the intervention after the creation of the panoramas.

The demographic and anatomical characteristics of the lesions are presented in Table I. The average duration of intervention was 74.5 min. The parameters concerning the irradiation were as follow: duration of fluoroscopy 17.8 ± 13.1 min, K_a 80.5 ± 68.4 mGy, DAS 2140 ± 1599 $\mu\text{Gy}\cdot\text{m}^2$. The average volume of contrast product (CP) was 24.5 ± 14 mL.

Considering simple lesions as TASC A and B lesions and complex lesions as TASC C and D, these parameters were as follow: for simple lesions: duration of fluoroscopy 15.5 ± 9.6 min, K_a 79.7 ± 60.8 mGy, DAS 2205 ± 1542 $\mu\text{Gy}\cdot\text{m}^2$, PC 22 ± 11 mL, and for complex lesions: duration of fluoroscopy 20.2 ± 9.6 min, K_a 81.3 ± 77.2 mGy, DAS 2231 ± 1691 $\mu\text{Gy}\cdot\text{m}^2$, CP 29 ± 16 mL.

DISCUSSION

This study reports the first use for endovascular procedures of peripheral revascularization in a non-hybrid room of software designed to assist angionavigation, based on a technique of fusion imaging and peroperative matching of images with a mobile plane sensor. This software, based on the creation of panoramas (fluoroscopic and angiographic) and of relocation and fusion imaging, was evaluated in this clinical study. In our study, the software was able to create fluoroscopic and angiographic panoramas automatically during each procedure without manual readjustment in 80.5% and 87.8% of the cases, respectively. The process of relocation also based on 2D-2D matching functioned in 85% of the procedures. The use of fusion imaging is thus possible in a conventional operating room with a mobile plane sensor and this software.

Many studies reported the advantages of fusion imaging for the surgeon and the patient in terms of reduction of operative time, irradiation and injected contrast product,⁷⁻⁹ but they were all carried out in hybrid rooms and for aortic procedures. More recently, Sailer et al. reported a feasibility study of imaging fusion in peripheral revascularization.¹⁵ This study showed that fusion was realizable with a fixed planed sensor for peripheral revascularization, however only six patients presented femoro-popliteal lesions.

The EndoNaut® software of angionavigation brings two innovations. Firstly, it allows the use of fusion imaging in a conventional room with a mobile plane sensor. The method used by this software relies on the scientific principle of “image stitching”. The principle was to assemble various images to put them in continuity. The images are stuck together with a common overlap. Secondly, it allows fusion imaging with a 2D-2D matching, without the need for a preoperative imaging which is not systematically necessary before femoro-popliteal revascularization. For the patients presenting critical ischemia with infra-inguinal lesions, the realization of a morphological examination is not always necessary because a complete arteriography of the lower extremity in intention to treat is carried out at the beginning of procedure. These morphological examinations are not always easily feasible and are a radiation source for the patient, aside from the economic costs for our health system.

Few data were published about the irradiation due to the peripheral endovascular procedures,. Segal et al.¹⁶ showed that the irradiation was higher during aortoiliac procedures than during the treatment of femoro-popliteal or below the knee lesions. In this study the average DSA was 179.6 $\text{Gy}\cdot\text{cm}^2$ for aorto-iliac lesions and 63.2 $\text{Gy}\cdot\text{cm}^2$ for femoro-popliteal lesions ($p < 0.001$). A similar study conducted by Sigterman et al.¹⁷ showed similar results with an average DAS of 142 $\text{Gy}\cdot\text{cm}^2$ vs. 58 $\text{Gy}\cdot\text{cm}^2$ ($p < 0.001$) in aortoiliac and femoro-popliteal procedures. These data show that the expected benefit of fusion imaging in terms of reduction in irradiation is low since the irradiation is much lower during femoro-popliteal procedures than during iliac and aortic procedures. Moreover these two studies were carried out with a fixed planed sensor. It was recently shown that irradiation was higher with the use

of a fixed planed sensor than with a mobile plane sensor for endovascular peripheral revascularizations.¹⁸ These results were also reported in a meta-analysis by Ruiters et al. on simple aortic procedures.⁵ A comparison of the parameters of irradiation between two randomized groups could then be considered with and without Endonaut. However the reported values of DAP and Kerma of air in the studies mentioned above remain far short of alert thresholds, and the problem of irradiation is undoubtedly less an issue than for the implantation of fenestrated stentgrafts. With regard to the use of iodized contrast, a track is envisaged to improve the software, which would consist in the use of dynamic acquisitions (fluoroscopy bolus) rather than successive acquisitions, to further decrease the quantity of contrast used during the diagnostic phase.

In this study we did not report quantitative criteria of accuracy for fusion and 2D-2D matching. There were procedures in which a manual adjustment was needed during the creation of the osseous and arterial panoramas and at the time of relocation. These readjustments were not quantified. However in the initial evaluation of the software, the accuracy of osseous panoramas was evaluated at 1.24 mm and that of the relocation at 2.6 mm. These error margins are low and negligible in femoro-popliteal procedures, in which millimeter accuracy is not required, except at the ostium of the superficial femoral artery. One limitation of the software is that it does not allow various angulations of the C-arm during the creation of the panorama. These constraints imposed to create the panoramas and for relocation (incidence of the C-arm, identical table height) are inherent in the 2D fusion suggested by the software. Without additional 3D information, which would complicate the use of the software, these constraints should be respected. Except in the femoral tripod, most of the femoro-popliteal procedures can be realized with the same incidence.

Another limitation of this study was the absence of comparison with a control group. However the aim of the study was to show the feasibility of creation of an arterial panorama with a mobile C-arm. It was also carried out in a university hospital, i.e. in a center where surgeons have different levels of experience and train the residents. The parameters of irradiation and contrast are thus more difficult to compare than in series reporting a single experience. Despite this disparity, the study showed the successful use of the software even without experience of the modern endovascular navigation tools.

CONCLUSION

Femoro-popliteal fusion imaging is feasible outside of a hybrid room with a mobile planed sensor and EndoNaut software. This preliminary study showed that it is possible to optimize the imagery of mobile C-arms for endovascular femoro-popliteal procedures without heavy equipment. These imagery tools bring an obvious but non quantifiable comfort to the operators in terms of visualization of the arterial image, of quality of the image, and use of tools for image processing. The clinical benefit must be evaluated in a comparative study with a larger number of patients.

REFERENCES

1. Norgren L, Hiatt WR, Dormandy JA, Nehler MR, Harris KA, Fowkes FGR, et al. Inter-society consensus for the management of peripheral arterial disease. *Int Angiol J Int Union Angiol.* 2007;26:81–157.

2. The TASC Steering Committee, Jaff MR, White CJ, Hiatt WR, Fowkes GR, Dormandy J, et al. An Update on Methods for Revascularization and Expansion of the TASC Lesion Classification to Include Below-the-Knee Arteries: A Supplement to the Inter-Society Consensus for the Management of Peripheral Arterial Disease (TASC II). *J Endovasc Ther.* 2015;22:663–77.
3. Kaladji A, Lucas A, Cardon A, Haigron P. Computer-aided surgery: concepts and applications in vascular surgery. *Perspect Vasc Surg Endovasc Ther.* 2012;24:23–7.
4. Hertault A, Maurel B, Sobocinski J, Martin Gonzalez T, Le Roux M, Azzaoui R, et al. Impact of hybrid rooms with image fusion on radiation exposure during endovascular aortic repair. *Eur J Vasc Endovasc Surg.* 2014;48:382–90.
5. de Ruyter QMB, Reitsma JB, Moll FL, van Herwaarden JA. Meta-analysis of Cumulative Radiation Duration and Dose During EVAR Using Mobile, Fixed, or Fixed/3D Fusion C-Arms. *J Endovasc Ther.* 2016;23:944–56.
6. Tacher V, Lin M, Desgranges P, Deux J-F, Grünhagen T, Becquemin J-P, et al. Image guidance for endovascular repair of complex aortic aneurysms: comparison of two-dimensional and three-dimensional angiography and image fusion. *J Vasc Interv Radiol.* 2013;24:1698–706.
7. Hertault A, Maurel B, Midulla M, Bordier C, Desponds L, Saeed Kilani M, et al. Editor's Choice - Minimizing Radiation Exposure During Endovascular Procedures: Basic Knowledge, Literature Review, and Reporting Standards. *Eur J Vasc Endovasc Surg.* 2015;50:21–36.
8. Garcia S, Ko B, Adabag S. Contrast-induced nephropathy and risk of acute kidney injury and mortality after cardiac operations. *Ann Thorac Surg.* 2012;94:772–6.
9. Lüders F, Malyar N, Meyborg M, Gebauer K, Brand E, Reinecke H. Impact of peripheral arterial occlusive disease on the development of contrast medium-induced acute kidney injury. *Nephron Clin Pract.* 2012;122:38–43.
10. Goudekettering SR, Heinen SGH, de Haan MW, Sailer AM, van den Heuvel DAF, van Strijen MJ, et al. Fluoroscopy with MRA fusion image guidance in endovascular iliac artery interventions: study protocol for a randomized controlled trial (3DMR-Iliac-roadmapping study). *Trials.* 2018;19:603.
11. Goudekettering SR, Heinen SG, van den Heuvel DA, van Strijen MJ, de Haan MW, Slump CH, et al. The use of 3D image fusion for percutaneous transluminal angioplasty and stenting of iliac artery obstructions: validation of the technique and systematic review of literature. *J Cardiovasc Surg (Torino).* 2018;59:26–36.
12. Haga M, Shimizu T, Nishiyama A, Shindo S. Three cases of fusion imaging in endovascular treatment of occlusive peripheral artery disease. *J Vasc Surg Cases Innov Tech.* 2019;5:427–30.
13. Lalys F, Favre K, Villena A, Durrmann V, Colleaux M, Lucas A, et al. A hybrid image fusion system for endovascular interventions of peripheral artery disease. *Int J Comput Assist Radiol Surg.* 2018 Mar 16;
14. Kumar A, SekharBandaru R, Rao B, Kulkarni S, Ghatpande N (2012) Automatic image alignment and stitching of medical images with seam blending. Presented at the World Academy of Science, Engineering and Technology Google Scholar.
15. Sailer AM, de Haan MW, de Graaf R, van Zwam WH, Schurink GWH, Nelemans PJ,

et al. Fusion guidance in endovascular peripheral artery interventions: a feasibility study. *Cardiovasc Intervent Radiol*. 2015;38:314–21.

16. Segal E, Weinberg I, Leichter I, Klimov A, Giri J, Bloom AI. Patient radiation exposure during percutaneous endovascular revascularization of the lower extremity. *J Vasc Surg*. 2013;58:1556–62.

17. Sigterman TA, Bolt LJJ, Snoeijs MG, Krasznai AG, Heijboer R, Schurink G-WH, et al. Radiation Exposure during Percutaneous Transluminal Angioplasty for Symptomatic Peripheral Arterial Disease. *Ann Vasc Surg*. 2016;33:167–72.

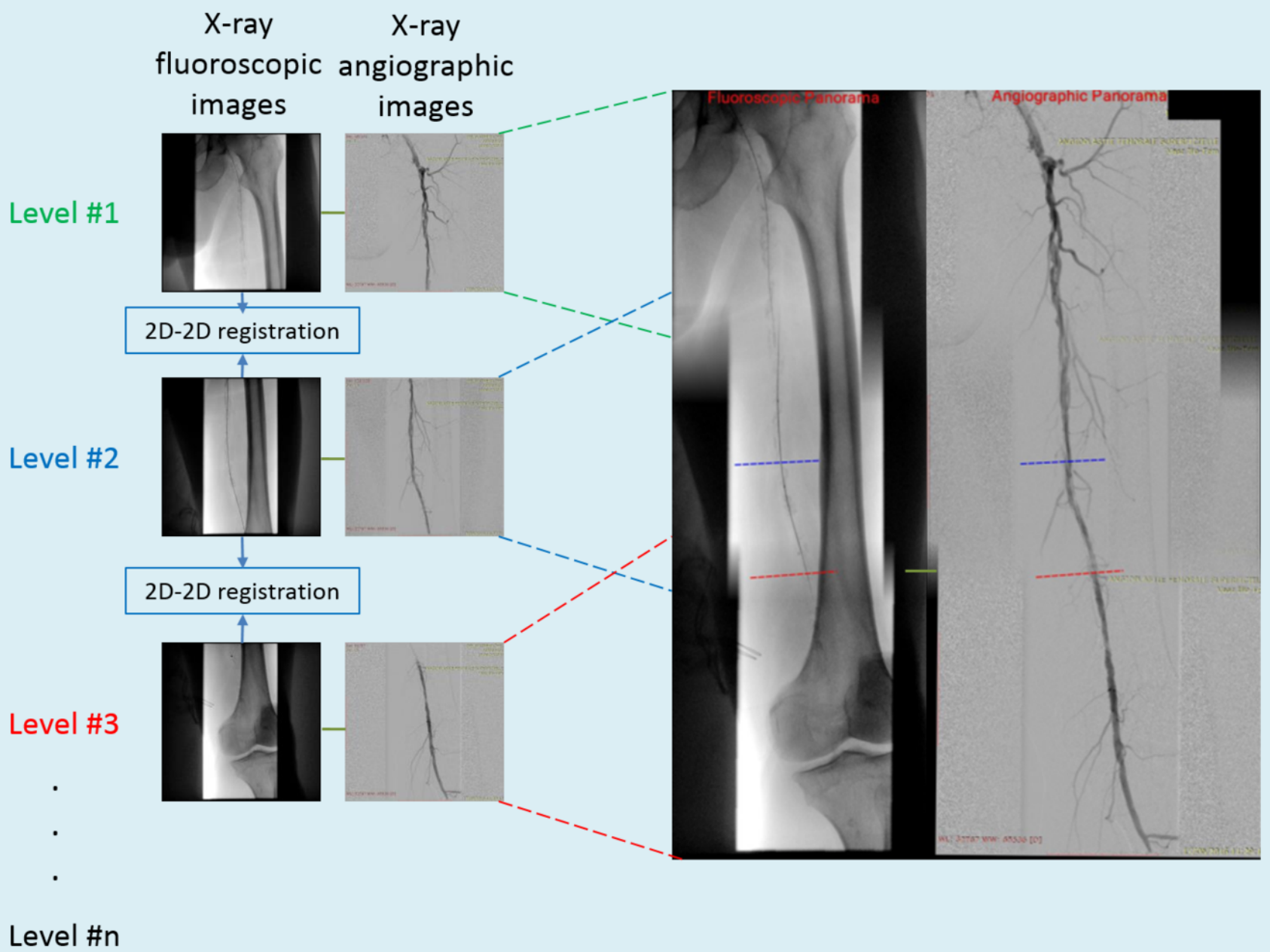
18. Guillou M, Maurel B, Necib H, Vent P-A, Costargent A, Chaillou P, et al. Comparison of Radiation Exposure during Endovascular Treatment of Peripheral Arterial Disease with Flat-Panel Detectors on Mobile C-arm versus Fixed Systems. *Ann Vasc Surg*. 2018;47:104–13.

LEGEND OF FIGURE

Fig. 1. EndoNaut® software operation.

Diagnostic phase

Creation of the fluoroscopic and angiographic panorama



Interventional phase

Relocalization + fusion based on 2D information

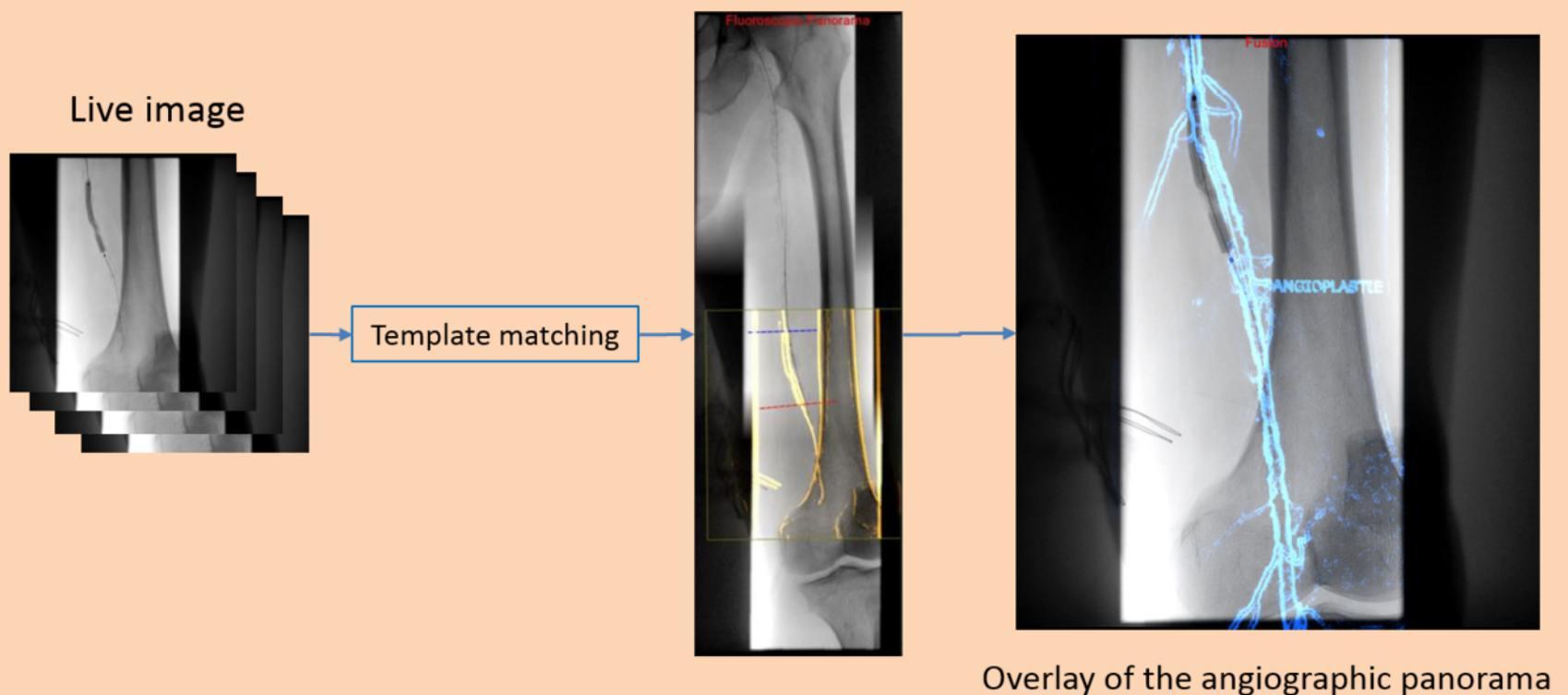


Table I. Clinical and anatomical characteristics

Age (years; average \pm SD)	74.5 \pm 11.2
BMI (kg/m²)	25.1 \pm 4.6
Approach	
Antegrade	12 (29.3%)
Crossover	28 (68.3%)
Safari	1 (2.4%)
Lesions	
Stenoses	17 (41.5%)
Occlusions	20 (35.7%)
TASC	
A	13 (31.7%)
B	8 (19.5%)
C	4 (9.8%)
D	16 (39.1%)
