



**HAL**  
open science

## **Prevention of retrograde ascending aortic dissection by cardiac pacing during hybrid surgery for zone 0 aortic arch repair**

Lucien Chassin-Trubert, Baris Ata Ozdemir, Arnaud Roussel, Grégory Dessertenne, Yves Castier, Ludovic Canaud, Pierre Alric

### **► To cite this version:**

Lucien Chassin-Trubert, Baris Ata Ozdemir, Arnaud Roussel, Grégory Dessertenne, Yves Castier, et al.. Prevention of retrograde ascending aortic dissection by cardiac pacing during hybrid surgery for zone 0 aortic arch repair. *Annals of Vascular Surgery*, 2021, 71, pp.48-55. <10.1016/j.avsg.2020.08.136>. <hal-02941064>

**HAL Id: hal-02941064**

**<https://hal.science/hal-02941064v1>**

Submitted on 19 Aug 2021

**HAL** is a multi-disciplinary open access archive for the deposit and dissemination of scientific research documents, whether they are published or not. The documents may come from teaching and research institutions in France or abroad, or from public or private research centers.

L'archive ouverte pluridisciplinaire **HAL**, est destinée au dépôt et à la diffusion de documents scientifiques de niveau recherche, publiés ou non, émanant des établissements d'enseignement et de recherche français ou étrangers, des laboratoires publics ou privés.



HAL Authorization

# Prevention of Retrograde Ascending Aortic Dissection by Cardiac Pacing During Hybrid Surgery for Zone 0 Aortic Arch Repair

Lucien Chassin-Trubert,<sup>1,2</sup> Baris Ata Ozdemir,<sup>1</sup> Arnaud Roussel,<sup>3</sup> Grégory Dessertenne,<sup>4</sup> Yves Castier,<sup>3</sup> Canaud Ludovic,<sup>1</sup> and Pierre Alric,<sup>1</sup> Montpellier, Paris, and Angers, France and Santiago, Chile

**Background:** Retrograde type A dissection (RTAD) after zone 0 hybrid aortic arch repair is highly lethal and not infrequent complication. The aim of this study was to assess the safety and effectiveness of rapid cardiac pacing as an adjunctive tool to prevent RTAD during or after hybrid procedures for zone 0 disease.

**Methods:** We performed a retrospective review of 42 consecutive patients with zone 0 hybrid aortic arch repair between November 2004 and January 2018. Right ventricular pacing was carried out through unipolar electrodes attached to the epicardium of the right ventricle through the sternotomy (the indifferent electrode was in the subcutaneous tissue). Pacing was utilised during the clamping of the ascending aorta, release of the aortic clamp, and stent-graft deployment.

**Results:** Operative indications were aortic arch aneurysm 45% ( $n = 19$ ), aortic arch dissection 45% ( $n = 19$ ), traumatic rupture of isthmus 7% ( $n = 3$ ), and type IA endoleak 2% ( $n = 1$ ). Urgent procedures 48% ( $n = 20$ ). The mean proximal aortic diameter was  $34.14 \pm 2.9$  mm. Mean stent-graft oversizing was  $12.97 \pm 3.4\%$ . The 30-day mortality rate was 14% ( $n = 6$ ). RTAD was observed in 7% ( $n = 3$ ). The actuarial survival rate was 74% over a mean follow-up of  $50 \pm 30.2$  months. Since January 2013, rapid right ventricular pacing (overdrive pacing at a rate of 200 beats/min) was systematically used ( $n = 24$ ). No RTAD was observed in this group of patients. Rapid right ventricular pacing reduced significantly the risk of RTAD ( $P = 0.038$ ).

**Conclusions:** Rapid right ventricular pacing is an effective method of inducing hypotension and appears to decrease the risk of retrograde type A dissection after zone 0 hybrid aortic arch repair.

Conflict of interest: none.

Source of Funding: This research did not receive any specific grant from funding agencies in the public, commercial, or not-for-profit sectors.

<sup>1</sup>Department of Vascular and Thoracic Surgery, Arnaud de Villeneuve Hospital, Montpellier, France.

<sup>2</sup>Clínica Universidad de los Andes, Servicio de Cirugía Vascular y Endovascular, Santiago, Chile.

<sup>3</sup>Department of Vascular and Thoracic Surgery, Bichat Hospital, Paris, France.

<sup>4</sup>Department of Vascular Surgery, Angers, France.

Correspondence to: Chassin-Trubert Lucien, Service de Chirurgie Vasculaire et Thoracique, Hôpital A de Villeneuve, 191 av Doyen Gaston Giraud, 34090 Montpellier, France; E-mail: [info@cirujanovascular.cl](mailto:info@cirujanovascular.cl)

## INTRODUCTION

Conventional surgical repair for aortic arch diseases necessitates arch replacement during deep hypothermia and circulatory arrest. Despite advances in the technique which have improved the outcomes and reduced morbidity,<sup>1</sup> many patients with severe comorbidities remain unsuitable for conventional repair. Aortic arch diseases or proximal extension of descending thoracic aortic are often deemed unsuitable for endovascular repair owing to the proximity of the supra-aortic trunks. To extend the proximal landing zone in the aortic arch, hybrid procedures that provide both a sufficient landing zone and preserve cerebral perfusion have been adopted as a valuable alternative.<sup>2</sup> We have already reported the midterm results for endovascular repair of aortic

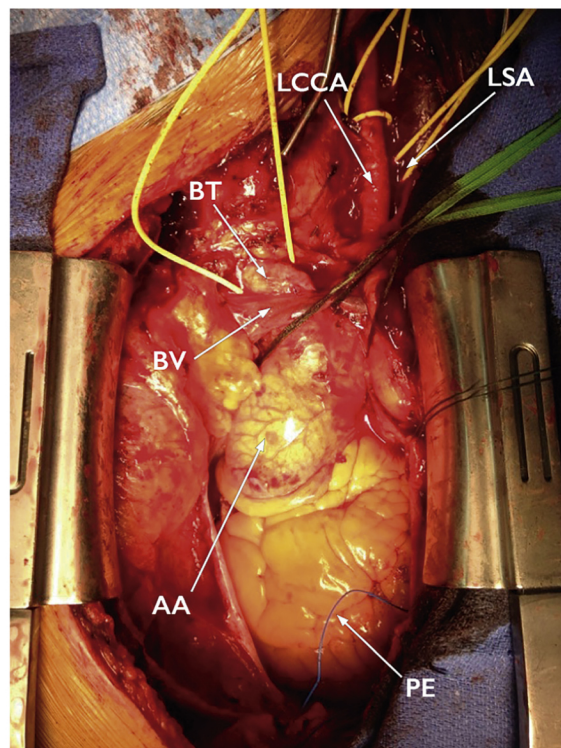
arch lesions.<sup>3</sup> The aortic arch is a challenging region both anatomically because of the proximity of the supra-aortic vessels, steep angulation of the aortic arch and physiologically as a consequence of fragility of the aortic wall, pulsatile movements of the aorta, and high blood flow. Complications of endovascular repair in the aortic arch include type I endoleak, stroke, and retrograde dissection.<sup>4</sup> The most feared complication of this procedure is retrograde type A aortic dissection, which has a low incidence but high mortality. The aim of this study is to report our series of hybrid repairs of zone 0 thoracic aortic lesions and outcomes with and without rapid pacing. We describe the technique of cardiac pacing during application of the side-biting clamp to the ascending aorta, declamping, and stent-graft deployment.

## MATERIAL AND METHODS

We performed a single-centre retrospective review of all patients who underwent zone 0 hybrid aortic arch repair from November 2004 to January 2018. The Ishimaru classification was used to categorize the proximal landing zone of the stent graft. We have focused our study on cases where coverage of the origin of the brachiocephalic trunk (zone 0) was required.

All patients underwent preoperative contrast-enhanced thorax computed tomographic angiography to assess the feasibility of endoluminal repair, size stent grafts, and plan implant strategy. Suitable morphology for stent-graft placement required a proximal aortic neck length of at least 20 mm. The stent-graft was oversized (<10% in acute aortic dissection, between 10% and 15% for aortic arch aneurysm or traumatic rupture of aortic isthmus, and 20% for patients with hemodynamic instability during emergency computed tomography angiography) greater than the minor axis of the aortic neck to provide sufficient radial force for adequate fixation. The preoperative computed tomographic imaging included femoral, iliac, and supra-aortic arteries to evaluate access vessels and supra-aortic trunks.

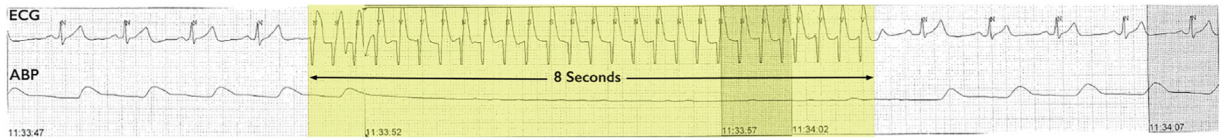
All procedures took place in the operating room with the patient under general anesthesia. Debranching preceded the deployment of the stent grafts either in the same sitting or as a staged procedure. Debranching and revascularization of supra-aortic trunks with a prosthetic graft was performed in all zone 0 cases through a median sternotomy. After systemic heparinization, a side-biting clamp was applied to the ascending aorta. The proximal end-to-side anastomosis was performed with a prosthetic 10 mm graft, followed by 2 end-to-side anastomoses



**Fig. 1.** Intraoperative picture before side-biting clamping of the ascending aorta. Note the pacing electrode (PE) attached to the epicardium of the right ventricle through the sternotomy. AA: ascending aorta. BV: brachiocephalic vein. BT: brachiocephalic trunk. LCCA: left common carotid artery. LSA: left subclavian artery.

to the brachiocephalic trunk and the left common carotid artery and an end-to-end anastomosis to the left subclavian artery. Prophylactic use of cerebrospinal fluid drainage to prevent spinal cord ischemia was not used.

The endovascular devices were delivered via the common femoral artery. A 260 cm, 0.035 inch guidewire (Terumo Medical Corporation, Tokyo, Japan) was placed, via the common femoral artery, under fluoroscopic control into the ascending aorta; a 5F calibrated pigtail catheter was advanced into the ascending aorta over the guidewire. This pigtail catheter was used to exchange the guidewire for an extrastiff guidewire (Lunderquist; Cook Inc). Angiography was performed through a 5F pigtail catheter advanced into the brachiocephalic trunk bypass graft. The stent graft was deployed under fluoroscopic control. A range of surgical clips was placed just below the aortoprosthetic anastomosis for an accurate placement of the stent graft. A baseline angiogram was performed before and after stent graft deployment to confirm proper position of the stent graft and complete exclusion of the lesion. Ballooning was performed selectively.



**Fig. 2.** Yellow zone shows the characteristics hemodynamic tracings during rapid ventricular pacing at 200 beats/second during a period of 8 sec. The top line is an electrocardiogram (ECG) tracing demonstrating initiation and cessation of rapid ventricular pacing. The bottom line

represents the arterial blood pressure (ABP) tracing with the decrease in pulsatile blood flow and mean arterial pressure during rapid pacing. Note the quick return to baseline after pacing cessation.

**Table I.** Patient characteristics

Variable	Mean, percentage (%)	<i>n</i> = 42 patients SD
<b>Demographics</b>		
Median age	70.38 years	±11.9 years
Male sex	83%	35 patients
<b>Comorbid conditions</b>		
Hypertension	76%	32 patients
Smoking	48%	20 patients
Dyslipidemia	43%	18 patients
Coronary artery disease	24%	10 patients
Chronic obstructive pulmonary disease	24%	10 patients
Peripheral arterial disease	21%	9 patients
Arrhythmia	15%	6 patients
Diabetes mellitus	12%	5 patients
Renal insufficiency	7%	3 patients
Congestive heart failure	7%	3 patients
Previous ascending aorta surgery	36%	15 patients
<b>ASA classification</b>		
ASA II	24%	10 patients
ASA III	43%	18 patients
ASA IV	29%	12 patients
ASA V	5%	2 patients

Right ventricular pacing was carried out through unipolar electrodes attached to the epicardium of the right ventricle through the sternotomy (the indifferent electrode was in the subcutaneous tissue) (Fig. 1). The patient was test paced at a rate of 200 beats/min, and the electrocardiogram and arterial waveform were examined to confirm adequate capture, a cessation of ventricular ejection and a low systolic blood pressure (Fig. 2). Rapid pacing was activated during application of the side-biting clamp to the ascending aorta, clamp removal, and proximal stent graft deployment.

### Statistical Analysis

Categorical data are presented as frequencies; continuous variables are expressed as median and range or standard deviation. Comparisons between

categorical variables are performed using chi-square test and with Student test for continuous variables. A probability value of <0.05 was considered statistically significant. All statistical analyses were performed using IBM SPSS Statistics 24 software (version 24.0.0.0).

### RESULTS

42 patients underwent thoracic aortic hybrid arch repair by sternotomy with stent graft deployment in zone 0. There were 35 men (83%) and 7 women (17%) with a mean age of 70.3 ± 11.9 years (range 43 to 91 years old). Baseline characteristics of the 42 patients are given in Table I. Indications were aneurysm of the aortic arch in 19 patients (45%), dissection of the aortic arch in 19 patients (45%), acute traumatic rupture of the aortic isthmus in 3 patients

**Table II.** Complications and reintervention during 50 months of follow-up after hybrid surgery for zone 0 aortic arch repair in 42 patients

Complications	Percentage (%)	<i>n</i> = 42 patients
Death < 30 days	14%	6 patients
Retrograde dissection	7%	3 patients
Stroke	10%	4 patients
Endoleak	10%	4 patients
Medullar ischemia	2%	1 patient
Thrombosis supra-aortic bypass	2%	1 patient
Myocardial infarction	5%	2 patients
Arrhythmia	12%	5 patients
Hemopericardium	7%	3 patients
Hemomediastinum	2%	1 patient
Hemorrhage	10%	4 patients
Mesenteric ischemia	10%	4 patients
Leg ischemia	5%	2 patients
Renal insufficiency	24%	10 patients
Respiratory distress	24%	10 patients
Sternal dehiscence	5%	2 patients
Nerve lesion	5%	2 patients
Access-related complication	12%	5 patients
Reintervention	31%	13 patients

(7%), and type IA endoleak in 1 patient (2%). Urgent procedures accounted for 48% (*n* = 20).

The mean ascending aortic diameter was  $34.14 \pm 2.9$  mm. Four different thoracic stent grafts were used: the Valiant Captivia device (Medtronic Vascular, Santa Rosa, CA, USA) in 57% (24 patients), the Excluder C-TAG device (W.L. Gore & Associates, Inc, Flagstaff, Ariz, USA) in 21% (9 patients), the Excluder TAG device (W.L. Gore & Associates, Inc, Flagstaff, AZ, USA) in 12% (5 patients), and the Talent device (Medtronic Vascular, Santa Rosa, CA, USA) in 10% (4 patients). The mean length of the covered aorta was  $285.3 \pm 117.7$  mm with a mean use of  $1.6 \pm 0.7$  stent grafts per procedure (range 1 to 3 stent-grafts). The mean percentage of thoracic stent-graft oversizing was  $12.97 \pm 3.4\%$ . The hybrid repair of the aortic arch was staged in 5 patients (12%) with a mean of 16.7 days between the open and the endovascular procedure.

During the index procedure two patients had a concomitant coronary revascularization with extracorporeal circulation, one patient underwent carotid stenting and another left superior lobectomy for malignant lesion. Technical success was achieved in all patients. Procedural complications and reinterventions are detailed in Table II. The 30-day mortality rate was 14% (6 patients) with no intraoperative deaths. The actuarial survival rate was 74% over a mean follow-up of  $50 \pm 30.2$  months.

Retrograde type A aortic dissection was observed in 3 patients (15%). No RTAD occurred during the index

procedure or between the aortic debranching and thoracic endovascular aortic repair (TEVAR) procedure. In 66% (2 patients), RTAD occurred within the first 30 days (at fourth and seventh postoperative days, respectively) and in 33% (1 patient), occurred on the 194th postoperative day. The 3 RTADs were symptomatic with acute thoracic pain as the principal symptom. These patients had a mean diameter of the ascending aorta of  $38.3 \pm 0.4$  mm, and the mean percentage oversizing was  $8 \pm 2.4\%$ . The 2 patients who developed RTAD within the first 30 perioperative days underwent immediate surgical conversion with ascending aortic replacement under circulatory arrest and suture between the prosthetic graft and the stent graft, which resulted in a favorable outcome for 1 of these 2 patients. The patient with the RTAD presenting on the 194th postoperative day was unable to proceed to surgery because of severe respiratory compromise and died without further intervention.

Since January 2013, right ventricular pacing was performed. This represents the latter 24 patients in the series. The hybrid surgery for zone 0 aortic arch repair in these 24 patients was performed in a single sitting. The duration of asystole corresponded exactly to the duration of overdrive pacing during each episode with a range between 8 and 12 sec. The patients reverted to normal sinus rhythm with no evidence of ischemia at the conclusion of each episode of overdrive pacing. The blood pressure almost immediately returned to normal after inactivation of the pacemaker in all patients.

**Table III.** Characteristics of patients, operative indications, and anatomic and endograft oversizing in the group of 18 patients treated without use of pacing and 24 patients with use of pacing as an adjunctive tool during zone 0 hybrid aortic arch repair. ( $P < 0,05$  for statistical significance)

Variable	No pacing group %, $n = 18$	Pacing group %, $n = 24$	$P$
<b>Demographics</b>			
Median age	71.16 $\pm$ 9.2 years	69.79 $\pm$ 14.0 years	( $P = 0.704$ )
Male sex	89% ( $n = 16$ )	79% ( $n = 19$ )	( $P = 0.403$ )
<b>Comorbid conditions</b>			
Hypertension	72% ( $n = 13$ )	79% ( $n = 19$ )	( $P = 0.601$ )
Smoking	56% ( $n = 10$ )	42% ( $n = 10$ )	( $P = 0.372$ )
Dyslipidemia	50% ( $n = 9$ )	38% ( $n = 9$ )	( $P = 0.418$ )
Coronary artery disease	33% ( $n = 6$ )	21% ( $n = 4$ )	( $P = 0.209$ )
Chronic obstructive pulmonary disease	28% ( $n = 5$ )	21% ( $n = 5$ )	( $P = 0.601$ )
Peripheral arterial disease	33% ( $n = 6$ )	13% ( $n = 3$ )	( $P = 0.103$ )
Arrhythmia	17% ( $n = 3$ )	13% ( $n = 3$ )	( $P = 0.703$ )
Diabetes mellitus	6% ( $n = 1$ )	17% ( $n = 4$ )	( $P = 0.271$ )
Renal insufficiency	6% ( $n = 1$ )	8% ( $n = 2$ )	( $P = 0.729$ )
Congestive heart failure	11% ( $n = 2$ )	5% ( $n = 1$ )	( $P = 0.387$ )
Previous ascending aorta surgery	22% ( $n = 4$ )	46% ( $n = 11$ )	( $P = 0.114$ )
<b>ASA Classification</b>			
ASA II	11% ( $n = 2$ )	33% ( $n = 8$ )	( $P = 0.094$ )
ASA III	44% ( $n = 8$ )	42% ( $n = 10$ )	( $P = 0.857$ )
ASA IV	39% ( $n = 7$ )	21% ( $n = 5$ )	( $P = 0.200$ )
ASA V	6% ( $n = 1$ )	5% ( $n = 1$ )	( $P = 0.834$ )
<b>Operative indication</b>			
Aortic arch aneurysm	61% ( $n = 11$ )	33% ( $n = 8$ )	( $P = 0.073$ )
Aortic arch dissection	33% ( $n = 6$ )	54% ( $n = 13$ )	( $P = 0.179$ )
Traumatic rupture of aortic isthmus	6% ( $n = 1$ )	8% ( $n = 2$ )	( $P = 0.729$ )
Type IA endoleak	0% ( $n = 0$ )	4% ( $n = 1$ )	( $P = 0.381$ )
<b>Operative detail</b>			
Urgent procedure	56% ( $n = 10$ )	42% ( $n = 10$ )	( $P = 0.372$ )
<b>Anatomic and endograft data</b>			
Ascending aorta diameter	35.16 $\pm$ 2.9 mm	33.37 $\pm$ 2.7 mm	( $P = 0.051$ )
Percentage of endograft oversizing	13.27 $\pm$ 3.8 %	12.75 $\pm$ 3.2 %	( $P = 0.635$ )

The group of 18 patients operated before January 2013 without the use of right ventricular pacing is comparable in demographics, comorbidities, American Society of Anesthesiologists classification, operative indication, ascending aortic diameter, and stent-graft oversizing with the 24 patients with rapid pacing as shown in Table III. Retrograde type 1 aortic dissection was significantly reduced from 17% to 0% ( $P < 0.038$ ) in the group of rapid pacing. There were no other significant differences between both groups in terms of complications. Details of complications and reintervention comparing both groups are provided in Table IV.

## DISCUSSION

Only a limited number of series of hybrid arch repair requiring complete supra-aortic debranching (zone 0 of Ishimaru classification) have been published.

Among the complications of endovascular aortic arch repair, retrograde type A dissection remains the most fatal leading to sudden death in 19% of cases and to surgical repair in 77% with an overall mortality rate of 42%.<sup>5</sup> On the basis of the data collected from 28 centers in the European Registry on Endovascular Aortic Repair Complications (EuREC), retrograde type A dissection after TEVAR is an uncommon complication with an incidence of 1.33% and with only one case observed in zone 0 debranching. Recent series report rates of 3.7% and 6.3% in landing zone 0 hybrid aortic arch repair.<sup>4,6</sup> In our opinion, the true incidence of RTAD is yet to be established, with most of the series reported representing mixed entities of aortic dissections and aneurysms with different aortic landing zones for TEVAR. A recent systematic review and meta-analysis<sup>7</sup> confirms that RTAD occurrence rate in zone 0 is higher than other landing zones with an incidence of 8.12% which congruent with

**Table IV.** Complications and reintervention after hybrid surgery for zone 0 aortic arch repair in the group of 18 patients treated without use of pacing and 24 patients with use of pacing as an adjunctive tool during zone 0 hybrid aortic arch repair. ( $P < 0.05$  for statistical significance)

Complications	No pacing group %, $n = 18$	Pacing group %, $n = 24$	$P$
Death <30 days	17% ( $n = 3$ )	13% ( $n = 3$ )	( $P = 0.703$ )
Retrograde dissection	17% ( $n = 3$ )	0% ( $n = 0$ )	( $P = 0.038$ )
Endoleak	17% ( $n = 3$ )	4% ( $n = 1$ )	( $P = 0.172$ )
Stroke	17% ( $n = 3$ )	4% ( $n = 1$ )	( $P = 0.172$ )
Medullar ischemia	0% ( $n = 0$ )	4% ( $n = 1$ )	( $P = 0.381$ )
Thrombosis supra-aortic bypass	0% ( $n = 0$ )	4% ( $n = 1$ )	( $P = 0.381$ )
Myocardial infarction	6% ( $n = 1$ )	4% ( $n = 1$ )	( $P = 0.834$ )
Arrhythmia	6% ( $n = 1$ )	17% ( $n = 4$ )	( $P = 0.363$ )
Hemopericardium	6% ( $n = 1$ )	8% ( $n = 2$ )	( $P = 0.729$ )
Hemomediastinum	0% ( $n = 0$ )	4% ( $n = 1$ )	( $P = 0.381$ )
Hemorrhage	6% ( $n = 1$ )	13% ( $n = 3$ )	( $P = 0.448$ )
Mesenteric ischemia	6% ( $n = 1$ )	13% ( $n = 3$ )	( $P = 0.559$ )
Leg ischemia	6% ( $n = 1$ )	4% ( $n = 1$ )	( $P = 0.834$ )
Renal insufficiency	17% ( $n = 3$ )	29% ( $n = 7$ )	( $P = 0.524$ )
Respiratory distress	33% ( $n = 6$ )	17% ( $n = 4$ )	( $P = 0.209$ )
Sternal dehiscence	6% ( $n = 1$ )	4% ( $n = 1$ )	( $P = 0.834$ )
Nerve lesion	6% ( $n = 1$ )	4% ( $n = 1$ )	( $P = 0.834$ )
Access related complication	17% ( $n = 3$ )	8% ( $n = 2$ )	( $P = 0.409$ )
Reintervention	39% ( $n = 7$ )	25% ( $n = 6$ )	( $P = 0.335$ )

the 7% obtained in our series. The incidence of RTAD increased markedly with combinations of higher risk scenarios, such as the association of dissection plus an ascending aortic diameter >40 mm plus native zone 0 as a proximal landing zone. The real incidence of RTAD reported in the literature could therefore be underestimated.

A number of potential mechanisms may be hypothesized to explain retrograde dissection in hybrid arch repair with total debranching that have been reported by Tshomba.<sup>8</sup> First, the endovascular procedure-related mechanisms with the advancement of stiff guidewires and large sheaths in the thoracic aorta and also proximal bare springs or hooks of endografts, excessive oversizing, or additional balloon dilatation may theoretically increase the risk of aortic damage and subsequent retrograde dissection. In the EuREC, 60% of retrograde dissection were classified as induced by the endograft itself.<sup>5</sup> Second, various aortic-related factors, such as kinked aortic arch and aortic wall friability, may play a role in development of retrograde dissection.<sup>9</sup> In the EuREC, 81% of patients who experienced retrograde dissection underwent TEVAR for aortic dissection, which was mainly acute. The connective tissue disorders, such as Marfan syndrome, are known as a poor indication for TEVAR.<sup>10–12</sup> Nevertheless, retrograde type A dissection occurring after endovascular repair of a zone 0 nondissecting arch

aneurysm has also been reported.<sup>8</sup> Third, dynamic interactions between endograft and landing zone may play a role in development of a retrograde dissection, especially in zone 0 debranching. A continuous motion resulting from its attachment to the beating heart is specific to the ascending aorta, including both radial expansion-contraction and wall translational motion.<sup>13</sup> These movements, along with the repeated slight back and forth motion of the endograft with the cardiac cycle, especially increased in the ascending aorta because of the high kinetic energy of blood flow, may theoretically increase the risk of endograft migration. Finally, the debranching procedure-related mechanisms with the risk of side-biting clamp of the ascending aorta under pulsatile flow is well known to develop iatrogenic type A dissection during off-pump coronary bypass surgery, especially in case of increased ascending aortic diameter.<sup>14</sup> This risk may be further amplified by the large anastomosis required on the ascending aorta for total arch debranching. The possible role solely of the arch debranching in retrograde dissection development, independently from endograft deployment, has been confirmed by a published case of retrograde type A dissection in the interval of a staged hybrid repair of a zone 0 debranching dissecting aneurysm.<sup>15</sup>

Considering the potential mechanisms of retrograde dissection occurring after hybrid aortic arch

repair with total debranching and the rate of retrograde dissection in our series, we decided in January 2013 to perform systematic rapid right ventricular pacing during both ascending aorta side-biting clamp, clamp removal, and stent-graft deployment with the aim to prevent retrograde dissection. Rapid right ventricular pacing has already been reported to facilitate precise deployment of endografts in the thoracic aorta<sup>16–18</sup> but not to prevent retrograde dissection during both lateral cross-clamping and clamp removal of the ascending aorta. Most reports recommend placement of a cardiac pacing catheter under fluoroscopy via the right or left femoral vein.<sup>16–18</sup> Ricotta J et al. reported their experience with rapid right ventricular pacing via pulmonary artery catheters, placed through the internal jugular vein accessed by the anesthesiologist during preparation for the TEVAR. It avoids the need for additional femoral vein access, which has been reported to have a higher complication rate than internal jugular vein access. Rapid right ventricular pacing has been described as a safe and reliable method of reducing pulsatile blood pressure, with nearly immediate onset and offset of action.<sup>16,17,19</sup> In addition, the pacing rate is readily titrated. Induced ventricular fibrillation is frequently used during cardiac surgery, and the technique is relatively simple, with little risk. It has been commonly used in balloon aortic valvuloplasties and percutaneous aortic valve replacements without negative cardiovascular consequences.<sup>20,21</sup> This technique is remarkably well tolerated, even in this high-risk population being treated for critical aortic stenosis and at prohibitive risk for conventional surgery. In the unlikely event that a patient does not spontaneously recover cardiac output when the rapid pacing is stopped, cardioversion and temporary pacing may be initiated until complete cardiac recovery is achieved. Potential complications of this technique are more related to venous access and positioning the pacemaker wire within the right ventricle. Care must be taken to avoid right ventricular perforation secondary to forceful manipulation. Nevertheless, during total supra-aortic vessels debranching, sternotomy and pericardiectomy give direct access to position an electrode on the right ventricle.

Several other approaches to blood pressure reduction have been reported. Pharmacologically induced systemic hypotension, most commonly using nitroglycerine, sodium nitroprusside, or short-acting beta-blockers, can lower the mean arterial pressure to 50 mm Hg for 1 to 4 min,<sup>22</sup> but this requires dose titration and has a considerably slower onset and offset of action than pacing. Another

pharmacological method of pressure reduction is transient (usually 10 to 30 sec), cardiac asystole induced by intravenous adenosine administration.<sup>23,24</sup> The Valsalva maneuver has been used, as has the induction of transient ventricular fibrillation.<sup>25</sup> Proximal aortic balloon occlusion effectively diminishes flow, but at the expense of greatly increased cardiac afterload with the potential for aortic or cardiac injury. The large occlusion balloon needs a large sheath through the brachial artery and a segment of normal aorta proximal to the lesion. Temporary vena cava balloon occlusion has also been reported,<sup>26</sup> using an occluding balloon inflated with diluted contrast or carbon dioxide. Possible complications of this technique include balloon rupture or migration and intracranial venous hypertension, particularly when the superior vena cava is occluded.

One of the limitations of our study is the small population being studied, which makes it difficult to draw robust statistical conclusions. The second limitation is the bias related to the learning curve, with the increased cumulative experience of the operators and refined technique for the recent group of patients where rapid pacing was used.

## CONCLUSION

Rapid right ventricular pacing is a simple and effective method of inducing hypotension, enables precise thoracic endograft deployment, and prevention of retrograde type A dissection for hybrid aortic arch repair in zone 0. It seems superior to many other approaches that have been used, particularly with regards to the rapid onset and offset of effect. Larger series and long-term clinical follow-up are required to fully assess the use of rapid right ventricular pacing to prevent retrograde type A dissection for hybrid aortic arch repair in zone 0.

---

*No acknowledgments.*

## REFERENCES

1. Sundt TM 3rd, Orszulak TA, Cook DJ, et al. Improving results of open arch replacement. *Ann Thorac Surg* 2008;86:787–96.
2. Bavaria J, Vallabhajosyula P, Moeller P, et al. Hybrid approaches in the treatment of aortic arch aneurysm: postoperative and midterm outcomes. *J Thorac Cardiovasc Surg* 2013;145:85–90.
3. Canaud L, Hireche K, Berthet JP, et al. Endovascular repair of aortic arch lesions in high-risk patients or after previous aortic surgery: midterm results. *J Thorac Cardiovasc Surg* 2010;140:52–8.

4. Geisbüscher P, Kotellis D, Müller-Eschner M, et al. Complications after aortic arch hybrid repair. *J Vasc Surg* 2011;53:935–41.
5. Eggebrecht H, Thompson M, Rousseau H, et al. European Registry on Endovascular Aortic Repair Complications. Retrograde ascending aortic dissection during or after thoracic aortic stent graft placement: insight from the European registry on endovascular aortic repair complications. *Circulation* 2009;120(11 Suppl):276–81.
6. Vallejo N, Rodriguez-Lopez JA, Heidari P, et al. Hybrid repair of thoracic aortic lesions for zone 0 and 1 in high-risk patients. *J Vasc Surg* 2012;55:318–25.
7. Yanqing C, Simeng Z, Lei L, et al. Retrograde type A aortic dissection after thoracic endovascular aortic repair: a systematic review and meta-analysis. *J Am Heart Assoc* 2017;6:e004649.
8. Tshomba Y, Bertoglio L, Marone EM, et al. Retrograde type A dissection after endovascular repair of a "zone 0" nondissecting aortic arch aneurysm. *Ann Vasc Surg* 2010;24:1–7.
9. Dong ZH, Fu WG, Wang YQ, et al. Retrograde type A aortic dissection after endovascular stent graft placement for treatment of type B dissection. *Circulation* 2009;119:735–41.
10. Van Keulen JW, Moll FL, Jahrome AK, et al. Proximal aortic perforation after endovascular repair of a type B dissection in a patient with Marfan syndrome. *J Vasc Surg* 2009;50:190–2.
11. Nordon IM, Hinchliffe RJ, Holt PJ, et al. Endovascular management of chronic aortic dissection in patients with Marfan syndrome. *J Vasc Surg* 2009;50:987–91.
12. Geisbüscher P, Kotellis D, von Tengge-Kobligk H, et al. Thoracic aortic endografting in patients with connective tissue diseases. *J Endovasc Ther* 2008;15:144–9.
13. Jin S, Oshinski J, Giddens DP. Effects of wall motion and compliance on flow patterns in the ascending aorta. *J Biomech Eng* 2003;125:347–54.
14. Ketenci B, Enc Y, Ozay B, et al. *Heart Surg Forum* 2008;11:231–6.
15. Akhyari P, Kamiya H, Heye T, et al. Aortic dissection type A after supra-aortic debranching and implantation of an endovascular stent-graft for type B dissection: a word of caution. *J Thorac Cardiovasc Surg* 2009;137:1290–2.
16. Moon MC, Dowdall JF, Roselli EE. The use of right ventricular pacing to facilitate stent graft deployment in the distal aortic arch: a case report. *J Vasc Surg* 2008;47:629–31.
17. Pornratanarangi S, Webster MW, Alison P, et al. Rapid ventricular pacing to lower blood pressure during endograft deployment in the thoracic aorta. *Ann Thorac Surg* 2006;81:21–3.
18. Ricotta JJ 2nd, Harbuzariu C, Pulido JN, et al. A novel approach using pulmonary artery catheter-directed rapid right ventricular pacing to facilitate precise deployment of endografts in the thoracic aorta. *J Vasc Surg* 2012;55:1196–201.
19. Nienaber CA, Kische S, Rehders TC, et al. Rapid pacing for better placing: comparison of techniques for precise deployment of endografts in the thoracic aorta. *J Endovasc Ther* 2007;14:506–12.
20. David F, Sanchez A, Yanez L, et al. Cardiac pacing in balloon aortic valvuloplasty. *Int J Cardiol* 2007;116:327–30.
21. Webb JG, Pasupati S, Achtem L, et al. Rapid pacing to facilitate transcatheter prosthetic heart valve implantation. *Catheter Cardiovasc Interv* 2006;68:199–204.
22. Bernard EO, Schmid ER, Lachat ML, et al. Nitroglycerin to control blood pressure during endovascular stent-grafting of descending thoracic aortic aneurysms. *J Vasc Surg* 2000;31:790–3.
23. Dorros G, Cohn JM. Adenosine-induced transient cardiac asystole enhances precise deployment of stent-grafts in the thoracic or abdominal aorta. *J Endovasc Surg* 1996;3:270–2.
24. Kahn RA, Moskowitz DM, Marin ML, et al. Safety and efficacy of high-dose adenosine-induced asystole during endovascular AAA repair. *J Endovasc Ther* 2000;7:292–6.
25. Kahn RA, Marin ML, Hollier L, et al. Induction of ventricular fibrillation to facilitate endovascular stent graft repair of thoracic aortic aneurysms. *Anesthesiology* 1998;88:534–6.
26. Ishiguchi T, Nishikimi N, Usui A, et al. Endovascular stent-graft deployment: temporary vena caval occlusion with balloons to control aortic blood flow-experimental canine study and initial clinical experience. *Radiology* 2000;215:594–9.