HAL open science

Autoimmune encephalitis concomitant with SARS-CoV-2 infection: insight from 18 F-FDG PET imaging and neuronal autoantibodies

Stephan Grimaldi, Stanislas Lagarde, Jean-Robert Harlé, Jean-Robert Harlé, Joseph Boucraut, Eric Guedj

To cite this version:

Stephan Grimaldi, Stanislas Lagarde, Jean-Robert Harlé, Jean-Robert Harlé, Joseph Boucraut, et al.. Autoimmune encephalitis concomitant with SARS-CoV-2 infection: insight from 18 F-FDG PET imaging and neuronal autoantibodies. Journal of Nuclear Medicine, 2020, 62 (5), 10.2967/jnumed.120.249292 . hal-02933208

HAL Id: hal-02933208

https://hal.science/hal-02933208

Submitted on 9 Sep 2020

HAL is a multi-disciplinary open access archive for the deposit and dissemination of scientific research documents, whether they are published or not. The documents may come from teaching and research institutions in France or abroad, or from public or private research centers.

L'archive ouverte pluridisciplinaire **HAL**, est destinée au dépôt et à la diffusion de documents scientifiques de niveau recherche, publiés ou non, émanant des établissements d'enseignement et de recherche français ou étrangers, des laboratoires publics ou privés.

Distributed under a Creative Commons Attribution 4.0 International License

Downloaded from jnm.snmjournals.org by on September 9, 2020. For personal use only.
Journal of Nuclear Medicine, published on July 24, 2020 as doi:10.2967/jnumed.120.249292

Autoimmune encephalitis concomitant with SARS-CoV-2 infection: insight from ^{18}F-FDG PET imaging and neuronal autoantibodies

Stephan Grimaldi[1*]; Stanislas Lagarde[2*]; Jean-Robert Harlé[3]; José Boucraut[4§]; Eric Guedj[5§]

1. Aix Marseille Univ, APHM, Timone Hospital, Department of Neurology and Movement Disorders, Marseille, France
2. Aix Marseille Univ, APHM, INSERM, INS, Inst Neurosci Syst, Timone Hospital, Epileptology Department, Marseille, France
3. Aix Marseille Univ, APHM, Timone Hospital, Department of Internal Medicine, Marseille, France.
4. Aix Marseille Univ, APHM, CNRS, INT, Conception Hospital, Immunology Laboratory, Marseille, France
5. Aix Marseille Univ, APHM, CNRS, Centrale Marseille, Institut Fresnel, Timone Hospital, CERIMED, Nuclear Medicine Department, Marseille, France

* Dual first authorship / § Dual senior authorship

Corresponding author:
Prof. Eric Guedj
eric.guedj@ap-hm.fr
Service de Médecine Nucléaire, CHU Timone, 264 rue Saint Pierre, 13005 Marseille, France
Tel: +33-491385558; Fax: +33-491384769

Word count: 2,173

Running title: Autoimmune encephalitis and SARS-CoV-2

Immediate Open Access: Creative Commons Attribution 4.0 International License (CC BY) allows users to share and adapt with attribution, excluding materials credited to previous publications.
License: https://creativecommons.org/licenses/by/4.0/.
Details: http://jnm.snmjournals.org/site/misc/permission.xhtml.

Downloaded from jnm.snmjournals.org by on September 9, 2020. For personal use only.

Abstract

We report the case of a 72-years-old man with concomitant autoimmune encephalitis and SARS-CoV-2 infection.

Methods: Review of clinical examination, CT, PET, MRI imaging, and autoantibodies testing.

Results: The patient presented subacute cerebellar syndrome and myoclonus several days after general infectious symptoms. The oropharyngeal swab test was positive for SARS-CoV-2. Brain MRI was normal. CSF testing showed normal cell counts, negative RT-qPCR and no oligoclonal banding. Brain ^{18}F-FDG-PET showed diffuse cortical hypometabolism, associated with putaminal and cerebellum hypermetabolism, compatible with encephalitis, and especially cerebellitis. The immunological study revealed high titers of IgG autoantibodies in serum and CSF directed against the nuclei of Purkinje cells, striatal and hippocampal neurons. Search for neoplasia including whole-body ^{18}F-FDG-PET and CT scans was negative. Treatment with steroids allowed a rapid improvement of symptoms.

Conclusion: This clinical case brings arguments on the possible relationship between SARS-CoV-2 infection and autoimmune encephalitis, and on the interest of ^{18}F-FDG-PET in such context.

Keywords

Autoimmune encephalitis, ^{18}F-FDG-PET, methylprednisolone, SARS-CoV-2

Downloaded from jnm.snmjournals.org by on September 9, 2020. For personal use only.

Introduction

Since late December 2019, severe acute respiratory syndrome coronavirus 2 (SARS-CoV-2) is causing worldwide outbreak with substantial morbidity and mortality. Most of patients present with fever and respiratory tract symptoms (*1*). Several neurological manifestations have been described, mostly acute cerebrovascular disease, impaired consciousness and muscle injury (*2*). Cases of Guillain-Barré syndrome (*3*) and meningitis/encephalitis (*4*) were also reported. In this context, possible impact of Positron Emission Tomography (PET) imaging is debated (*5*). Here, we report a case of suspected autoimmune encephalitis concomitant with SARS-CoV-2 infection, corroborated by high titers of anti-neuronal antibodies, ^{8}F-Fluorodeoxyglucose (^{18}F-FDG) PET imaging, and clinical improvement after immunomodulatory treatment.

Case report

A 72-year-old non-smoker man with a single episode of transient global amnesia ten years ago in his past medical history, presented progressive diffuse arthralgia and sore throat (day 0). Two days after, his general practitioner started Josamycin for 4 days. On day 8, he exhibited fever episode (38-38.5°C) without rhinorrhea, cough or dyspnea, leading to the prescription of azithromycin. He never experienced anosmia or ageusia. On day 12, a chest computed tomography (CT)-Scan showed peripheral bilateral ground-glass lesions and consolidative opacities suggestive of SARS-CoV-2 infection. Symptoms improved gradually. On day 17, he started to develop bilateral upper limb action tremor. The next day, tremor worsen involving lower limb and trunk, making the walk and the sit-position impossible leading to his admission to hospital. Neurological exam showed cerebellar syndrome (action tremor, ataxia, dysarthria and upper limbs dysmetria) associated with spontaneous diffuse myoclonus mostly affecting proximal limbs and worsen by movements, also stimulus-sensitive. The remaining of neurological exam was normal including ocular motility and deep tendon reflexes. His body temperature, oxygen saturation, respiratory rate and lung auscultation were normal. A moderate biological inflammatory syndrome was present with increased fibrinogen (7.07 g/L, normal:1.90-4.30) and C-Reactive protein (14 mg/L, normal: 0.0-5.0). The first nasopharyngeal swab test for SARS-CoV-2 was positive (day 18), as well as afterwards the serology which was strongly positive for IgM and IgG. The next naso-/oro-pharyngeal swab quantitative reverse transcription Polymerase Chain Reaction (RT-qPCR) tests were negative (days 21-22-26-27). Electroencephalogram showed symmetric diffuse background

Downloaded from jnm.snmjournals.org by on September 9, 2020. For personal use only.

slowing, reactive to stimulation, without interictal paroxysm, notably no correlation of the myoclonus on back-averaging. Brain magnetic resonance imaging (MRI) including gadolinium contrast injection was normal (Figure 1). Brain PET with ^{18}F-FDG showed putaminal and cerebellum hypermetabolism associated with diffuse cortical hypometabolism, confirmed by whole-brain voxel-based SPM quantification (Figure 1). Slight lung and hilar lymph nodes hypermetabolisms were noticed, matching with post-infectious pseudo-nodular retractile consolidation on CT scan, without straightforward argument for neoplasia. Cerebrospinal fluid (CSF) testing showed normal cell counts (4×10^6/L), mild elevated protein level (49mg/dL), negative RT-qPCR and no oligoclonal banding. Nerve tissue immunostaining with the serum and CSF revealed the presence of autoantibodies directed against the nuclei of Purkinje cells, striatal and hippocampal neurons, as illustrated with the CSF in Figure 2. This immunostaining does not evoke any previously described targets for autoimmune encephalitis. The titer of the immunoglobulin G (IgG) isotype autoantibodies in the serum was extremely high (1/25000) whereas it was 1/96 in the CSF. Same intensity and reactivity in serum and CSF are observed at the same IgG concentration ruling out intrathecal autoantibody synthesis in concordance with the absence of CSF specific IgG oligoclonal banding. Dot-blot against onconeural antigens and cell-based assays against membrane antigens have all been negative. Finally, anti-nuclear, anti-phospholipid, anti-polynuclear autoantibodies and other tissues autoantibodies were negative. Because of the suspected autoimmune nature of the encephalitis, we started promptly immunomodulatory treatment: at first intravenous immunoglobulins (0.4g/kg/day for 5 days) since day 23 with a good tolerance but without significant clinical improvement. We then decided to treat the patient with intravenous methylprednisolone (1g/day for 5 days) on day 30. To help reducing myoclonus, we introduced oral drops of clonazepam (0.3 mg three times a day) but the treatment was stopped because of drowsiness. Clinically, the patient improved considerably after the methylprednisolone treatment leading to cessation of myoclonus and upper-limb dysmetria and allowing the walk without assistance. He was thus discharged from hospital on day 37. Moreover, we did not observe any sign of SARS-CoV-2 re-activation.

Downloaded from jnm.snmjournals.org by on September 9, 2020. For personal use only.

Discussion

As other β-coronavirus group, neuro-invasive potential of SARS-CoV-2 is suspected. It is supposed that a rapid entry into human host cells is mainly mediated by cellular receptor angiotensin-converting enzyme 2 (ACE2) which is expressed in human airway epithelia, vascular endothelia but also in the brain, particularly brainstem (both in neurons and glia) (*6*). However, in our case, a primary infection of the central nervous system (CNS) seems unlikely because of: 1) onset of neurological symptoms at the time of regression of infectious symptoms (with only slight residual thoracic abnormalities on PET/CT); 2) negativity of the next naso-/oro-pharyngeal swab RT-qPCR tests; 3) absence of meningeal reaction and negativity of SARS-CoV-2 RT-qPCR in CSF. On the opposite, the autoimmune hypothesis is supported by: 1) very high titer of IgG antineuronal autoantibodies, excluding potential induction of antibodies secondary to neuronal damage; 2) brain PET hypermetabolism pattern compatible with encephalitis, and especially cerebellitis (*7*); 3) clinical improvement after immunomodulatory treatments (*8*). It's interesting to notice the correlation of clinical symptoms with brain PET hypermetabolism and the targets of the autoantibodies. The mismatch between the abnormalities found on brain PET and the normality of MRI also highlights the potential of PET as an early biomarker (*9*). Absence of oligoclonal banding or hypercellularity should not preclude the disease as it's frequently reported in other autoimmune encephalitis (e.g. Contactin-associated protein-like 2 (CASPR2) or Leucine-rich glioma Inactivated 1 (LGI1) autoantibodies). These encephalitis are also characterized by very high titers of autoantibodies, passage of autoantibodies into the CNS and efficacy of steroids (*10,11*). In our case, antibodies are present at very high levels in the serum and are not synthesized in the CNS, probably acting by passage through the CSF (*11*). Finally, an alternative hypothesis could be an incidental association between SARV-Cov2 infection and autoimmune encephalitis as for example part of a paraneoplastic syndrome. However: 1) no neoplasia was initially detected on whole-body ^{18}F-FDG-PET and CT scans in this non-smoker patient; 2) lung findings are compatible with SARS-CoV-2 post-infection lesions (*12*); 3) all anti-onconeural testing were negative. Obviously, follow-up remains necessary to exclude a tumor occurrence. Due to the presence of antibodies with intracellular targets, methylprednisolone seemed the best first-line treatment option (*8*). We were at this moment nevertheless concerned about a potential worsening of infectious symptoms due to corticosteroids, and we initially started intravenous immunoglobulins. The recent results of the RECOVERY (Randomised Evaluation of COVid-19 thERapY) trial would now certainly

Downloaded from jnm.snmjournals.org by on September 9, 2020. For personal use only.

encourage to use steroids as first-line therapy (*13*). Because of the lack of significant clinical improvement after 5 days of intravenous immunoglobulins, we then prescribed methylprednisolone leading to major improvement, and without sign of viral re-activation.

To conclude, medical community should be aware of potential post-SARS-Cov-2 autoimmune syndromes that could appear until several days after resolution of infectious symptoms. In suspected encephalitis, the search of SARS-CoV-2 notably in the CSF, anti-neuronal autoantibodies, associated with ^{18}F-FDG-PET, despite complex logistic and procedure in this context, could help to determine the diagnosis and the management of patients, especially in MRI negative cases. Further studies are required to identify the neuronal autoantigen in order to sustain or discard the hypothesis of a cross-reactivity with viral antigens.

Downloaded from jnm.snmjournals.org by on September 9, 2020. For personal use only.

Disclosure

No potential conflicts of interest relevant to this article exist.

Acknowledgments

We warmly thank Pr. Azulay Jean-Philippe, Pr. Eusebio Alexandre (Department of Neurology and Movement Disorders, University Hospital of Marseille), Dr Gonzalez Sandra and Dr Salgues Betty (Department of Nuclear Medicine, University Hospital of Marseille) for having shared their evaluation.

Key points

- Question: Can SARS-CoV-2 infection be associated with autoimmune encephalitis?
- Pertinent Findings: We report the case of a 72-years-old man presenting subacute cerebellar syndrome and myoclonus with positive oropharyngeal swab test for SARS-CoV-2. An autoimmune encephalitis was suspected despite normal brain MRI and CSF tests because brain ^{18}F-FDG-PET showed diffuse pattern compatible with encephalitis and especially cerebellitis, and because high titers of autoantibodies directed against the nuclei of Purkinje cells, striatal and hippocampal neurons were detected.
- Implications for Patient Care: Despite complex logistic and procedure in this context, ^{18}F-FDG-PET could help to determine the diagnosis and the management of such patients, especially in MRI negative cases. Treatment with steroids allowed a rapid improvement of symptoms.

Downloaded from jnm.snmjournals.org by on September 9, 2020. For personal use only.

References

1. Wang D, Hu B, Hu C, et al. Clinical Characteristics of 138 Hospitalized Patients With 2019 Novel Coronavirus-Infected Pneumonia in Wuhan, China. *JAMA*. 2020;323(11):1061–9

2. Mao L, Jin H, Wang M, et al. Neurologic Manifestations of Hospitalized Patients With Coronavirus Disease 2019 in Wuhan, China. *JAMA Neurol*. 2020;77(6):1–9.

3. Toscano G, Palmerini F, Ravaglia S, et al. Guillain–Barré Syndrome Associated with SARS-CoV-2. *N Engl J Med*. 2020. [Epub ahead of print]

4. Moriguchi T, Harii N, Goto J, et al. A first case of meningitis/encephalitis associated with SARS-Coronavirus-2. *Int J Infect Dis*. 2020;94:55-58

5. Guedj E, Verger A, Cammilleri S. PET imaging of COVID-19: the target and the number. *Eur J Nucl Med Mol Imaging*. 2020;47(7):1636-1637.

6. Steardo L, Steardo L Jr, Zorec R, Verkhratsky A. Neuroinfection may contribute to pathophysiology and clinical manifestations of COVID-19. *Acta Physiol (Oxf)*. 2020;229(3):e13473.

7. Baumgartner A, Rauer S, Mader I, Meyer PT. Cerebral FDG-PET and MRI findings in autoimmune limbic encephalitis: correlation with autoantibody types. *J Neurol*. 2013;260(11):2744-53.

8. Macher S, Zimprich F, De Simoni D, Höftberger R, Rommer PS. Management of Autoimmune Encephalitis: An Observational Monocentric Study of 38 Patients. *Front Immunol.* 2018;9:2708

9. Solnes LB, Jones KM, Rowe SP, et al. Diagnostic Value of 18F-FDG PET/CT Versus MRI in the Setting of Antibody-Specific Autoimmune Encephalitis. *J Nucl Med*. 2017;58(8):1307-1313.

Downloaded from jnm.snmjournals.org by on September 9, 2020. For personal use only.

10. Jarius S, Hoffmann L, Clover L, Vincent A, Voltz R. CSF findings in patients with voltage gated potassium channel antibody associated limbic encephalitis. *J Neurol Sci.* 2008;268(1-2):74-7.

11. van Sonderen A, Ariño H, Petit-Pedrol M, et al. The clinical spectrum of Caspr2 antibody–associated disease. *Neurology*. 2016;87(5):521–8.

12. Setti L, Kirienko M, Dalto SC, Bonacina M, Bombardieri E. FDG-PET/CT findings highly suspicious for COVID-19 in an Italian case series of asymptomatic patients. *Eur J Nucl Med Mol Imaging*. 2020;47(7):1649-1656

13. Statement from the Chief Investigators: low-cost dexamethasone reduces death by up to one third in hospitalised patients with severe respiratory complications of COVID-19. Randomised Evaluation of COVID-19 Therapy website. https://www.recoverytrial.net/files/recovery_dexamethasone_statement_160620_v2final.pdf. Updated June 16, 2020. Accessed June 21, 2020.

Downloaded from jnm.snmjournals.org by on September 9, 2020. For personal use only.

Figure 1. ^{18}F-FDG brain, whole-body PET and brain MRI findings

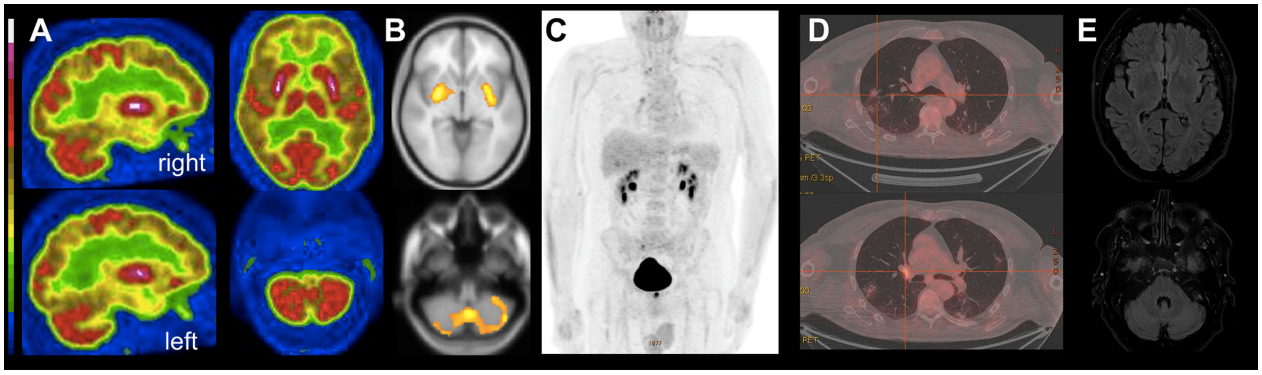

Brain ^{18}F-FDG PET sagittal and axial slices (A) showing diffuse cortical hypometabolism, associated with putaminal and cerebellum hypermetabolism confirmed by SPM comparison (B) to 20 healthy elderly subjects ($p<0.001$, $k>600$). Whole-body ^{18}F-FDG PET/CT showing slight lung and hilar lymph nodes hypermetabolisms on MIP (C) and axial fused slices (D), matching with pseudo-nodular retractile consolidation post-infectious findings on CT scan, without straightforward argument for neoplasia. Brain MRI axial slices on T2-weighted FLAIR of putamen and cerebellum (E) showing no abnormalities.

Downloaded from jnm.snmjournals.org by on September 9, 2020. For personal use only.

Figure 2. **Immunostaining of neuronal nuclei.**

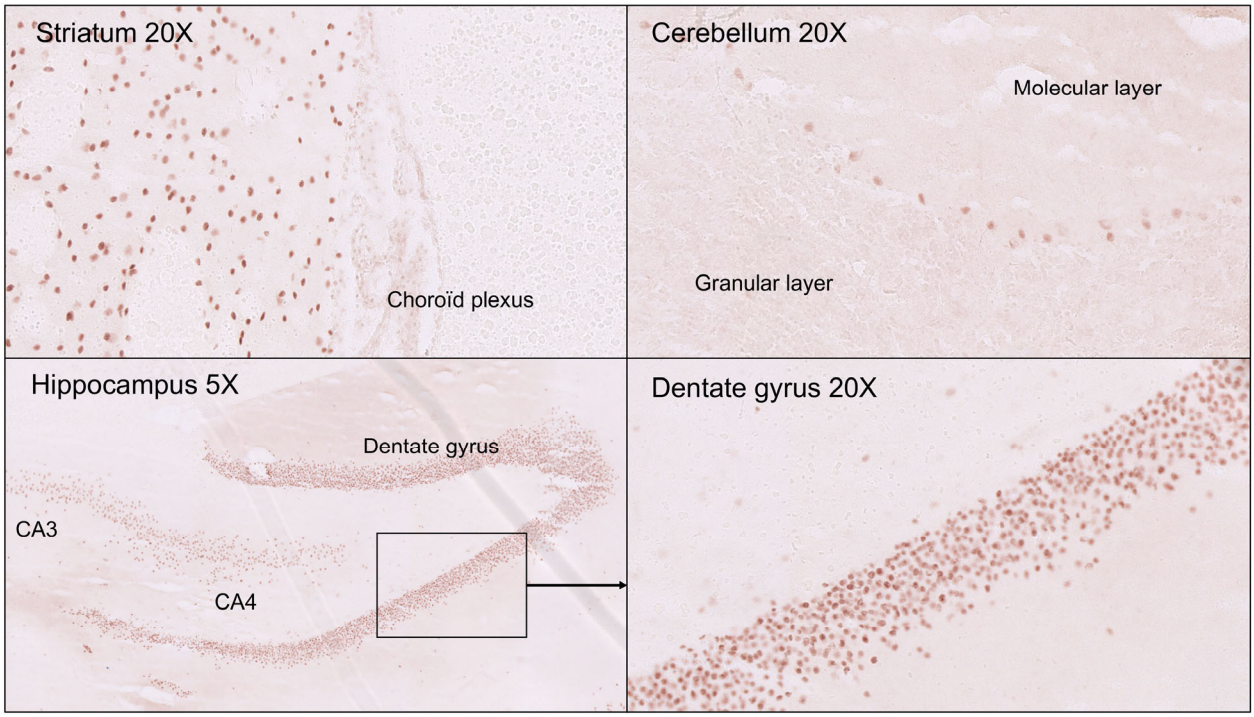

25µ sections are obtained from frozen rat nerve tissue, and incubated with different dilutions of serum or CSF and peroxidase labelled anti-IgG antisera. Immunostaining was revealed in the presence of 3-amino-9-ethylcarbazole. This NDP.view2 figure shows the labelling with the CSF diluted to 1/6 on the nuclei of Purkinje cells in the cerebellum, and striatal and hippocampal neurons.

Downloaded from jnm.snmjournals.org by on September 9, 2020. For personal use only.

The Journal of NUCLEAR MEDICINE

Autoimmune encephalitis concomitant with SARS-CoV-2 infection: insight from ^{18}F-FDG PET imaging and neuronal autoantibodies

Stephan Grimaldi, Stanislas Lagarde, Jean-Robert Harle, Joseph Boucraut and Eric Guedj

J Nucl Med.
Published online: July 24, 2020.
Doi: 10.2967/jnumed.120.249292

This article and updated information are available at:
http://jnm.snmjournals.org/content/early/2020/07/23/jnumed.120.249292

Information about reproducing figures, tables, or other portions of this article can be found online at:
http://jnm.snmjournals.org/site/misc/permission.xhtml

Information about subscriptions to JNM can be found at:
http://jnm.snmjournals.org/site/subscriptions/online.xhtml

JNM ahead of print articles have been peer reviewed and accepted for publication in *JNM*. They have not been copyedited, nor have they appeared in a print or online issue of the journal. Once the accepted manuscripts appear in the *JNM* ahead of print area, they will be prepared for print and online publication, which includes copyediting, typesetting, proofreading, and author review. This process may lead to differences between the accepted version of the manuscript and the final, published version.

The Journal of Nuclear Medicine is published monthly.
SNMMI | Society of Nuclear Medicine and Molecular Imaging
1850 Samuel Morse Drive, Reston, VA 20190.
(Print ISSN: 0161-5505, Online ISSN: 2159-662X)

© Copyright 2020 SNMMI; all rights reserved.

SNMMI SOCIETY OF NUCLEAR MEDICINE AND MOLECULAR IMAGING