



HAL
open science

Non-congenital dorsal tumefaction with rapid growth in a young child identified as an intramuscular hemangioma

Davide Russo, Sylvie Fraitag, Bertrand Bruneau, Nathalie Stock, Sylvie Aillet, Alain Dupuy, Catherine Droitcourt

► **To cite this version:**

Davide Russo, Sylvie Fraitag, Bertrand Bruneau, Nathalie Stock, Sylvie Aillet, et al.. Non-congenital dorsal tumefaction with rapid growth in a young child identified as an intramuscular hemangioma. JAAD Case reports, 2020, 6 (7), pp.616-618. 10.1016/j.jdc.2020.04.039 . hal-02931629

HAL Id: hal-02931629

<https://hal.science/hal-02931629>

Submitted on 29 Sep 2020

HAL is a multi-disciplinary open access archive for the deposit and dissemination of scientific research documents, whether they are published or not. The documents may come from teaching and research institutions in France or abroad, or from public or private research centers.

L'archive ouverte pluridisciplinaire **HAL**, est destinée au dépôt et à la diffusion de documents scientifiques de niveau recherche, publiés ou non, émanant des établissements d'enseignement et de recherche français ou étrangers, des laboratoires publics ou privés.



Distributed under a Creative Commons Attribution - NonCommercial - NoDerivatives 4.0 International License

Non-congenital dorsal tumefaction with rapid growth in a young child identified as an intramuscular hemangioma



David Russo, MD,^{a,b} Sylvie Fraitag, MD,^c Bertrand Bruneau, MD,^d Nathalie Stock, MD,^c Sylvie Aillet, MD,^f Alain Dupuy, MD, PhD,^{a,b,g} and Catherine Droitcourt, MD, PhD^{a,b,g,h}
Rennes and Paris, France

Key words: intramuscular hemangioma; noninvoluting congenital hemangioma; rapidly involuting congenital hemangioma; soft-tissue tumors.

INTRODUCTION

Intramuscular capillary-type hemangioma now called *intramuscular hemangioma* (IMH) has been defined recently and is classified in the category of “provisionally unclassified vascular anomalies,” according to the latest revision of the International Society for the Study of Vascular Anomalies classification.¹ Several reported cases of IMH have been misdiagnosed and confused with common intramuscular venous malformations.² Here we report the case of a 3-year-old child who had an IMH presenting as a rapidly growing mass.

CASE REPORT

A 3-year-old boy was referred for a mass on the right side of his back (Fig 1). He was born at 38 weeks' gestation after an uncomplicated pregnancy. The mass was absent at birth and was observed at the age of 1 year. At this age, an ultrasonography performed in another care center showed a well-circumscribed, high-flow vascular lesion within the right *Latissimus dorsi* muscle surrounded by increased fat density. Magnetic resonance imaging at that time identified a well-delineated intramuscular tissue lesion of 33 × 21 × 12 mm with flow void, without phleboliths, sparing the adjacent structures. Signals were isointense on the T1-weighted image and hyperintense on the T2-weighted image with early intense homogeneous contrast enhancement after

Abbreviations used:

IMH: intramuscular hemangioma
NICH: noninvoluting congenital hemangioma

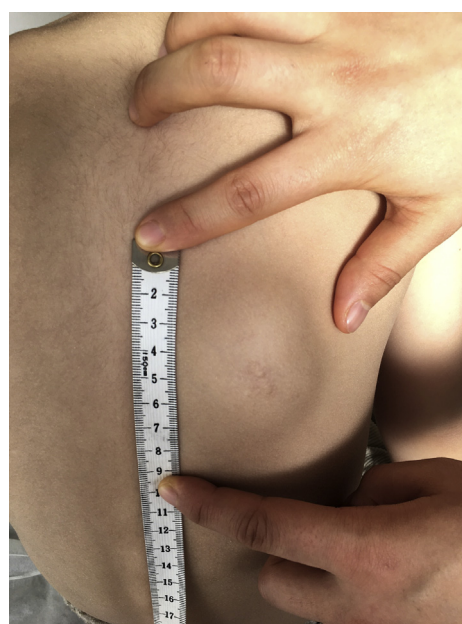

Fig 1. Skin-colored mass localized on the right side of the back of a 3-year-old child.

From the University of Rennes^a; CHU Rennes, Department of Dermatology^b; AP-HP, Hôpital Necker-Enfants Malades, Department of Pathology, APHP, Paris^c; the Departments of Radiology,^d Pathology,^e and Pediatric Surgery,^f CHU Rennes; REPERES Pharmaco-Epidemiology and Health Services Research, University Rennes 1 and French School of Public Health^g; and INSERM, CIC.^h

Funding sources: None.

Conflicts of interest: None disclosed.

Correspondence to: Dr Catherine Droitcourt, MD, PhD, Department of Dermatology, Pontchaillou Hospital, 2 rue

Henri le Guilloux, 35000 Rennes, France. E-mail: catherine.droitcourt@chu-rennes.fr.

JAAD Case Reports 2020;6:616-8.
2352-5126

© 2020 by the American Academy of Dermatology, Inc. Published by Elsevier, Inc. This is an open access article under the CC BY-NC-ND license (<http://creativecommons.org/licenses/by-nc-nd/4.0/>).

<https://doi.org/10.1016/j.jdc.2020.04.039>

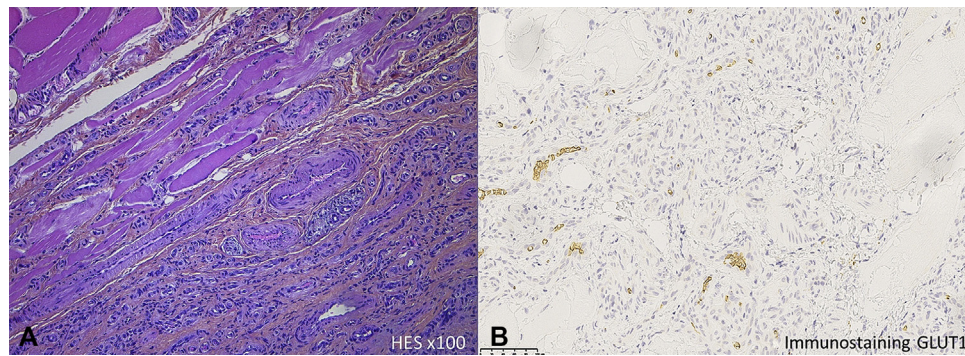


Fig 2. **A**, Hematoxylin-eosin–stained sections of skin tissue show the proliferation of small-diameter, regular capillaries between the skeletal muscle bundles (original magnification, $\times 100$). **B**, Glucose transporter 1 (GLUT 1) immunostaining: negative (original magnification, $\times 25$).

gadolinium injection. He and his parents then lived abroad for 2 years and no follow-up was carried out.

When the child was 3 years old, he returned to France and because of the persistent growth of the lesion, the child was referred to our department. The physical examination found an indurated, skin-colored, nonpulsatile, fixed, nontender tumor measuring 45 mm in diameter with some superficial telangiectasias. The rest of the clinical examination was normal. Ultrasonography examination identified a high-flow vascular lesion of stable echo structure, with a size increase of 30% ($41 \times 15 \times 18$ mm) from the previous measurement. Given the uncertainty of the diagnosis, a percutaneous biopsy was performed. The histologic analysis found lobules and sheets of regular, small-diameter capillaries lined with plump endothelial cells lying between skeletal muscle fibers. No intra- or perilesional fat contingent was observed (Fig 2, A). Immunohistochemical staining was negative for GLUT-1 (glucose transporter 1) (Fig 2, B) and D2-40 (anti-Podoplanin, lymphatic immunohistochemical staining). A diagnosis of intramuscular capillary-type hemangioma (or IMH) was made. Because of the persistent growth and the onset of discomfort, it was decided to completely excise under general anesthesia.

DISCUSSION

IMH was initially described as a type of venous malformation.²⁻⁴ Currently, it is defined as a benign vascular GLUT1-negative tumor located in skeletal muscle. IMH mainly occurs in young adults and children,² but it has been rarely reported in infants. Indeed, the median age of onset was 25 years in a case series including 89 patients⁵ and 8.1 years in a case series including exclusively 22 children.² To our knowledge, this lesion has never been described in the neonatal period. The origin is unknown, but

somatic mutations in *KRAS* and *MAP2K1* have recently been identified in some specimens of IMH.⁶ IMHs are characterized by a skin-colored, nonpulsating, nontender soft-tissue mass, mainly located on the limbs and the trunk. The clinical course is stable, or with slow growth, without spontaneous regression, thus differing from infantile hemangioma, which is characterized by rapid growth after birth and slow regression after 12 to 18 months.⁷ It also differs from rapidly involuting congenital hemangioma, which has a distinctive evolutive profile, with maximum size at birth and rapid involution over 1 year. In addition, these lesions are more often subcutaneous than intramuscular.^{4,7} Because IMHs have no spontaneous regression, they could be confused with a form of intramuscular noninvoluting congenital hemangioma (NICH), in particular for the nodular clinical subtype.⁸ Two clinical subtypes of NICHs have been described - a patch type and a more protuberant nodular type both are mostly fully formed at birth with a nonprogressive course, and they display typical, coarse telangiectasia and areas of discoloration. In addition, imagery may show calcifications and areas of arterio-venous shunt, never described in IMH.^{4,8} NICHs are very different histologically; they are lobulated vascular tumors composed of small, well-differentiated vessels lined by endothelial cells, with prominent, sometimes hobnailed nuclei. There is a fibrotic stroma containing abnormal large vessels composed of veins, arteries, and lymphatics.⁹

Sonography is required to identify the intramuscular location, and Doppler shows high vascular density with low-resistance arterial flow⁴ excluding the diagnosis of intramuscular venous malformation and cystic lymphangioma. The presence of an intra- or periadipocytic contingent is

frequently described.¹⁰ Magnetic resonance imagery features include a well-defined mass, with isointense signals in muscle on T1-weighted images.³

Only histology including immunostaining can definitively confirm the diagnosis of IMH and eliminate the more serious diagnoses—soft-tissue tumors such as rhabdoid tumor, rhabdomyosarcoma, or infantile fibrosarcoma.

This case of an IMH with features, including the young age at onset and a phase of rapid growth, show that this entity should be included in the differential diagnosis with malignant soft-tissue tumors.

We thank Angela Verdier for linguistic revision.

REFERENCES

1. ISSVA-Classification-2018.pdf. Available at: <http://www.issva.org/UserFiles/file/ISSVA-Classification-2018.pdf>. Accessed July 29, 2019.
2. Yilmaz S, Kozakewich HP, Alomari AI, Fishman SJ, Mulliken JB, Chaudry G. Intramuscular capillary-type hemangioma: radiologic–pathologic correlation. *Pediatr Radiol*. 2014;44(5):558-565.
3. Navarro OM. Magnetic resonance imaging of pediatric soft-tissue vascular anomalies. *Pediatr Radiol*. 2016;46(6):891-901.
4. Johnson CM, Navarro OM. Clinical and sonographic features of pediatric soft-tissue vascular anomalies part 1: classification, sonographic approach and vascular tumors. *Pediatr Radiol*. 2017;47(9):1184-1195.
5. Allen PW, Enzinger FM. Hemangioma of skeletal muscle. An analysis of 89 cases. *Cancer*. 1972;29(1):8-22.
6. Goss JA, Konczyk DJ, Smits PJ, et al. Intramuscular fast-flow vascular anomaly contains somatic MAP2K1 and KRAS mutations. *Angiogenesis*. 2019;22(4):547-552.
7. Léauté-Labrèze C, Harper JJ, Hoeger PH. Infantile haemangioma. *Lancet*. 2017;390(10089):85-94.
8. Lee PW, Frieden IJ, Streicher JL, McCalmont T, Haggstrom AN. Characteristics of noninvoluting congenital hemangioma: a retrospective review. *J Am Acad Dermatol*. 2014;70(5):899-903.
9. Gorincour G, Kokta V, Rypens F, Garel L, Powell J, Dubois J. Imaging characteristics of two subtypes of congenital hemangiomas: rapidly involuting congenital hemangiomas and non-involuting congenital hemangiomas. *Pediatr Radiol*. 2005;35(12):1178-1185.
10. Fernandez-Pineda I, Jenkins JJ, Santiago TC, Prajapati HJ, Pappo AS. Awareness of intramuscular capillary type hemangioma in the differential diagnosis of soft-tissue tumors in children. *Pediatr Blood Cancer*. 2016;63(12):2252-2253.