



**HAL**  
open science

## **Stereoelectroencephalography (SEEG) and epilepsy surgery in posttraumatic epilepsy: A multicenter retrospective study**

Alexane Fierain, Aileen Mcgonigal, Stanislas Lagarde, H el ene Catenoux, Luc Valton, Sylvain Rheims, Anca Nica, Agn es Trebuchon-da Fonseca, Romain Carron, Fabrice Bartolomei

### **► To cite this version:**

Alexane Fierain, Aileen Mcgonigal, Stanislas Lagarde, H el ene Catenoux, Luc Valton, et al.. Stereoelectroencephalography (SEEG) and epilepsy surgery in posttraumatic epilepsy: A multicenter retrospective study. *Epilepsy & Behavior*, 2020, 112, pp.107378. 10.1016/j.yebeh.2020.107378 . hal-02929555

**HAL Id: hal-02929555**

**<https://hal.science/hal-02929555v1>**

Submitted on 23 Nov 2020

**HAL** is a multi-disciplinary open access archive for the deposit and dissemination of scientific research documents, whether they are published or not. The documents may come from teaching and research institutions in France or abroad, or from public or private research centers.

L'archive ouverte pluridisciplinaire **HAL**, est destin ee au d ep ot et  a la diffusion de documents scientifiques de niveau recherche, publi es ou non,  emanant des  tablissements d'enseignement et de recherche fran ais ou  trangers, des laboratoires publics ou priv es.

# Stereoelectroencephalography (SEEG) and epilepsy surgery in post-traumatic epilepsy: a multicenter retrospective study.

FIERAIN Alexane<sup>1,2</sup>, McGONIGAL Aileen.<sup>1,3</sup>, LAGARDE Stanislas.<sup>1,3</sup>,  
CATENOIX H el ene.<sup>5,6</sup>, VALTON Luc.<sup>7</sup>, RHEIMS Sylvain.<sup>5,6</sup>, NICA Anca.<sup>8</sup>, ,  
TREBUCHON Agnes<sup>1,3</sup>, CARRON Romain<sup>4</sup>, , BARTOLOMEI Fabrice<sup>1,3</sup>.

- 
1. APHM, Timone Hospital, Epileptology Department, Marseille, France
  2. Reference Epilepsy Center, Universit  Catholique de Louvain - Cliniques universitaires Saint-Luc, Brussels, Belgium
  3. Aix Marseille Univ, APHM, INSERM, INS, Inst Neurosci Syst, Timone Hospital, Epileptology Department, Marseille, France
  4. Aix Marseille Univ, APHM, INSERM, INS, Inst Neurosci Syst, Timone Hospital, Functional and Stereotactic Neurosurgery Department, Marseille, France
  5. Translational and Integrative Group in Epilepsy Research (TIGER), INSERM U1028, CNRS UMR5292, Lyon Neuroscience Research Center, University Lyon 1, Lyon, France
  6. Department of Functional Neurology and Epileptology, Hospices Civils de Lyon and University of Lyon, Lyon, France
  7. Neurophysiological Investigations, H pital Pierre Paul Riquet, CHU Purpan (Toulouse University Hospital), Toulouse, France ; Centre de Recherche Cerveau et Cognition (CerCo), CNRS UMR 5549, Toulouse Mind and Brain Institute, University of Toulouse 3 (Universit  Paul-Sabatier), Toulouse, France
  8. Rennes University Hospital, Neurology Department, CIC 1414, LTSI (Laboratoire de Traitement du Signal et de l'Image), Inserm U1099, Rennes, France

**\*Corresponding Author :** Prof. Fabrice Bartolomei (MD, PhD)

Epileptology Department, H pital La Timone, Assistance Publique – H pitaux de Marseille,  
264 Rue Saint-Pierre, 13005, Marseille, France

[Fabrice.bartolomei@ap-hm.fr](mailto:Fabrice.bartolomei@ap-hm.fr) Tel : +33(0)491384990 Fax : +33(0)0491385826

## **Abstract**

**Purpose:** Post-traumatic epilepsy (PTE) is a common cause of drug-resistant epilepsy, especially in young adults. Nevertheless, such patients are not common candidates for intracranial presurgical evaluation. We investigated the role of stereo-electroencephalography (SEEG) in defining epileptogenicity and surgical strategy in PTE patients.

**Methods:** We analyzed ictal SEEG recordings from 18 patients. We determined the seizure onset zone (SOZ) by quantifying the epileptogenicity of the sampled structures, using the “epileptogenicity index”. We also identified seizure onset patterns (SOP) through visual and frequency analysis. Post-surgical outcome was assessed by Engel’s classification.

**Results:** The SOZ in PTE was most often located in temporal lobes, followed by frontal lobes. The SOZ was network-organized in the majority of the cases. Half of the SOP did not contain fast discharges. Half of the recordings showed SOZ that were less extensive than the post-traumatic lesions seen on brain magnetic resonance imaging (MRI). All but one operated patient benefited from tailored cortectomy. Only 3 patients were contraindicated for surgical resection due to bilateral epileptogenicity. The overall surgical outcome was good in a majority of patients (67% Engel I).

**Conclusion:** Despite the potential risk of bilateral or multifocal epilepsy, PTE patients may benefit from presurgical assessment in well-selected cases. In this context, SEEG allows guidance of tailored resections adapted to the seizure onset zone.

**Key words:** focal epilepsy, epilepsy surgery, traumatic brain injury, SEEG

**Abbreviations:** PTE: post-traumatic epilepsy, TBI: traumatic brain injury, SEEG: stereoelectroencephalography, MRI: magnetic resonance imaging, SOZ: seizure onset zone, SOP: seizure onset pattern, EI: epileptogenicity index, MTS: mesial temporal sclerosis, TLE: temporal lobe epilepsy, FLE: frontal lobe epilepsy

## 1. Introduction

Post-traumatic epilepsy (PTE) is a common cause of structural epilepsy, defined by the occurrence of one or more late unprovoked seizures associated with a known traumatic brain injury (TBI)[1, 2]. Several risk factors for developing PTE have been identified, including duration of loss of consciousness, missile injuries, intracerebral hemorrhage, diffuse cerebral contusions, acute subdural hematoma with surgical evacuation, early post-traumatic seizures and depressed skull fracture[3]. Estimated relative risks of seizure occurrence have been estimated to be 1.5 after mild TBI (loss of consciousness or amnesia less than 30 minutes), 2.9 after moderate TBI (loss of consciousness from 30 min to 1 day or a skull fracture) and 17.2 after severe TBI (loss of consciousness of more than 1 day, SDH or brain contusion)[3, 4]. PTE can occur even decades after the initial TBI[5] and accounts for 20% of symptomatic epilepsy in the general population[6]. Post-traumatic seizures can be difficult to control[7] and the diagnosis of PTE is present in 5% of all epilepsy patients referred to specialized epilepsy centers. Nevertheless, such epilepsy is not frequently assessed for epilepsy surgery, in particular using intracranial recordings. Indeed, PTE accounts for 2-3% of pre-surgical series using SEEG[8, 9]. Head injuries frequently cause bilateral or multifocal injuries not amenable to epilepsy surgery. There are also surgical challenges due to scar tissue and adhesions secondary to the TBI[10]. Therefore, presurgical evaluation of such epilepsies can be a challenging task in locating a limited seizure onset zone and guiding possible resective surgery.

Only a few series have studied surgical outcome of selected patients with PTE.

Outcome was found to be favorable in temporal cases associated with hippocampal sclerosis[7, 11-13]but more uncertain in extra-temporal cases[14] [15]. However,

while cases localized to the temporal region are often associated with hippocampal sclerosis, they may exhibit more widespread injury on neuroimaging[11]. The MRI aspect is therefore not a reliable indicator of the potential seizure onset zone.

To our knowledge there have been no studies specifically dedicated to presurgical invasive evaluation using stereoelectroencephalography (SEEG) in PTE. The usefulness of intracranial explorations in these cases has however been highlighted, contributing to a better prognosis in series using subdural grid recordings[14]. Our objectives were to describe the SEEG-based characteristics of epileptogenicity in PTE and to correlate these data with surgical outcome.

## **2. Material and methods**

### **2.1. Patients' selection**

We selected 26 patients from four different French tertiary epilepsy centers (Marseille, Lyon, Toulouse and Rennes) with post-traumatic drug-resistant epilepsies who benefited from presurgical evaluation between 1998 and 2018. All of the patients suffered from severe traumatic brain injury (TBI), defined according to Annegers *et al* [4] : post-traumatic loss of consciousness/amenia > 1 day and/or brain contusion/intra-cranial hematoma. The delay between the acute brain injury and the epilepsy onset was not restrictive, since it has been shown that brain-injured patients can develop epilepsy even more than 10 years after TBI[4, 16].

### **2.2. Pre-surgical evaluation**

Prior to SEEG and/or surgery, all patients included underwent non-invasive assessment for drug-resistant focal epilepsy, including clinical history, neurological examination, long-term video-EEG monitoring, neuropsychological evaluation, 1.5 and/or 3 Tesla brain magnetic resonance imaging (MRI), interictal 18-

fluorodeoxyglucose-positron emission tomography (18PET-FDG). Some of them also underwent ictal single photon emission computed tomography (SPECT), functional MRI and/or Wada test for language assessment. SEEG exploration was carried out during long term video-SEEG monitoring as part of patients' normal clinical care. The SEEG was decided on a case-by-case basis in order to clearly define the seizure-onset zone, in particular its relationship with the post-traumatic lesion. It was indicated only in cases where a reasonable hope of surgery was considered after the non-invasive phase and in accordance with French guidelines[17]. The targeting and number of electrodes was individually designed based on the data of the non-invasive pre-surgical assessment performed for each patient, according to hypotheses about the localization of the seizure onset zone (SOZ).

The institutional review board of the French Institute of Health approved this study and written consent from patients or legal tutors was obtained.

### **2.3. SEEG recordings**

Recordings were performed using intracerebral multiple contact electrodes (Dixi Medical™ or Alcis™) ; 5-15 contacts) placed intracranially according to stereotactic methodology[17]. The anatomical localization of the electrodes was defined using post-implantation 1.5T MRI or using a fusion of pre-implantation brain MRI and post-implantation brain computed tomography (CT). Signals were recorded on a Natus or Micromed System, sampled at 256 Hz, 512Hz or 1024Hz, depending on the time of recording and recorded on a hard disk (16bits/sample) using no digital filter. Two hardware filters were present in the acquisition process, one high-pass filter

(cut-off frequency equal to 0.16 Hz) and one antialiasing low pass filter (cut-off frequency equal to 97Hz at 256Hz, 170Hz at 512Hz or 340Hz at 1024Hz).

#### 2.4. Signal analysis

The seizure onset was defined as the first change of intracranial EEG signal within the context of a sustained rhythmic discharge and correlated with clinical signs. Electroclinical seizures resulting from direct cortical stimulation were excluded. Seizure-onset pattern (SOP) determination was assessed by two independent epileptologists (AF and FB), blinded to clinical data. SOP were described using visual analysis combined with time-frequency analysis and defined for the electrodes involved in the SOZ, within the first 5 seconds of the discharge. We categorized eight different SOP, as previously reported by our group [8, 18]. As previously discussed, four patterns were considered to be “fast SOP” (included ictal discharge above 12 Hz) and four were considered to be slow SOP, because of the absence of clear fast discharge (see Supplementary Figure). If ictal recordings of a patient showed different types of SOP, the most prevalent type of SOP was selected. The SOZ was defined using visual analysis complemented by a systematic calculation of the epileptogenicity index (EI) [19, 20]. The EI is used to determinate the epileptogenicity of analyzed brain structures, by quantifying two important features of the SEEG signal during the transformation from preictal to ictal activity: the energy ratio (ER) redistribution (decrease of low frequency below 12hz and increase of high frequency above 12 Hz) and its delay of occurrence (in regards of the first structure generating ictal discharge). The normalized EI value ranges from 0 (selected brain structure not involved in the ictal discharge) to 1 (maximum epileptogenicity, which means that the selected brain structure generates a rapid



discharge with a minimal delay). The SOZ was defined without EI in case of SOP not including fast discharge. We used the methodology of previous studies of our group to characterize the SOZ[21, 22] : the SOZ extension was classified as “focal” (one sub-lobe involved) or “network” (more than one sub-lobe involved) according to the number of distinct brain regions (“sub-lobes”) involved, defined by a high nEI ( $\geq 0.4$ ) or visual analysis (e.g. structures involved within the five first seconds of the ictal discharge) when the SOP was characterized by lower frequencies. The sub-lobes were distinguished as follows: mesial temporal, lateral temporal, insular, orbitofrontal, mesial prefrontal, lateral prefrontal, premotor, central (pre- and postcentral), operculum (frontal and Rolandic), mesial parietal, lateral parietal, mesial occipital and lateral occipital.

### **2.5.Surgical outcome**

Surgical outcome was regularly assessed during the post-operative follow up, using the Engel classification[23]. The latest surgical outcome was used in this study, with exclusion of patients with less than 12 months of follow-up.

### **2.6.Statistical analysis**

Chi-squared ( $\chi^2$ ) and Fisher’s exact test and Mann Whitney U test were used to compare respectively categorical data or continuous data between some clinical parameters (localization of the SOZ, type of SOP (slow vs fast), organization of the SOZ (focal versus network), epilepsy duration and surgical outcome. In these analyses,  $p \leq 0.05$  was considered to be statistically significant.

## **3. Results**

### 3.1. Clinical and SEEG data

During the period under consideration, 1227 SEEG procedures were performed in the 4 centres. We reviewed 26 patients with drug-resistant PTE representing thus 2% of the total SEEG procedures. Three patients were excluded due to multiple etiologies (2 with TBI and focal cortical dysplasia type II) or incomplete medical records (1). Furthermore, we excluded 2 patients because SEEG recordings were not available for analysis and 3 patients who did not benefit from SEEG recordings and who were operated based on non-invasive assessment (Fig1). Eighteen patients (5 women and 13 men) were thus selected for this study. Fourteen (74%) were right-handed and the mean age was 41 years (range 25-61). All of them suffered from severe TBI. The mean time between TBI and seizure onset was 4.5 years (range 0.2-25) and the mean age at seizure onset was 22.6 years old (range 5-38). All patients presented post-traumatic MRI lesions: 4/18 had hippocampal sclerosis and 17/18 had encephalomalacia/gliosis (8/18 focal and 9/18 multifocal, detailed in Table 1). Mean number of sublobes involved by post-traumatic lesions was 2.8 (range 1-7).

All the selected patients underwent SEEG exploration and recordings. The mean number of implanted electrodes per patient was 11.4 (range 7-14), with bilateral implantations in 55.5%. One patient (5%) experienced a surgical complication of intracranial electrode implantation (asymptomatic subdural hematoma). The mean number of lobes sampled per patient was 3.3 (where implantations sampled frontal, temporal, parietal and/or occipital lobes in 94, 100, 44 and 5.5% of the cases, respectively). The mean number of intra-lesional electrodes per patient was 3 (range

1-6). A total of 59 seizures were analyzed; mean number of seizures per patient was 3.3 (range 1-5).

### **3.2. Quantification of epileptogenicity and SOZ organization**

Visual analysis and quantification led to the anatomical definition of the SOZ in all the patients. Finally, we could classify the involved SOZ as follows: temporal 8/18 (44%), temporal-plus (temporal and frontal) 4/18 (22%), bi-temporal 2/18 (11%) and frontal 4/18 (22%). One example of a temporal “plus” epilepsy is represented in Fig 2. Thus, taken as a whole, a majority of explored PTE included the temporal lobe region.

As described in the methods, SOZ extension and organization were defined as the number of sub-lobes displaying a high epileptogenicity index ( $\geq 0.4$ ) or, for the cases with lower frequency patterns involved visually within the 5 first seconds of the epileptic discharge. SOZ displayed a focal organization in 44.4% (3 lateral temporal, 4 mesial temporal, 1 precentral) and a network organization in 63.6% (detailed in Table 1). The SOZ was bilateral in 16% of cases and involved temporal lobe in 77.7% of the patients. Using the sub-lobar categorization, we compared the extent of the SOZ to the post-traumatic lesion (Fig 3B). Interestingly, SOZ was less extensive than the corresponding post-traumatic lesion in 50% of the patients, in terms of sub-lobes involved (detailed in Table 1).

### **3.3. Seizure-onset patterns**

The SOP determination was the following: 6/18 slow wave or baseline shift followed by low voltage fast activity (LVFA) (pattern D according to [8, 18]; 4/18 sharp

theta/alpha activity (pattern F) ; 2/18 delta - brush (pattern H) ; 1/18 beta sharp activity (pattern G) ; 1/18 LVFA (pattern A); 1/18 preictal spiking followed by LVFA (pattern B); 1/18 burst of polyspikes followed by LVFA (pattern C). Two patients showed 2 types of SOP (with only two available seizures per patient): delta brush (pattern H) and rhythmic slow spike (pattern E) for the first one; preictal spiking followed by LVFA (pattern B) in seizures emerging from the left side of the brain and rhythmic slow spikes (pattern E) in seizures emerging from the right side of the brain of the second patient. Examples of SOP seen in our study are represented in Fig 3A. Taken as a whole, we noticed that half of cases involved slow onset patterns without clear fast discharge. We did not find significant statistical association between slow versus fast patterns and type of epilepsy (temporal versus extra-temporal,  $p=0.33$ ) or the network versus focal organization of the SOZ ( $p=0.9$ ).

### **3.4.Surgical outcome**

Thirteen patients (72%) benefited from surgical resection after SEEG. The mean duration of epilepsy before surgery was 18.6 years (SD 5.2). The 5 remaining patients were either contraindicated for surgery due to bilateral EZ (3/5) or refused to be operated (2/5).

Surgery was a tailored resection based on SOZ localization from SEEG recordings except one patient with a mesial temporal lobe epilepsy who underwent selective amygdalohippocampectomy with Gamma Knife radiosurgery (Table 1). Undesired side-effects were mild to moderate and only transient (dysarthria/ facial palsy/hemiplegia worsening/headache/depression) in 5/13 patients. However, one patient died after resective surgery due to malignant brain edema. In the remaining 7 patients, no side effects were observed.

Surgical outcome was excellent in 8/12 (Engel I) (66%), slight improvement in 3/12 (Engel III, 2/3 FLE) and no worthwhile improvement in 1/12 (Engel IV). Mean follow-up duration was 39.5 months, with no significant difference between patients with Engel class Ia and the others (Engel class II-IV) (mean duration 36.5 and 45.5 months respectively, range 12-60 months). Post-operative MRI showed complete SOZ resection in 9/13, associated with excellent outcomes (Engel Ia) in 7/9. Incomplete resection of the SOZ (4/13), mainly due to close relationship with eloquent cortices, was associated with poorer outcomes (1/4 Engel I, 1/4 Engel III, 1/4 Engel IV).

Comparing seizure-free (n=8) with non-seizure-free (n=4) patients, we did not find significant association with the epilepsy duration before surgery (p=0.6) or age at onset (p=0.46), presence of hippocampal sclerosis (p=0.56) or type of SOZ (focal versus network, p=0.27). It should be noted, however, that the outcome seems to be better in focal cases than in network cases (3/4 of Engel III IV outcomes are network cases). Better outcome tended to be associated with pure temporal localization of the SOZ (Engel I, 6/7, 85%) versus extratemporal/temporal-plus (including bi-temporal) localization (Engel I, 1/5, 20%), though this was non-significant (Fisher test p=0.09).

#### **4. Discussion**

We report here the first retrospective study of SEEG-based analysis in PTE. We collected 18 cases from four epilepsy surgery centers in France over a period of twenty years, confirming that PTE is rare indication for patients undergoing presurgical evaluation. This is in agreement with the low rate of glial scars (potentially post-traumatic) in the European Brain Bank of epilepsy surgery specimens[24] and in agreement with previous SEEG series[8, 9].

#### **4.1. The seizure-onset zone in PTE**

Our results showed that seizures arose mainly from temporal lobe (77.7% ; 44.4% temporal and 33.3% temporal “plus”), and frontal lobe (22.3%), consistent with previous findings[13, 14]. None of our patients suffered from parietal or occipital lobe epilepsy. In our sample, only 22.2% showed mesial temporal sclerosis (MTS), less than in previous studies[13, 25]. Most of the patients (63.6%) showed a network organization of the SOZ, which was slightly more frequent in frontal lobe localization. Only 16% of our sample presented bilateral SOZ. By comparison, the proportion of cases with network organization of the SOZ appeared to be similar in other causes of drug-resistant epilepsy explored in SEEG, such as malformations of cortical development[22] or tuberous sclerosis[26] .

Slightly more than a third of the patients presented an SOZ smaller than the post-traumatic lesion (detailed in Table 1, example of patient 4 detailed in Fig 4). This is an important finding, since the main explanation for the lack of surgical data concerning PTE could be the belief that such epilepsies are less likely to be surgical candidates due to their “non-focal” nature and/or large lesion on MRI. Our findings highlight the interest of SEEG in this population, since in most cases tailored resection was possible, and was sometimes smaller than the visible MRI lesion.

Regarding the SOP, these were composed by relatively slow ictal discharge (below 12 Hz) in half of the cases, showing that fast discharges are not a necessary hallmark of seizure onset in such cases. It has already been proposed to distinguish patterns including LVFA (with or without preceding spikes) from patterns characterized by rhythmic slower activity (rhythmic theta-alpha waves or spikes). These slow SOP are found in a non-negligible proportion of SOP collected in a large SEEG retrospective study[8].

## 4.2.Surgical outcome

We reviewed the surgical series related to PTE, detailed in Table 2. Some series[25],[12] showed better surgical outcomes in temporal lobe epilepsy (TLE) (63 and 69% Engel I respectively) than in frontal lobe epilepsy(FLE) (30 and 33% Engel I respectively). These findings have been confirmed by another study[14] showing an Engel class I rate of 28% following resection of extra-temporal epileptic SOZ (mostly located in the frontal lobe) in PTE, highlighting the negative impact on outcome of absence of MRI lesions, absence of intracranial recordings prior to surgery and localization of the SOZ in the dominant hemisphere. Another study[27] found slightly better surgical outcomes in non-traumatic mesial TLE comparing with post-traumatic mesial TLE (40% and 50-69% of Engel class I, respectively), a tendency found in another study (78% and 63% of Engel class I, respectively), although non-statistically significant in this last study[14]. More recently, Hitti *et al*[13] reviewed their institutional surgical experience in PTE and found an overall excellent surgical outcome (Engel Class I 68.8%), with a vast majority (82.6%) of mesial TLE. In our study, we confirmed previous findings showing an overall long-term surgical outcome that was good to excellent, with only one operated patient who did not experience worthwhile improvement of his epilepsy. Moreover, we found a globally better surgical outcome for TLE (Engel I 77%, Engel III 11.5%, Engel IV 11.5%) than for FLE (25% Engel I, 50% Engel III). As previously highlighted[14], intracranial electrode implantation during the presurgical assessment of drug-resistant PTE plays a crucial role in surgical outcome of such epilepsies. Nevertheless, only a few patients included in previous studies have benefited from intracranial recordings, using mainly subdural electrodes[11, 13, 25, 27]. Implantation of invasive electrodes may indeed be surgically challenging due to

adhesions and scar tissue secondary to head trauma. On the contrary, SEEG electrode implantation is less affected by this issue[28] and only one patient in our group suffered from an asymptomatic post-SEEG complication (subdural hemorrhage).

To our knowledge, the present study is the first one carried out using SEEG prior to surgery for PTE. The good results obtained suggest that patient selection was satisfactory in the present series, and that PTE should not be considered *per se* to be a contraindication to pursuing pre-surgical evaluation, including intracerebral recordings if necessary. Of note, about a third of our sample displayed a SOZ smaller than the MRI post-traumatic lesions observed. Therefore, SEEG data are crucial in this scenario to tailor the surgical resection, which can sometimes be smaller than the MRI lesion.

## 5. References

- [1] Szaflarski JP, Nazzal Y, Dreer LE. Post-traumatic epilepsy: current and emerging treatment options. *Neuropsychiatr Dis Treat* 2014;10: 1469-77.
- [2] Scheffer IE, Berkovic S, Capovilla G, Connolly MB, French J, Guilhoto L, Hirsch E, Jain S, Mathern GW, Moshe SL, Nordli DR, Perucca E, Tomson T, Wiebe S, Zhang YH, Zuberi SM. ILAE classification of the epilepsies: Position paper of the ILAE Commission for Classification and Terminology. *Epilepsia* 2017;58: 512-521.
- [3] Agrawal A, Timothy J, Pandit L, Manju M. Post-traumatic epilepsy: an overview. *Clin Neurol Neurosurg* 2006;108: 433-9.
- [4] Annegers JF, Coan SP. The risks of epilepsy after traumatic brain injury. *Seizure* 2000;9: 453-7.
- [5] Hung C, Chen JW. Treatment of post-traumatic epilepsy. *Curr Treat Options Neurol* 2012;14: 293-306.
- [6] Frey LC. Epidemiology of posttraumatic epilepsy: a critical review. *Epilepsia* 2003;44: 11-7.
- [7] Diaz-Arrastia R, Agostini MA, Madden CJ, Van Ness PC. Posttraumatic epilepsy: the endophenotypes of a human model of epileptogenesis. *Epilepsia* 2009;50 Suppl 2: 14-20.
- [8] Lagarde S, Buzori S, Trebuchon A, Carron R, Scavarda D, Milh M, McGonigal A, Bartolomei F. The repertoire of seizure onset patterns in human focal epilepsies: Determinants and prognostic values. *Epilepsia* 2019;60: 85-95.

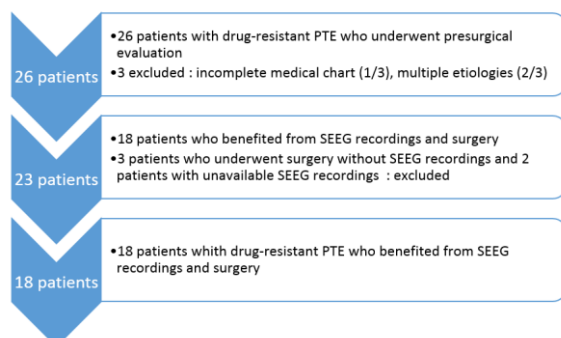


- [9] Gonzalez-Martinez J, Bulacio J, Alexopoulos A, Jehi L, Bingaman W, Najm I. Stereoelectroencephalography in the "difficult to localize" refractory focal epilepsy: early experience from a North American epilepsy center. *Epilepsia* 2013;54: 323-30.
- [10] Mathern GW, Babb TL, Vickrey BG, Melendez M, Pretorius JK. Traumatic compared to non-traumatic clinical-pathologic associations in temporal lobe epilepsy. *Epilepsy Res* 1994;19: 129-39.
- [11] Marks DA, Kim J, Spencer DD, Spencer SS. Seizure localization and pathology following head injury in patients with uncontrolled epilepsy. *Neurology* 1995;45: 2051-7.
- [12] Hartzfeld P, Elisevich K, Pace M, Smith B, Gutierrez JA. Characteristics and surgical outcomes for medial temporal post-traumatic epilepsy. *Br J Neurosurg* 2008;22: 224-30.
- [13] Hitti FL, Piazza M, Sinha S, Kvint S, Hudgins E, Baltuch G, Diaz-Arrastia R, Davis KA, Litt B, Lucas T, Chen HI. Surgical Outcomes in Post-Traumatic Epilepsy: A Single Institutional Experience. *Oper Neurosurg (Hagerstown)* 2020;18: 12-18.
- [14] Hakimian S, Kershenovich A, Miller JW, Ojemann JG, Hebb AO, D'Ambrosio R, Ojemann GA. Long-term outcome of extratemporal resection in posttraumatic epilepsy. *Neurosurg Focus* 2012;32: E10.
- [15] Kazemi NJ, So EL, Mosewich RK, O'Brien TJ, Cascino GD, Trenerry MR, Sharbrough FW. Resection of frontal encephalomalacias for intractable epilepsy: outcome and prognostic factors. *Epilepsia* 1997;38: 670-7.
- [16] Brady RD, Casillas-Espinosa PM, Agoston DV, Bertram EH, Kamnaksh A, Semple BD, Shultz SR. Modelling traumatic brain injury and posttraumatic epilepsy in rodents. *Neurobiol Dis* 2019;123: 8-19.
- [17] Isnard J, Taussig D, Bartolomei F, Bourdillon P, Catenoix H, Chassoux F, Chipaux M, Clemenceau S, Colnat-Coulbois S, Denuelle M, Derrey S, Devaux B, Dorfmüller G, Gilard V, Guenot M, Job-Chapron AS, Landre E, Lebas A, Maillard L, McGonigal A, Minotti L, Montavont A, Navarro V, Nica A, Reyns N, Scholly J, Sol JC, Szurhaj W, Trebuchon A, Tyvaert L, Valenti-Hirsch MP, Valton L, Vignal JP, Sauleau P. French guidelines on stereoelectroencephalography (SEEG). *Neurophysiol Clin* 2018;48: 5-13.
- [18] Lagarde S, Bonini F, McGonigal A, Chauvel P, Gavaret M, Scavarda D, Carron R, Regis J, Aubert S, Villeneuve N, Giusiano B, Figarella-Branger D, Trebuchon A, Bartolomei F. Seizure-onset patterns in focal cortical dysplasia and neurodevelopmental tumors: Relationship with surgical prognosis and neuropathologic subtypes. *Epilepsia* 2016;57: 1426-35.
- [19] Medina Villalon S, Paz R, Roehri N, Lagarde S, Pizzo F, Colombet B, Bartolomei F, Carron R, Benar CG. EpiTools, A software suite for presurgical brain mapping in epilepsy: Intracerebral EEG. *J Neurosci Methods* 2018;303: 7-15.
- [20] Bartolomei F, Chauvel P, Wendling F. Epileptogenicity of brain structures in human temporal lobe epilepsy: a quantified study from intracerebral EEG. *Brain* 2008;131: 1818-30.
- [21] Lagarde S, Roehri N, Lambert I, Trebuchon A, McGonigal A, Carron R, Scavarda D, Milh M, Pizzo F, Colombet B, Giusiano B, Medina Villalon S, Guye M, Benar CG, Bartolomei F. Interictal stereotactic-EEG functional connectivity in refractory focal epilepsies. *Brain* 2018;141: 2966-2980.
- [22] Aubert S, Wendling F, Regis J, McGonigal A, Figarella-Branger D, Peragut JC, Girard N, Chauvel P, Bartolomei F. Local and remote epileptogenicity in focal cortical dysplasias and neurodevelopmental tumours. *Brain* 2009;132: 3072-86.
- [23] Engel J, Jr. Update on surgical treatment of the epilepsies. Summary of the Second International Palm Desert Conference on the Surgical Treatment of the Epilepsies (1992). *Neurology* 1993;43: 1612-7.
- [24] Blumcke I, Spreafico R, Haaker G, Coras R, Kobow K, Bien CG, Pfafflin M, Elger C, Widman G, Schramm J, Becker A, Braun KP, Leijten F, Baayen JC, Aronica E, Chassoux F, Hamer H, Stefan H, Rössler K, Thom M, Walker MC, Sisodiya SM, Duncan JS, McEvoy AW, Pieper T, Holthausen H, Kudernatsch M, Meencke HJ, Kahane P, Schulze-Bonhage A, Zentner J, Heiland DH, Urbach H, Steinhoff BJ, Bast T, Tassi L, Lo Russo G, Ozkara C, Oz B, Krsek P, Vogelgesang S, Runge U, Lerche H, Weber Y, Honavar M, Pimentel J, Arzimanoglou A, Ulate-Campos A, Noachtar S, Hartl E, Schijns O, Guerrini R, Barba C, Jacques TS, Cross JH, Feucht M, Muhleberger A, Grunwald T, Trinka E, Winkler PA,

- Gil-Nagel A, Toledano Delgado R, Mayer T, Lutz M, Zountsas B, Garganis K, Rosenow F, Hermsen A, von Oertzen TJ, Diepgen TL, Avanzini G, Consortium E. Histopathological Findings in Brain Tissue Obtained during Epilepsy Surgery. *N Engl J Med* 2017;377: 1648-1656.
- [25] Gupta PK, Sayed N, Ding K, Agostini MA, Van Ness PC, Yablon S, Madden C, Mickey B, D'Ambrosio R, Diaz-Arrastia R. Subtypes of post-traumatic epilepsy: clinical, electrophysiological, and imaging features. *J Neurotrauma* 2014;31: 1439-43.
- [26] Neal A, Ostrowsky-Coste K, Jung J, Lagarde S, Maillard L, Kahane P, Touraine R, Catenoix H, Montavont A, Isnard J, Arzimanoglou A, Bartolomei F, Guenot M, Rheims S. Epileptogenicity in tuberous sclerosis complex: A stereoelectroencephalographic study. *Epilepsia* 2020;61: 81-95.
- [27] Schuh LA, Henry TR, Fromes G, Blaivas M, Ross DA, Drury I. Influence of head trauma on outcome following anterior temporal lobectomy. *Arch Neurol* 1998;55: 1325-8.
- [28] Cardinale F, Casaceli G, Raneri F, Miller J, Lo Russo G. Implantation of Stereoelectroencephalography Electrodes: A Systematic Review. *J Clin Neurophysiol* 2016;33: 490-502.

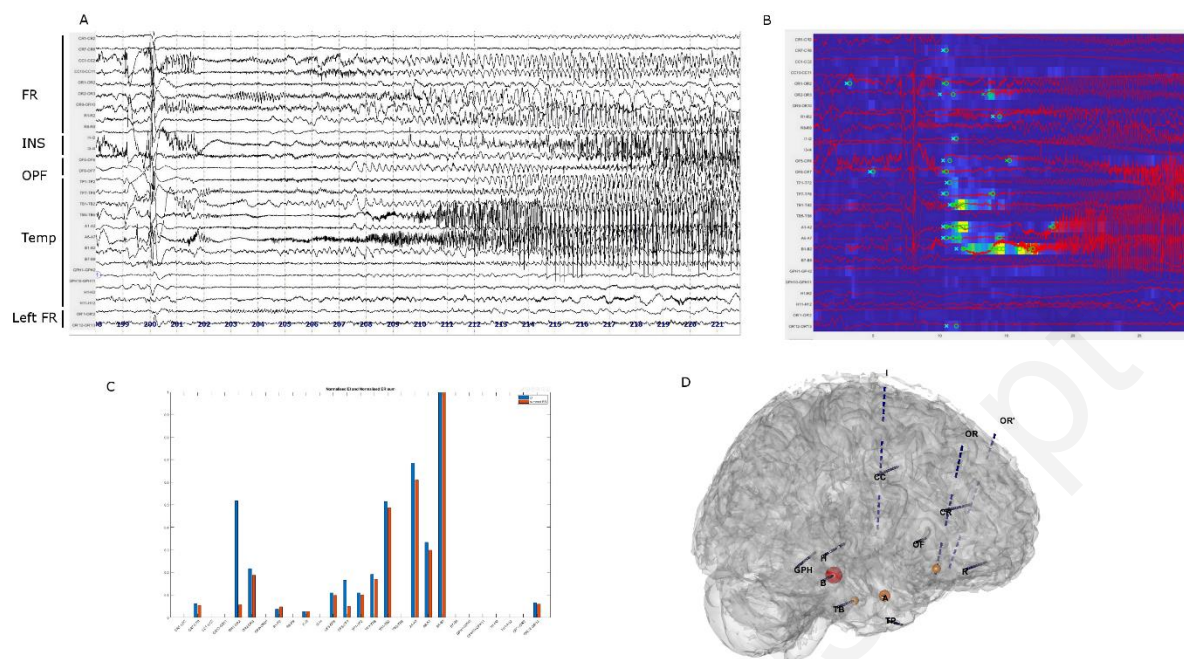
### **Legends of Tables and Figures**

**Figure 1. Flow chart of patient selection.** *PTE = post-traumatic epilepsy; SEEG = stereoelectroencephalography*



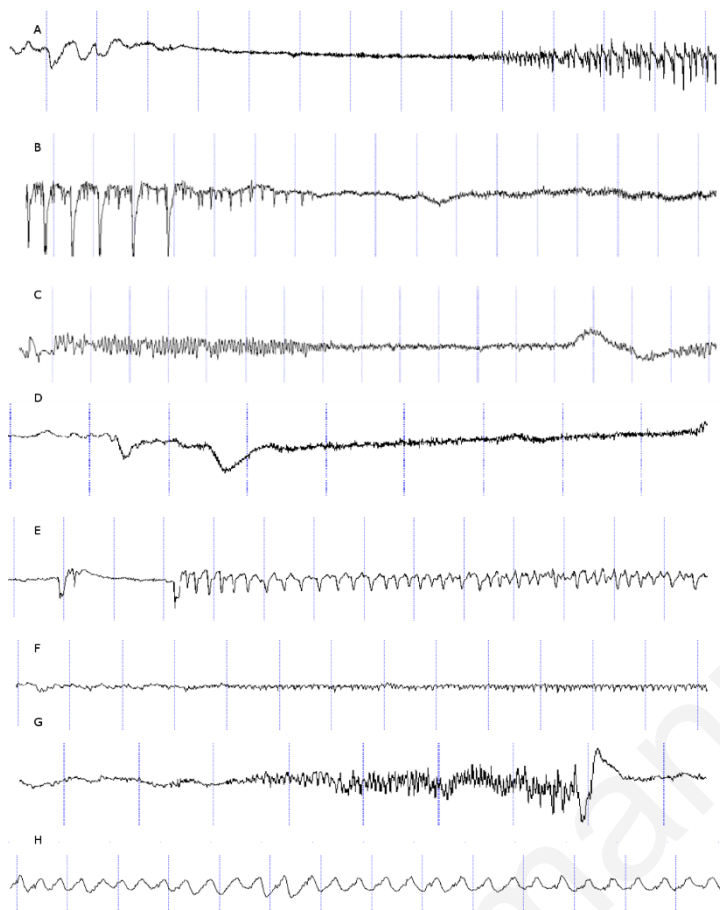
**Figure 2. Example of a seizure classified as “temporal plus” in terms of SOZ**

**localization.** A : SEEG recording of a seizure beginning from the right temporal and frontal lobes (temporal mesial and orbitofrontal) *FR = Right Frontal, INS = right insular, OPF = right frontal operculum, Temp = right temporal, Left FR = Left frontal* ; Electrode positions and names are visible on panel D. B : Epileptogenicity Index map showing the increase in energy ratio (blue to yellow scale) and the time of detection (circle – alarm time- and cross – detection time ) in each selected SEEG channel C : EI values displaying high epileptogenicity values ( $nEI \geq 0.4$ ) in the right mesial temporal and orbitofrontal sublobes ; D : 3D representation of the SEEG exploration; the balloons indicate the EI detections. Balloon color (from yellow to red) and dimension correspond to the EI value.



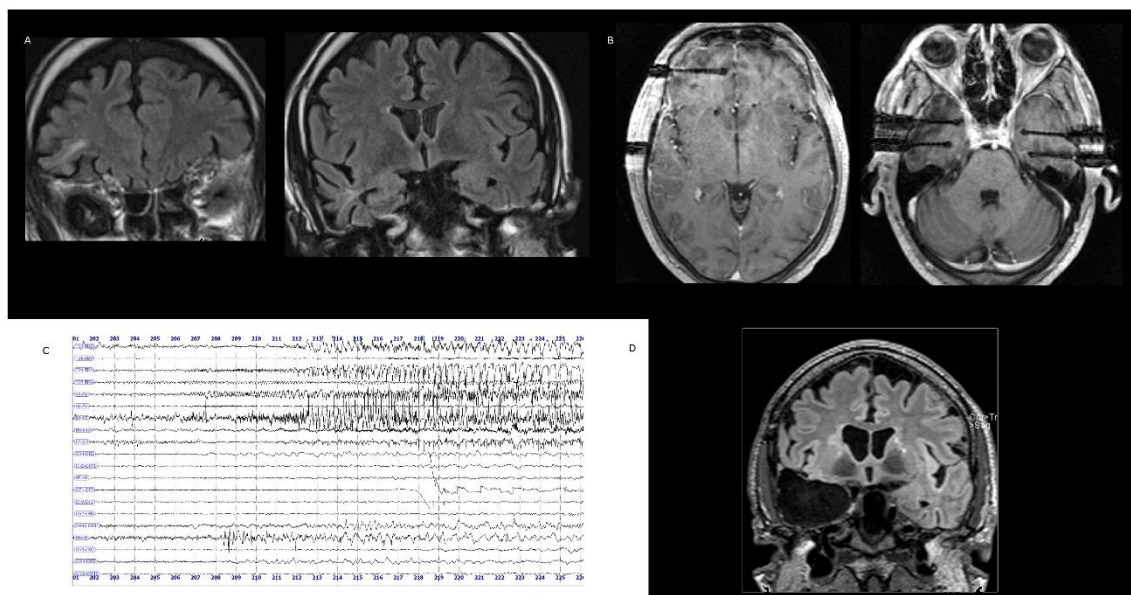
**Figure 3.**

**A/Examples of different categories of seizure-onset patterns (SOP):** Pattern A, Low voltage fast activity (LVFA); B, preictal spiking followed by LVFA; C, burst of polyspikes followed by LVFA; D, slow wave or baseline shift followed by LVFA; E, rhythmic slow spikes; F, sharp theta/alpha activity; G, beta sharp activity; H, delta-brush. **B/ Seizure onset zone (SOZ) and extension of post-traumatic MRI lesions:** *SOZ = lesion* indicates a good correspondence between MRI visible lesion and the SOZ; *SOZ > lesion* that SOZ is larger than the MRI lesions, *SOZ < lesions* indicates that the SOZ is smaller than the lesions and *SOZ ≠ lesions* means that the SOZ is located in other sublobe(s) than the one(s) involved by the lesion.



**Figure 4. Illustrative case of post-traumatic temporal lobe epilepsy in a patient with an extensive fronto-temporal lesion (patient 4).**

A: coronal slices of the pre-operative T2 FLAIR-weighted MRI showing the right frontal (lateral prefrontal) (left image) and the right temporal (polar atrophy and gliosis) (right image) post-traumatic lesions ; B: axial slices of a T2 FLAIR-weighted MRI showing the position of the frontal lesional (left image) and bi-temporal (right image) SEEG electrodes ; C: SEEG recording of a typical seizure, showing involvement of the temporo-polar electrodes but not the frontal lesional electrode (R 5-6) ; D : coronal slices of T2 FLAIR-weighted MRI after surgery (right temporal lobectomy).



**Table 1. Clinical, neuroradiological and surgical outcome in the studied population.** TBI: traumatic brain injury, SOZ: seizure onset zone determined on SEEG recordings, HS: hippocampal sclerosis, GK: Gamma Knife radiosurgery

**Table 2. Published surgical series on post-traumatic epilepsies.**

PTE = Post traumatic epilepsy ; TBI = traumatic brain injury ; vEEG = video-electroencephalography ; SEEG = stereoelectroencephalography ; TLE = Temporal lobe epilepsy ; MTLE = Mesial temporal lobe epilepsy ; MTS = mesio-temporal sclerosis ; ATL = anterior temporal lobectomy ; FLE = frontal lobe epilepsy ; EcoG = electrocorticography ; PLE = parietal lobe epilepsy ; OLE = occipital lobe epilepsy ; VNS = vagal nerve stimulation ; RNS = responsive neurostimulation

**Table 1**

Accepted manuscript

Patient	Age at TBI	Age at epilepsy onset	Localization of the MRI post-traumatic lesions	Localization of the SOZ	SOZ organization	Surgery	Complete removal of MRI lesion	Complete removal of SOZ	Outcome 23
1	16	16	Right Temporal (mesio-lateral)	Temporal (right temporal, mesial and lateral)	Network	right lateral temporal cortectomy	N	N	Engel I
2	23	23	Right fronto-temporal (lateral)	Temporal (right temporal lateral)	Focal	right temporal cortectomy (internal pole, hippocampus and T1)	N	Y	N/A
3	8	9	Bilateral fronto-temporal	Frontal (right central and premotor)	Network	right frontal cortectomy (precentral)	N	Y	Engel III
4	15	15	Right fronto-temporal (lateral)	Temporal (right temporal lateral)	Focal	right temporal cortectomy (pole, hippocampus, T1)	N	Y	Engel I
5	24	28	Left frontal	Temporal plus (left prefrontal, left temporal, mesial and lateral)	Network	left temporal lobectomy (lateral, amygdala, hippocampus)	N	N	Engel IV
6	29	40	Right temporal (lateral, insular)	Temporal plus (right temporal mesial, orbitofrontal)	Network	Right temporo-frontal cortectomy (LTA and orbitofrontal)	Y	Y	Engel I
7	12	12	Left frontal (basal)	Frontal (left orbitofrontal, prefrontal mesial)	Network	Left frontal cortectomy (orbitofrontal, anterior cingulate gyrus, anterior corpus callosum)	Y	Y	Engel I
8	5	5	Left frontal (lateral)	Frontal (left prefrontal lateral, premotor)	Network	left frontal cortectomy (premotor)	N	N	Engel III
9	21	30	Right fronto-temporal (anterior)	Temporal plus (left temporal mesial, right temporal mesial, right insular, right orbitofrontal)	Network	N (bilateral SOZ)	N/A	N/A	N/A
10	20	24	Right temporal (lateral and posterior)	Temporal plus (bilateral temporal mesial)	Network	N (bilateral SOZ)	N/A	N/A	N/A
11	15	15	Left temporal (mesial and anterior)	Temporal plus (left prefrontal mesial, left temporal lateral)	Network	N (refused)	N/A	N/A	N/A
12	4	7	Bilateral frontal (basal), right temporal (mesial ; HS)	Temporal (right temporal mesial)	Focal	Right anterior temporal lobectomy	Y	Y	Engel I
13	27	27	Bilateral frontal, left temporal (mesial ; HS)	Temporal (left temporal mesial)	Focal	Left anterior temporal lobectomy	N	Y	Engel III
14	20	26	Right frontal (basal), right temporal (mesio-lateral), left temporal (pole)	Temporal plus (left temporal mesial, right temporal lateral)	Network	N (bilateral SOZ)	N/A	N/A	N/A
15	10	11	Right frontal (large, lateral and pole), right temporal (pole), left frontal (anterior)	Frontal (right precentral)	Focal	right frontal cortectomy (precentral)	N	N (functional risk)	N/A (death)
16	22	23	Left temporal (mesio-lateral ; HS)	Temporal (left temporal mesial)	Focal	Left anterior temporal lobectomy	Y	Y	Engel I
17	24	38	Left temporal (lateral)	Temporal (left temporal mesial)	Focal	Left selective amygdalo-hippocampectomy (GK)	N	Y	Engel I
18	25	25	Left temporal (pole, mesial ; HS)	Temporal (left temporal lateral)	Focal	Left temporal polar cortectomy	N	Y	Engel I



Table 2

Authors and date	Number of patients	Material/method	Population characteristics	Epilepsy type	Surgery	Outcome
<b>Mathern et al, 1994<sup>9</sup></b>	26	Clinical and histopathological findings; no vEEG or intracranial recordings Comparison with non PT-TLE (94)	-Age : 0,2-29 years -TBI classification : 15/26 severe, 6/26 moderate, 5/26 mild	TLE	Not detailed	Better outcome in post-traumatic TLE (80% Engel I) than TLE post birth brain injury (18% Engel I)
<b>Marks et al, 1995<sup>10</sup></b>	25	Presurgical assessment of refractory epilepsy, using vEEG in 25/25 and intracranial EEG in 21/25 (grids/strips mainly, depth electrodes only for MTLE)	-Mean age at TBI : 10.7 years -Mean age at epilepsy onset : 13,6 years	- MTLE E 17/2 5 - "Neocortical" epilepsy 8/25	-MTLE : 14/17 ATL -Neocortical epilepsy : 3/8 neocortical cortexotomy (2/3 partial frontal cortexotomy + callosotomy, 1/3 occipital cortexotomy) ; 5/17 contraindicated	-MTLE : - 6/14 (42,8%) : seizure free, 5/6 with MTS - 7/14 (50%) : no seizure improvement (no MTS) - 1/14 (7,2%) : 50% reduction of seizures (no MTS) -Neocortical epilepsy : 3/3 seizure-free
<b>Kazemi et al, 1997<sup>14</sup></b>	17	Presurgical assessment of refractory epilepsy, using vEEG and per-operative EcoG	- Post-traumatic encephalomalacia 8/17 -Others 9/17	FLE	Tailored frontal cortexotomy (guided by MRI lesion findings) in all patients	Engel I 59%, Engel II 11,5% <i>Better outcome with complete resection of the encephalomalacia (71% Engel I vs 0% Engel I)</i>
<b>Schuh et al, 1998<sup>26</sup></b>	29	-Presurgical assessment of refractory TLE, using intracranial EEG monitoring (depth electrodes or grids) in only 34/102 patients -Include only operated patients (anterior TL) - Comparison with non PT MTLE (93)	-Mean age at epilepsy onset : 12.1-14.9 years -Mean age at surgery : 31.9-34.2 years	MTLE	ATL in all post-traumatic MTLE	Poorer outcome in post-traumatic MTLE (40% Engel I) vs no history of head trauma (50-69% Engel I)
<b>Diaz Arrastia et al, 2000<sup>8</sup></b>	33	Presurgical assessment of refractory epilepsy with vEEG in 23/33 patients who had refractory PTE	-PT Epilepsy -Mean age at TBI 22.9 years old -Mean time between	MTLE E 8/23	ATL 2/8	Engel I 50%, Engel II 50%

		TBI and epilepsy onset : 1.6 years				
<b>Hartzfield et al, 2008<sup>11</sup></b>	57	-Presurgical assessment of refractory PTE, using vEEG and per-operative EcoG -Inclusion of operated patients	-Mean age at resection 36years -Average duration of epilepsy 18 years -MRI findings : 16 /57 MTS ; other 26/57 : gliosis (mostly in frontal lobes), focal atrophy, encephalomalacia ; -- 15/57 patients with normal MRI	- MTL E 30/57 - Extrahippocampal resection 20/57 - VNS 7/57 Extra hippocampal resection 27/57	<u>PTE group</u> : - Medial temporal resection 30/57, with MTS in 53% - Extrahippocampal resection 20/57 - VNS 7/57 <u>Non-PTE group</u> : 31/31 with mesial temporal lobe resection	PTE group : - Medial temporal lobe resection : Engel I 63%, Engel II 10%, - Extrahippocampal resections : Engel I 30%, Engel II 25%, - no statistical difference between PTE and non-PTE patients
<b>Hakimiane et al, 2012<sup>13</sup></b>	21	-Presurgical assessment of refractory epilepsy with vEEG in 21/21, and intracranial recordings in 16/21 (mainly grids/strips) -Only patients with extra-temporal refractory PTE	-Mean age at TBI 15,7years -Mean age at surgery : 34,7 years -Mean age at epilepsy onset : 15,7 years Severity of TBI : 8/21 mild, 12/21 moderate to severe ; one had both type of severity -MRI findings : encephalomalacia 12/21	-FLE 12/2 1 - Frontal plus epilepsy : 6/21 - "Posterior epilepsy : 3/21	-Frontal lobectomy 12/21 -Frontal and temporal lobectomy 6/21 Posterior neocortical resection (parietal, posterior temporo-occipital and temporo-parietal) resections 3/21	-Overall : Engel I 28%, Engel II 57%, -Risk factors of worst outcomes : MRI-negative PTE, no invasive monitoring assessment, resection in the dominant hemisphere

<b>Gupta et al, 2014</b> <sup>24</sup>	123	Presurgical assessment of refractory epilepsy with vEEG in 21/21, and intracranial recordings in 16/21 (mainly grids/strips)	-Mean age at TBI : 20years -Mean age at epilepsy onset : 23,1years	FLE 22/123 (procedures not detailed) ; mostly TLE (with a majority of MTS), others are FLE 40/1 23 (32/4 0 lesio nal) TLE 66/1 23 (46/6 6 lesio nal, 29/4 MTS ) PLE : 4/12 3 (3/4 lesio nal) OLE : 4/12 3 (3/4 lesio nal) Mult ifoca l : 1/12 3	22/123 (procedures not detailed) ; mostly TLE (with a majority of MTS), others are FLE	-TLE : Engel I 69%, Engel II 19%, -FLE : Engel I 33%, Engel II 17%,,
<b>Hitti et al, 2019</b> <sup>12</sup>	23	Presurgical assessment of refractory epilepsy with vEEG in 23/23, and intracranial recordings in 8/23	-Mean age : 38 years -TBI classification : 60,9% moderate to severe, 30,1% mild	MTL E 19/2 3, all with MTS Neoc	ATL: 14 Tailored cortectomy: 2 VNS implantation 7 (multiple foci)	_Resection group : Engel I 68,8%, Engel II 18,8%, -VNS group : average seizure frequency reduction 30,6%, leading to RNS 3/7 RNS implantation in 3/3 with more than 50% of seizure reduction

---

ortic  
al  
epile  
psy  
4/23

---

Accepted manuscript

Accepted manuscript