



HAL
open science

Subcutaneous Implantable Cardioverter-Defibrillator Lead Extraction First Multicenter French Experience

Nathalie Behar, Vincent Galand, Raphael P Martins, Peggy Jacon, Nicolas Badenco, Hugues Blangy, Christine Alonso, Benoît Guy-Moyat, Rim El Bouazzaoui, Alain Lebon, et al.

► **To cite this version:**

Nathalie Behar, Vincent Galand, Raphael P Martins, Peggy Jacon, Nicolas Badenco, et al.. Subcutaneous Implantable Cardioverter-Defibrillator Lead Extraction First Multicenter French Experience. *JACC: Clinical Electrophysiology*, 2020, 6 (7), pp.863-870. 10.1016/j.jacep.2020.04.012 . hal-02929476

HAL Id: hal-02929476

<https://hal.science/hal-02929476>

Submitted on 22 Aug 2022

HAL is a multi-disciplinary open access archive for the deposit and dissemination of scientific research documents, whether they are published or not. The documents may come from teaching and research institutions in France or abroad, or from public or private research centers.

L'archive ouverte pluridisciplinaire **HAL**, est destinée au dépôt et à la diffusion de documents scientifiques de niveau recherche, publiés ou non, émanant des établissements d'enseignement et de recherche français ou étrangers, des laboratoires publics ou privés.



Distributed under a Creative Commons Attribution - NonCommercial 4.0 International License

SUBCUTANEOUS ICD LEAD EXTRACTION: FIRST MULTICENTER FRENCH EXPERIENCE

Nathalie Behar, MD^{1,2,3}, Vincent Galand, MD^{1,2,3}, Raphaël P. Martins, MD, PhD^{1,2,3}, Peggy Jacon, MD⁴, Nicolas Badenco, MD⁵, Hugues Blangy, MD⁶, Christine Alonso, MD⁷, Benoit Guy-Moyat, MD⁸, Rim El Bouazzaoui, MD⁹, Alain Lebon, MD¹⁰, Cédric Giraudeau, MD¹¹, Christelle Marquie, MD¹², Christophe Leclercq, MD, PhD^{1,2,3}

Working group address:

1 CHU Rennes, Service de Cardiologie et Maladies Vasculaires, Rennes, F-35000, France

2 Université de Rennes 1, CIC-IT 1414, F-35000, France

3 INSERM, U1099, Rennes, F-35000, France

4 Cardiology Department- University Hospital of Grenoble Alpes, CS 10217, 38043, Grenoble Cedex 9, France

5. APHP, Hôpital Pitié Salpêtrière, Paris, France

6. CHRU Nancy, département de cardiologie, VANDOEUVRE, 54511, France

7. Ambroise-Paré hospital, 92200 Neuilly-sur-Seine, France.

8. CHU Dupuytren, service de cardiologie, LIMOGES, 87042, France

9. University Hospital of Montpellier, CHU de Montpellier, 34000

10. Saint Martin private hospital center, Caen, France

11. Pôle santé Oreliance, Saran 45770, France

12. CHU Lille, Hopital Cardiologique 2 avenue Oscar Lambret, 59000 Lille, France.

Corresponding author: Nathalie Behar, Service de Cardiologie et Maladies Vasculaires, CHU de Rennes, 2 rue Henri Le Guilloux, 35000 Rennes, France. Tel: + 33 299 282 525, Fax: +33 299 282 529, email : nathalie.behar@chu-rennes.fr

Disclosures: none

ABSTRACT

Aims. Subcutaneous ICD (S-ICD) has been developed to limit lead-related complications inherent to transvenous ICD devices. To date, no study has specifically investigated the safety and feasibility of S-ICD lead extraction procedures.

Methods. Patients requiring S-ICD lead extraction between February 1st 2014 and February 28th 2019 were retrospectively included in 10 centers. The primary endpoint of the study was procedural success, defined as the removal of all the lead and lead material from the subcutaneous space. Secondary endpoints included procedural complications, and the need for specific extraction tools.

Results. S-ICD lead extraction procedures were performed in 32 patients (mean age 45.7 ± 13.8 years, 75.0% males, 65.6% in primary prevention). The median time from S-ICD lead implantation was 9.3 (5.4-17.5) months. The primary endpoint, i.e. complete removal of the material, was achieved in 96.9% of the patients, and only 1 procedural failure occurred (3.1%). Simple traction of the S-ICD lead was successful in 19 patients (59.4%), while 3 patients (9.4%) needed an additional incision and 9 patients (28.1%) required mechanical sheath to remove lead adhesions around the coil. No procedure related complication occurred. Patients with successful simple traction extraction were implanted more recently 7.1 (2.8-12.2) vs 16.5 (7.5-20.8) months ($p=0.04$) and had less prior history of sternotomy (2 (10.5%) vs 5 (38.5%) patients, $p=0.09$).

Conclusion. S-ICD lead extraction is an efficient and safe procedure, but may require some specific tools like mechanical sheath, specifically when fibrotic adhesions developed around the parasternal coil.

Keywords: Subcutaneous ICD; lead extraction; mechanical sheath

CONDENSED ABSTRACT

The present study investigated the safety and feasibility of Subcutaneous ICD lead extraction procedures performed in 32 patients (mean age 45.7 ± 13.8 years, 75.0% males). The primary endpoint, i.e. complete removal of the material, was achieved in 96.9% of the patients. No procedure related complication occurred.

Key words: Subcutaneous ICD, mechanical sheath, lead extraction

ABBREVIATIONS

ICD: implantable cardioverter defibrillator

TLE: transvenous lead extraction

S-ICD: Subcutaneous ICD

CRT: cardiac resynchronization therapy

SQC: subcutaneous defibrillator shocking coil

INTRODUCTION

Implantable cardioverter-defibrillator (ICD) is a well-established therapy to prevent sudden cardiac death in primary or secondary prevention. (1,2) However, ICD is associated with short and long-term complications, essentially due to the transvenous lead, like endocarditis, or lead dysfunction (3,4). Transvenous lead extraction (TLE) techniques have been described using a stepwise approach and are now facilitated by the availability of a large number of extraction tools, making the procedure more successful and safe (5), although TLE remains a procedure with a non-negligible rate of both minor and major complications. (6)

Subcutaneous ICD (S-ICD) has been developed to limit lead-related complications, particularly in young patients with an expected longer lifetime with ICD therapy. (7,8) Along with growing experience using S-ICD therapy, complications have been reported sometimes necessitating the subcutaneous lead to be repositioned or removed. (9)

Although S-ICD lead extraction procedure is expected to be safer and less challenging than TLE procedure, no study has investigated its safety and feasibility thus far. Thus, the aim of this multicenter study was to characterize efficacy and safety of S-ICD lead extraction procedures

METHODS

STUDY POPULATION. This study is a retrospective multicenter observational study of patients referred for S-ICD lead extraction with or without generator removal in 10 centers. All the patients requiring S-ICD lead extraction with or without generator removal between February 1st 2014 and February 28th 2019 were included. The study was approved by local ethics committee and all patients gave their informed consent to participate.

BASELINE ASSESSMENT. Baseline data, including demographic characteristics and data from the initial S-ICD implantation were collected in a French prospective registry. Data regarding the extraction procedure were collected retrospectively from hospital medical charts for all enrolled patients.

PROCEDURAL CHARACTERISTICS. S-ICD lead extraction procedures were performed in the EP lab or the operating room of each center under general anesthesia. After skin preparation, pulse generator pocket was opened to release the lead from the can. Then, the xiphoidal wound (left or right depending of initial electrode implantation side) was opened and the sleeve suture removed. The proximal part of the lead (between the can and the xiphoidal wound) was released by simple manual traction through the parasternal tunnelization. A third incision was performed to release the distal lead suture if a 3-incisions technique was used during the initial implantation. Then, parasternal tunnelization was approached. First, a simple manual traction on the S-ICD lead was. If unsuccessful, other tools were used at physician discretion (mechanical sheath, additional incisions...).

STUDY END POINTS. The primary endpoint of the study was the rate of procedural success defined as removal of all the lead and lead material from the subcutaneous space. Secondary endpoints included procedural complications and the need for specific lead extraction tools. Two groups were then defined and compared according to the S-ICD lead extraction technique: patients with successful S-ICD lead extraction using simple traction of the lead (simple traction group) and patients requiring additional tools: additional incisions, specific tools (unsuccessful simple traction group).

STATISTICAL ANALYSIS. Qualitative variables are summarized with frequencies (percentage); continuous data as mean \pm standard deviation or median (interquartile range) depending on their distribution, which was assessed using the Kolmogorov-Smirnov test. Categorical variables were compared using the χ^2 tests or Fisher's exact test. Continuous variables were compared using Student's *t*-test or the Mann-Whitney U-test for two-group comparisons. A p-value <0.05 was considered statistically significant. The analyses were performed with the SPSS statistical package, version 11.0 (SPSS Inc., Chicago, IL.)

RESULTS

BASELINE CHARACTERISTICS. During the study period, a total of 1011 S-ICD were implanted in 10 French centers. Among these patients, 32 patients (3.2%) required S-ICD lead extraction.

Patients' characteristics and data from the initial S-ICD implantation are summarized in table

1. Mean age of the overall population was 45.7 ± 13.8 years with a majority of males (75.0%). The S-ICD was mainly implanted in primary prevention (65.6%).

Implanted devices were primarily Boston Emblem S-ICD A209 with a 3401 lead (n=28, 87.5%) while there were 3 first generation Cameron SQ-RX with a Qtrack lead (9.4%) and 1 Boston Emblem S-ICD A219 with a 3501 lead (3.1%). The generator was positioned in an intermuscular, subcutaneous, and sub muscular pocket in 25 (78.1%), 4 (12.5%) and 3 (9.4%) of cases, respectively. Twenty-six leads were placed in a left parasternal position (81.2%). Most of the patients only had 2 incisions during the initial implantation while a three incisions-implantation technique was performed in 6 cases (18.8%). Of note, a total of 7 patients had a history of sternotomy (6 prior and 1 after S-ICD implantation, respectively).

S-ICD LEAD EXTRACTION PROCEDURE. The characteristics of S-ICD lead extraction procedures are summarized in table 2. A total of 32 leads were extracted. The median delay from S-ICD lead implantation to extraction was 9.3 (5.4-17.5) months. Indications for S-ICD lead extraction procedures were device infection for 9 patients (28.1%) (i.e. whole device infection (n=4); sleeve infection (n=3) and generator pocket infection (n=2)), heart transplantation for 7 patients (21.9%), a problem with the sensing vectors with or without inappropriate shock for 5 patients (15.6%), the need for a conventional transvenous ICD/resynchronization therapy for 5 patients (15.6%: 4 for antitachycardia pacing and 1 for cardiac resynchronization therapy (CRT)), lead dislodgement for 4 patients (12.5%), and a technical issue in 2 patients (6.3%: 1 premature battery depletion and 1 abnormal lead impedance) (Figure 1). Interestingly, S-ICD extraction for device infection or heart transplantation tended to occur earlier than extractions for sensing vector or technical issues (Figure 2).

The stepwise approach for S-ICD lead procedure is summarized in figure 2. First, a generator pocket incision was performed, and lead removed from the can. Then, the xiphoidal wound (left or right) was opened and a simple traction of the lead was performed to remove the lead from the generator pocket to the xiphoidal wound. In all cases (n=32), this first step was straightforward and the horizontal portion of the lead was easily removed. Then, the parasternal tunnelization was approached. For patients with a 3-incisions' technique at the initial S-ICD implantation (n=6), the superior parasternal wound was opened and the suture at the tip electrode was released. For 19 patients (59.4%), a simple traction on the lead permitted a complete S-ICD lead extraction. One patient had a sternotomy for heart transplantation after S-ICD implantation, and during the surgery, the lead was inadvertently trapped into a sternotomy wire. The subsequent extraction procedure was a failure since the lead could definitely not be extracted. Three patients (9.4%) needed an extra superior parasternal incision

to allow a forward and backward movement to release S-ICD lead from parasternal adhesions. For the last 9 patients (28.1%), some specific tools were required to remove the lead adhesions around the coil. These tools were passive mechanical sheath used for TLE: regular Byrd dilatator sheath (Cook Intravascular Inc, Leechburg, PA, USA) for 8 patients and Visisheath S (Spectranetics, Colorado Springs, CO, USA) for 1 patient. The dilatator sheath was placed around the S-ICD lead and was pushed forward while a gentle counter-traction was performed on the lead (CENTRAL ILLUSTRATION). Eventually, S-ICD lead extraction procedure was completely successful in 31 (96.9%) patients. No procedure related complication was reported.

Table 3 summarized the comparison between the simple traction and unsuccessful simple traction groups. Both groups were similar regarding age, male gender, technique of the initial S-ICD implantation (number of incisions and S-ICD lead position). The S-ICD leads were older in the unsuccessful simple traction group compared to simple traction group with a median delay from implant 7.1 (2.8-12.2) vs 16.5 (7.5-20.8) months ($p=0.04$). Patients with a previous median sternotomy tended to be more prevalent in the unsuccessful simple traction group (5 (38.5%) vs 2 (10.5%) patients, $p=0.09$).

MANAGEMENT AFTER S-ICD LEAD EXTRACTION. Among the study population 14 patients underwent an immediate reimplantation at the time of extraction: 7 were implanted with a transvenous ICD while 7 received a new S-ICD (including 2 patients for whom the parasternal side of tunnelization was changed). In the remaining 18 patients, 8 previously infected patients were lately implanted with a new device (including 5 transvenous ICD and 3 S-ICD), and 10 patients did not receive any new device. Indeed, 7 patients had a heart transplantation and 3 patients with infected devices either did not meet an indication for ICD implantation or did not consent to ICD reimplantation despite a guideline indication.

DISCUSSION

MAIN FINDINGS. To the best of our knowledge, the present study is the first multicenter observational study to specifically investigate S-ICD lead extraction procedures. The main results of the study are: 1) A simple traction of the S-ICD lead through the xiphoidal incision is sufficient to remove the lead in up to 60% of the patients; 2) In one third of the procedures, mechanical sheaths are required to remove fibrotic adhesions around the coil; 3) A stepwise approach results in a very high success rate of extraction, and only external factors were responsible for extraction failure in our study (S-ICD lead tighten in sternotomy steel wires); 4) The procedure is safe and no procedure related complication occurred.

ICD LEAD EXTRACTION. With 50 years of experience, a stepwise approach is used for TLE extraction, starting with simple traction, followed by the use of non-powered tools and eventually powered tools or femoral approach (5). A recent review demonstrated that such a stepwise approach can reach a clinical success extraction rate of 100% (10). Simple manual traction is often effective to remove leads implanted in the previous 12 months, but often not-sufficient to remove chronically implanted leads and additional extraction tools are often needed. According to Buiten et al, TLE clinical success is reached in only 32% of leads with simple traction, 44% with a locking stylet, 71% with a mechanical dilatator and 97% when a femoral approach is attempted (10). Regarding the use of powered sheath, TLE clinical success is reported in 95% of patients when a Laser sheath is used (10) and 95 to 100% when rotating mechanical sheath is used (11,12)

TLE is a safe procedure in most cases, but still carries a significant risk of extraction failure and also a non-negligible risk of mortality, mostly related to tearing of the great vessels and cardiac structures (13). Lastly, indications for TLE are mostly infectious and especially

endocarditis. Indeed, in the ELECTRA registry, non-infectious indications represented 47% of procedures while in the present study, non-infectious indications represented 71.9% of procedures (14).

SPECIFIC ISSUES RELATED TO S-ICD EXTRACTION. In some cases, fibrosis can develop around ICD leads, mainly at the parasternal site around the coil avoiding the extraction of S-ICD lead by a simple traction through the xiphoidal incision. In the present study, as no specific approach for S-ICD lead extraction was recommended at the time of the procedure, several approaches were attempted by operators. The most efficient and less aggressive one was the use of a non-powered mechanical sheath to release the fibrotic adherences around the coil at the parasternal site. This mechanical approach should be attempted before performing additional incisions. The only procedural failure was the consequence of a particular condition, i.e. the S-ICD lead blocked into steel sternotomy wires. Such situation could be easily avoided by removing the S-ICD during the heart transplant procedure.

Nakhla et al reported their experience on removal of subcutaneous defibrillator shocking coil (SQC) in 21 patients (15). The median age of SQC was 177 days. One device extraction was performed surgically while 20 were completed percutaneously, 3 of the patients requiring additional incisions and 1 the use of a laser sheath. There was no procedural complication. Ip reported in a case report (16) an S-ICD lead extraction procedure in a 72-years-old patient, performed 1059 days after implantation. The author described a technique similar to the one used in the present study, with a Byrd dilatator sheath used to disrupt fibrotic adhesions along the coil. During the 6-years of follow-up in the initial Dutch S-ICD cohort including 118 patients (17), some data regarding S-ICD extraction were provided: the S-ICD was extracted in 10 patients (8%), 8 of which as a consequence of device infection. As in the present study,

the procedure did not result in any complication. Theuns et al (18) reported the long-term follow-up of the European regulatory trial cohort consisting in 55 patients with a median 5.8 years follow-up. Five patients (9%) were explanted: 1 for infection and 4 for transvenous ICD implantation. In the EFFORTLESS registry (19), 10 (1.0%) patients required an S-ICD extraction for a transvenous ICD implantation and 24 (2.4%) patients for device infection. However, in all the studies reported above, no data were provided regarding the S-ICD extraction procedure per-se.

In our study, those leads extracted by a simple traction were implanted more recently than those requiring mechanical sheaths. Similar results were observed for transvenous leads (20). Indeed, fibrotic adhesions may increase with the age of the S-ICD lead. Fibrotic adherences were mostly located around the coil lead, in the para-sternal area. Conversely, there was no fibrosis around the proximal part of S-ICD lead (i.e in the left subcutaneous latero-thoracic area). Indeed, operators did not experience any issue to remove the proximal portion of the lead, while every lead extraction failure was related to the para-sternal lead location.

Furthermore, more than one-third of the patients requiring mechanical tools for lead extraction had a history of median sternotomy, which may represent a potential factor increasing local fibrosis due to scar tissue formation and hampering an easy extraction of the lead. As previously explained, one patient had a sternotomy for heart transplantation after S-ICD implantation, during which the lead was inadvertently trapped into a sternotomy wire. The subsequent extraction procedure failed. Such patients should be carefully managed by cardiac surgeons and the para-sternal lead removed at the time of heart transplant. Further studies, including a larger number of patients, are warranted to precisely determine the predictors of challenging or failed procedures. Nevertheless, it seems crucial that such procedures should be performed by experienced operators since they may require dedicated extraction tools and appropriate skills.

LIMITATIONS. We acknowledge some limitations in the present study. First, the analysis was performed as a retrospective review of a cohort of patients requiring S-ICD lead extraction procedure.

The main limitation of this study is the relatively small sample size despite being the only and largest reported, considering the rare incidence of S-ICD lead extraction.

Furthermore, the median delay from S-ICD lead implantation was 9.3 (5.4-17.5) months, which may sound relatively short, but is a consequence of the recent availability of S-ICDs.

Additionally, S-ICD recipients are different than those patients implanted with transvenous ICD leads; consequently, risk factors for complications or failed extraction are probably different, and further studies will be required to better define this specific population, complications and risk factors.

Lastly, no data has been published so far regarding older S-ICD leads (i.e. implanted over than 5 years) and new technical problems may emerge, requiring specific technics or tools for complete removal of the material.

CONCLUSION

S-ICD lead extraction is an efficient and safe procedure when using a stepwise strategy. A simple traction of the lead through the xiphoidal incision is sufficient to remove the lead in up to 60% of the cases but may require some specific tools like mechanical sheath when fibrotic adhesions are present around the parasternal coil. Further studies are needed to prospectively assess the factors resulting in more challenging procedures and the efficacy of such stepwise strategy in older S-ICD leads.

PERSPECTIVES:

COMPETENCY IN PATIENT CARE AND PROCEDURAL SKILLS: It is the first multicenter observational study to specifically investigate S-ICD lead extraction procedures. A simple traction of the S-ICD lead through the xiphoidal incision is sufficient to remove the lead in up to 60% of the patients. In one third of the procedures, mechanical sheaths are required to remove fibrotic adhesions around the coil. A stepwise approach results in a very high success rate of extraction. The procedure is safe and no procedure related complication occurred.

TRANSLATIONAL OUTLOOK: Further studies are needed to prospectively assess the factors resulting in more challenging procedures and the efficacy of such stepwise strategy in older S-ICD leads.

REFERENCES:

1. Moss AJ, Zareba W, Hall WJ, Klein H, Wilber DJ, Cannom DS et al; Multicenter Automatic Defibrillator Implantation Trial II Investigators. Prophylactic implantation of a defibrillator in patients with myocardial infarction and reduced ejection fraction. *N Engl J Med.* 2002; 346: 877-83.
2. Theuns DA, Smith T, Hunink MG, Bardy GH, Jordaens L. Effectiveness of prophylactic implantation of cardioverter-defibrillators without cardiac resynchronization therapy in patients with ischaemic or non-ischaemic heart disease: a systematic review and meta-analysis. *Europace.* 2010; 12: 1564-70.
3. Sacher F, Probst V, Maury P, Babuty D, Mansourati J, Komatsu Y, et al. Outcome after implantation of a cardioverter-defibrillator in patients with Brugada syndrome: a multicenter study-part 2. *Circulation.* 2013; 128: 1739-47.
4. Olde Nordkamp LR, Postema PG, Knops RE, van Dijk N, Limpens J, Wilde AA, et al. Implantable cardioverter-defibrillator harm in young patients with inherited arrhythmia syndromes: A systematic review and meta-analysis of inappropriate shocks and complications. *Heart Rhythm.* 2016; 13: 443-54.
5. Kusumoto FM, Schoenfeld MH, Wilkoff BL, Berul CI, Birgersdotter-Green UM, Carrillo R, et al. 2017 HRS expert consensus statement on cardiovascular implantable electronic device lead management and extraction. *Heart Rhythm.* 2017; 14: e503-e551.
6. Hauser RG, Katsiyannis WT, Gornick CC, Almquist AK, Kallinen LM. Deaths and cardiovascular injuries due to device-assisted implantable cardioverter-defibrillator and pacemaker lead extraction. *Europace.* 2010; 12: 395-401.
7. Bardy GH, Smith WM, Hood MA, Crozier IG, Melton IC, Jordaens L, et al. An entirely subcutaneous implantable cardioverter-defibrillator. *N Engl J Med.* 2010; 363: 36-44.

8. Burke MC, Gold MR, Knight BP, Barr CS, Theuns DAMJ, Boersma LVA, et al. Safety and Efficacy of the Totally Subcutaneous Implantable Defibrillator: 2-Year Results From a Pooled Analysis of the IDE Study and EFFORTLESS Registry. *J Am Coll Cardiol.* 2015; 65: 1605-1615.
9. Calvagna GM, Ceresa F, Patanè S. Pocket infection as a complication of a subcutaneous implantable cardioverter-defibrillator. *Int J Cardiol.* 2014; 177: 616-8.
10. Buiten MS, Van der Heijden AC, Schalijs MJ, Van Erven L. How adequate are the current methods of lead extraction? A review of the efficiency and safety of transvenous lead extraction methods. *Europace.* 2015; 17: 689-700.
11. Aytemir K, Yorgun H, Canpolat U, Şahiner ML, Kaya EB, Evranos B, et al. Initial experience with the TightRail™ Rotating Mechanical Dilator Sheath for transvenous lead extraction. *Europace* 2016; 18: 1043-1048.
12. Hussein AA, Wilkoff BL, Martin DO, Karim S, Kanj M, Callahan T, et al. Initial experience with the Evolution mechanical dilator sheath for lead extraction: Safety and efficacy. *Heart Rhythm.* 2010; 7: 870-873.
13. Wazni O, Epstein LM, Carrillo RG, Love C, Adler SW, Riggio DW, et al. Lead Extraction in the Contemporary Setting: The LEXICON Study. *J Am Coll Cardiol.* 2010; 55: 579-586.
14. Bongiorni MG, Kennergren C, Butter C, Deharo JC, Kutarski A, Rinaldi CA, et al; on behalf of ELECTRa Investigators. The European Lead Extraction ConTrolled (ELECTRa) study: a European Heart Rhythm Association (EHRA) Registry of Transvenous Lead Extraction Outcomes. *Eur Heart J.* 2017; 38: 2995-3005.

15. Nakhla S, Hussein AA, Brunner MP, Wazni O, Wilkoff BL, Tarakji KG. Removal of subcutaneous defibrillator shocking coils: Lessons to learn for future extraction of subcutaneous defibrillator systems. *Pacing Clin Electrophysiol.* 2018; 41: 1341-1344
16. Ip JE. Technique for subcutaneous implantable cardioverter-defibrillator extraction. *J Cardiovasc Electrophysiol.* 2019; 30: 789-791
17. Quast ABE, van Dijk VF, Yap SC, Maass AH, Boersma LVA, Theuns DA, et al. Six-year follow-up of the initial Dutch subcutaneous implantable cardioverter-defibrillator cohort: Long-term complications, replacements, and battery longevity. *J Cardiovasc Electrophysiol.* 2018; 29: 1010-1016
18. Theuns DA, Crozier IG, Barr CS, Hood MA, Cappato R, Knops RE, et al. Longevity of the Subcutaneous Implantable Defibrillator: Long-Term Follow-Up of the European Regulatory Trial Cohort. *Circ Arrhythm Electrophysiol.* 2015; 8: 1159-63.
19. Boersma L, Barr C, Knops R, Theuns D, Eckardt L, Neuzil P, et al. EFFORTLESS Investigator Group. Implant and Midterm Outcomes of the Subcutaneous Implantable Cardioverter-Defibrillator Registry: The EFFORTLESS Study. *J Am Coll Cardiol.* 2017; 70: 830-841.
20. Marijon E, Boveda S, De Guillebon M, Jacob S, Vahdat O, Barandon L, et al. Contributions of advanced techniques to the success and safety of transvenous leads extraction. *Pacing Clin Electrophysiol.* 2009; 32 Suppl 1:S38-41.

TABLE 1: Baseline Characteristics of the Study Population.

	All patients (n=32)
Age at S-ICD extraction procedure, years	45.7 ± 13.8
Male gender	24 (75.0)
Body mass index, kg/m ²	22.9 (20.5-28.6)
Underlying cardiomyopathy:	
- Ischemic	11 (34.4)
- None	8 (25.0)
- Hypertrophic	5 (15.6)
- Dilated	4 (12.5)
- Others	4 (12.5)
LVEF, %	50.0 (30.2-60.0)
S-ICD indication: secondary prevention	11 (34.4)
History of median sternotomy	7 (21.9)
S-ICD implanted devices	
- Cameron SQ-RX generator +Q-Track 3010 lead	3 (9.4)
- Emblem A209 generator + Emblem 3401 lead	28 (87.5)
- Emblem A219 generator + Emblem 3501 lead	1 (3.1)
Pulse generator pocket location:	
- Subcutaneous	4 (12.5)
- Intermuscular	25 (78.1)
- Submuscular	3 (9.4)
S-ICD lead position:	
- Left parasternal	26 (81.2)
- Right parasternal	6 (18.8)
S-ICD lead implantation technique	
- 2-incisions	26 (81.2)
- 3-incisions	6 (18.8)

TABLE 2: S-ICD lead extraction procedural characteristics

	All patients (n=32)
Delay from implant (months)	9.3 (5.4-17.5)
Associated generator extraction	26 (81.3)
Number of incision	
- 2 incisions	23 (71.9)
- 3 incisions	9 (28.1)
S-ICD lead extraction technique	26 (81.2)
- Simple traction	19 (59.4)
- Additional incision (forward and backward movement)	3 (9.4)
- Mechanical sheath	9 (28.1)
<i>Regular Byrd dilatator sheath (13.9 french outer diameter)</i>	8 (25.0)
<i>Visisheath S (16.4 french outer diameter)</i>	1 (3.1)
S-ICD lead extraction procedure time, min	40.0 (28.7-66.2)
S-ICD lead extraction success	31 (96.9)

TABLE 3: baseline and S-ICD lead extraction characteristics according to the success of simple traction.

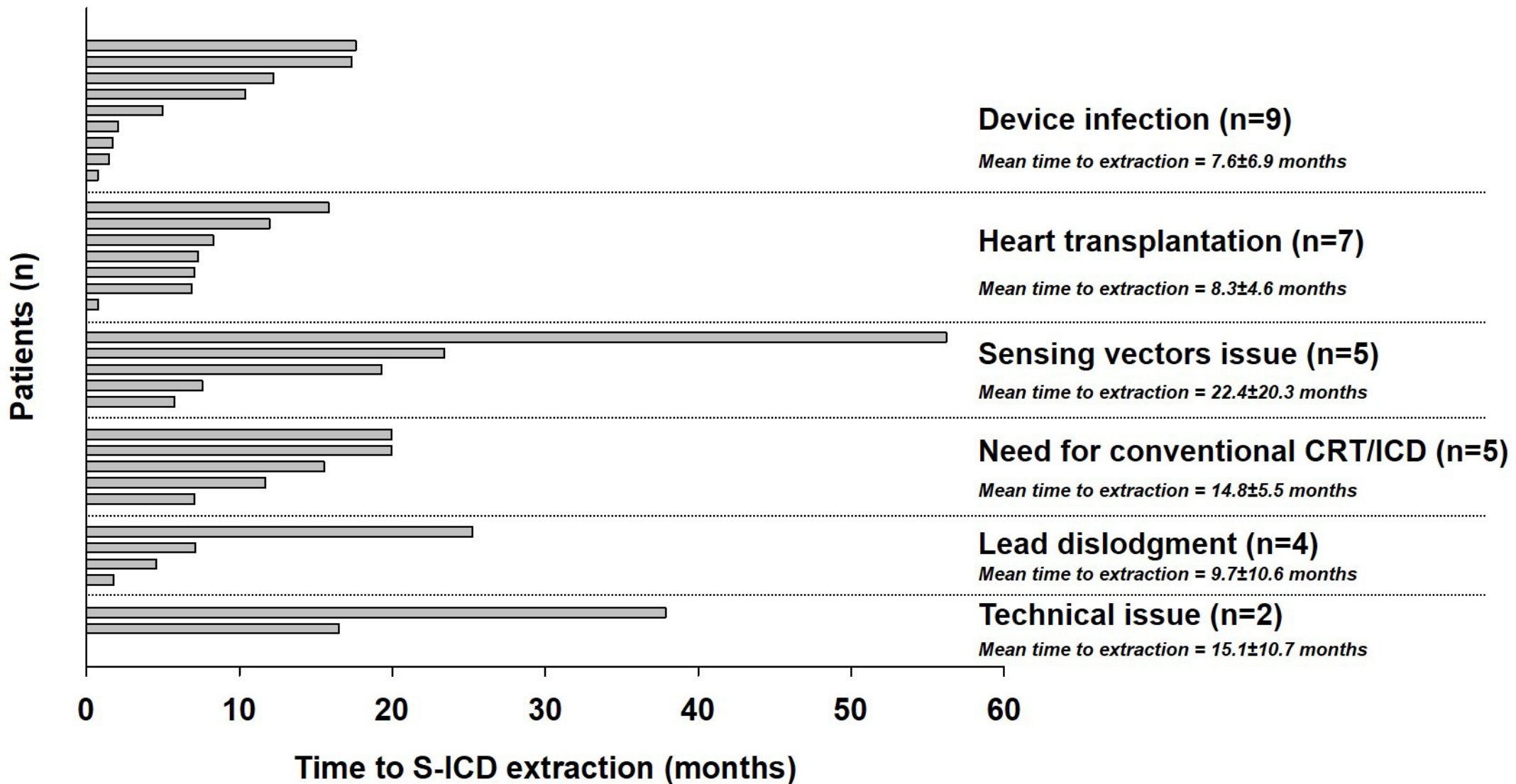
	Simple traction group (n=19)	Unsuccessful simple traction group (n=13)	p-value
Age at S-ICD extraction procedure, years	46.3±14.9	44.8±12.6	0.769
Male gender	14 (73.7)	10 (76.9)	0.835
History of median sternotomy	2 (10.5)	5 (38.5)	0.091
S-ICD lead position:			0.967
- Left parasternal	16 (84.2)	10 (76.9)	
- Right parasternal	3 (15.8)	3 (23.1)	
S-ICD lead implantation technique			0.954
- 2-incisions	15 (78.9)	11 (84.6)	
- 3-incisions	4 (21.1)	2 (15.4)	
Delay from implant (months)	7.1 (2.8-12.2)	16.5 (7.5-20.8)	0.040
S-ICD lead extraction procedure time, min	32.5 (25.0-52.0)	40.0 (32.5-68.7)	0.364
S-ICD lead extraction success	19 (100.0)	12 (92.1)	0.406

FIGURES LEGEND:

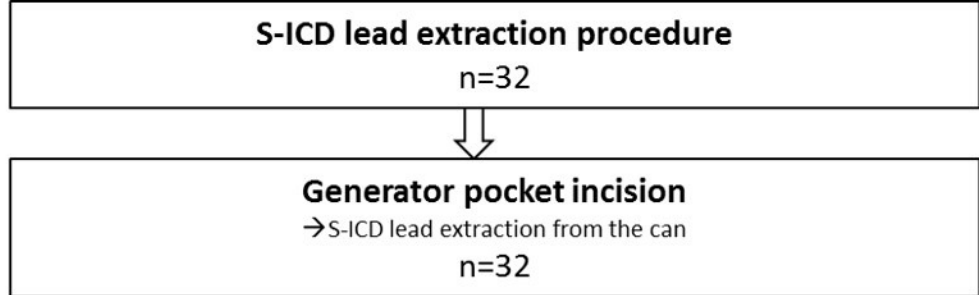
FIGURE 1: Distribution of S-ICD lead extraction procedures indication and time to device extraction

FIGURE 2: Summary of the stepwise strategy used for S-ICD lead extraction procedure.

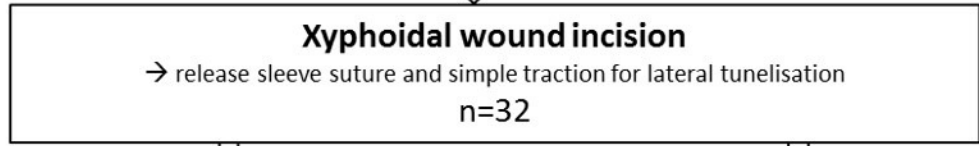
CENTRAL ILLUSTRATION: S-ICD lead extraction technique using the Regular Byrd dilatator sheath (13.9 french outer diameter). Panel A: S-ICD lead is released from the tunnelization between xiphoidal wound and the generator can pocket. Panel B: Regular Byrd dilatator sheath is placed around the lead (it's mandatory to cut the sheath in order to apply traction on the lead). Panel C: the sheath progresses while a gentle counter-traction is performed on the lead.



1st Step

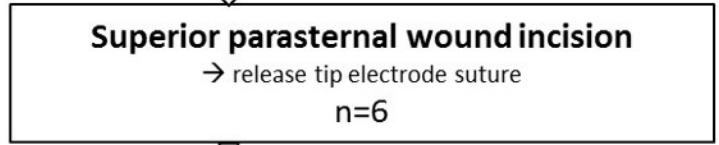


2nd Step

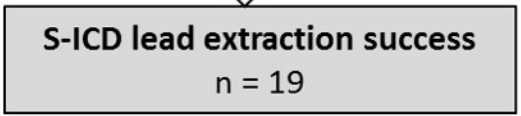
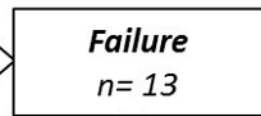
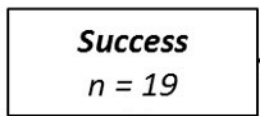


3rd Step

For patients with 3-incisions
initial S-ICD implantation



4th Step



5th Step

