



HAL
open science

Bone decalcification to assess programmed cell death ligand 1 expression in bone metastases of non-small cell lung cancers

Guillaume Pontarollo, Cyrille B Confavreux, Jean-Baptiste Pialat, Sylvie Isaac, Fabien F Forest, Violaine Yvorel, Jean-Michel Maury, Nicolas Girard, Marie Brevet

► To cite this version:

Guillaume Pontarollo, Cyrille B Confavreux, Jean-Baptiste Pialat, Sylvie Isaac, Fabien F Forest, et al.. Bone decalcification to assess programmed cell death ligand 1 expression in bone metastases of non-small cell lung cancers. *Journal of Bone Oncology*, 2020, 21, pp.100275. 10.1016/j.jbo.2020.100275 . hal-02929279

HAL Id: hal-02929279

<https://hal.science/hal-02929279>

Submitted on 21 Jul 2022

HAL is a multi-disciplinary open access archive for the deposit and dissemination of scientific research documents, whether they are published or not. The documents may come from teaching and research institutions in France or abroad, or from public or private research centers.

L'archive ouverte pluridisciplinaire **HAL**, est destinée au dépôt et à la diffusion de documents scientifiques de niveau recherche, publiés ou non, émanant des établissements d'enseignement et de recherche français ou étrangers, des laboratoires publics ou privés.



Distributed under a Creative Commons Attribution - NonCommercial 4.0 International License

Bone decalcification to assess programmed cell death ligand 1 expression in bone metastases of non-small cell lung cancers

Guillaume Pontarollo (1), Cyrille B. Confavreux (2), Jean-Baptiste Pialat (3), Sylvie Isaac (4), Fabien Forest (5), Violaine Yvorel (5), Jean-Michel Maury (6), Nicolas Girard (7), Marie Brevet (1)

(1) Hospices Civils de Lyon, Institut de pathologie multisite des Hospices Civils de Lyon Site Est, Bron cedex 69677, France, Université Lyon-1, Lyon 69008, France.

(2) Hospices Civils de Lyon, Centre Hospitalier Lyon Sud, Service de rhumatologie, Pierre-Bénite F-69370; Université Lyon-1, Lyon 69008, France; INSERM UMR 1033, Centre Expert des Metastases et Oncologie Osseuse Secondaire (CEMOS), Lyon 69008, France.

(3) Hospices Civils de Lyon, Service de radiologie, Pierre-Bénite 69370, France; Université Lyon-1, Lyon 69008, France.

(4) Hospices Civils de Lyon, Institut de pathologie multisite des Hospices Civils de Lyon Site Sud, Pierre-Bénite 69370, France; Université Lyon-1, Lyon 69008, France.

(5) Hôpital universitaire de Saint Etienne – Site Nord, Service de pathologie, Saint Etienne, France

(6) Hospices Civils de Lyon, Hôpital Cardio-vasculaire et pneumologique de Louis Pradel, service de chirurgie cardio-vasculaire, Bron Cedex 69677, France; Université Lyon-1, Lyon 69008, France.

(7) Institut Curie, Institut du Thorax Curie-Montsouris, Paris Cedex 75248, France; Université
Lyon-1, Lyon 69008, France.

Corresponding author:

Pr Marie Brevet, MD, PhD

Service de pathologie et de neuropathologie est

Centre de biologie et de pathologie est

Hospices Civils de Lyon

59 boulevard Pinel

69677 Bron

France

Tel: +33 4 27 85 61 84

Fax: +33 4 72 35 70 67

Email: marie.brevet01@chu-lyon.fr

brevetm@gmail.com

HIGHLIGHTS

- Rapid determination of PD-L1 expression has become a necessity in lung cancer
- The decalcification process is a critical point for bone metastasis specimens
- EDTA or formic acid decalcification may be used for PD-L1 IHC in routine practice

ABSTRACT

As for molecular alterations of lung adenocarcinoma, it is critical that pathologists are able to give PD-L1 expression status before first-line of treatment. The present study compared PD-L1 expression (clone 22-C3) in decalcified using EDTA or formic acid and non-decalcified lung cancer metastases bone samples. Among the 84 bone samples analysed for PD-L1 expression, and independently of decalcification, TPS $\geq 1\%$ was 25.0% and $\geq 50\%$ was 11.4%. There was no significant difference between decalcified samples (n=45) and non-decalcified samples (n=39) for both TPS $\geq 1\%$ (p=0.32) and TPS $\geq 50\%$ (p=1). To conclude, we confirm decalcified bone metastasis specimens may be used for PD-L1 IHC in routine practice. These results also highlight potentially interesting specificities of the bone microenvironment that should be further studied.

KEYWORDS

lung carcinoma; PD-L1; bone metastases; decalcification; immunotherapy

INTRODUCTION

As is the case for molecular alterations of non-small cell lung cancer (NSCLC), the capacity of pathologists to give PD-L1 expression status before first-line treatment is now critical for patient therapy [1,2]. The challenge of routine practice is to obtain histopathological diagnosis, as well as molecular and immunohistochemical biomarker analysis within 7-10 days. In our institution, about 20% of lung cancer diagnoses are performed on a bone biopsy alone (unpublished data). For bone metastasis specimens, the decalcification process is a critical point. Nitric acid-based agents allow rapid tissue decalcification (a few hours to 2-3 days depending of the proportion of hard tissue in the sample) but lead to poor DNA quality and a loss of antigenicity [3], precluding molecular and immunohistochemical analysis. Thus, alternative decalcification agents, such as EDTA and formic acid, are now commonly used in pathology departments; these provide good morphological results and allow immunohistochemistry (IHC) or molecular biology tests to be performed. For instance, immunohistochemical analysis of biomarkers, such as HER2 protein in breast cancer, are performed on bone samples with low rates of discordance comparing bone metastases to primary tumours [3,4]. Nevertheless, bone samples still continue to be excluded from clinical trials and there is currently no data available concerning PD-L1 status of NSCLC bone metastases.

Our team has previously published a study that reported the value and efficacy of decalcified bone metastasis biopsy to make a histopathological and molecular diagnosis in patients presenting lung tumours with synchronous bone metastasis [5]. Herein, we compare the expression of PD-L1 between decalcified and non-decalcified bone metastasis of NSCLC.

MATERIAL & METHODS

Patients and tumour samples

The prospective multidisciplinary cohort POUMOS was initiated in 2011 at the Hospices Civils de Lyon, Lyon, France [5,6] and approved by the regional ethics committee (*Comité de protection des personnes Sud-Est IV*, L11-76). Bone tissue samples from patients with bone metastatic NSCLC are still collected. Samples obtained between 1 April 2016 and 31 November 2018 were included in the present study. IHC for PD-L1 was performed as part of routine practice in the pathology department of the Hospices Civils de Lyon. Clinical data, such as sex, age, stage of the disease, and histopathological reports were retrospectively collected as part of the POUMOS study. Based on medical histopathological report and/or histopathological slides reviewed by two thoracic pathologists, lung carcinomas were classified according to the World Health Organization histopathological classification [1].

Decalcification procedure

For bone metastases of lung cancer, decalcification of bone was performed, when necessary, after formaldehyde fixation using EDTA (0.5M EDTA pH8.0, Promega, Madison, WI, USA) between April 2016 and June 2017 then formic acid (Decalcifying Solution, Formic Acid 5%, Aqueous; Newcomersupply, Middleton, WI, USA) from July 2017 until November 2018. Decalcification was performed for minimum of four hours for biopsies and from 4-to-15 days for surgical specimens, with overnight alternative cycles (formaldehyde fixation / decalcification). No decalcification was performed when major osteolysis was observed. Specimens were then dehydrated and paraffin-embedded according to routine procedures. All samples were included in the tumour bank “Tissu-tumorotheque Est” (*Centre de Ressources Biologiques*, CRB) of the Hospices Civils de Lyon.

Immunohistochemical analysis

Standard 4- μ m thick FFPE sections were subjected to IHC analysis using an anti-PD-L1 antibody (22-C3 antibody; Agilent, Santa Clara, CA, USA; dilution 1/100; Optiview DAB IHC detection kit, Roche, Switzerland) on a Ventana automated staining platform (BenchMark ULTRA, Tucson, AZ, USA). The tumour proportion score (TPS) for PD-L1 staining was calculated considering membranous PD-L1 expression of tumour cells, independently of the intensity of the staining [7]. Following European medicines agency guidelines, positivity of PD-L1 expression was defined as $TPS \geq 1\%$ and $TPS \geq 50\%$. Positive control was present on each slide, and samples with ≤ 30 tumour cells were excluded from analysis.

Statistical analysis

All patients were included in the statistical analyses. Categorical variables were compared using the Chi-squared or Student's t-test. A p-value < 0.05 was considered significant. Statistical analyses were performed using the Graph Pad software (San Diego, CA, USA).

RESULTS

Patients and samples characteristics

A total of 88 specimens of NSCLC bone metastases were included in the present study.

Patients were mainly men (63/88, 71.6%) and the median age was 65.4 years (range: 41-86).

The specimens were obtained by CT-guided bone biopsies in 62 cases (70.5%) and surgical resection in 26 cases (29.5%), mainly from hip (40/88, 45.5%) and vertebrae (32/88, 36.4%).

Lung non-squamous carcinoma was the most frequent histological diagnosis (81/88, 92.0%).

No decalcification was performed in 41 cases (46.6%) because of massive tumour infiltration and lytic bone lesion. In the other cases, decalcification procedure was performed using EDTA in 35 cases (39.8%) and formic acid in 12 cases (13.6%; Table 1).

PD-L1 expression

PD-L1 expression status was obtained in 84 cases (95.5%); most of the samples presented > 100 tumour cells (76/88, 86.4%) while four cases could not be evaluated due to insufficient material. Irrespective of decalcification, TPS \geq 1% was found in 21/84 cases (25.0%) and TPS \geq 50% in 10/88 (11.4%; Figure 1). There was no significant difference in the frequency of PD-L1 expression between samples not decalcified (n=39) and those decalcified using EDTA/formic acid (n= 45; Table 2).

DISCUSSION

In this study, we found that EDTA/formic acid decalcification of lung cancer bone metastases may be used to evaluate immunohistochemical PD-L1 expression in NSCLC.

An important result of the present study is that the frequency of PD-L1 expression in NSCLC bone metastases seems lower than that described in lung tumours. Among 1695 lung tumour samples, O'Malley *et al.* found 70.2% of tumours had a TPS $\geq 1\%$ and 36.5% a TPS $\geq 50\%$ [8]. A lower frequency was described by Evans *et al.* who found 55.6% of NSCLC with a TPS $\geq 1\%$ and 30.6% a TPS $\geq 50\%$ [9]. Nevertheless, the frequency of PD-L1 expression is dependent of the clone of PD-L1 antibody, the immunostainer, and the IHC protocol used in routine diagnosis [7]; Evans *et al.* used the commercial PD-L1 22-C3 PharmDx assay [9] while the study reported by O'Malley *et al.* was based on results obtained using different PD-L1 clones including 22C3, 28-8, SP142 and SP263 [8]. Furthermore, although the size of the samples could limit interpretation of PD-L1 expression, the latter studies included samples from surgical resection, biopsies and cytology [8,9]. Herein, PD-L1 expression was assessed mostly on small samples that could underestimate the frequency of expression, which may explain part of the difference, but the variety of technical issues potentially affecting the accuracy of the test precludes comparison.

In recent publications, authors have described a good concordance between primary tumours and soft tissue metastases, depending on the tumour and the TPS (better concordance was found when TPS $\geq 50\%$) [6,10]. Focusing on NSCLC and when considering a cut-off of 50%, Munari *et al.* described a discrepancy of 9.3% of paired samples for PD-L1 expression [10]. This kind of study was not possible herein because we could not evaluate PD-L1 expression on the primary tumour, only on the bone metastases. Furthermore, PD-L1 expression could be increased in some specific metastatic sites; Evans *et al.* described a significant overexpression

of PD-L1 in pleural and nodal metastases [9] . In bone, they found a more frequent expression of PD-L1 than in the present study (49.8% TPS >1%, and 26.3% TPS \geq 50% [9]). In bone, PD-L1 expression could vary according to the technical aspects described above, but, in addition, the decalcification procedure and the microenvironment of the bone could also contribute to this difference. Herein, there was no significant difference in PD-L1 expression among decalcified and non-decalcified bone samples. These results confirm on lung cancer bone metastases the data recently published on placentas and lung samples [11] where the authors reported a decrease of PD-L1 expression when the samples were subjected to acid-based decalcifiers while there was little change in staining intensity or in the proportion of stained cells with EDTA or formic acid. With regards to the microenvironnement, ongoing studies in our department are investigating specifically the immune component of bone metastases stroma. The bone is the third common sites for metastasis that could be explained by high blood flow, tumor cell-stroma cell interactions and growth factors produced by the bone marrow that stimulate tumor growth [12]. Understanding the immune regulatory mechanisms in the bone marrow microenvironnement is important for the development of immune therapies in NSCLC.

To conclude, we confirm decalcified bone metastasis specimens may be used for PD-L1 IHC in routine practice. These results also highlight potentially interesting specificities of the bone microenvironment that should be further studied.

FUNDING

This work was supported by the Hospices Civils de Lyon young investigator research grant (to CC).

ACKNOWLEDGEMENTS

The authors thank the technical team of the departments of pathology from the Hospices Civils de Lyon for performing PD-L1 immunohistochemistry and we thank Dr Philip Robinson (DRCI, Hospices Civils de Lyon) for help in manuscript preparation. The authors also thank the biological resource centre of the Hospices Civils de Lyon (Tissu-tumorotheque Est).

BIBLIOGRAPHY

- [1] T.S.K. Mok, Y.-L. Wu, I. Kudaba, D.M. Kowalski, B.C. Cho, H.Z. Turna, G. Castro, V. Srimuninnimit, K.K. Laktionov, I. Bondarenko, K. Kubota, G.M. Lubiniecki, J. Zhang, D. Kush, G. Lopes, Pembrolizumab versus chemotherapy for previously untreated, PD-L1-expressing, locally advanced or metastatic non-small-cell lung cancer (KEYNOTE-042): a randomised, open-label, controlled, phase 3 trial, *The Lancet*. 393 (2019) 1819–1830. [https://doi.org/10.1016/S0140-6736\(18\)32409-7](https://doi.org/10.1016/S0140-6736(18)32409-7).
- [2] R.S. Herbst, P. Baas, D.-W. Kim, E. Felip, J.L. Pérez-Gracia, J.-Y. Han, J. Molina, J.-H. Kim, C.D. Arvis, M.-J. Ahn, M. Majem, M.J. Fidler, G. de Castro, M. Garrido, G.M. Lubiniecki, Y. Shentu, E. Im, M. Dolled-Filhart, E.B. Garon, Pembrolizumab versus docetaxel for previously treated, PD-L1-positive, advanced non-small-cell lung cancer (KEYNOTE-010): a randomised controlled trial, *The Lancet*. 387 (2016) 1540–1550. [https://doi.org/10.1016/S0140-6736\(15\)01281-7](https://doi.org/10.1016/S0140-6736(15)01281-7).
- [3] F. Forest, G. Cote, D. Laville, V. Da Cruz, P. Dal Col, F. Camy, M. Mobarki, A. Clemenson, V. Yvorel, M. Péoc'h, Impact of delayed fixation and decalcification on PD-L1 expression: a comparison of two clones, *Virchows Arch*. (2019). <https://doi.org/10.1007/s00428-019-02613-w>.
- [4] F.M. Savi, G.I. Brierly, J. Baldwin, C. Theodoropoulos, M.A. Woodruff, Comparison of Different Decalcification Methods Using Rat Mandibles as a Model, *J. Histochem. Cytochem.* 65 (2017) 705–722. <https://doi.org/10.1369/0022155417733708>.
- [5] C.B. Confavreux, N. Girard, J.-B. Pialat, P.-P. Bringuier, M. Devouassoux-Shisheboran, J.-C. Rousseau, S. Isaac, F. Thivolet-Bejui, P. Clezardin, M. Brevet, Mutational profiling of bone metastases from lung adenocarcinoma: results of a prospective study (POUMOS-TEC), *BoneKEy Rep.* 3 (2014). <https://doi.org/10.1038/bonekey.2014.75>.

- [6] L. Chambard, N. Girard, E. Ollier, J.-C. Rousseau, F. Duboeuf, M.-C. Carlier, M. Brevet, P. Szulc, J.-B. Pialat, J. Wegrzyn, P. Clezardin, C.B. Confavreux, Bone, muscle, and metabolic parameters predict survival in patients with synchronous bone metastases from lung cancers, *Bone*. 108 (2018) 202–209. <https://doi.org/10.1016/j.bone.2018.01.004>.
- [7] S. Lantuejoul, J. Adam, N. Girard, M. Duruisseaux, A. Mansuet-Lupo, A. Cazes, I. Rouquette, L. Gibault, S. Garcia, M. Antoine, J.M. Vignaud, F. Galateau-Sallé, C. Sagan, C. Badoual, F. Penault-Llorca, D. Damotte, Tests immunohistochimiques PD-L1 dans les cancers du poumon non à petites cellules : recommandations par le groupe PATTERN de pathologistes thoraciques, *Ann. Pathol.* 38 (2018) 110–125. <https://doi.org/10.1016/j.annpat.2018.01.007>.
- [8] D.P. O'Malley, Y. Yang, S. Boisot, S. Sudarsanam, J.-F. Wang, V. Chizhevsky, G. Zhao, S. Arain, L.M. Weiss, Immunohistochemical detection of PD-L1 among diverse human neoplasms in a reference laboratory: observations based upon 62,896 cases, *Mod. Pathol.* (2019). <https://doi.org/10.1038/s41379-019-0210-3>.
- [9] M. Evans, B. O'Sullivan, F. Hughes, T. Mullis, M. Smith, N. Trim, P. Taniere, The Clinicopathological and Molecular Associations of PD-L1 Expression in Non-small Cell Lung Cancer: Analysis of a Series of 10,005 Cases Tested with the 22C3 Assay, *Pathol. Oncol. Res.* (2018). <https://doi.org/10.1007/s12253-018-0469-6>.
- [10] E. Munari, G. Zamboni, G. Lunardi, M. Marconi, M. Sommaggio, M. Brunelli, G. Martignoni, G.J. Netto, M.O. Hoque, F. Moretta, M.C. Mingari, M.C. Pegoraro, F.R. Mariotti, P. Vacca, L. Moretta, G. Bogina, PD-L1 expression comparison between primary and relapsed non-small cell lung carcinoma using whole sections and clone SP263, *Oncotarget*. 9 (2018). <https://doi.org/10.18632/oncotarget.25770>.

[11] Strickland AL, Blacketer S, Molberg K, Markantonis J, Lucas E. Effects of decalcifying agents of variable duration on PD-L1 immunohistochemistry. *Am J Clin Pathol*. 2019 Oct 11. pii: aqz161. doi: 10.1093/ajcp/aqz161. [Epub ahead of print]

[12] L. Xiang, D. Gilkes, The Contribution of the Immune System in Bone Metastasis Pathogenesis, *Int. J. Mol. Sci.* 20 (2019) 999. <https://doi.org/10.3390/ijms20040999>.

Table 1: Clinical and histopathological characteristics.

Table 2: Tumour cell PD-L1 expression according to decalcification procedure

Figure 1: Illustrations of PD-L1 expression. A illustrates high PD-L1 expression (TPS $\geq 50\%$) while B illustrates an absence of PD-L1 expression (TPS $< 1\%$).

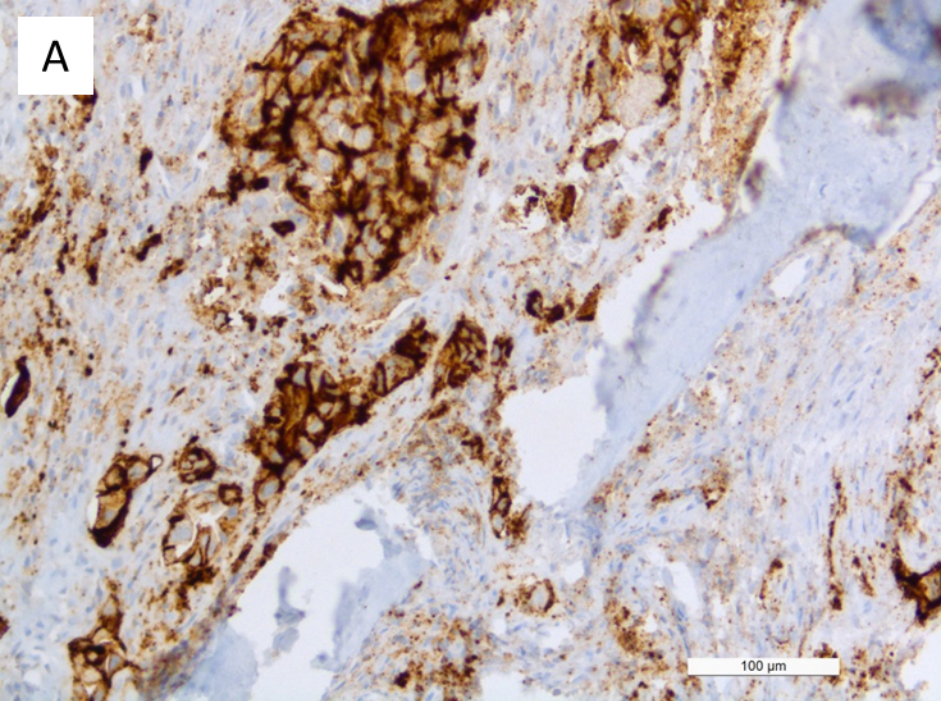
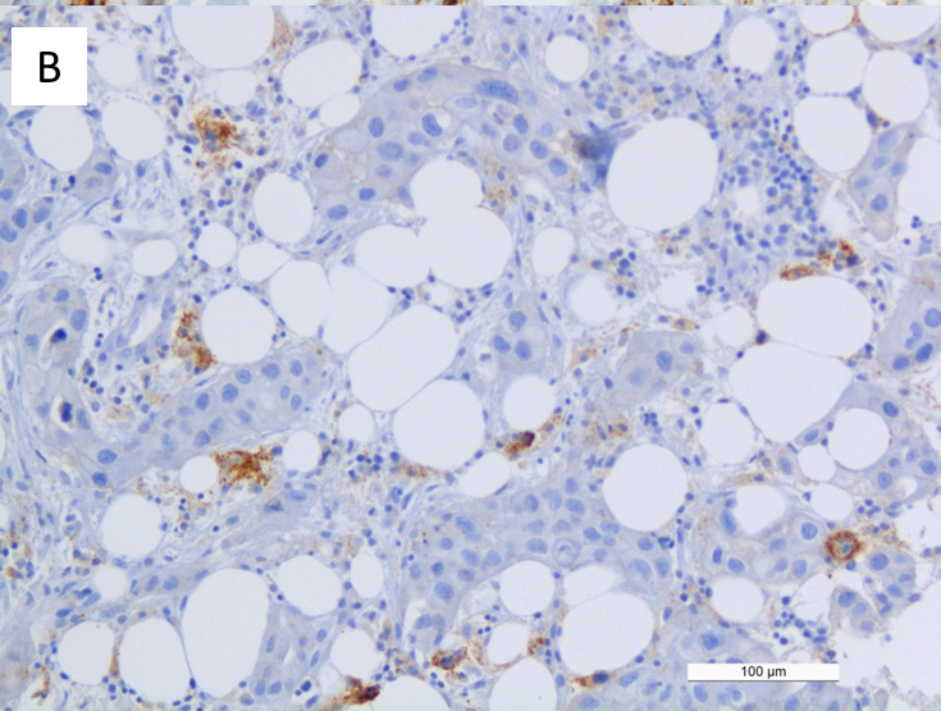
A**B**

Table 1: Clinical and histopathological characteristics.

	Total population, n=88
Gender, n (%)	
male	63 (71.6)
female	25 (28.4)
Median age, years (range)	65.4 (41-86)
Type of sample, n (%)	
percutaneous biopsies	62 (70.5)
surgical samples	26 (29.5)
Tumour localization, n (%)	
hip	40 (45.5)
vertebrae	32 (36.4)
other	16 (18.2)
Histological type of NSCLC, n (%)	
non-squamous carcinoma	81 (92.0)
squamous carcinoma	7 (7.9)
Decalcification procedure, n (%)	
no decalcification	41 (46.6)
EDTA	35 (39.8)
formic acid	12 (13.6)
Number of tumour cells / sample, n (%)	
>100 cells/sample	76 (86.4)
50-100 cells/sample	5 (5.7)
30-49 cells/sample	3 (3.4)
<30 cells /sample	4 (4.5)

Table 2: Tumour cell PD-L1 expression according to decalcification procedure

	No decalcification (n=39)	EDTA or formic acid decalcification (n=45)	p-value	Total (n=84)
TPS < 1%, n (%)	27 (69.2)	36 (80.0)		63 (75.0)
TPS ≥ 1%, n (%)	12 (30.8)	9 (20.0)	0.32 ^a	21 (25.0)
TPS ≥ 50%, n (%)	4 (10.3)	6 (13.3)	1 ^a	10 (11.4)

^a p-value calculated versus the TPS < 1%