



PD-L1 inhibitor-induced worsening of eosinophilic obstructive lung disease successfully rescued with anti-interleukin 5 receptor (IL-5R) therapy

Flora Wassmer, Carey Suehs, Clement Boissin, Arnaud Bourdin, Jérémy Charriot

► To cite this version:

Flora Wassmer, Carey Suehs, Clement Boissin, Arnaud Bourdin, Jérémy Charriot. PD-L1 inhibitor-induced worsening of eosinophilic obstructive lung disease successfully rescued with anti-interleukin 5 receptor (IL-5R) therapy. *Journal of Allergy and Clinical Immunology: In Practice*, 2020, 9 (1), pp.567-569. 10.1016/j.jaip.2020.08.022 . hal-02922639

HAL Id: hal-02922639

<https://hal.science/hal-02922639>

Submitted on 6 Aug 2021

HAL is a multi-disciplinary open access archive for the deposit and dissemination of scientific research documents, whether they are published or not. The documents may come from teaching and research institutions in France or abroad, or from public or private research centers.

L'archive ouverte pluridisciplinaire **HAL**, est destinée au dépôt et à la diffusion de documents scientifiques de niveau recherche, publiés ou non, émanant des établissements d'enseignement et de recherche français ou étrangers, des laboratoires publics ou privés.

PD-L1 inhibitor-induced worsening of eosinophilic obstructive lung disease successfully rescued with anti-interleukin 5 receptor (IL-5R) therapy

Flora Wassmer, MD^a, Carey Suehs, PhD^{a,b},
Clement Boissin, MD^a, Arnaud Bourdin, MD, PhD^{a,c}, and
Jeremy Charriot, MD^{a,c}

Clinical Implications

- Programmed death ligand-1 pathway blockade therapy may disrupt control of a pre-existing obstructive lung disease. In this kind of situation, concomitant anti-IL-5 receptor therapy remains safe and effective.

Biologics positively transformed the world of asthma.¹⁻³ Benralizumab, a monoclonal antibody that binds to the IL-5 receptor (IL-5R), induces sustained eosinophil depletion and improvement of asthma control.² Surprisingly, this benefit could not be reproduced in chronic obstructive pulmonary disease (COPD) despite the choice of blood eosinophil count as an inclusion criterion.⁴ Whether asthmatics who smoke fit in these complex clinical situations is one aspect of the asthma-COPD overlap (ACO) debate.

In tandem, the oncology field has also considerably evolved with the development of programmed death ligand-1 (PD-L1) and programmed death-1 (PD-1) pathway therapies. Durvalumab is a monoclonal antibody that blocks PD-L1 binding with PD-1 and CD80, thus allowing T cells to recognize and then kill tumor cells overexpressing PD-1.⁵ Despite close relationships between obstructive lung diseases, smoking, and lung cancer, little is known about the interactions between PD-1/PDL-1 signaling pathways and these diseases, especially in regard to airway inflammation and hyperresponsiveness (AHR). Here, we present the case of a patient with purported ACO consecutively treated with durvalumab for lung adenocarcinoma and then with benralizumab for subsequently worsening eosinophilic obstructive lung disease.

A 71-year-old man with a medical history of allergic rhinitis, hypertension, and type 2 diabetes initially presented in July 2017 at our respiratory department for an acute dyspnea episode associated with wheezing, cough, and sputum. The patient had multiple known sensitizations (dust mites, cat, dog). He reported a family history of asthma, active smoking (5 cigarettes per day, 55 pack-years), and no occupational exposure. He described similar recurrent wheezing episodes since childhood but no hospitalization before this. He did not receive any systemic steroids or antibiotics in the past 5 years. Regarding this episode, no evident trigger was found (microbiology and virology were both negative). Initial forced expiratory volume in 1 second (FEV₁) was measured at 1040 mL (35% of the predicted value) and gained 13% (120 mL) after bronchodilatation. Chest high-resolution computed tomography (CT) revealed predominantly upper lobe emphysema and bronchial wall thickening. Clinical

and paraclinical features are summarized in Table I and Figure 1. In this case of severe nonreversible obstructive airflow, smoking history, and emphysema, a dual inhaled bronchodilator with a long-acting β -agonist and a long-acting muscarinic agonist was first introduced. During follow-up, significant seasonal variability of symptoms and FEV₁ (from 720 to 1180 mL, 25% to 40% of predicted value) were noted, with hospitalizations for exacerbations always occurring during the same period (July 2017, 2018, and 2019). Blood eosinophilia ranged from 320 to 390/mm³. Despite smoking cessation, allergen avoidance, and antihistamine therapy, severe exacerbations became increasingly frequent and systematically required short courses of oral steroids to achieve prompt clinical improvement. These elements favored the diagnosis of ACO. Inhaled corticosteroids were promptly added (budesonide 1600 mg daily), and then azithromycin 250 mg/day was introduced in July 2018. The latter failed to reduce the patient's exacerbation rate and was stopped after 6 months. Finally, a daily dose of 10 mg of prednisolone was required to gain and maintain control.

In October 2018, a spiculated nodule of 18 mm in the right upper lobe, along with 2 other homolateral nodules, was discovered on a chest CT scan. Endobronchial ultrasound-guided node aspiration confirmed the diagnosis of lung adenocarcinoma (T4 N2 M0). The PD-1 expression of tumor cells was 5%. Concomitant radiotherapy and 6 cycles of chemotherapy (paclitaxel and carboplatin) were administered before durvalumab was introduced in June 2019, given the partial response observed at 6 months. Whereas only 1 mild exacerbation occurred during chemotherapy, from the start of durvalumab, we observed a worsening of asthma control with 3 exacerbations (2 of which were severe) occurring in a 2-month period of treatment. Each exacerbation required an increasingly stronger dosage regimen of oral steroids, with a novel minimum effective dose of 20 mg of prednisolone between exacerbations. A new CT-scan ruled out PD-L1 inhibitor-induced interstitial lung disease.

A multidisciplinary consensus decided to start an anti-IL-5R therapy (benralizumab) in September 2019. A dramatic clinical improvement with combined immunotherapy (durvalumab-benralizumab) was observed, namely no exacerbations and a significant improvement in Asthma Control Test scores. FEV₁ remained unchanged (Table I). Oral corticosteroid tapering is still ongoing with a current dosage regimen of 5 mg/day of prednisolone concomitantly with a tapering of inhaled corticosteroids. To date, lung cancer remains stable and no side effects induced by this combination immunotherapy were noticed.

We here report the first observation of obstructive lung disease worsening induced by durvalumab and then rescued with anti-IL5R therapy.

Previously published preliminary observations suggest that a PD-1 pathway blockade does not worsen obstructive lung diseases such as asthma or COPD in terms of symptoms, lung function, or exacerbations. Side effects reported in "real-life studies" of these molecules in these patients are quite consistent.⁶ However, PD-1 is an important negative regulator of KLRG1⁺ ILC2 subsets in both mice and humans. PD-1 is exclusively expressed by ILC2s, and disrupting PD-1 signaling either by

TABLE I. Clinical evolution of obstructive lung disease according to treatment

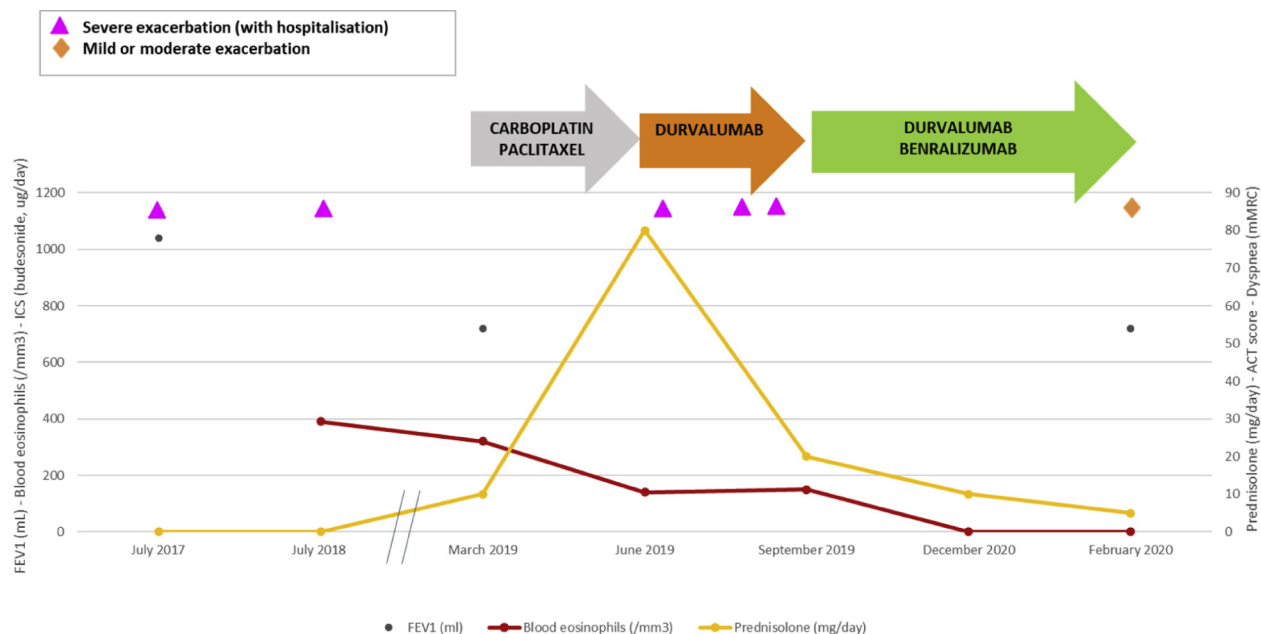
	July 2017	July 2018	March 2019	June 2019*	September 2019†	December 2019	February 2020
mMRC dyspnea scale‡	1	2	2	4	4	1	1
ACT	14	16	13	5	10	24	20
FEV ₁ (mL)	1040		720				720
Blood eosinophils (/mm ³)		390	320	140	150	0	0
Prednisolone (mg/d)	0	0	0	80	20	10	5
ICS (BUD µg/d)	0	800	800	1600	1600	800	400

ACT, Asthma Control Test; BUD, Budesonide; FEV₁, Forced Expiratory Volume in 1 second; ICS, Inhaled Corticosteroids

*Durvalumab introduced.

†Benralizumab introduced.

‡Modified Medical Research Council Dyspnea Scale: 0 = dyspnea only with strenuous exercise; 1 = dyspnea when hurrying or walking up a slight hill; 2 = walks slower than people of the same age because of dyspnea or has to stop for breath when walking at own pace; 3 = stops for breath after walking 100 yards or after a few minutes; 4 = too dyspneic to leave house or breathless when dressing.

**FIGURE 1.** Evolution of blood eosinophils according to treatment.

genetic deletion or by antibody blockade significantly enhances KLRG1⁺ ILC2 cells in both number and function. Specifically, the target function relevant to this case report is the production of IL-13 in the lungs, which plays a major role in the pathophysiology of asthma.⁷

McGee et al⁸ showed that immune checkpoint inhibitors targeting PD-1 could reverse AHR and reduce inflammation through interaction with Tregs from lung tissue in mice. This effect was counter-balanced with the administration of an anti-PD-1.⁸

Nevertheless, studies assessing the PD-1 family members in asthma have also shown conflicting results. For instance, a mouse model of allergic asthma showed that blocking PD-1/PDL-1 improved AHR, not through the alteration of the magnitude of the T2 immune response, but actually through the development of a concomitant Th17 immune response.⁹

PD-L1 pathway blockade therapy for lung cancer may disrupt control of a pre-existing obstructive lung disease; this can be rescued with concomitant anti-IL-5R as an add-on therapy. More attention to PD-1/PD-L1 pathway therapy

safety is required in regard to our observation, keeping in mind that biologics may remain safe and efficient in such cases.

^aDepartment of Respiratory Diseases, University of Montpellier, CHU Montpellier, Montpellier, France

^bDepartment of Medical Information, University of Montpellier, CHU Montpellier, Montpellier, France

^cPhyMedExp, University of Montpellier, CNRS, INSERM, CHU Montpellier, Montpellier, France

No funding was received for this work.

Conflicts of interest: C. Suehs reports a grant from AstraZeneca. A. Bourdin reports grants, personal fees, nonfinancial support, and other from AstraZeneca, Boehringer Ingelheim, GlaxoSmithKline, and Actelion; personal fees, nonfinancial support, and other from Novartis, Regeneron, and Chiesi Pharmaceuticals; personal fees and nonfinancial support from Teva; personal fees from Gilead; nonfinancial support and other from Roche; and other from Nuvaira, from null, outside the submitted work. The rest of the authors declare that they have no relevant conflicts of interest.

Received for publication June 12, 2020; revised August 10, 2020; accepted for publication August 10, 2020.

Available online August 22, 2020.

Corresponding author: Jeremy Charriot, MD, CHU Montpellier, Hôpital Arnaud de Villeneuve, 371. Av. du doyen Gaston Giraud, 34295 Montpellier Cedex, France.
E-mail: j-charriot@chu-montpellier.fr.

REFERENCES

1. Ortega HG, Liu MC, Pavord ID, Brusselle GG, FitzGerald JM, Chetta A, et al. Mepolizumab treatment in patients with severe eosinophilic asthma. *N Engl J Med* 2014;371:1198-207.
2. Bleecker ER, FitzGerald JM, Chanez P, Papi A, Weinstein SF, Barker P, et al. Efficacy and safety of benralizumab for patients with severe asthma uncontrolled with high-dosage inhaled corticosteroids and long-acting β_2 -agonists (SIROCCO): a randomised, multicentre, placebo-controlled phase 3 trial. *Lancet Lond Engl* 2016;388:2115-27.
3. Castro M, Corren J, Pavord ID, Maspero J, Wenzel S, Rabe KF, et al. Dupilumab efficacy and safety in moderate-to-severe uncontrolled asthma. *N Engl J Med* 2018;378:2486-96.
4. Criner GJ, Celli BR, Brightling CE, Agusti A, Papi A, Singh D, et al. Benralizumab for the prevention of COPD exacerbations. *N Engl J Med* 2019;381:1023-34.
5. Ohaegbulam KC, Assal A, Lazar-Molnar E, Yao Y, Zang X. Human cancer immunotherapy with antibodies to the PD-1 and PD-L1 pathway. *Trends Mol Med* 2015;21:24-33.
6. Hui R, Özgüroğlu M, Villegas A, Daniel D, Vicente D, Murakami S, et al. Patient-reported outcomes with durvalumab after chemoradiotherapy in stage III, unresectable non-small-cell lung cancer (PACIFIC): a randomised, controlled, phase 3 study. *Lancet Oncol* 2019;20:1670-80.
7. Taylor S, Huang Y, Mallett G, Stathopoulou C, Felizardo TC, Sun M-A, et al. PD-1 regulates KLRG1+ group 2 innate lymphoid cells. *J Exp Med* 2017;214:1663-78.
8. McGee HS, Yagita H, Shao Z, Agrawal DK. Programmed death-1 antibody blocks therapeutic effects of T-regulatory cells in cockroach antigen-induced allergic asthma. *Am J Respir Cell Mol Biol* 2010;43:432-42.
9. McAlees JW, Lajoie S, Dienger K, Sproles AA, Richgels PK, Yang Y, et al. Differential control of CD4(+) T-cell subsets by the PD-1/PD-L1 axis in a mouse model of allergic asthma. *Eur J Immunol* 2015;45:1019-29.