



**HAL**  
open science

## Self-expanding metallic Y-stent compared to silicone Y-stent for malignant lesions of the main carina: A single center retrospective study

S. Lachkar, S. Couraud, M. Salaün, M. Roger, S. Bota, F. Guisier, L. Thiberville

### ► To cite this version:

S. Lachkar, S. Couraud, M. Salaün, M. Roger, S. Bota, et al.. Self-expanding metallic Y-stent compared to silicone Y-stent for malignant lesions of the main carina: A single center retrospective study. *Respiratory Medicine and Research*, 2020, 78, pp.100767. 10.1016/j.resmer.2020.100767. hal-02922603

**HAL Id: hal-02922603**

**<https://hal.science/hal-02922603>**

Submitted on 22 Aug 2022

**HAL** is a multi-disciplinary open access archive for the deposit and dissemination of scientific research documents, whether they are published or not. The documents may come from teaching and research institutions in France or abroad, or from public or private research centers.

L'archive ouverte pluridisciplinaire **HAL**, est destinée au dépôt et à la diffusion de documents scientifiques de niveau recherche, publiés ou non, émanant des établissements d'enseignement et de recherche français ou étrangers, des laboratoires publics ou privés.



Distributed under a Creative Commons Attribution - NonCommercial 4.0 International License

**Self-expanding metallic Y-stent compared to silicone Y-stent for malignant lesions of the main carina: a single center retrospective study.**

Samy Lachkar, MD<sup>1</sup>, Segolene Couraud MD<sup>1</sup>, Mathieu Salaün MD,PhD<sup>1,2</sup>, Maxime Roger MD<sup>1</sup>, Suzanna Bota MD<sup>1</sup>, Florian Guisier, MD,<sup>1,2</sup>Luc Thiberville MD,PhD<sup>1,2</sup>

1: Department of Pulmonology, Thoracic Oncology and Respiratory Intensive Care & CIC-CRB 1404, Rouen University Hospital, F 76000, Rouen, France;

2: Normandie Univ, UNIROUEN, QuantIF- LITIS EA 4108, Rouen University Hospital Department of Pulmonology, Thoracic Oncology and Respiratory Intensive Care & CIC-CRB 1404, F 76000, Rouen, France

Correspondence to:

Dr Samy Lachkar,

Department of Pulmonology, Thoracic Oncology, and Respiratory Intensive Care, Rouen University Hospital,

1 rue de Germont, 76031 Rouen Cedex, France.

Email: samy.lachkar@chu-rouen.fr

**Running Title: Metallic vs silicone Y-stent for malignant lesion of the main carina.**

## **ABSTRACT :**

**Background:** Bifurcation stents are often required in patients with malignant airway obstruction or fistulization involving the main carina. The silicone Y stent is the most used but remains challenging to place. The self-expanding metallic Y (SEM) stent appears easy to use. **The objective is to** report the feasibility, efficacy, and tolerance of SEM Y stent compared to silicone Y stent in patients with malignant tumors involving the main carina.

**Patients and methods:** This retrospective single center study was performed between May 2004 and May 2017. All patients with malignant carina involvement treated with a bronchial Y stent were included.

### **Results:**

Forty silicone Y stents and 38 SEM Y stents were placed. Seven stenting placements failed in the silicone Y group but none in the SEM Y stent group ( $p=0,008$ ). The median duration of the procedure was 80 min (25-210) in the silicone Y group and 50 min (25-110min) in the SEM Y group ( $p=0,001$ ). There was no significant difference in terms of early or late complications between the 2 groups.

Nine silicone Y stents (26.5%) and 7 SEM Y stents (18.4%) were removed ( $p=0,4$ ). The median survival time following stent insertion was 171 days (Interquartile range (IQR) : 53- 379) in the silicone Y group and 104 days (IQR: 53-230) in the SEM Y group.

### **Conclusion**

If silicone Y stent remains the best solution for benign obstruction, SEM Y stent seems to be an easy alternative with no difference in terms of complication or ablation for malignant lesions involving the main carina.

Keywords: Bronchoscopy; lung cancer; stent, rigid bronchoscopy

## **INTRODUCTION**

Thirty percent of lung cancer patients have a central airway obstruction at the time of diagnosis (1). These conditions are usually revealed by dyspnea, hemoptysis, or sepsis that can be life-threatening and require urgent therapeutic response. Treatment of malignant stenosis restricting more than 50 % of the tracheobronchial cross section may be an indication for stenting (2). Another tracheobronchial stenting indication is tracheo- and/or broncho-esophageal fistula that complicates oesophageal cancers in 5-10% of the cases(3, 4). In this indication, the purpose of the stent placement is to provide a seal, as tight as possible, of the fistula to prevent aspiration and pneumonia. In inoperable patients, malignant stenosis or fistula involving the lower trachea, the main carina, and the mainstem bronchi, often require the placement of a Y-stent.

The most commonly used Y-stent in the carinal region is the silicone Y stent (Dumon™, Novatech, La Ciotat) (figure 1a). Placement of a silicone Y stent follows two steps (5): first, recanalizing the obstructed central airways by either mechanical or photoablative means; and second, deploying the stent through the channel of the rigid bronchoscope. The main advantage of silicone stent is the ability for onsite customization to cover only the stenotic areas, and thus limit mucus plugging. However, this procedure appears sometimes difficult to perform for complex stenosis or tracheo / broncho-esophageal fistula (TBEF) due to patient characteristics, airway anatomy, physician/surgeon expertise or available equipment.

In order to address these issues, Hauck *et al.* (6) described the use of two self-expanding nitinol stents to create a Y-configuration. This technique required the bronchoscopic creation of an opening in one stent to allow the second stent to be placed. In 2007, Yang *et al* (7) described the first custom-made, self-expanding metallic Y stent (figure 1b) that appeared easier to insert. Since then, several studies have reported the

use of metallic Y stents from different manufacturers for tracheobronchial stenosis and fistula management (8-11).

To our knowledge, no study comparing SEM Y stent and silicon Y stent has been reported.

The objective of this study was to report the feasibility, efficacy, and tolerance of SEM Y stent compared to silicon Y stent in patients with malignant tumors involving the main carina.

## **PATIENTS & METHODS:**

### *Patients*

This retrospective single center study was performed at Rouen University Hospital, France between May 2004 and May 2017. All patients, who underwent a tracheal or bronchial stent during the study period were retrieved from the Rouen University Hospital Database. Patients with malignant carina involvement (stenosis or TBEF), not suitable for curative surgery, and treated with bronchial Y stent, were selected for the present study. The study protocol was approved by the Institutional Review Board of Rouen University Hospital, France (protocol number: E2019-34).

Data were collected from patient's charts, including patients' characteristics, American Society of Anaesthesiologists (ASA) score, symptoms before stenting, origin of malignant disease, previous oncology treatment; procedures including recanalization, type of stent, and outcomes including stent complications and patient survival. Length of the stenting procedure was collected from the anaesthesiology detailed reports, from the introduction of the rigid bronchoscope to its removal at the end of the procedure.

### *Stenting procedure*

All stents were placed under general anesthesia with rigid-bronchoscopy and mechanical ventilation. Recanalization technique (mechanical debulking with rigid bronchoscope or electrocaagulation) was used before stenting if needed.

The placement of a silicone Y stent follows two steps (5) : first, recanalizing the obstructed central airways by either mechanical debulking with rigid bronchoscope or electrocaagulation ; second, deploying the stent through the channel of the rigid bronchoscope (after adjusting the length of the stent). The stent deployment can be performed by the “pushing” technique, where the stent is placed above the carina and then gently pushed down with the open rigid forceps to be finally placed at the bifurcation; or the “pulling back” technique, where both bronchial limbs are inserted into the most narrowed bronchus and then are grasped with the forceps, slowly pulling the stent back until the shorter of the two bronchial limbs slips into position.

The SEM Y stent is a nitinol stent covered by polyethylene (MICRO-TECH (Nanjing) Co., Ltd). This stent cannot be adjusted for length, but different sizes are available. The technique used for placement of the SEM Y stent has been described (8). Two guide wires are inserted via the flexible bronchoscope into the left and right main bronchi, and the entire stent system (within the introducer sheath) is advanced so that the bronchial stents are placed into the main bronchi. The two bronchial stent branches are deployed by withdrawing their retaining threads, and the tracheal stent is deployed by withdrawing the introducer sheath, assuring a complete release of the Y stent.

Once in position the stent gradually expands to a predetermined shape that matches the intraluminal contour of the tracheobronchial tree. All procedures were performed using fluoroscopy.

### Statistics:

Kaplan-Meier and Log-rank test were used to compare survival between groups ; Chi<sup>2</sup> and Fisher’s exact tests were used to compare frequencies, and Mann-Whitney test was used to compare quantitative data.

Significance was set at  $p < 0,05$ .

## **RESULTS**

From May 2004 to May 2017, 272 bronchial stenting procedures were performed at the Bronchoscopy Department of Rouen University Hospital, France. Among these, 78 (29%) Y stents were placed for malignancies involving the main carina, including 40 silicone Y stents (May 2004 to May 2012) and 38 SEM Y Stents (Dec 2010 to May 2017).

### *Patients' characteristics*

Detailed results and demographics are displayed in Table 1.

The main indication for stenting was tracheobronchial obstruction in 61 patients, including 20 compressions (SEM n=7, silicone n=13), association of tracheo-oesophageal fistula and obstruction in 4 patients (SEM n=2), and fistula without obstruction in 13 (SEM n=10).

From the 78 patients, 25 had oesophageal cancer (SEM n=14), 47 had primary lung cancer (SEM n=22), and 6 had extrathoracic primary cancer (SEM n=2)

Fewer patients had a previous chemotherapy and or radiation therapy for their cancer before stent placement in the silicone Y group compared to SEM Y group (22.5% vs 52.6%, respectively,  $p = 0.01$ ). There was no significant difference between the two groups for other patients' characteristics (age, sex, origin of cancer, symptoms ASA score).

### *Perioperative period*

The details of the stenting procedures are displayed in table 2.

Mechanical and/ or electrocoagulation debulking was performed in 19 patients (55.9%) in the silicone Y group and in 19 patients (50%) in the SEM Y group. Twenty-one autoexpansive esophageal stents were placed after the bronchial stent procedure (9 in the silicone Y group and 12 in the SEM Y group).

The stenting procedure failed in 7 patients (17.1%) in the silicone Y group, replaced by a straight self expanding metallic stent in 6 patients and by a SEM Y stent in 1 patient ( $p=0,008$ ) All SEM Y procedures were successful. No perioperative complication has been reported.



The median duration of the procedure (total rigid bronchoscopy duration, including recanalization and stenting) were: 50 min (Interquartile Range (IQR)= 40-76min) in the SEM Y group and 80 min (IQR= 56-108min ) in the silicone Y group ( $p<0,001$ ) . For patients not requiring recanalization the median duration was about 40 min (IQR = 38-60) for the 19 patients in the SEM Y group and 50 min (IQR= 40-70) for the 16 patients in the silicone Y group ( $p=0,17$ ).

#### *Oncological treatment after stenting*

After stenting 20 patients (58.8%) in the silicone Y group and 26 (68.4%) in the SEM Y group received oncological treatment, including chemotherapy in 18 and 22 patients; and radiation therapy in 12 patients and 12 patients for silicone Y and SEM Y groups, respectively.

#### *Post operative outcomes*

These results are detailed in table 3.

Early or late complications were reported in 55% of patients in the silicone Y stent group and in 65% in the SEM Y stent group ( $p=0,120$ ).

Early complications (<7 days) were reported in 9 patients (27%) in the silicone Y stent group, including 10 events related to mucus accumulation leading to bronchoscopy in 8 patients, malignant stenosis in one patient and mucus plug in one patient. Early complications were reported in 7 patients in the SEM Y stent group (15%) including 5 cases of secretion accumulation leading to bronchoscopy and 1 mucus plug, and one early death at day +1 after stent placement not related to the stent but due to a pulmonary embolism.

Late complications (>7 days) were reported in 15 patients out of 33 inserted silicone Y stent patients (46%). These complications included 13 desobstructions for secretions, 6 mucus plugs, 4 granulomas, and 2 persistent cough. Late complications were reported in 23 patients (59%) in the SEM Y group including 17 secretions, 10 mucus plugs, 4 granulomas, 4 persistent cough.

### Duration of stent and stent removal

The mean duration of the stent was 102 days (IQR : 47-203 days) in the silicone Y group and 78 days (IQR= 44-141 days) in the SEM Y group with no significant difference between the 2 groups (p=0,5).

Stent removal was performed in 9 patients (26.5%) in the silicone Y group with a mean stent duration of 154 days. The reason for removal was a tumoral volume reduction after oncological treatment in 6 patients, a mucus plug in 2 patients and tumoral progression with persistent cough in 1 patient.

Stent removal was performed in 7 patients (18,4%) in the SEM Y group with a median stent duration of about 116 days. The reason for removal was a tumoral response in 5 patients, and mucus plugs in two patients.

For both stent, all stents removal attempts were successful, and we didn't use complementary techniques.

### Survival

During the study period, 66 patients (85%) died, including 32 (80%) in the silicone Y group and 34 (89%) in the SEM Y group with no significant difference between the 2 groups. The median survival time following stent insertion was 171 days (Interquartile range (IQR) : 53- 379) in the silicone Y group and 104 days (IQR: 53-230) in the SEM Y group.

## **DISCUSSION**

To our knowledge this is the first study comparing the silicone Y stent and the SEM Y stent for the treatment of tracheobronchial malignant lesions involving the main carina. We found no significant difference between the two techniques in terms of tolerance, complications and efficiency, but the SEM Y stent seemed to be faster to insert with less failure placements than the silicone Y stent.

To date, the most commonly used Y stent for the carinal region is the silicone Y stent (12), which safety and efficacy in maintaining airway patency is well-documented (5). In addition, silicone stents are economical and can be easily customized. They could be easily removed, even after a long period of time. For these reasons, the silicone stent is currently the recommended stent for benign lesions by most authors (13).

The Y silicone stent group characteristics of the present series, appears similar to those reported by Dutau on 86 patients in 2004 (5), and by Seghal *et al.*(14) in 2017, concerning the annual rate of stent placement, the median procedure time, stent-related complications, stent duration and patient's survival.

In contrast to previous reports (5,14), placement of the silicone Y stent appeared in our series sometimes difficult, with 7 failures out of 40 attempts. Moreover, silicone stents can only be inserted using rigid bronchoscopy placed beyond the bronchial obstruction which represents a potential restricting factor to the use of these stents (15,16).

Recently, a multicenter registry study of patients who benefited from therapeutic bronchoscopy for malignant central airway obstruction reported that metallic stents were used more frequently than silicone stents (15). Indeed, the self-expanding metallic stent appears to have several advantages over the silicone stent, especially in malignant and palliative indications. First, the insertion of a self-expanding stent does not require the complete recanalization of the bronchus or the need to overpass the stenosis using the rigid bronchoscope. Second, for tracheobronchial fistula management, the metallic stent appears to have a better conformation to shape the irregular airways and offers a better tightness (7, 16).

In the present study, the placement of the metallic Y-stent was easy to perform, in accordance to previous reports (7-11). The procedure often takes less than 40 minutes and no procedure failures was reported.

Several authors have reported the placement of metallic Y stents using flexible bronchoscope (17) or without fluoroscopy (18). In our series, we performed rigid bronchoscopy and fluoroscopy, which was considered safer compared to flexible bronchoscope in patients with extensive tumor infiltration, with narrow tracheobronchial lumen or significant bleeding risk during the procedure.

Here, we report the same rate of stent-related complications in the silicone Y stent group compared to the SEM Y stent group. Not fully covered self expanding stents have been reported to be more difficult to extract than silicone Y stents (16). The SEM Y stents used in this study are almost completely covered by a polypropylene coating except for the distal 5 mm of the right main bronchi, and the proximal tracheal branch. As other authors (10, 11), we found similar rates of stent removal between the two groups, and reported no complication upon removal of both stents. Therefore, the small uncovered parts of SEM Y stents does not seem to hamper the ability to remove the stent.

Our study has several limitations. First, it is a retrospective study conducted in a single center, with a small patient population and only a historical control group. Second, the period of time of Y Dumon stent placement is anterior to those of SEM Y stent placement with only 2 years of overlap period. However, the same fully trained operators performed the procedures in both periods. Third, our series includes only malignant stenoses and broncho-oesophageal fistula, and no conclusion could be drawn from the present study concerning the treatment of benign lesions. Finally, objective pulmonary function parameters and arterial blood gas levels were not evaluated before and after the procedure, which would have provided a more definitive means of determining the efficacy of airway recanalization.

### **CONCLUSION:**

If for benign obstruction the silicone Y stent remain the best solution, for malignant lesion of the main carina, SEMY stent seems to be an easy alternative for palliation in patients with malignant central airway obstruction or malignant airway-oesophageal fistula. It appears faster to place than Y silicone stents, and with no difference in terms of complication or removal possibility.

## ACKNOWLEDGMENTS

The authors are grateful to Nikki Sabourin-Gibbs, Rouen University Hospital, for her help in editing the manuscript.

### Authors contributions

SL and SC had full access to all of the data in the study and take responsibility for the integrity of the data and the accuracy of the data analysis, including and especially any adverse effects. SL, SC, MS, MR, SB, MS, and LT contributed substantially to the study design, data analysis and interpretation, and the writing of the manuscript.

## References

1. Ernst A, Feller-Kopman D, Becker HD, *et al.* Central airway obstruction. *Am J Respir Crit Care Med.* 2004;169(12):1278-97.
2. Freitag L, Ernst A, Unger M, *et al.* A proposed classification system of central airway stenosis. *Eur Respir J.* 2007;30(1):7-12.
3. Duranceau A, Jamieson GG. Malignant tracheoesophageal fistula. *Ann Thorac Surg.* 1984;37(4):346-54.
4. Burt M, Diehl W, Martini N, *et al.* Malignant esophagorespiratory fistula: management options and survival. *Ann Thorac Surg.* 1991;52(6):1222-8; discussion 8-9.
5. Dutau H, Toutblanc B, Lamb C, *et al.* Use of the Dumon Y-stent in the management of malignant disease involving the carina: a retrospective review of 86 patients. *Chest.* 2004;126(3):951-8
6. Hauck RW, Born P, Helmberger H, *et al.* Y-nitinol airway stent for management of central airway compression due to metastatic colon cancer. *Endoscopy.* 2003;35(10):858-60.
7. Yang RM, Han XW, Wu G, *et al.* Implantation of a self-expandable metallic inverted Y-stent to treat tracheobronchial stenosis in the carinal region: initial clinical experience. *Clin Radiol.* 2007;62(12):1223-8.
8. Conforti S, Durkovic S, Rinaldo A, Gagliardone MP, *et al.* Self-expanding y stent for the treatment of malignant tracheobronchial stenosis. Retrospective study. *Arch Bronconeumol.* 2016;52(11):e5-e7.
9. Han XW, Wu G, Li YD, *et al.* Overcoming the delivery limitation: results of an approach to implanting an integrated self-expanding Y-shaped metallic stent in the carina. *J Vasc Interv Radiol.* 2008;19(5):742-7.
10. Gompelmann D, Eberhardt R, Schuhmann M, *et al.* Self-expanding Y stents in the treatment of central airway stenosis: a retrospective analysis. *Ther Adv Respir Dis.* 2013;7(5):255-63.
11. Madan K, Dhooria S, Sehgal IS, *et al.* A Multicenter Experience With the Placement of Self-Expanding Metallic Tracheobronchial Y Stents. *J Bronchology Interv Pulmonol.* 2016;23(1):29-38.
12. Dutau H, Breen D, Bugalho A, *et al.* Current Practice of Airway Stenting in the Adult Population in Europe: A Survey of the European Association of Bronchology and Interventional Pulmonology (EABIP). *Respiration.* 2018;95(1):44-54.
13. Folch E, Keyes C. Airway stents. *Ann Cardiothorac Surg.* 2018;7(2):273-83.
14. Sehgal IS, Dhooria S, Madan K, *et al.* Placement of tracheobronchial silicone Y-stents: Multicenter experience and systematic review of the literature. *Lung India.* 2017;34(4):311-7.
15. Ost DE, Ernst A, Grosu HB, *et al.* Therapeutic bronchoscopy for malignant central airway obstruction: success rates and impact on dyspnea and quality of life. *Chest.* 2015;147(5):1282-98.
16. Dutau H, Musani AI, Plojoux J, *et al.* The use of self-expandable metallic stents in the airways in the adult population. *Expert Rev Respir Med.* 2014;8(2):179-90.
17. Fu YF, Wei N, Zhang K, *et al.* Subcarinal ventilation-assisted Y-shaped stent insertion under local anesthesia for patients with complex tracheobronchial stenosis: initial clinical experience. *Diagn Interv Radiol.* 2014;20(4):330-4.
18. Ozdemir C, Sokucu SN, Karasulu L, *et al.* Placement of self-expandable bifurcated metallic stents without use of fluoroscopic and guidewire guidance to palliate central airway lesions. *Multidiscip Respir Med.* 2016;11:15.

## Figure Legends

Figure 1a : Silicone Y stent (Dumon™, Novatech, Marseille)

Figure 1b : Self- expanding metallic Y stent (MICRO-TECH (Nanjing) Co., Ltd)

Table 1: patients' characteristics

	Silicone Y Stent	SEM Y Stent	p
<b>Mean age (min-max)</b>	<b>60.6 [38-85]</b>	<b>57.7 [37-78]</b>	<b>1</b>
<b>Sex (M/F)</b>	<b>25/15</b>	<b>28/10</b>	<b>0,38</b>
<b>Symptoms</b>			
Dyspnea	33 (82.5%)	27 (71.7%)	<b>NS</b>
Cough	22 (55%)	24 (63.2%)	
Hemoptysis	9 (22.5%)	11 (28.9%)	
Wheezing	9 (22.5%)	5 (13.2%)	
Pneumonia	1 (2.5%)	8 (21.1%)	
Dysphagia	3 (7.5%)	9 (23.7%)	
<b>Cancer origin</b>			
Lung	25 (62.5%)	22 (57.9%)	<b>0,76</b>
Esophageal	11 (27.5%)	14 (36.8%)	
Others	3 (7.5%)	2 (5.3%)	
NA	1 (2.5%)	0 (0%)	
<b>Stage of the disease</b>			
Metastatic	22 (55%)	24 (63.2%)	<b>0,49</b>
Locally advanced	18 (45%)	14 (36.8%)	
<b>Previous treatment</b>			
No	31 (77.5%)	18 (47.4%)	<b>0.0064</b>
Yes	9 (22.5%)	20 (52.6%)	
<b>ASA Score</b>			
I	0 (0%)	0 (0%)	<b>0,11</b>
II	4 (10%)	7 (18.4%)	
III	14 (35%)	21 (55.3%)	
IV	11 (27.5%)	6 (15.8%)	
V	1 (2.5%)	0 (0%)	
NA	10 (25%)	4 (10.5%)	
<b>Indication for stenting</b>			
Stenosis	35 (87.5%)	26 (68.4%)	<b>0,007</b>
Fistula	3 (7.5%)	10 (26.3%)	
Stenosis + fistula	2 (5%)	2 (5.3%)	

(abbreviations: SEM Y Stent: self-expanding metallic Y stent ; min: minimal; max: maximum; M : male; F= female; NA: Not available; NS: not significant)



Table 2: perioperative outcomes

	Silicone Y-Stent (n=40)	SEM Y Stent (n=38)	p
Recanalization procedure (%)	19 (55,9%)	19 (50%)	1
Failure of the Y Stent (n)	7 (17%)	0	0,008
Median OR time (minutes) (min-max)	124 (50-245)	90 (50-235)	< 0,001
Median procedure time (minutes) (min-max)	80 (25-210)	50 (25-110)	
Median procedure time (minutes) (without recanalization) (min-max)	50 (25-110)	40 (25-85)	0,17

(abbreviations: SEM Y: self-expanding metallic Y stent ; min: minimum; max: maximum; OR : operating room; NS: not significant)

Table 3: Post operative outcomes

	Silicone Y Stent (n= 33)	SEM Y Stent (n=39)	p
Symptom relief (n)	27 (81%)	32 (82%)	1
Complications (n)	18 (55%)	25 (65%)	0,120
Early complications (n) (<7 days)	9 (27%)	6 (15%)	0,25
Late complications (n) (>7days)	15 (46%)	23 (59%)	0,34
Mean duration of stent (days)	150.2 (8 - 707)	112 (1-540)	0,5
Stent removal (n)	9 (26.5%)	7 (18.4%)	0,4

(abbreviations: SEM Y: self-expanding metallic Y stent ; NS: not significant)

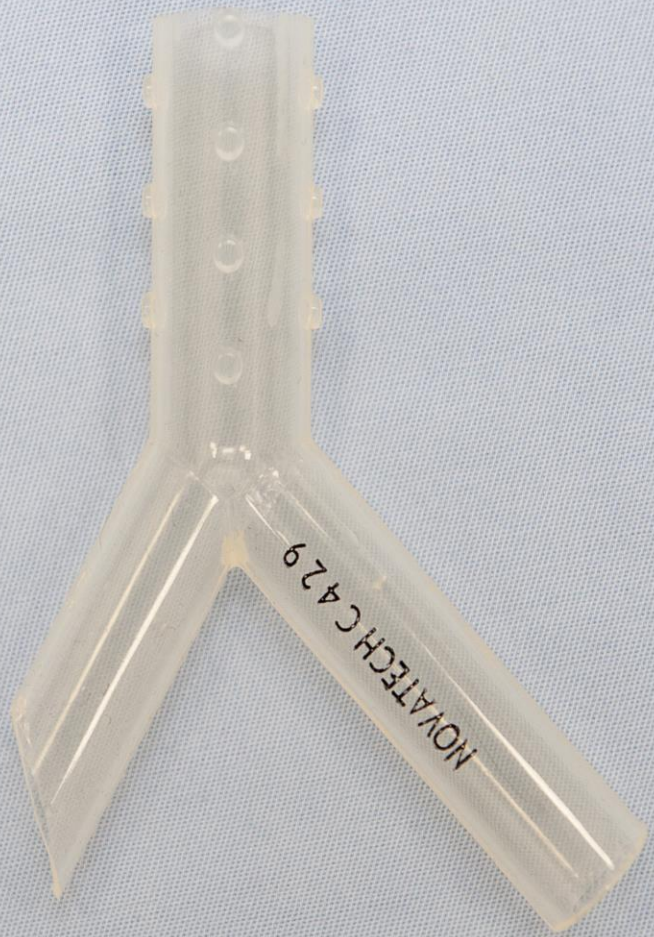


Figure 1a : Silicone Y stent (Dumon™, Novatech, Marseille)






Figure 1b : Self- expanding metallic Y stent  
(MICRO-TECH (Nanjing) Co., Ltd)