HAL open science

Impact of positron emission tomography with computed tomography for image-guided radiotherapy

V. Isnardi, S. Thureau, P. Vera

▶ To cite this version:

V. Isnardi, S. Thureau, P. Vera. Impact of positron emission tomography with computed tomography for image-guided radiotherapy. Cancer/Radiothérapie, 2020, 24 (5), pp.362-367. 10.1016/j.canrad.2020.03.006 . hal-02922493

HAL Id: hal-02922493

https://hal.science/hal-02922493v1

Submitted on 18 Jul 2022

HAL is a multi-disciplinary open access archive for the deposit and dissemination of scientific research documents, whether they are published or not. The documents may come from teaching and research institutions in France or abroad, or from public or private research centers.

L'archive ouverte pluridisciplinaire **HAL**, est destinée au dépôt et à la diffusion de documents scientifiques de niveau recherche, publiés ou non, émanant des établissements d'enseignement et de recherche français ou étrangers, des laboratoires publics ou privés.

Distributed under a Creative Commons Attribution - NonCommercial 4.0 International License

Version of Record: https://www.sciencedirect.com/science/article/pii/S1278321820300767
Manuscript_c9de47c9f4d927943e16c4365b16edd0

Impact of positon emission tomography with computed tomography for image-guided radiotherapy

Impact de la tomographie par émission de positons combinée à la scanographie pour la radiothérapie

Vanina ISNARDI [a], Sébastien THUREAU [b*,c,d,e,f], Pierre VERA [c,d,e,f]

[a] Department of Nuclear Medicine, centre Léon-Bérard, 28, promenade Léa-et-Napoléon-Bullukian, 69008 Lyon, France

[b] Department of Radiotherapy and Medical Physic, centre Henri-Becquerel, 1, rue d'Amiens, 76038 Rouen, France

[c] Department of Nuclear Medicine Cancer, centre Henri-Becquerel, 1, rue d'Amiens, 76038 Rouen, France

[d] CHU de Rouen, 1 rue de Germont, 76031 Rouen cedex, France

[e] CNRS, laboratoire QuantIF, EA4108-Litis, FR UMR 3638, 1, rue d'Amiens, 76000 Rouen, France

[f] Faculty of Medicine, université de Rouen Normandie, rue d'Amiens, 76000 Rouen, France

*Corresponding author; e-mail: sebastien.thureau@chb.unicancer.fr

Keywords

PET; radiotherapy; adaptative radiation.

Mots clé

TEP ; radiothérapie ; radiothérapie adaptative

Abstract

Therapeutic effectiveness in radiotherapy is partly related to correct staging of the disease and then precise therapeutic targeting. Positon emission tomography (PET) allows the stage of many cancers to be determined and therefore is essential before deciding on radiation treatment. The definition of the therapeutic target is essential to obtain correct tumour control and limit side effects. The part of

© 2020 published by Elsevier. This manuscript is made available under the CC BY NC user license
https://creativecommons.org/licenses/by-nc/4.0/

adaptive radiotherapy remains to be defined, but PET by its functional nature makes it possible to define the prognosis of many cancers and to consider radiotherapy adapted to the initial response allowing an increase over the entire metabolic volume, or targeted at a subvolume at risk per dose painting, or with a decrease in the dose in case of good response at interim assessment.

Résumé

L'efficacité thérapeutique en radiothérapie est en partie liée à un bilan correct de la maladie et ensuite à une définition précise de la cible thérapeutique. La tomographie par émission de positrons (TEP) permet de préciser le stade de nombreux cancers et est donc essentielle avant de décider d'une radiothérapie. Par la suite, elle permet de définir de manière précise le volume cible, étape essentielle pour obtenir un contrôle correct de la tumeur et limiter les effets secondaires. La partie de la radiothérapie adaptative reste à définir, mais la TEP par sa nature fonctionnelle permet de définir le pronostic de nombreux cancers et d'envisager une radiothérapie adaptée à la réponse initiale permettant une augmentation sur l'ensemble du volume métabolique, ou de cibler sur un sous-volume à risque par « dose painting », ou encore une diminution de la dose en cas de bonne réponse lors du bilan pendant la radiothérapie.

1. Introduction

Latest technical and technological improvements in the field of radiotherapy allow to deliver higher doses to the tumour, and to improve protection of healthy tissues. Thus, an accurate delineation of the target volume is crucial, in order to improve local control, with limited toxicity.

To achieve this purpose, target volume delineation relies on multimodality imaging. CT, even with contrast media is often limited but remains mandatory to establish treatment planification. Magnetic resonance imaging (MRI) and positon emission tomography with computed tomography (PET/CT), with (^{18}F)-fluorodeoxyglucose (FDG) or other tracers, give further information about tumour boundaries and intrinsic characteristics, and has become essential to the radiotherapist's toolbox. Moreover, both modalities could lead to a more personalized treatment with the concepts of dose escalation or de-escalation, dose painting, and adaptative radiotherapy.

In 2009, the International Atomic Energy Agency (IAEA) expert report already encouraged the routine use of FDG PET/CT in radiotherapy planning for non-small cell lung cancer and the potential interest for head and neck cancer, lymphoma and oesophageal cancer (1). However, it also alerted to the need of rigorous and consistently applied protocols, with a chain of quality control. The segmentation method of PET/CT images also needs to be chosen carefully, as to this date, no reference segmentation method exists (2). These items have already been discussed in a previous issue (3).

In this article we will present data supporting the use of PET/CT for radiotherapy planning in daily practice, in lung cancer, head and neck cancer, oesophagus cancer and lymphoma. Then we will discuss about other tumour location in which PET/CT could improve tumour delineation and the potential role of PET/CT for dose escalation, dose painting and adaptative radiotherapy, with the help of FDG or other tracers.

2. Data supporting the use of PET/CT for radiotherapy planning in daily practice

2.1. Non-small cell lung cancer

FDG PET/CT is currently recommended in the initial staging of non-small cell lung cancer for non- or oligometastatic patient in order to confirm that the patient is candidate to a local treatment (4). It enables detection of unknown metastases in about 10 to 20 % patients with apparent stage III cancer (5). Several studies have shown an impact of FDG PET/CT on radiotherapy planning in more than 30% of patients, leading to a cancellation in case of distant metastases or to a modification of radiotherapy target volume (5-7).

Concerning the primary tumour, FDG PET/CT allows to exclude atelectasis and thus to reduce target volume, and to improve inter-observer variability in tumour delineation (8,9).

Concerning the nodal target volume, in a phase II comparative study, Bradley et al. have shown that disagreements between CT and FDG PET/CT occurred in about 50% of patients, confined mainly to one or two nodal stations (5). FDG PET/CT shows good performances for nodal staging in non-small cell lung cancer, better than CT, with a median sensitivity and a specificity of 85% and 90% respectively (61 % and 79% for CT), and a negative predictive value superior to 90% in case of T1-T2 tumour (10,11). Two prospective studies have demonstrated low rate of isolated nodal failure, less than 5 % with selective nodal irradiation principle, based on FDG PET/CT for non-small cell lung cancer (5,12).

In summary, as specified in the guidelines from the European Organization for Research and Treatment of Cancer (EORTC) published in 2010 (13):

- it is reasonable to delineate the tumour on the basis of FDG PET/CT to reduce the irradiated volume in case of atelectasis;
- it is recommended to include FDG positive nodes in the gross tumour volume, even if they are not enlarged in CT, and if histologic examination is not feasible to exclude false positive;
- but it requires strict standardization of PET/CT acquisition, and to keep in mind that a rapid decrease of FDG uptake could occur soon after the onset of chemotherapy.

2.2. Squamous cell carcinoma of the head and neck

FDG PET/CT is currently recommended for initial staging of locally advanced squamous cell carcinoma of the head and neck (stage III/IV) in order to detect distant metastasis, but could also be proposed in any stage if synchronous localisations could impact later treatment (4).

FDG PET/CT helps primary tumour detection in squamous cell carcinoma of the head and neck and undifferentiated nasopharyngeal tumour with a reported overall sensitivity of 93 to 100%, specificity of 90 to 100% and an accuracy of 94 to 98% (14). And in case of cervical lymph node metastasis of an unknown primary tumour, FDG PET/CT is able to detect about 25% of occult primary tumours (15). Furthermore, it has been shown that the introduction of FDG PET/CT led to significantly smaller gross tumour volumes for pharyngolaryngeal squamous cell carcinoma than those delineated on CT or MRI (15). A comparison with the laryngeal specimens showed that FDG PET gross tumour volumes were the closest to the histologic ones.

Concerning nodal metastases detection, FDG PET/CT shows diagnostic performances comparable to CT and anatomical MRI, and seemed to be outperformed by diffusion-weighted MRI (16). In addition, its sensitivity dropped off in case of no clinical evidence of metastatic nodes (17). Thus it is not routinely recommended for the nodal staging. International guidelines published in 2018 recommend the inclusion of FDG PET/CT data for the delineation of the gross tumour volume of the primary cancer, for locally advanced tumour, besides clinical examination, endoscopic, CT and MRI data (18). Although there is currently no standard segmentation defined, they recommend the use of user-independent segmentation algorithms.

2.3. Oesophageal cancer

FDG PET/CT is currently recommended in the initial staging of oesophageal cancer as it allows for improved detection of distant metastasis, with a sensitivity and specificity of 71% and 93%, better than CT (52% and 91 % respectively), especially coeliac and supraclavicular metastatic nodes (4,19).

Some studies reported a significant positive correlation between FDG PET/CT-based tumour lengths and pathological findings, often with a visual segmentation method or with the use of a predefined threshold (19-21). However a more recent study has shown significant differences in tumour lengths estimated by PET or endoscopic ultrasound (20). The endoscopic ultrasound length was more than 2 cm longer than the PET length in 38% of cases, and the PET length was greater than 2cm longer than the endoscopic ultrasound length in 5% of cases, suggesting the complementarity of both modalities to define the gross tumour volume of the primary cancer.

Thus, the potential impact of FDG PET/CT on the planning target volume relies on its ability to detect distant node metastasis, and to help to better define craniocaudal limits, as confirmed in few studies

(21-24). More recently, Metzger et al. have reported that the use of FDG PET/CT for staging and planning of primary or neoadjuvant chemoradiotherapy for oesophageal cancer has a favourable impact on patient survival (25).

2.4. High grade lymphoma

FDG PET/CT is well known as the most accurate imaging method for determining disease extent, nodal and extranodal, in high grade lymphoma, Hodgkin and non-Hodgkin diseases (26). Moreover, FDG PET/CT performed after treatment is an effective tool for discriminating residual active disease from fibrotic masses, with a higher sensitivity for Hodgkin lymphoma and higher specificity for non-Hodgkin lymphoma (27,28).

Simultaneously, new radiotherapeutic strategies for lymphoma has been developed, more targeted, with more accurate and reduced field, in order to limit long-term adverse events. In particular, the involved site and the involved node radiotherapy principles have emerged for definitive radiotherapy of early stage Hodgkin lymphoma.

Thus, FDG PET/CT is mandatory first for selecting patients candidate to definitive radiotherapy, by confirming an early stage for Hodgkin lymphoma, and characterizing a residual mass at the end of treatment of non-Hodgkin lymphoma, and second for helping to define treatment field. In particular, pretreatment FDG PET/CT is required for the application of the involved site and involved node radiotherapy principles in both early stage of Hodgkin and non Hodgkin lymphomas (29-32). This pretreatment FDG PET/CT needs to be performed in treatment position in case of involved node radiotherapy (33). But as it is often logistically difficult to obtain this first PET/CT in treatment position, involved site radiotherapy allows for larger margins around the initially involved nodes. Furthermore, close collaboration between radiation oncologists and nuclear medicine physicians is highly encouraged, and the latter should use a common atlas of nodal station in their reports (33-35).

2.5. Other tumour locations

There is growing interest for the use of PET/CT in other tumour locations with FDG or other PET tracers.

Prostate-specific PET tracers are of interest for patients with a biochemical recurrence of prostate cancer, especially when salvage radiotherapy could be performed. Salvage radiotherapy should be performed as early as possible, optimally when serum prostate-specific antigen levels are below 0.5 ng/ml. Prostate-specific membrane antigen (PSMA) PET tracers show better performances than choline tracers and fuciclovine, with compared median detection rate of 51.5% , 19.5% and 38% respectively for PSA levels below 1 ng/ml (36). In a recent meta-analysis, Perera et al. reported PSMA PET detection rates of 33 % for PSA levels below 0.2 ng/ml and 46% for PSA levels 0.2 to less than

0.5 ng/ml, in patients with biochemical recurrence after radical prostatectomy (37). In addition, another meta-analysis reported that PSMA PET increased the proportion of patients assigned to radiotherapy from 56% to 62%, and that 24 % of patients received increased dose to the sites of suspected recurrence and/or an enlarged target volume including the sites of recurrence, while 20% received stereotactic body radiotherapy to single metastases or oligometastasis (38).

For anal cancer, FDG PET/CT could provide additional information that could lead to major changes in treatment strategy in almost one in five patients, but induces changes in irradiated field in only 4% (39). Nevertheless, Bassi et al. observed a change in gross tumour volume, with a mean increase of 25 % (40).

FDG PET/CT could also be useful in other tumour location, once the lesions show a significant uptake, as for example in liver metastasis and cholangiocarinomas, in primary cardiac tumour, or in case of reirradiation, particularly when conventionnal imaging is of limited performance, when iodine contrast media is contra-indicated or when the patient is wearing a pacemaker or any metallic devices preventing MRI (41-43). But one should keep in mind the intrinsic PET limitations such as a rather low spatial resolution and a high level of noise (16).

3. Potential role of PET/CT for dose escalation, dose painting and adaptative radiotherapy

Current radiotherapy techniques allow us to consider delivering heterogeneous doses within the target volume. With the routine use of intensity-modulated radiation for the treatment of many cancer (head and neck, brain tumour, lung cancer, etc.) allowing to deliver a very precise dose to the gross tumour volume, but there is still a risk of local recurrences confirming the presence of radioresistant areas. Functional imaging allows considering the selection of these areas (biological target volume) in order to deliver a variable dose depending on the risk of recurrence (44). This imaging can be used before the start of radiotherapy as a complement to the planning scanner or during treatment to adapt to the early response. Several tracers can be used to target areas and the choice of tracer will depend on the location treated; the most commonly used tracers are those used to target hypoxia, proliferation or tumour metabolism. In this context, the method of definition and segmentation of target volumes is important and it has been demonstrated that the delineation method has an impact on the defined volume. Many methods exist and have been reworked in a previous article (3).

3.1. Non small cell lung cancer

As mentioned in the previous chapter, PET/CT is recommended in the staging and the planning for non small cell lung cancer treated by radiation. While the level of evidence is lower and currently does not allow consideration of dose painting radiotherapy from PET, many studies confirm its value in defining patients at risk of recurrence and radioresistant areas. For example, several studies have

shown the prognostic implications of changes in standardized uptake value and suggested that FDG PET/CT could predict the response to chemoradiation or induction chemotherapy (45,46). FDG is the tracer that has been most used to propose a dose adapted to pretherapeutic PET. Three studies have shown that the most hypermetabolic area before radiotherapy was an area at risk of local recurrence (47-49). The same results were found for stereotactic radiotherapy for lung cancer (50). A randomized phase II study (NCT01024829) has now been completed and has focused on increasing the dose with an integrated boost to the area of the primary tumor with 50% of the maximum standardized uptake value (72Gy) according to the normal tissue tolerance. Initial toxicity results demonstrate the feasibility of this dose increase (51). The first alternative to this adapted radiotherapy to FDG PET is the use of other tracers in pretherapeutic examinations. For the proliferation with 3'-(^{18}F)-fluoro-3'-deoxythymidine (FLT), there is only preclinical data or studies showing the feasibility of using this tracer for lung cancer (52-54). The tracer for which we have the most data is the (^{18}F)-labelled misonidazole that allows to define hypoxic zones with PET/CT. In particular, there is a French phase II trial that confirms the possibility of boosting the hypoxic zone without increasing toxicity. In addition, a boost to the hypoxic volumes appears to improve the survival of hypoxic patients compared to those receiving a standard dose (55, 56) (figure 1). This strategy based on hypoxia is different from a boost on hypermetabolic volume with a specific therapeutic impact (57, 58). However, Di Perri et al. consider that there is a good correlation between hypoxic volumes and FDG hotspots, but not from our group (58,59).

The third alternative is to adapt the dose to changes in PET during radiotherapy. In a previous study, we had shown that it was possible to define a pertreatment segmentation method for both primary tumour and lymph nodes (60). In this context, a French phase II/III study is ongoing to demonstrate the interest of increasing the dose at 74Gy on the hypermetabolic volume during radiotherapy (at 42Gy) (RTEP7 - NCT02473133). A similar phase II trial has just completed including 138 patients to study the use of FDG PET/CT between the 18th and 19th fraction with a dose determined by contraints at organs at risk (RTOG 1106 - NCT01507428).

3.2. Squamous cell carcinoma of the head and neck

With lung cancers, head and neck cancers are the ones for which there are the most published and ongoing studies. It's for this location that the Brussels teams proposed a dose adapted to PET fixation using two methods. The first strategy is a boost at a subvolume. It is the simplest technique and close to the usual techniques in case of several dose levels, the name generally used for this strategy is "dose painting by volume". The second strategy "dose painting by numbers" is very interesting because it proposes to assign a dose to each voxel according to its level of PET fixation (61).

Many studies confirm the feasibility of a boost based on FDG fixation without increasing the dose to the organs at risk (62,63). Two studies are in progress on ClinicalTrial.gov focusing on dose painting

using FDG PET with adaptive dose escalation compared to standard treatment. The dose usually proposed is about 80Gy over the radioresistance area; it has been shown that a higher dose can be harmful with a risk of late mucosal ulcers (64).

As confirmed very recently, hypoxia makes it possible to select patients with a good or poor prognosis, with a hazard ratio at 9 for local control in a study involving 37 patients (65). As FDG, it has been shown that it is possible to increase the dose to more than 80Gy without increasing the dose to at-risk organs. For head and neck, several tracers were tested, such as (^{18}F)-labelled misonidazole azomycin arabinoside, flortanidazole (HX4), or erythronitroimidazole, or (^{64}Cu)-labelled diacetyl-bis(N4-methylthiosemicarbazone (ATSM). Studies based on an equivalent probability of tumor control between normoxic and hypoxic tumors show that an increase of 15 to 20% in hypoxic volumes is possible without increasing the dose to organs at risk (66).

A new strategy could be considered with a dose reduction for Human papilloma virus positive cancers with hypoxia. If this hypoxia is resolved within 1 week of treatment, a selectively de-escalate dose to the nodes (60Gy) is possible with a good local control (67).

The problem remains linked to the anatomical modification of lesions during radiotherapy and therefore to the difficulty of targeting radioresistant voxels (68).

3.3. Oesophageal cancer

For oesophageal cancer, there are far fewer studies for adaptive radiotherapy. However, it is a cancer for which the optimal dose of radiotherapy remains to be defined and for which the level of toxicity remains high.

As with lung cancers, it appears that the most hypermetabolic area before treatment is an area at risk of recurrence (69). Another French study proposes to define the target volume based on an automatic segmentation of the FDG PET to allow a decrease in dose to organs at risk or an increase in dose up to 66Gy (70).

FLT PET, which represents proliferation, appears to be an interesting tracer both in initial planning and in the early response. (71-73). Data on hypoxia in oesophageal cancers are very limited. While it is confirmed that there is significant binding of hypoxia tracers in esophageal cancers, there is no adaptive radiotherapy study based on these tracers (74).

3.4. Other tumour locations

3.4.1. Gynaecological cancer

In most other cancers, pretreatment PET is used to consider targeted boosts. This is case for pelvic cancers, particularly cervical and prostate cancer. PET is often associated with MRI. For cervical

cancer, it has been shown that it is possible to consider boosting pathological pelvic lymph nodes to about 60Gy (75,76). However, this strategy remains controversial and if it does not increase toxicity, it is difficult to demonstrate the value in terms of tumour control. Indeed, the most important study on the interest of a boost on pathological lymph nodes was retrospective and did not use PET (77).

3.4.2. Prostatic cancer

As we have seen previously, there are specific tracers for prostatic cancer with choline or PSMA. FDG PET/CT has no place in radiotherapy planning. During definitive primary radiotherapy, dose escalation to the prostate should improve the local control, but the local toxicity remains high. More accurate determination of the dominant intraprostatic lesion, which is the more aggressive and less responding lesion, should lead to diminish local toxicity while preserving local tumour control (78,79). There is growing of interest for PSMA PET/CT to this purpose. As PSMA uptake is known to be correlated to the aggressiveness of the lesions, a miss of low grade intraprostatic lesions seems to be acceptable for radiotherapy purposes (80), and a PSMA PET gross tumour volume contouring finally appears to be feasible in 95 % of patients (81). Some studies suggested that (^{68}Ga)-labelled PSMA PET gives complementary data to the multiparametric MRI for the delineation of the dominant intraprostatic lesion (82). It has been demonstrated that it is possible to increase the dose up to 95Gy from combining multiparametric MRI and PET data using tumour control probability calculations (83).

4. Conclusion

PET/CT has become essential in the planning of many cancers including lung, head and neck, Hodgkin's disease and prostate cancer (table 1). However, it sometimes has to be combined with MRI imaging and segmentation methods have yet to be defined. The interest of PET/MRI must be demonstrated in prospective studies. The development of targeted treatments for recurrent areas requires imaging with very good sensitivity and specificity, as is the case for prostate cancers. Current techniques allow us to consider treatments by dose painting or even adaptive dose painting, and in this context, it seems that functional imaging is essential. However, it is now impossible to say that the best functional imaging is still that of metabolism, hypoxia or proliferation.

Disclosure

The authors declare that they have no conflict of interests.

References

1. MacManus M, Nestle U, Rosenzweig KE, Carrio I, Messa C, Belohlavek O, et al. Use of PET and PET/CT for radiation therapy planning: IAEA expert report 2006–2007. Radiother Oncol 2009;91(1):85-94.

2. Im H-J, Bradshaw T, Solaiyappan M, Cho SY. Current methods to define metabolic tumor volume in positron emission tomography: which one is better? Nucl Med Mol Imaging 2018;52(1):5-15.

3. Thureau S, Texte E, Decazes P, Gensanne D, Gouel P, Modzelewski R, et al. [Definition of target volume: When et how can the radiation oncologist use PET?] Cancer Radiother 2019;23(6-7):745-752.

4. Salaün PY, Abgral R, Malard O, Querellou-Lefranc S, Quere G, Wartski M, et al. Good clinical practice recommendations for the use of PET/CT in oncology. Eur J Nucl Med Mol Imaging 2020;47(1):28-50.

5. Bradley J, Bae K, Choi N, Forster K, Siegel BA, Brunetti J, et al. A phase II comparative study of gross tumor volume definition with or without PET/CT fusion in dosimetric planning for non–small-cell lung cancer (NSCLC): primary analysis of Radiation Therapy Oncology Group (RTOG) 0515. Int J Radiat Oncol Biol Phys 2012;82(1):435-41.e1

6. Mac Manus MP, Hicks RJ. The role of positron emission tomography/computed tomography in radiation therapy planning for patients with lung cancer. Semin Nucl Med 2012;42(5):308-19. S

7. Pommier P, Touboul E, Chabaud S, Dussart S, Le Pechoux C, Giammarile F, et al. Impact of (^{18}F)-FDG PET on treatment strategy and 3D radiotherapy planning in non-small cell lung cancer: A prospective multicenter study. AJR Am J Roentgenol. 2010;195(2):350-5.

8. Nestle U, Walter K, Schmidt S, Licht N, Nieder C, Motaref B, et al. (^{18}F)-deoxyglucose positron emission tomography (FDG-PET) for the planning of radiotherapy in lung cancer: high impact in patients with atelectasis. Int J Radiat Oncol Biol Phys 1999;44(3):593-7.

9. Steenbakkers RJHM, Duppen JC, Fitton I, Deurloo KEI, Zijp LJ, Comans EFI, et al. Reduction of observer variation using matched CT-PET for lung cancer delineation: A three-dimensional analysis. Int J Radiat Oncol 2006;64(2):435-48.

10. Gould MK, Kuschner WG, Rydzak CE, Maclean CC, Demas AN, Shigemitsu H, et al. Test performance of positron emission tomography and computed tomography for mediastinal staging in patients with non-small-cell lung cancer: a meta-analysis. Ann Intern Med 2003;139(11):879-92.

11. Wang J, Welch K, Wang L, Kong F-MS. Negative predictive value of positron emission tomography and computed tomography for stage T1-2N0 non-small-cell lung cancer: a meta-analysis. Clin Lung Cancer 2012;13(2):81-9.

12. De Ruysscher D, Wanders S, van Haren E, Hochstenbag M, Geeraedts W, Utama I, et al. Selective mediastinal node irradiation based on FDG-PET scan data in patients with non-small-cell lung cancer: a prospective clinical study. Int J Radiat Oncol Biol Phys 2005;62(4):988-94.

[1]13. De Ruysscher D, Faivre-Finn C, Nestle U, Hurkmans CW, Le Péchoux C, Price A, et al. European Organisation for Research and Treatment of Cancer recommendations for planning and delivery of high-dose, high-precision radiotherapy for lung cancer. J Clin Oncol 2010;28(36):5301-10.

14. Troost EGC, Schinagl DAX, Bussink J, Oyen WJG, Kaanders JHAM. Clinical evidence on PET-CT for radiation therapy planning in head and neck tumours. Radiother Oncol 2010;96(3):328-34.

15. Daisne J-F, Duprez T, Weynand B, Lonneux M, Hamoir M, Reychler H, et al. Tumor volume in pharyngolaryngeal squamous cell carcinoma: comparison at CT, MR imaging, and FDG PET and validation with surgical specimen. Radiology 2004;233(1):93-100.

16. Grégoire V, Thorwarth D, Lee JA. Molecular imaging-guided radiotherapy for the treatment of head-and-neck squamous cell carcinoma: does it fulfill the promises? Semin Radiat Oncol 2018;28(1):35-45.

17. Kyzas PA, Evangelou E, Denaxa-Kyza D, Ioannidis JPA. (^{18}F)-fluorodeoxyglucose positron emission tomography to evaluate cervical node metastases in patients with head and neck squamous cell carcinoma: a meta-analysis. J Natl Cancer Inst 2008;100(10):712-20.

18. Lee AW, Ng WT, Pan JJ, Poh SS, Ahn YC, AlHussain H, et al. International guideline for the delineation of the clinical target volumes (CTV) for nasopharyngeal carcinoma. Radiother Oncol 2018;126(1):25-36.

19. van Vliet EPM, Heijenbrok-Kal MH, Hunink MGM, Kuipers EJ, Siersema PD. Staging investigations for oesophageal cancer: a meta-analysis. Br J Cancer 2008;98(3):547-57.

20. Foley KG, Morgan C, Roberts SA, Crosby T. Impact of positron emission tomography and endoscopic ultrasound length of disease difference on treatment planning in patients with oesophageal cancer. Clin Oncol (R Coll Radiol) 2017;29(11):760-766.

21. Moureau-Zabotto L, Touboul E, Lerouge D, Deniaud-Alexandre E, Grahek D et al. [Impact of computed tomography (CT) and 18F-deoxyglucose positron emission tomography (FDG-PET) image fusion for conformal radiotherapy in esophageal carcinoma.] Cancer Radiother 2005;9(3):152-60.

22. Schreurs LM, Busz DM, Paardekooper GM, Beukema JC, Jager PL, Van der Jagt EJ, et al. Impact of 18-fluorodeoxyglucose positron emission tomography on computed tomography defined target volumes in radiation treatment planning of esophageal cancer: reduction in geographic misses with

equal inter-observer variability: PET/CT improves esophageal target definition. Dis Esophagus 2010;23(6):493-501.

23. Le Grange F, Wickers S, Warry A, Warrilow J, Bomanji J, Tobias JS. Defining the target in cancer of the oesophagus: direct radiotherapy planning with fluorodeoxyglucose positron emission tomography-computed tomography. Clin Oncol (R Coll Radiol) 2015;27(3):160-7.

24. Muijs CT, Beukema JC, Woutersen D, Mul VE, Berveling MJ, Pruim J, et al. Clinical validation of FDG-PET/CT in the radiation treatment planning for patients with oesophageal cancer. Radiother Oncol 2014;113(2):188-92.

25. Metzger J-C, Wollschläger D, Miederer M, Vaupel P, Moehler M, Schmidberger H, et al. Inclusion of PET-CT into planning of primary or neoadjuvant chemoradiotherapy of esophageal cancer improves prognosis. Strahlenther Onkol 2017;193(10):791-799.

26. Gallamini A, Borra A. Role of PET in lymphoma. Curr Treat Options Oncol 2014;15(2):248-61.

27. Zijlstra JM, Lindauer-van der Werf G, Hoekstra OS, Hooft L, Riphagen II, Huijgens PC. (^{18}F)-fluorodeoxyglucose positron emission tomography for post-treatment evaluation of malignant lymphoma: a systematic review. Haematologica 2006;91(4):522-9.

28. Terasawa T, Nihashi T, Hotta T, Nagai H. (^{18}F)-FDG PET for posttherapy assessment of Hodgkin's disease and aggressive Non-Hodgkin's lymphoma: a systematic review. J Nucl Med 2008;49(1):13-21.

29. Specht L, Yahalom J, Illidge T, Berthelsen AK, Constine LS, Eich HT, et al. Modern radiation therapy for Hodgkin lymphoma: field and dose guidelines from the international lymphoma radiation oncology group (ILROG). Int J Radiat Oncol Biol Phys 2014;89(4):854-62.

30. Zelenetz AD, Wierda WG, Abramson JS, Advani RH, Andreadis CB, Bartlett N, et al. Non-Hodgkin's Lymphomas, version 3.2012. J Natl Compr Canc Netw 2012;10(12):1487-98.

31. Girinsky T, Ghalibafian M, Bonniaud G, Bayla A, Magne N, Ferreira I, et al. Is FDG-PET scan in patients with early stage Hodgkin lymphoma of any value in the implementation of the involved-node radiotherapy concept and dose painting? Radiother Oncol 2007;85(2):178-86.

32. Girinsky T, Specht L, Ghalibafian M, Edeline V, Bonniaud G, Van Der Maazen R, et al. The conundrum of Hodgkin lymphoma nodes: to be or not to be included in the involved node radiation fields. The EORTC-GELA lymphoma group guidelines. Radiother Oncol 2008;88(2):202-10.

33. Édeline V, Remouchamps V, Isnardi V, Vander Borght T. Multimodality imaging using PET/CT (^{18}F)-fluorodeoxyglucose for radiotherapy field delineation of localized Hodgkin lymphoma. Cancer Radiother 2018;22(5):384-392.

34. Terezakis SA, Schöder H, Kowalski A, McCann P, Lim R, Turlakov A, et al. A prospective study of ^{18}FDG-PET with CT coregistration for radiation treatment planning of lymphomas and other hematologic malignancies. Int J Radiat Oncol Biol Phys 2014;89(2):376-83.

35. Girinsky T, Aupérin A, Ribrag V, Elleuch M, Fermé C, Bonniaud G, et al. Role of FDG-PET in the implementation of involved-node radiation therapy for Hodgkin lymphoma patients. Int J Radiat Oncol Biol Phys 2014;89(5):1047-1052.

36. Evans JD, Jethwa KR, Ost P, Williams S, Kwon ED, Lowe VJ, et al. Prostate cancer-specific PET radiotracers: A review on the clinical utility in recurrent disease. Pract Radiat Oncol 2018;8(1):28-39.

37. Perera M, Papa N, Christidis D, Wetherell D, Hofman MS, Murphy DG, et al. Sensitivity, specificity, and predictors of positive (^{68}Ga)-prostate-specific membrane antigen positron emission tomography in advanced prostate cancer: a systematic review and meta-analysis. Eur Urol 2016;70(6):926-937

38. Han S, Woo S, Kim YJ, Suh CH. Impact of (^{68}Ga)-PSMA PET on the management of patients with prostate cancer: a systematic review and meta-analysis. Eur Urol 2018;74(2):179-190.

39. Heriot AG, Hicks RJ, Drummond EGP, Keck J, Mackay J, Chen F, et al. Does positron emission tomography change management in primary rectal cancer? A prospective assessment. Dis Colon Rectum 2004;47(4):451-8.

40. Bassi MC, Turri L, Sacchetti G, Loi G, Cannillo B, La Mattina P, et al. FDG-PET/CT imaging for staging and target volume delineation in preoperative conformal radiotherapy of rectal cancer. Int J Radiat Oncol Biol Phys 2008;70(5):1423-6.

41. Bundschuh RA, Andratschke N, Dinges J, Duma MN, Astner ST, Brügel M, et al. Respiratory gated (^{18}F)FDG PET/CT for target volume delineation in stereotactic radiation treatment of liver metastases. Strahlenther Onkol 2012;188(7):592-8.

42. Onal C, Topuk S, Yapar AF, Yavuz M, Topkan E, Yavuz A. Comparison of computed tomography- and positron emission tomography-based radiotherapy planning in cholangiocarcinoma. Onkologie 2013;36(9):484-90.

43. Elsayad K, Scobioala S, Kriz J, Haverkamp U, Eich HT. Advances in image-guided radiation therapy for primary cardiac angiosarcoma: the role of PET-CT and MRI. Oncol Res Treat 2016;39(5):290-4.

44. Roberts HJ, Zietman AL, Efstathiou JA. Painting Dose: The ART of radiation. Int J Radiat Oncol Biol Phys 2016;96(4):722-728.

45. Abramyuk A, Tokalov S, Zöphel K, Koch A, Szluha Lazanyi K, Gillham C, et al. Is pre-therapeutical FDG-PET/CT capable to detect high risk tumor subvolumes responsible for local failure in non-small cell lung cancer? Radiother Oncol 2009;91(3):399-404.

46. Ganem J, Thureau S, Gouel P, Dubray B, Salaun M, Texte E, et al. Prognostic value of post-induction chemotherapy (^{18}F)-FDG PET-CT in stage II/III non-small cell lung cancer before (chemo-) radiation. PLoS One 2019;14(10):e0222885.

47. Aerts HJ, van Baardwijk AA, Petit SF, Offermann C, Loon Jv, Houben R, et al. Identification of residual metabolic-active areas within individual NSCLC tumours using a pre-radiotherapy (^{18}F)-fluorodeoxyglucose-PET-CT scan. Radiother Oncol 2009;91(3):386-92.

48. Calais J, Thureau S, Dubray B, Modzelewski R, Thiberville L, Gardin I, et al. Areas of high (^{18}F)-FDG uptake on preradiotherapy PET/CT identify preferential sites of local relapse after chemoradiotherapy for non-small cell lung cancer. J Nucl Med 2015;56(2):196-203.

49. Jouglar E, Isnardi V, Goulon D, Ségura-Ferlay C, Ayadi M, Dupuy C, et al. Patterns of locoregional failure in locally advanced non-small cell lung cancer treated with definitive conformal radiotherapy: Results from the Gating 2006 trial. Radiother Oncol 2018;126(2):291-299.

50. Park J, Choi Y, Ahn KJ, Park SK, Cho H, Lee JY. Maximum standardized uptake value at pre-treatment PET in estimating lung cancer progression after stereotactic body radiotherapy. Radiat Oncol J 2019;37(1):30-36.

51. van Diessen J, De Ruysscher D, Sonke JJ, Damen E, Sikorska K, Reymen B, et al. The acute and late toxicity results of a randomized phase II dose-escalation trial in non-small cell lung cancer (PET-boost trial). Radiother Oncol 2019;131:166-173

52. Li C, Zhang X, Pang L, Huang Y, Gao Y, Sun X, et al. Spatial concordance of tumor proliferation and accelerated repopulation from pathologic images to 3'-(^{18}F)-fluoro-3'-deoxythymidine PET images: a basic study guided for PET-based radiotherapy dose painting. Mol Imaging Biol 2019;21(4):713-721.

53. Vera P, Bohn P, Edet-Sanson A, Salles A, Hapdey S, Gardin I, et al. Simultaneous positron emission tomography (PET) assessment of metabolism with (^{18}F)-fluoro-2-deoxy-d-glucose (FDG), proliferation with (^{18}F)-fluoro-thymidine (FLT), and hypoxia with (^{18}F)-fluoro-misonidazole (F-miso) before and during radiotherapy in patients with non-small-cell lung cancer (NSCLC): a pilot study. Radiother Oncol 2011;98(1):109-16.

54. Lelandais B, Ruan S, Denœux T, Vera P, Gardin I. Fusion of multi-tracer PET images for dose painting. Med Image Anal 2014;18(7):1247-59.

55. Vera P, Thureau S, Chaumet-Riffaud P, Modzelewski R, Bohn P, Vermandel M, et al. Phase II study of a radiotherapy total dose increase in hypoxic lesions identified by (^{18}F)-misonidazole PET/CT in patients with non-small cell lung carcinoma (RTEP5 Study). J Nucl Med 2017;58(7):1045-1053.

56. Vera P, Mihailescu SD, Lequesne J, Modzelewski R, Bohn P, Hapdey S, et al. Radiotherapy boost in patients with hypoxic lesions identified by (^{18}F)-FMISO PET/CT in non-small-cell lung carcinoma: can we expect a better survival outcome without toxicity? [RTEP5 long-term follow-up]. Eur J Nucl Med Mol Imaging 2019;46(7):1448-1456.

57. Thureau S, Dubray B, Modzelewski R, Bohn P, Hapdey S, Vincent S, et al. FDG and FMISO PET-guided dose escalation with intensity-modulated radiotherapy in lung cancer. Radiat Oncol 2018;13(1):208

58. Thureau S, Modzelewski R, Bohn P, Hapdey S, Gouel P, Dubray B, et al. Comparison of hypermetabolic and hypoxic volumes delineated on (^{18}F)-FDG and (^{18}F)-fluoromisonidazole PET/CT in non-small-cell lung cancer patients. Mol Imaging Biol 2019;DOI: 10.1007/s11307-019-01422-6 .

59. Di Perri D, Lee JA, Bol A, Hanin FX, Janssens G, Labar D, et al. Correlation analysis of (^{18}F)-fluorodeoxyglucose and (^{18}F)-fluoroazomycin arabinoside uptake distributions in lung tumours during radiation therapy. Acta Oncol 2017;56(9):1181-1188.

60. Ganem J, Thureau S, Gardin I, Modzelewski R, Hapdey S, Vera P. Delineation of lung cancer with FDG PET/CT during radiation therapy. Radiat Oncol 2018;13(1):219.

61. Grégoire V, Jeraj R, Lee JA, O'Sullivan B. Radiotherapy for head and neck tumours in 2012 and beyond: conformal, tailored, and adaptive? Lancet Oncol 2012;13(7):e292-300.

62. Thorwarth D, Soukup M, Alber M. Dose painting with IMPT, helical tomotherapy and IMXT: a dosimetric comparison. Radiother Oncol 2008;86(1):30-4.

63. Differding S, Sterpin E, Janssens G, Hanin FX, Lee JA, Grégoire V. Methodology for adaptive and robust FDG-PET escalated dose painting by numbers in head and neck tumors. Acta Oncol 2016;55(2):217-25.

64. Madani I, Duprez F, Boterberg T, Van de Wiele C, Bonte K, Deron P, et al. Maximum tolerated dose in a phase I trial on adaptive dose painting by numbers for head and neck cancer. Radiother Oncol 2011;101(3):351-5

65. Thorwarth D, Welz S, Mönnich D, Pfannenberg C, Nikolaou K, Reimold M, et al. Prospective evaluation of a tumor control probability model based on dynamic (^{18}F)-FMISO PET for head-and-neck cancer radiotherapy. J Nucl Med 2019;60(12):1698-1704.

66. Henriques de Figueiredo B, Zacharatou C, Galland-Girodet S, Benech J, De Clermont-Gallerande H, Lamare F, et al. Hypoxia imaging with (^{18}F)-FMISO-PET for guided dose escalation with intensity-modulated radiotherapy in head-and-neck cancers. Strahlenther Onkol 2015;191(3):217-24.

67. Lee N, Schoder H, Beattie B, Lanning R, Riaz N, McBride S, et al. Strategy of using intratreatment hypoxia imaging to selectively and safely guide radiation dose de-escalation concurrent with chemotherapy for locoregionally advanced human papillomavirus-related oropharyngeal carcinoma. Int J Radiat Oncol Biol Phys 2016;96(1):9-17.

68. Yan D, Chen S, Krauss DJ, Chen PY, Chinnaiyan P, Wilson GD. Tumor voxel dose-response matrix and dose prescription function derived using (^{18}F)-FDG PET/CT images for adaptive dose painting by number. Int J Radiat Oncol Biol Phys 2019;104(1):207-218.

69. Calais J, Dubray B, Nkhali L, Thureau S, Lemarignier C, Modzelewski R, et al. High FDG uptake areas on pre-radiotherapy PET/CT identify preferential sites of local relapse after chemoradiotherapy for locally advanced oesophageal cancer. Eur J Nucl Med Mol Imaging 2015;42(6):858-67.

70. Encaoua J, Abgral R, Leleu C, El Kabbaj O, Caradec P, Bourhis D, et al. [Radiotherapy volume delineation based on (^{18}F)-fluorodeoxyglucose positron emission tomography for locally advanced or inoperable oesophageal cancer.] Cancer Radiother 2017;21(4):267-275.

71. Yue J, Chen L, Cabrera AR, Sun X, Zhao S, Zheng F, et al. Measuring tumor cell proliferation with 18F-FLT PET during radiotherapy of esophageal squamous cell carcinoma: a pilot clinical study. J Nucl Med 2010;51(4):528-34

72. Zhang G, Han D, Ma C, Lu J, Sun T, Liu T, et al. Gradient-based delineation of the primary GTV on FLT PET in squamous cell cancer of the thoracic esophagus and impact on radiotherapy planning. Radiat Oncol 2015;10:11.

73. Gerbaudo VH, Killoran JH, Kim CK, Hornick JL, Nowak JA, Enzinger PC, et al. Pilot study of serial FLT and FDG-PET/CT imaging to monitor response to neoadjuvant chemoradiotherapy of esophageal adenocarcinoma: correlation with histopathologic response. Ann Nucl Med 2018;32(3):165-174.

74. Randa Tao, Bryan Ager, Shane Lloyd, Anna Torgeson, Michelle Denney, David Gaffney, et al. Hypoxia imaging in upper gastrointestinal tumors and application to radiation therapy. J Gastrointest Oncol 2018;9(6):1044-1053.

75. Arnesen MR, Rekstad BL, Stokke C, Bruheim K, Løndalen AM, Hellebust TP, et al. Short-course PET based simultaneous integrated boost for locally advanced cervical cancer. Radiat Oncol 2016;11:39.

76. Wujanto C, Choo BA, Tan D, Ilancheran A, Ng J, Low JJH, et al. Does external beam radiation boost to pelvic lymph nodes improve outcomes in patients with locally advanced cervical cancer? BMC Cancer 2019;19(1):385.

77. Ariga T, Toita T, Kasuya G, Nagai Y, Inamine M, Kudaka W, et al. External beam boost irradiation for clinically positive pelvic nodes in patients with uterine cervical cancer. J Radiat Res 2013;54(4):690-6.

78. Monninkhof EM, van Loon JWL, van Vulpen M, Kerkmeijer LGW, Pos FJ, Haustermans K, et al. Standard whole prostate gland radiotherapy with and without lesion boost in prostate cancer: Toxicity in the FLAME randomized controlled trial. Radiother Oncol 2018;127(1):74-80.

79. Pinkawa M, Piroth MD, Holy R, Klotz J, Djukic V, Corral NE, et al. Dose-escalation using intensity-modulated radiotherapy for prostate cancer - evaluation of quality of life with and without (^{18}F)-choline PET-CT detected simultaneous integrated boost. Radiat Oncol 2012;7:14.

80. Zamboglou C, Wieser G, Hennies S, Rempel I, Kirste S, Soschynski M, et al. MRI versus (^{68}Ga)-PSMA PET/CT for gross tumour volume delineation in radiation treatment planning of primary prostate cancer. Eur J Nucl Med Mol Imaging 2016;43(5):889-897

81. Zamboglou C, Schiller F, Fechter T, Wieser G, Jilg CA, Chirindel A, et al. (^{68}Ga)-HBED-CC-PSMA PET/CT versus histopathology in primary localized prostate cancer: a voxel-wise comparison. Theranostic 2016;6(10):1619-28.

82. Zschaeck S, Lohaus F, Beck M, Habl G, Kroeze S, Zamboglou C, et al. PSMA-PET based radiotherapy: a review of initial experiences, survey on current practice and future perspectives. Radiat Oncol 2018;13(1):90.

83. Zamboglou C Thomann B, Koubar K, Bronsert P, Krauss T, Rischke HC, et al. Focal dose escalation for prostate cancer using (^{68}Ga)-HBED-CC PSMA PET/CT and MRI: a planning study based on histology reference. Radiat Oncol 2018;13(1):81.

Figure legend

Figure 1. Impact of positon emission tomography with computed tomography for image-guided radiotherapy. (a,b) PET imaging before treatment; (a) FDG PET; (b) Fmiso PET; (c) FDG PET during radiation with good response but an oesophagitis. FDG: fluorodeoxyglucose; Fmiso: fluoromisonidazole; PET: positon emission tomography.

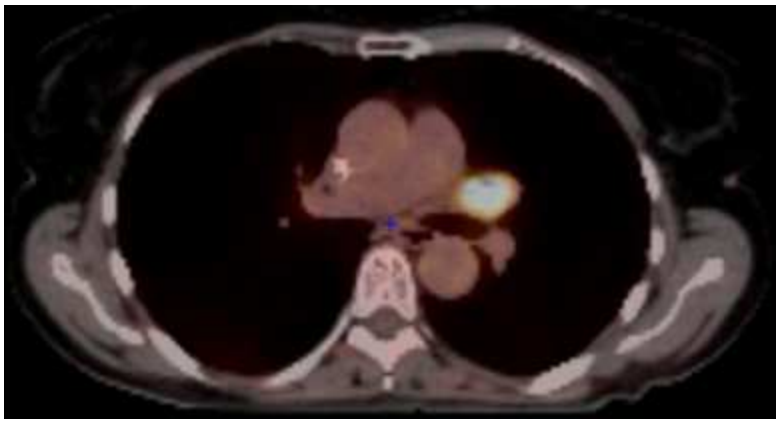

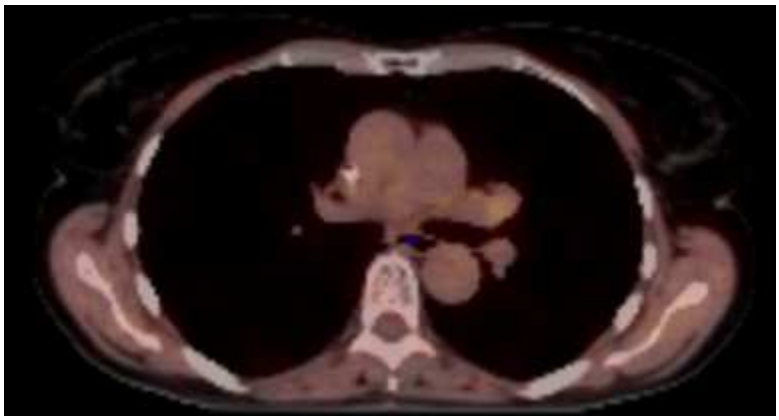

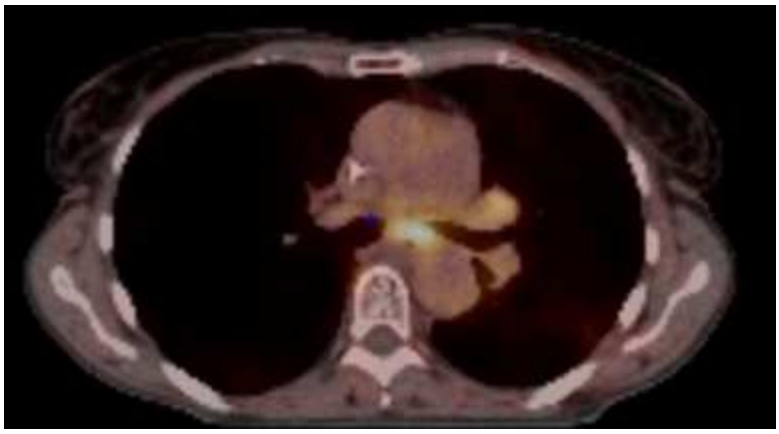

Table 1. Synthesis of current recommendations for the use of positon emission tomography for radiotherapy planification.

Primary tumour	Staging	Targeting
Lung	Recommended for non or oligometastatic non small cell lung cancer	Exclusion of atelectasis Inclusion of PET positive nodes (if histologic examination is not feasible to exclude false positive)
Head and neck	Recommended for locally advanced head and neck squamous cell carcinoma	Help in delineation of the primary gross tumour volume for locally advanced cancer User-independent segmentation algorithms
Oesophagus	Recommended before chemoradiotherapy	Detection of distant nodes Help in defining craniocaudal limits
Lymphoma	Recommended for high grade lymphoma (Hodgkin and non Hodgkin diseases)	Detection of involved nodes or involved sites, especially in case of involved node or involved site radiotherapy